

Insulinoma Presenting as New-Onset Psychiatric Symptoms

Lauren Cusick, PA-S, Peter Sandor, MHS, PA-C
Quinnipiac University Physician Assistant Program

Introduction

- Insulinomas are rare insulin-secreting neuroendocrine tumors that occur in approximately four out of a million people each year.¹
- Observational studies show that they occur more often in women and those over the age of 50.^{2,3}
- These pancreatic beta cell tumors are mostly benign and occur sporadically. However, less than 10% of cases are associated with Multiple Endocrine Neoplasia Type 1 (MEN1).^{2,3}
- Table 1 displays the most common neuroglycopenic and autonomic symptoms associated with insulinomas and hypoglycemia.²
- One retrospective cohort study found that these symptoms most often occur during a period of fasting. However, postprandial symptoms have also been observed in a quarter of patients.³
- The variability of the clinical presentation may lengthen the time between the onset of symptoms and the diagnosis of the insulinoma from days to years.¹
- Diagnosis is often made based on clinical presentation and the presence of hypoglycemia and hyperinsulinemia during a period of fasting or spontaneously (Table 2).⁴
- Glucose, insulin, C-peptide, and proinsulin plasma levels are drawn to differentiate between endogenous and exogenous insulin as the cause of hypoglycemia as well as to confirm hyperinsulinemia.⁴
- Common differential diagnoses include: MEN1, sulfonylurea-induced hypoglycemia, insulin autoimmune hypoglycemia, noninsulinoma pancreatogenous hypoglycemia syndrome (NIPHS), and post-gastric bypass hypoglycemia.⁴
- Imaging modalities that have high sensitivities for locating insulinomas are MRI and CT preoperatively and sonography intraoperatively.⁵

Table 1. Neuroglycopenic and Autonomic Symptoms Associated with Insulinoma²

Diaphoresis	Tremors
Anxiety	Palpitations
Drowsiness	Confusion
Amnesia	Hunger
Unconsciousness	Headache
Seizure	Lightheadedness

Table 2. Diagnostic Criteria of Hyperinsulinemic Hypoglycemia Consistent with Insulinoma⁴

- The presence of autonomic and/or neuroglycopenic symptoms in addition to the following plasma concentrations:
- Glucose <3.0 mmol/l OR <55 mg/dl
 - Insulin ≥ 3.0 μ U/ml
 - C-peptide ≥ 0.2 nmol/l
 - Proinsulin ≥ 5.0 pmol/l

Case Description

History

- A 27-year-old African American male presented to the emergency department with altered mental status following a syncopal event at home characterized by seizure-like activity, vomiting, urinary incontinence, and hypoglycemia with a blood glucose level of 25 mg/dl.
- For the past three months, he experienced delusions of objects going missing, visual hallucinations of objects changing color, feelings of “living in an alternate universe”, and periods of amnesia lasting between minutes and hours.
- He received a diagnosis of delusional disorder following an episode of paranoia one month prior.
- No past medical history.
- Social history significant for daily marijuana use.
- Review of systems positive for difficulty concentrating, loss of appetite, impaired memory, and visual hallucinations.
- No known allergies to medications.
- Family history:
 - Maternal aunt: Type II DM
 - Mother: Asthma

Physical Exam

- Vitals in emergency department:
 - Temperature: 98.2°F
 - Pulse: 62 bpm
 - Blood pressure: 134/93 mm Hg
 - Respiratory rate: 18 bpm
 - Oxygen saturation: 99% on room air
- Oriented to person, place, and time. Cooperative, behaving appropriately, and exhibiting impaired recent memory.
- Head atraumatic, normocephalic.
- Pupils equally round, reactive to light, and accommodating.
- Abdomen soft, nontender, nondistended.
- Normal mood and affect.
- Patient had one episode of visual hallucinations when his blood glucose level was 38 mg/dl which resolved upon administration of dextrose.
- No focal deficits or tremor noted.
- Remainder of physical exam within normal limits.

Differential Diagnosis

- Seizure disorder
- Factitious disorder
- Drug-induced hypoglycemia
- Insulinoma
- MEN1
- Insulin autoimmune hypoglycemia

Diagnostic Results

- Figure 1 displays the patient’s recorded blood glucose levels. During this time, he was placed on a 10% dextrose infusion due to continued hypoglycemia.
- EEG displayed no epileptiform discharges, electroencephalographic seizures, or lateralized focal abnormalities.
- CT of head displayed no intracranial abnormalities.
- Psychiatry diagnosed patient with an adjustment disorder.
- Lab values:
 - Plasma glucose: 49 mg/dl
 - Plasma insulin: 12.1 μ U/ml
 - Plasma C-peptide: 1.5 nmol/l
 - Plasma proinsulin: 15.2 pmol/l
 - IGF-1: 146 ng/ml (60-329 ng/ml in males ages 26-30)
 - Prolactin: 4.5 ng/ml (<20 ng/ml in males)
 - Calcium: 9.6 mg/dl
 - Phosphate: 3.8 mg/dl
- Plasma lab values showed the absence of both sulfonylurea concentrations and insulin antibodies.
- Urine drug screen was positive for marijuana.
- Patient did not meet criteria for MEN1 diagnosis based on IGF-1, prolactin, calcium, and phosphate values.
- Figure 2 shows an abdominal ultrasound that displays a 1.4 x 1.2 cm hypoechoic mass in the region of the pancreatic head that does not demonstrate vascularity or calcifications.
- Abdominal MRI with and without contrast showed a 1.2 cm mildly enhancing nodule in the uncinate process of the pancreas.

Discussion

- Surgery was performed and an encapsulated 1.2 x 1.4 cm tumor was removed from the uncinate process toward the superior aspect of the pancreatic head. Pathology later confirmed that this tumor was an insulinoma.
- According to the literature, most benign insulinoma cases consist of a solitary tumor located in the head of the pancreas with a median diameter less than 2 cm.²
- This patient’s unusual clinical presentation was similar to those of two insulinoma cases in which the individuals had primarily psychiatric symptoms including delusions, hallucinations, and disordered behavior. In both cases, symptoms resolved following treatment.^{6,7}

Recommended Treatment

- Research shows that enucleation is the preferred surgical technique for the removal of an insulinoma.⁵
- Patients with nonmalignant insulinomas who undergo surgical excision often make a full recovery and return to a state of euglycemia.²

Case Outcome

- Since removal of the tumor, blood glucose levels have remained within normal limits and psychiatric symptoms have resolved.

Conclusion

- Insulinomas are rare pancreatic islet cell tumors that may go undiagnosed for months to years due to the variability of the clinical presentation.
- Insulinoma patients with a clinical presentation more consistent with that of a psychiatric disorder make it difficult for clinicians to recognize that symptoms are the result of hypoglycemia.
- It is crucial that all patients with psychiatric clinical presentations are assessed for an organic cause of their symptoms to prevent misdiagnosis and the delay of appropriate treatment.

References

- Service FJ, Dale AJ, Elveback LR, Jiang NS. Insulinoma: clinical and diagnostic features of 60 consecutive cases. *Mayo Clin Proc.* 1976;51(7):417-429.
- Peltola E, Hannula P, Huhtala H, et al. Characteristics and outcomes of 79 patients with an insulinoma: a nationwide retrospective study in Finland. *Int J Endocrinol.* 2018;2018(1):205948. doi: 10.1155/2018/205948.
- Placzkowski KA, Vella A, Thompson GB, et al. Secular trends in the presentation and management of functioning insulinoma at the Mayo Clinic, 1987-2007. *J Clin Endocrinol Metab.* 2009;94(4):1069-1073. doi: 10.1210/jc.2008-203.
- Cryer PE, Axelrod L, Grossman AB, et al. Evaluation and management of adult hypoglycemic disorders: an Endocrine Society Clinical Practice Guideline. *J Clin Endocrinol Metab.* 2009;94(3):709-728. doi: 10.1210/jc.2008-1410.
- Mehrabi A, Fischer L, Hafezi M, et al. A systematic review of localization, surgical treatment options, and outcome of insulinoma. *Pancreas.* 2014;43(5):675-686. doi: 10.1097/MPA.0000000000000110.
- Aggarwal S, Nand N, Damle N, Godara R, Kumar R. Insulinoma presenting with neuropsychiatric symptoms. *J Assoc Physicians India.* 2017;65(6):95-96. Retrieved from http://www.japi.org/june_2017/15_cr_insulinoma.html.
- González-Clavijo AM, Fierro-Maya LF. Patient with neuropsychiatric symptoms and insulinoma of difficult preoperative localization. *Rev.Fac.Med.* 2014;62(4):637-640. doi: 10.15446/revfacmed.v62n4.44498.

Figure 1. Blood Glucose Levels During the First 120 Hours of Admission

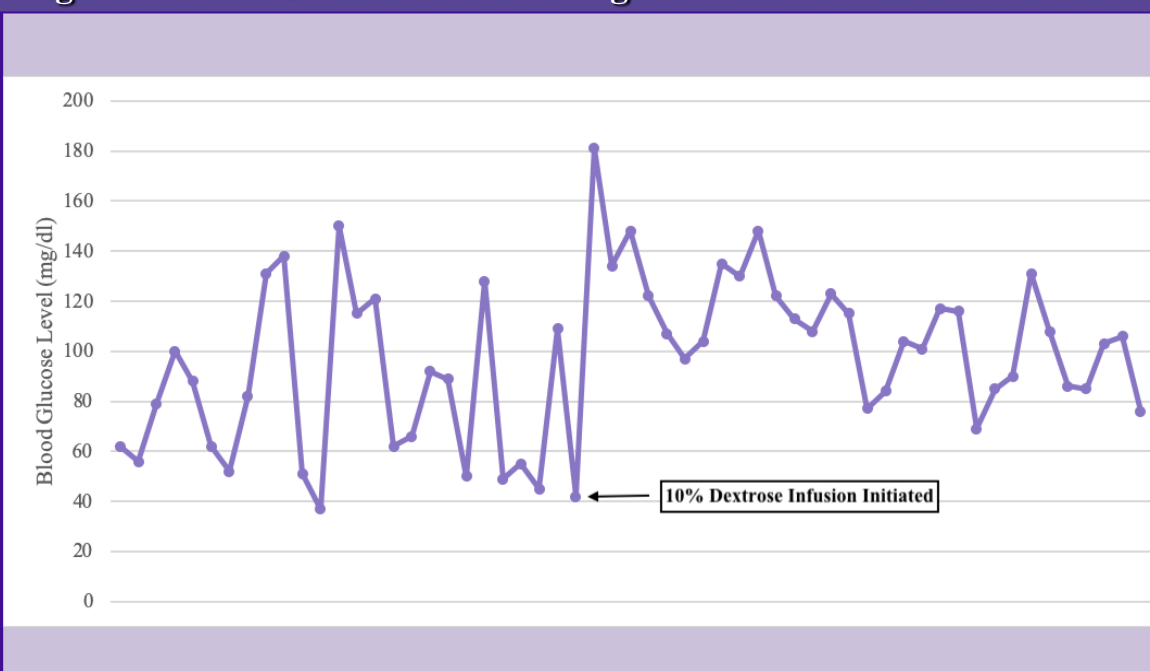


Figure 2. Abdominal Ultrasound of Pancreatic Head

