

# Otorhinolaryngologica Italica

Volume 35

5

October 2015

*Official Journal of the Italian Society of Otorhinology  
Head and Neck Surgery*

Organo Ufficiale della Società Italiana di Otorinolaringologia  
e Chirurgia Cervico-Facciale

## Review

Outcome predictors of treatment effectiveness  
for fungal malignant external otitis: a systematic review

## Head and neck

Differential diagnosis of parotid gland tumours:  
which magnetic resonance findings should be taken in account?

## Basic research in otorhinology

Macrophageal infiltration and microvessel density in laryngeal carcinoma:  
study of 52 cases

## Salivary glands

Learning curve in diagnostic and interventional sialendoscopy  
for obstructive salivary diseases

## Sleep disorders

Which cephalometric analysis for maxillo-mandibular surgery  
in patients with obstructive sleep apnoea syndrome?

## Otology

Cartilage ossiculoplasty in cholesteatoma surgery:  
hearing results and prognostic factors

## Audiology

Binaural squelch and head shadow effects in children  
with unilateral cochlear implants and contralateral hearing aids

## Clinical techniques and technology

3D computed tomographic evaluation of the upper airway space of patients  
undergoing mandibular distraction osteogenesis for micrognathia

## Case series and reports

Ossifying fibromas of the paranasal sinuses: diagnosis and management

Surgical approach to isolated bilateral orbital floor fractures

Bleomycin sclerotherapy for lymphatic malformation  
after unsuccessful surgical excision: case report

# ACTA

PACINI  
EDITORE  
MEDICINA

[www.actaitalica.it](http://www.actaitalica.it)



# ACTA

## Otorhinolaryngologica Italica

*Official Journal of the Italian Society of Otorhinolaryngology - Head and Neck Surgery*  
Organo Ufficiale della Società Italiana di Otorinolaringologia e Chirurgia Cervico-Facciale

Former Editors-in-Chief: C. Calearo†, E. de Campora, A. Staffieri, M. Piemonte, F. Chiesa

### Editorial Board

*Editor-in-Chief:*

G. Paludetti

*President of S.I.O.:*

R. Filipo

*Former Presidents of S.I.O.  
and Editors-in-Chief:*

I. De Vincentiis, D. Felisati, L. Coppo,  
G. Zaoli, P. Miani, G. Motta,  
L. Marcucci, A. Ottaviani,  
P. Puxeddu, M. Maurizi, G. Sperati,  
D. Passali, E. de Campora, A. Sartoris,  
P. Laudadio, M. De Benedetto,  
S. Conticello, D. Casolino,  
A. Rinaldi Ceroni, M. Piemonte,  
A. Staffieri, F. Chiesa, R. Fiorella,  
A. Camaioni, A. Serra, G. Spriano

### Editorial Staff

*Editor-in-Chief:*

G. Paludetti

*Deputy Editor:*

J. Galli

*Associate Editors:*

G. Almadori, F. Ottaviani

*Editorial Coordinator:*

E. De Corso

*Editorial Assistant:*

P. Moore

*Treasurer:*

L. de Campora

### Italian Scientific Board

L. Bellussi, G. Danesi, C. Grandi,

A. Martini, L. Pignataro, F. Raso,

R. Speciale, I. Tasca

### International Scientific Board

J. Betka, P. Clement, M. Halmagyi,

L.P. Kowalski, M. Pais Clemente,

J. Shah, H. Stammberger, R. Laszig,

G. O'Donoghue, R.J. Salvi, R. Leemans,

M. Remacle, F. Marshal, H.P. Zenner,

B. Scola Yurrita, R.W. Gilbert

### Editorial Office

*Editor-in-Chief:*

G. Paludetti

Department of Head and Neck Surgery -  
Otorhinolaryngology

Catholic University of the Sacred Heart

“A. Gemelli” Hospital

L.go F. Vito, 1 - 00168 Rome, Italy

Tel. +39 06 30154439

Fax + 39 06 3051194

actaitalicaorl@rm.unicatt.it

*Editorial Coordinator:*

E. De Corso

eugenio.decorso@policlinicogemelli.it

*Editorial Secretary:*

R. Gallus

gallusroberto@gmail.com

### Argomenti di Acta

**Otorhinolaryngologica Italica**

*Editor-in-Chief:* G. Paludetti

*Editorial Coordinator:* M.R. Marchese

raffaellamarchese@gmail.com

© Copyright 2015 by

Società Italiana di Otorinolaringologia

e Chirurgia Cervico-Facciale

Via Luigi Pigorini, 6/3

00162 Rome, Italy

### Publisher

Pacini Editore Srl

Via Gherardesca, 1

56121 Pisa, Italy

Tel. +39 050 313011

Fax +39 050 3130300

info@pacineditore.it

www.pacinieditore.it

*Acta Otorhinolaryngologica Italica is cited*

*in Index Medicus, MEDLINE, PubMed*

*Central, Science Citation Index Expanded,*

*Scopus, DOAJ, Open-J Gate, Free Medical*

*Journals, Index Copernicus, Socolar*

*Journal Citation Reports:*

*Impact Factor 1.640*

*Acta Otorhinolaryngologica Italica is*

*available on Google Scholar*

PACINI  
EDITORE  
MEDICINA

www.actaitalica.it



# Contents

## Review

- Outcome predictors of treatment effectiveness for fungal malignant external otitis: a systematic review  
*Predittori di efficacia nel trattamento dell'otite esterna maligna fungina: una review sistematica*  
M. Mion, R. Bovo, R. Marchese-Ragona, A. Martini. . . . . pag. 307

## Head and neck

- Differential diagnosis of parotid gland tumours: which magnetic resonance findings should be taken in account?  
*Diagnosi differenziale dei tumori parotidici: quali caratteristiche di risonanza magnetica considerare?*  
T. Tartaglione, A. Botto, M. Sciandra, S. Gaudino, L. Danieli, C. Parrilla, G. Paludetti, C. Colosimo . . . . . » 314

## Basic research in otorhinolaryngology

- Macrophageal infiltration and microvessel density in laryngeal carcinoma: study of 52 cases  
*Infiltrazione macrofagica e densità capillare nel carcinoma della laringe. Studio su 52 casi*  
T.M. Popov, T. Dikov, T.E. Goranova, G. Stancheva, R.P. Kaneva, S. Todorov, O. Stoyanov, J. Rangachev, T. Marinov, D.P. Popova, V.I. Mitev, D. Konov . . . . . » 321

## Salivary glands

- Learning curve in diagnostic and interventional sialendoscopy for obstructive salivary diseases  
*Curva di apprendimento nella scialoendoscopia diagnostica e interventistica per le patologie salivari ostruttive*  
P. Farneti, G. Macrì, G. Gramellini, M. Ghirelli, F. Tesei, E. Pasquini . . . . . » 325

## Sleep disorders

- Which cephalometric analysis for maxillo-mandibular surgery in patients with obstructive sleep apnoea syndrome?  
*Quale analisi cefalometrica per la chirurgia maxillo-mandibolare in pazienti con sindrome delle apnee ostruttive notturne?*  
B. Brevi, A. Di Blasio, C. Di Blasio, F. Piazza, L. D'Ascanio, E. Sesenna . . . . . » 332

## Otology

- Cartilage ossiculoplasty in cholesteatoma surgery: hearing results and prognostic factors  
*Risultati uditivi e fattori prognostici nell'ossiculoplastica con cartilagine in pazienti affetti da otite cronica colesteatomatosa*  
N. Quaranta, S. Taliente, F. Coppola, I. Salonna . . . . . » 338

## Audiology

- Binaural squelch and head shadow effects in children with unilateral cochlear implants and contralateral hearing aids  
*Gli effetti squelch binaurale e ombra nei bambini con impianto cocleare monolaterale e protesi acustica controlaterale*  
H. Dincer D'Alessandro, G. Sennaroglu, E. Yücel, E. Belgin, P. Mancini . . . . . » 343

## Clinical techniques and technology

- 3D computed tomographic evaluation of the upper airway space of patients undergoing mandibular distraction osteogenesis for micrognathia  
*Valutazione mediante tomografia assiale computerizzata 3D delle vie aeree superiori di pazienti sottoposti a distrazione osteogenetica mandibolare per micrognazia*  
A. Bianchi, E. Betti, G. Badiali, F. Ricotta, C. Marchetti, A. Tarsitano . . . . . » 350

## Case series and reports

- Ossifying fibromas of the paranasal sinuses: diagnosis and management  
*Fibroma ossificante dei seni paranasali: diagnosi e management*  
M. Ciniglio Appiani, B. Verillaud, D. Bresson, E. Sauvaget, J.-P. Blancal, J.-P. Guichard, J.-P. Saint Maurice, M. Wassef, A. Karligkiotis, R. Kania, P. Herman . . . . . » 355

- Surgical approach to isolated bilateral orbital floor fractures  
*Approccio chirurgico alle fratture isolate bilaterali del pavimento orbitario*  
M. Giarda, A. Tavolaccini, F. Arcuri, M. Brucoli, A. Benech . . . . . » 362

- Bleomycin sclerotherapy for lymphatic malformation after unsuccessful surgical excision: case report  
*Scleroterapia con bleomicina per malformazioni linfatiche dopo fallimento dell'escissione chirurgica: caso clinico*  
A. Vlahovic, A. Gazikalovic, O. Adjic . . . . . » 365

- In Memoriam of Prof. Andrea Bosatra  
M. Spanio, A. Semeraro . . . . . » 368

- Calendar of events - Italian and International Meetings and Courses . . . . . » 369

REVIEW

# Outcome predictors of treatment effectiveness for fungal malignant external otitis: a systematic review

## *Predittori di efficacia nel trattamento dell'otite esterna maligna fungina: una review sistematica*

M. MION, R. BOVO, R. MARCHESE-RAGONA, A. MARTINI

Institute of Otolaryngology, Department of Neurosciences, Padova University, Italy

### SUMMARY

The aim of this review is to summarise literature data on clinical aspects and traditional management of fungal malignant external otitis (FMEO), and to identify potential predictive factors of positive treatment outcome. Articles were initially selected based on their titles or abstracts. Full articles were then retrieved and further scrutinised according to predetermined criteria. Reference lists of selected articles were searched for any missed publications. The selected articles were methodologically evaluated. Of an initial 143 references, 14 were selected that focalised on the management of FMEO. The majority of studies demonstrated a correlation between treatment effectiveness, assessed as symptom resolution, and clinical and management variables: abstention from surgical debridement, absence of facial palsy, *Aspergillus* spp. as causative pathogen and absence of imaging findings at diagnosis and follow-up. The effectiveness of FMEO treatment depends on the assessment of cranial nerve state, the causative pathogen and imaging findings. Above all, absence of facial nerve palsy, *Aspergillus* spp. and absence of radiological signs at diagnosis and during follow-up correlate with symptom resolution. The fact that conservative treatment may be associated with a better outcome than surgical debridement could purely reflect that patients with more aggressive and advanced illness required debridement, whereas milder disease was treated conservatively. Thus, caution should be advised in the interpretation of data due to the need for further trials on the topic.

KEY WORDS: Fungal • Malignant external otitis • Predictive factors • Review • Treatment

### RIASSUNTO

Obiettivo dello studio è stato riassumere i dati della letteratura sugli aspetti clinici e la gestione abituale dell'otite esterna maligna fungina (OEMF), ed identificare possibili fattori predittivi di esito positivo del trattamento. Gli articoli sono stati inizialmente selezionati sulla base del titolo e degli abstract. Sono poi stati recuperati ed analizzati per intero seguendo criteri predeterminati. È stata stilata una lista di riferimento degli articoli selezionati per cercare eventuali pubblicazioni mancati. Gli studi raccolti sono stati infine valutati metodologicamente. Dei 143 articoli iniziali, ne sono stati selezionati 14 focalizzati sulla gestione dell'OEMF. La maggior parte di questi ha dimostrato una correlazione tra l'efficacia del trattamento, inteso come risoluzione dei sintomi, ed alcune variabili cliniche e di gestione della patologia quali l'astensione da procedure chirurgiche invasive, l'assenza di paralisi facciale, l'*Aspergillus* spp come patogeno causante e l'assenza di segni radiologici alla diagnosi e nel corso del follow-up. L'efficacia del trattamento dipende dalla valutazione dello stato dei nervi cranici, dal patogeno alla base e dai segni radiologici, più precisamente: l'assenza di paralisi facciale, l'*Aspergillus* spp e l'imaging negativo alla diagnosi e durante il follow-up correlano con la risoluzione dei sintomi. L'evidenza che il trattamento farmacologico possa associarsi ad un miglior outcome rispetto a procedure chirurgiche invasive potrebbe semplicemente riflettere il fatto che pazienti affetti da una patologia più avanzata richiedono un approccio più aggressivo mentre le forme più lievi possono essere trattate in modo conservativo. È necessario quindi prestare attenzione nell'interpretazione dei dati a causa della necessità di ulteriori studi sull'argomento.

PAROLE CHIAVE: Fungina • Otite esterna maligna • Fattori predittivi • Review • Trattamento

Acta Otorhinolaryngol Ital 2015;35:307-313

### Introduction

Malignant external otitis (MEO) is an aggressive and potentially fatal infection that originates in the external ear canal and spreads progressively along the soft tissue and bone of the skull base<sup>1</sup>. Since Chandler's publication of the first comprehensive case series of MEO in 1968<sup>1</sup>, the most commonly reported causative pathogen is *Pseudomonas aeruginosa*.

Fungi are rarely involved in MEO, but have been identified in immunocompromised patients, such as those with AIDS or acute leukaemia. *Aspergillus fumigatus* is the most common cause of fungal malignant external otitis (FMEO)<sup>2</sup>. *Aspergillus* FMEO occurs in immunocompromised patients, usually with profound and long-lasting neutropenia or under long-term steroid therapy, as well as in individuals with uncontrolled diabetes mellitus<sup>2</sup>.

The disease manifests as a painful inflammation of the external ear canal, associated with purulent otorrhoea and granulation polyps. Otagia is presenting symptom in 75% of cases<sup>3</sup>; it is intense, particularly during the night, and associated with severe temporal or occipital headache. The purulent otorrhoea appears with a frequency ranging from 50 to 80% and varies from a moist and modest secretion to greenish malodorous and abundant exudates. Histologically, granulation tissue is characterised by non-specific inflammation with inflammatory cell infiltration and hyperplasia of squamous epithelium<sup>3</sup>.

The progression of the disease has been divided into three clinical stages: in the first, there is infection of the external auditory canal and adjacent soft tissues with severe pain, with or without facial nerve palsy. The second stage is characterised by extension of infection with osteitis of skull base and temporal bone, or multiple cranial nerve neuropathies. In the third stage, the infection reaches the intracranial structures, neck spaces and large blood vessels. This stage is always associated with poor prognosis. The most frequent causes of death are meningitis, large vessel septic thrombophlebitis or rupture, septicaemia, pneumonia caused by inhalation for vagal paralysis and cerebrovascular accident<sup>3</sup>.

The treatment of FMEO classically includes extensive surgical debridement and intensive long-term antifungal therapy with amphotericin B and/or itraconazole and/or voriconazole. Despite this management, FMEO is associated with substantial morbidity and mortality, mostly due to late diagnosis and patient comorbidities<sup>2</sup>. Treatment failure can also be a result of suboptimal therapeutic management as a consequence of antifungal agent toxicity. In particular, the side effects of amphotericin B, particularly renal failure, may require interruption of antifungal agents or decrease in dosage<sup>2</sup>, even if newer liposomal amphotericin formulations have largely eliminated renal failure as a side effect of this therapy.

Based on these premises, the aim of this review was to summarise literature data on clinical aspects and traditional management of FMEO, and to identify potential predictive factors of positive treatment outcome.

## Materials and methods

### Search strategy

The search strategy was designed to include papers on the basis of their relevance for answering the clinical research question: "Can FMEO treatment effectiveness, assessed as symptoms' resolution, be predicted by any clinical and/or management variable?"

The inclusion criteria were based on the type of the study: articles that were published after 2000, focusing on clinical manifestations, diagnostic tools, pos-

sible therapies and pitfalls of FMEO. The choice to limit the included studies to those publishing after 2000 was due to the need for an updated approach to the disease.

In order to identify relevant studies, as the first step, a search was carried out in the Medline databases using a combination of MeSH and keyword terms related to FMEO (i.e., fungal or mycotic malignant external otitis). No language limitations were set.

This first search step allowed the identification of a list of potential citations for inclusion in this review. Titles and abstracts on this list were screened by one independent reviewer (MM), who then determined whether to retrieve the full-text or not on the basis of the citations' potential relevance to the review's clinical research question.

As a further expansion of the search, searches were performed "by hand" within the Scopus database, the authors' personal libraries, and the references lists of the full-text studies were performed to identify potential additional relevant citations.

All the retrieved full-texts were included in the review by consensus of all authors.

Data extraction from the included publications was performed by the same author who performed the initial search. Data regarding the demographic features of the sample, comorbidities, pathogens, complications, imaging findings, treatments and symptoms resolution were put into descriptive tables. All data have been represented as they appeared in the original publication.

**Table I.** Grading of evidence statements.

Level of evidence	Type of evidence
1++	High quality meta-analyses, systematic reviews of RCTs, or RCTs with a very low risk of bias.
1+	Well-conducted meta-analyses, systematic reviews of RCTs, or RCTs with a low risk of bias.
1-	Meta-analyses, systematic reviews of RCTs, or RCTs with a high risk of bias <sup>*</sup> .
2++	High-quality systematic reviews of case-control or cohort studies. High quality case-control or cohort studies with a very low risk of confounding, bias or chance and a high probability that the relationship is casual.
2+	Well-conducted case-control or cohort studies with a low risk of confounding, bias or chance and a moderate probability that the relationship is casual.
2-	Case-control or cohort studies with a high risk of confounding, bias or chance and a significant risk that the relationship is casual <sup>*</sup> .
3	Non-analytic studies (for example case reports, case series).
4	Expert opinion, formal consensus.

<sup>\*</sup> Studies with a level of evidence "-" are not used as a basis for making recommendation; RCT: randomised controlled trial

### Quality assessment

As a quality assessment strategy, the included studies were methodologically appraised according to the National Institute for Health and Clinical Excellence's levels of evidence (Table I).

### Statistical analyses

Descriptive baseline and follow-up data were presented for each patient. Statistical analyses were conducted with the aim to identify potential predictors of treatment effectiveness.

Numerical continuous variables were expressed as means  $\pm$  standard deviation and nominal variables were described by the absolute and relative (%) frequency.

For all statistical procedures, symptom resolution was the main outcome variable which is adopted in a regression analysis to be predicted by the dichotomic study variables (i.e. sex [M/F], diabetes [yes/no], pathogen [*Aspergillus*/no *Aspergillus*], facial palsy [yes/no], imaging findings [yes/no], treatment [monotherapy/no monotherapy] [surgical debridement/no surgical debridement]).

For dichotomic variables, single variable regression analysis was performed, with the aim to screen among the potential predictors of the outcome variable. For all statistical analyses, the level of significance was set at  $p < 0.05$ . All statistical procedures were performed with the Statistical Package for the Social Sciences (SPSS 19.0; SPSS Inc., Chicago, Ill).

## Results

### Literature search

One hundred forty-three citations were retrieved from the first phase of the search. A total of 132 references were excluded after screening of the titles and abstracts because they were clearly not relevant for this review, published before the year 2000, were not relevant to the clinical research question, or were duplicate studies. Full texts of the remaining 11 references were retrieved, along with three additional full text articles that were identified as potentially relevant by the second-step search expansion. Based on the inclusion criteria, 14 articles were selected for inclusion in this review (Fig. 1).

### Overview of analysed studies

Of the 14 studies included in the review, all except three<sup>2,4,5</sup> are case reports. The average age of the 25 subjects is  $62.6 \pm 18$ , with 19 males and six females (Tables IIa, IIb). 80% of patients had diabetes mellitus.

Regarding the pathogen implicated, in the majority of cases *Aspergillus* spp. was found (61%), followed by *Candida* spp. (27%) and *Scedosporium apiospermum* (7%). Only one study<sup>6</sup> described *Malassezia sympodialis* as the cause of the disease.

52% of the subjects developed facial nerve palsy.

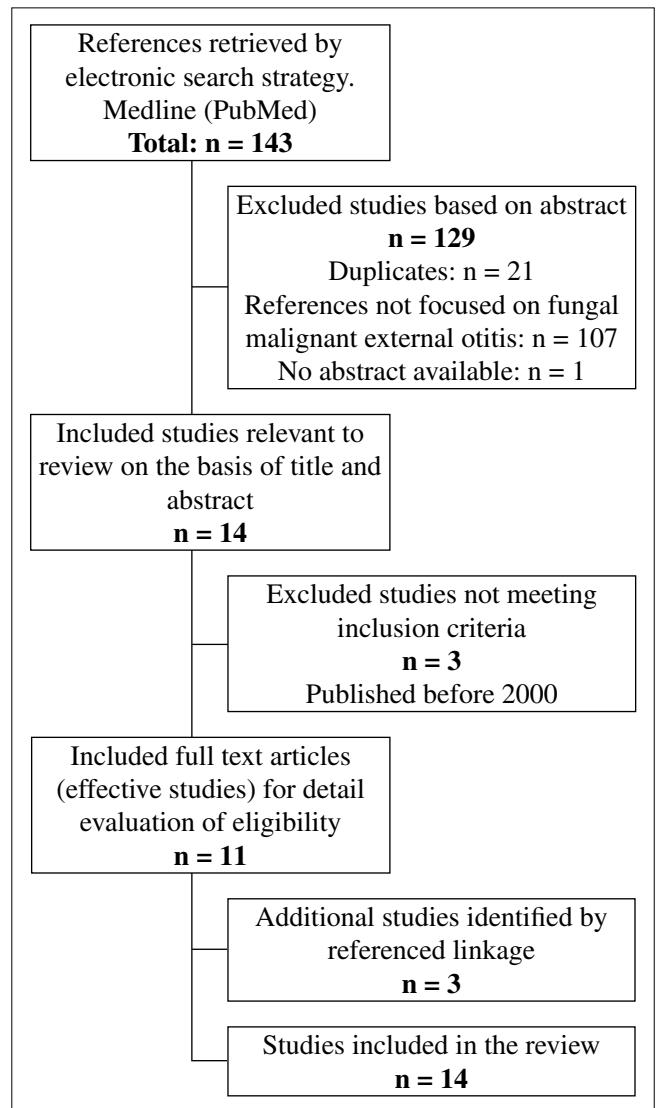


Fig. 1. Study flow diagram.

Table IIa. Baseline and follow-up data on the study population.

	All
No. of patients	25
Sex	19 (M) / 6 (F)
Age (range)	62.6 $\pm$ 18 (7-85)
Diabetes	80%
<i>Aspergillus</i> spp.	16 (61%)
<i>Candida</i> spp.	7 (27%)
<i>S. apiospermum</i>	2 (7%)
<i>M. sympodialis</i>	1 (4%)
Facial nerve palsy	13 (52%)
Imaging findings	9 (36%)
Monotherapy	16 (64%)
Duration	178.4 days
Combination therapy	9 (36%)
Duration	151.62 days
Surgical debridement	14 (56%)
Symptom resolution	15 (60%)

**Table IIb.** Summary of reviewed studies.

Main author	Year of paper	Age (y)	M/F	Comorbidity	Pathogen	Nerve palsy	CT or MRI findings	Therapy	SD	Symptom resolution
Walton et al. <sup>7</sup>	2014	83	M	DM2	<i>A. flavus</i>	VII	Y	Voric iv (2 wk) then oral (11 mo)	N	Y
Tarazi et al. <sup>4</sup>	2012	77	M	DM2	<i>Aspergillus</i>	No	Unspec	AmB then voric	N	Y
Tarazi et al. <sup>4</sup>	2012	85	F	DM2	<i>Aspergillus</i>	VII	Unspec	AmB then voric	N	Y
Tarazi et al. <sup>4</sup>	2012	70	F	DM2	<i>Aspergillus</i>	No	Unspec	Voric	N	Y
Bovo et al. <sup>3</sup>	2012	69	M	DM2	<i>A. fumigatus</i>	VII	Y	Voric iv (400 mg x2 l day, then 200 mg x2 for 3 mo)	Y	No - facial palsy
Lilic et al. <sup>8</sup>	2012	70	M	DM2	<i>S. apiospermum</i>	VII	Y	Ciprofloxacin (oral + topical)	N	No - died
Halsey et al. <sup>9</sup>	2011	62	M	AML	<i>A. wentii</i>	VII	Unspec	AmB (2 wk) then Itz (8 wk)	Y	No - facial palsy
Hamzany et al. <sup>5</sup>	2011	68	M	DM2	<i>Candida</i>	VII	Y	Voric + cloxacillin (42 days)	Y	No - died
Hamzany et al. <sup>5</sup>	2011	68	M	DM2	<i>Candida</i>	VII	Y	Voric (42 days)	Y	No
Hamzany et al. <sup>5</sup>	2011	68	M	DM2	<i>Candida</i>	VII	N	Voric(42 days)	Y	No
Hamzany et al. <sup>5</sup>	2011	68	M	DM2	<i>Candida</i>	VII	N	Ciproflox + ceftaz (110 days) then ceftaz + ofloxacin + vanco (66 days) then flucon + meropenem (60 days) then AmB (30 days)	Y	Y
Hamzany et al. <sup>5</sup>	2011	68	M	DM2	<i>Candida</i>	VII	N	Flucon (75 days) then flucon + rifampicin + fusidic ac (30 days)	Y	Y
Hamzany et al. <sup>5</sup>	2011	68	M	DM2	<i>Candida</i>	No	N	Ceftaz (78 days) then meropenem (55 days) + Itz (225 days)	Y	Y
Hamzany et al. <sup>5</sup>	2011	68	M	DM2	<i>Aspergillus</i>	No	Unspec	Meropenem (40 days) then flucon (42 days) then flucon + rifampicin + linezolid (60 days)	Y	Y
Hamzany et al. <sup>5</sup>	2011	68	F	DM2	<i>Aspergillus</i>	No	Unspec	Voric + cotrimox (130 days)	N	Y
Hamzany et al. <sup>5</sup>	2011	68	F	Nil	<i>Aspergillus</i>	No	Unspec	Ceftaz (42 days) then flucon + ampicillin (30 days)	N	Y
Parize et al. <sup>2</sup>	2009	48	M	Polychondritis	<i>A. niger</i>	No	Y	Voric (19 wk at 400 mg/day)	N	Y
Parize et al. <sup>2</sup>	2009	40	F	IDDM, renal tx, CRF	<i>A. niger</i>	No	Y	Voric (52 wk at 600 mg/day)	Y	No - hearing loss
Ling et al. <sup>10</sup>	2008	77	M	NIDDM, HTN, gout	<i>Candida</i> , <i>A. flavus</i>	VII	Y	Voric (14 wk at 400 mg/day) + caspofungin	Y	Y
Narozny et al. <sup>11</sup>	2006	65	M	NIDDM	<i>Aspergillus</i>	VII, IX, X	Unspec	AmB + Itz	Y	No - died
Tzuku et al. <sup>12</sup>	2006	17	F	IDDM	<i>S. apiospermum</i>	No	Y	AmB	Y	No - died
Bellini et al. <sup>13</sup>	2003	73	M	NIDDM	<i>A. niger</i>	Unspec	Unspec	AmB (2 g in 3 wk) then Itz (13 wk at 600 mg/day)	N	Y
Shelton et al. <sup>14</sup>	2002	58	M	Nil	<i>A. niger</i>	Unspec	Unspec	Itz (6 wk)	N	Y
Finer et al. <sup>15</sup>	2002	7	M	Neuroblastoma	<i>A. flavus</i>	Unspec	Unspec	AmB (6 days) then Itz (77 wk at 200 mg/day)	N	Y
Chai et al. <sup>6</sup>	2000	53	M	NIDDM	<i>M. sympodialis</i>	VII, IX, X, XII	Unspec	AmB than flucon	N	No - facial palsy

M: male; F: female; DM2: diabetes mellitus type II; AML: acute myeloid leukaemia; NIDDM: non insulin-dependent diabetes mellitus; tx: transplant; CRF: chronic renal failure; HTN: hypertension; Y: yes; N: no; Unspec: unspecified; Voric: voriconazole; AmB: amphotericin B; Itz: itraconazole; Ciproflox: ciprofloxacin; Ceftaz: ceftazidime; Vanco: vancomycin; Flucon: fluconazole; Cotrimox: cotrimoxazol

In 36% of cases, there was evidence of the disease by imaging, seen as soft-tissue filling of mastoid air cells and middle ear and thickening of the roof of the external ear canal at the magnetic resonance<sup>2</sup> or skull base osteomyelitis with involvement of the temporal bone by CT<sup>7</sup>.

64% of patients were treated with monotherapy, i.e. voriconazole or amphotericin B, and the average duration of the treatment was 178.4 days. 36% of cases were treated with associations of antifungal drugs for a mean period of 151.62 days. 56% of subjects underwent surgi-

cal debridement. 60% of the 25 cases showed complete resolution of symptoms.

In accordance with the clinical research question underlying this review, correlation between symptom resolution and clinical/management variables was assessed in all studies.

#### Correlation analysis

In accordance to the main criterion for inclusion in this review, all the studies assessed the correlation between symptom resolution and dichotomic study variables (Ta-

**Table III.** Single variable correlation analysis. Predictors of symptom resolution.

Predictors	Correlation with symptom resolution	p value
No surgical debridement	5.416	0.022
Absence of facial palsy	5.416	0.022
<i>Aspergillus</i> as causative pathogen	4.250	0.041
Absence of imaging findings	4.250	0.041
Monotherapy	2.097	0.173
Diabetes	1.427	0.307
Male sex	0.412	0.702

ble III). Single variable regression analyses showed that four of the dichotomic predictors were related with treatment outcomes: abstention from surgical debridement and absence of facial palsy ( $\chi^2 = 5.416$ ,  $p = 0.022$ ), *Aspergillus* spp. as causative pathogen and absence of imaging findings were correlated with resolution of symptoms ( $\chi^2 = 4.250$ ,  $p = 0.041$ ).

Male sex, presence of diabetes, preference for monotherapy over a combination of anti-fungal agents was not related with treatment outcomes.

#### Assessment of the quality of studies

All 14 studies could be categorised as evidence level 3 according to the National Institute for Health and Clinical Excellence's levels of evidence. Thus, when considering the quality of those selected, the assessment showed a good level of the reviewed articles as well as their qualitative homogeneity. However, their methodological heterogeneity did not allow for a meta-analysis of data.

## Discussion

MEO is an insidious disease with frequently delayed diagnosis. Almost 95% of the cases reported in the literature are attributed to *P. aeruginosa*<sup>3</sup>. Nevertheless, other associated bacteria or fungi can have an important role in the aetiology of MEO, particularly in immunocompromised patients, where *Pseudomonas* is not the predominant pathologic organism<sup>3</sup>. Thus, even the isolation of *Pseudomonas* from aural discharge may be not sufficient or specific enough to distinguish between the two forms. In fact, *P. aeruginosa* is frequently a saprophyte in the external auditory meatus, as *Staphylococcus* coagulase negative, diphtheroids, *Micrococcus* spp., *Alternaria* spp., *Penicillium* spp. and miceti.

As emphasised by Leonetti and Marzo<sup>16</sup>, patients are either referred with previous cultures and biopsy findings or are extremely tender on external auditory meatus manipulation; general anaesthesia is required to obtain an adequate biopsy. For these reasons, it is tempting to rely ei-

ther on previous findings or on bacteriologic data to direct therapy. As a consequence, *Pseudomonas* isolation may delay correct diagnosis of fungal infection: the failure to respond to anti-pseudomonal therapy can lead to surgical exploration and detection of miceti<sup>9</sup>.

On the other hand, *Aspergillus* spp. is also frequently isolated from external auditory canal smears and diagnosis of FMEO should be based on histopathologic confirmation on deep tissue biopsy or isolation from blood cultures or fistula exudates<sup>17</sup>. Deep tissue specimens obtained at surgery are necessary to diagnose fungi: this should reduce the risk of contamination or isolation of pathogenic saprophytes<sup>12</sup>. Sometimes, fungal cultures at the time of admission are negative and convert to positive only in later samples. In these cases, the primary infection can be caused by a bacterial pathogen, and owing to the prolonged course of the disease and antibiotic treatment, patients acquire an opportunistic fungal infection<sup>5</sup>.

*Aspergillus fumigatus* was once thought to be the most common fungal pathogen in FMEO<sup>10</sup>, with *Aspergillus flavus* assumed to be a less frequent cause of the condition. However, recent research reveals that *A. flavus* is about 100 times more virulent than *A. fumigatus* and has an optimum temperature for growth of 37°C, which may explain its particular pathogenicity in humans<sup>7</sup>.

MRI and CT can be used in association with other imaging modes for diagnosis and follow-up of FMEO (i.e., Tc<sup>99m</sup>MDP bone scanning, Ga<sup>67</sup> citrate scanning and Ga<sup>67</sup> SPECT). It is important to underline that the repeated studies performed in the patients with persistent disease showed that the number of subjects with radiological evidence of bone involvement increased in FMEO and decreased in MEO<sup>5</sup>.

The presence of fungal pathogen makes the disease more invasive<sup>5</sup>. This was further confirmed by the higher number of facial nerve palsies in the patients with FMEO: VII nerve palsy is reported in 75% of patients with *Aspergillus* spp. infection, compared with only 34% in MEO due to *P. aeruginosa*<sup>5,9</sup>.

The decision between conservative antimicrobial therapy and surgical treatment can present a therapeutic challenge in the management of these life-threatening infections, especially in patients with existing immunodeficiency and illness<sup>3</sup>. Although bone sequestra and abscess are treated surgically, the need for more aggressive treatment is debatable. Some authors suggest that prompt surgical debridement consisting of radical mastoidectomy is indicated in the majority of cases, particularly in fungal diseases, which are more invasive with respect to bacterial pathogens<sup>2,3</sup>. In the series reported by Hamzany<sup>5</sup>, extensive surgery was carried out in 78% of FMEO vs 18% in bacterial ones. However, other authors stress the fact that extensive surgery may be counterproductive because of the risk of exposing healthy bone to infection<sup>18</sup>. Unfortunately, there are neither guidelines nor definite rec-



ommendations with regards to surgical treatment of the different forms of FMEO.

The important principles of FMEO treatment include aggressive control of diabetes, improvement of immunocompetency when possible, and prolonged administration of adequate doses of antifungal agents, although the optimum duration of therapy remains unknown<sup>9</sup>. Amphotericin B and itraconazole were favoured for treatment of FMEO in the earlier case reports, whereas voriconazole has played a role in the therapy of the majority of reported cases since 2008. Voriconazole is currently recommended as first-line treatment in cases of invasive aspergillosis<sup>7</sup>. The intravenous form is recommended for use in systematically unwell patients, with the oral form being reserved for those who are stable or have improved following initial intravenous treatment. Voriconazole is widely distributed throughout tissues and, in its oral form, is not usually associated with worsening of renal function. This is particularly important as patients with comorbidities affecting renal function such as diabetes, who develop aspergillosis FMEO, therefore require treatment with voriconazole. The most commonly reported side effect of this antifungal agent include visual disturbances, particularly to colour vision, abnormal liver function tests, deranged renal function, skin photosensitivity, skin cancer and electrolyte abnormalities<sup>7</sup>. As noted in the literature, amphotericin B was most frequently used, although it has a significantly poorer safety profile, including adverse effects on renal function. Itraconazole and caspofungin have also been used in cases reported in the literature<sup>7</sup>.

Regarding hyperbaric oxygen, there is as yet no uniformity in treatment design. Several reports suggested a beneficial effect of hyperbaric oxygen, along with traditional treatment<sup>10,11</sup>, whereas the Cochrane Collaboration Database<sup>19</sup> found no clear data supporting its efficacy relative to antibiotics and/or surgery.

According to our research, abstention from surgical debridement and the absence of facial palsy are positive predictors of symptoms resolution, followed by *Aspergillus* spp. as causative pathogen and absence of imaging findings.

The counterproductivity of extensive surgery found from our research confirms the conclusions of Carfrae et al.<sup>18</sup>, but the fact that conservative treatment is statistically associated with a better outcome than surgical debridement could purely reflect the disease stage rather than actively contributing to the results: patients with more aggressive and advanced illness required debridement, whereas milder disease was treated conservatively.

Sparing the facial nerve and absence of radiological signs intuitively indicate a less invasive form of FMEO, which correlates with a better prognosis. Even if the presence of fungal pathogen makes the disease more invasive than the bacterial form of MEO, *Aspergillus* spp. is more susceptible to anti-fungal agents than other fungi, i.e. *Candida* spp. The reviewed studies were selected on the basis of their

description of clinical aspects and consequent management of FMEO. The choice to limit the included studies to those published after 2000 was due to the need for an updated approach to this disease. In spite of this strategy, unfortunately, the statistical analysis of predictors of outcome is flawed with a small series of case reports and study designs were so heterogeneous that meta-analysis of data could not be performed, and the extraction of sound, clinically-useful, conclusions was hard to perform. As a strength of the review, the studies had the common feature of relying on an accurate characterisation of management, using updated diagnostic techniques and treatments. Also, importantly, despite their methodological heterogeneity, all studies provided an acceptable<sup>3</sup> level of evidence according to the National Institute for Health and Clinical Excellence's grading. Within these limitations, some correlations between the outcomes of FMEO therapy and study variables were reported.

Notwithstanding this interesting information, it must be recognised that the available literature is too limited to permit a recommendation of any particular strategy in the clinical setting: decisions based solely on the studied factors cannot be recommended, especially because an integrated analysis of other risk factors (e.g., age, comorbidities, among others), must be taken into account. More information should be drawn on the amount of the advancement needed to achieve the best balance between benefit and discomfort, which was shown to be a critical aspect in the FMEO literature. Moreover, as a further limitation of this review, it should be pointed out that the external validity is not optimal due to the poor consistency between the reviewed studies as concerns the methodological features.

## Conclusions

This systematic review identified 14 studies trying to relate specific clinical and management variables to the effectiveness of FMEO treatment. The outcome depends particularly on absence of facial nerve palsy, *Aspergillus* spp. as causative pathogen and absence of radiological signs at diagnosis and during follow-up. The fact that conservative treatment is statistically associated with a better outcome than surgical debridement could purely reflect the disease stage rather than actively contributing to the results: patients with more aggressive and advanced illness required debridement, whereas milder disease was treated conservatively.

Notwithstanding, the overall conclusions that can be drawn from this review are still limited by the somewhat inconsistent findings and the heterogeneity of study designs. Thus, it is suggested that further trials are performed before recommending any suggestions in the clinical setting.

## References

- <sup>1</sup> Chandler JR. *Malignant external otitis*. Laryngoscope 1968;78:1257-94.
- <sup>2</sup> Parize P, Chandesris MO, Lanternier F, et al. *Antifungal therapy of Aspergillus invasive otitis externa: efficacy of voriconazole and review*. Antimicrob Agents Chemother 2009;53:1048-53.
- <sup>3</sup> Bovo R, Benatti A, Ciorba A, et al. *Pseudomonas and Aspergillus interaction in malignant external otitis: risk of treatment failure*. Acta Otorhinolaringol Ital 2012;32:416-9.
- <sup>4</sup> Tarazi AE, Al-Tawfiq A, Abdi RF. *Fungal malignant otitis externa: pitfalls, diagnosis, and treatment*. Otol Neurotol 2012;33:769-73.
- <sup>5</sup> Hamzany Y, Soudry E, Preis M, et al. *Fungal malignant external otitis*. J of Infect 2011;62:226-31.
- <sup>6</sup> Chai FC, Auret K, Christiansen, Yuen PW, et al. *Malignant otitis externa caused by Malassezia sympodialis*. Head Neck 2000;22:87-9.
- <sup>7</sup> Walton J, Coulson C. *Fungal malignant otitis externa with facial nerve palsy: tissue biopsy aids diagnosis*. Case Rep Otolaryngol 2014;2014:192318.
- <sup>8</sup> Lilic N, Mowjood M, Wong M. *A rare and sinister variant of a common ailment: Fungal malignant otitis externa*. J Surg Case Rep 2012;2012(9):4.
- <sup>9</sup> Halsey C, Lumley H, Luckit J. *Necrotising external otitis caused by Aspergillus wentii: a case report*. Mycoses 2011;54:e211-3.
- <sup>10</sup> Ling SS, Sader C. *Fungal malignant otitis externa treated with hyperbaric oxygen*. Internat J Infect Dis 2008;12:550-2.
- <sup>11</sup> Narozny W, Kuczkowski J, Stankiewicz C, et al. *Value of hyperbaric oxygen in bacterial and fungal malignant external otitis treatment*. Eur Arch Otorhinolaryngol 2006;263:680-4.
- <sup>12</sup> Tuzcu A, Bahceci M, Celen MK, et al. *Necrotizing (malignant) otitis externa: an unusual localization of mucormycosis*. Indian J Med Microbiol 2006;24:289-91.
- <sup>13</sup> Bellini C, Antonini P, Ermanni S, et al. *Malignant otitis externa due to Aspergillus niger*. Scand J Infect Dis 2003;35:284-8.
- <sup>14</sup> Shelton JC, Antonelli PJ, Hackett R. *Skull base fungal osteomyelitis in an immunocompetent host*. Otolaryng 2002;126:76-8.
- <sup>15</sup> Finer G, Greenberg D, Leibovitz E, et al. *Conservative treatment of malignant (invasive) external otitis caused by Aspergillus flavus with oral itraconazole solution in a neutropenic patient*. Scand J Infect Dis 2002;34:227-9.
- <sup>16</sup> Marzo SJ, Leonetti JP. *Invasive fungal and bacterial infections of the temporal bone*. Laryngoscope 2003;113:1503-7.
- <sup>17</sup> Martínez-Berriotxo A, Montejo M, Aguirrebengoa K, et al. *Otomastoiditis caused by Aspergillus in AIDS*. Enferm Infecc Microbiol Clin 1997;15:200-2.
- <sup>18</sup> Carfrae MJ, Kesser BW. *Malignant otitis externa*. Otolaryngol Clin North Am 2008;41:537-49.
- <sup>19</sup> Phillips JS, Jones SEM. *Hyperbaric oxygen as an adjuvant treatment for malignant otitis externa (Review)*. The Cochrane collaboration. Cochrane Database Syst Rev 2005;18(2):CD004617.

Received: April 2, 2015 - Received: June 18, 2015

HEAD AND NECK

# Differential diagnosis of parotid gland tumours: which magnetic resonance findings should be taken in account?

## *Diagnosi differenziale dei tumori parotidici: quali caratteristiche di risonanza magnetica considerare?*

T. TARTAGLIONE<sup>1</sup>, A. BOTTO<sup>1</sup>, M. SCIANDRA<sup>1</sup>, S. GAUDINO<sup>1</sup>, L. DANIELI<sup>1</sup>, C. PARRILLA<sup>2</sup>, G. PALUDETTI<sup>2</sup>, C. COLOSIMO<sup>1</sup>

<sup>1</sup> Department of Radiological Sciences, Università Cattolica del Sacro Cuore, "A. Gemelli" Hospital, Roma, Italy

<sup>2</sup> Department of Head and Neck Surgery Otorhinolaryngology, Università Cattolica del Sacro Cuore, "A. Gemelli" Hospital, Roma, Italy

### SUMMARY

Our aim was to define typical magnetic resonance (MRI) findings in malignant and benign parotid tumours. This study is based on retrospective evaluation of pre-surgical MRI of 94 patients with parotid gland tumours. Histology results were available for all tumours. There were 69 cases of benign (73%) and 25 cases of malignant (27%) tumours, including 44 pleomorphic adenomas, 18 Warthin's tumours, 7 various benign tumours, 6 squamous cell carcinomas, 3 carcinoma ex pleomorphic adenomas, 2 mucoepidermoid carcinomas, 1 adenoid cystic carcinoma and 13 various malignant tumours. The following MRI parameters were evaluated: shape, site, size, margins, signal intensity (SI) on T1w and T2w images, contrast enhancement, signal of cystic content, presence or absence of a capsule, perineural spread, extraglandular growth pattern and cervical adenopathy. Statistical analysis was performed to identify the MRI findings most suggestive of malignancy, and to define the most typical MRI pattern of the most common histologies. Ill-defined margins ( $p < 0.001$ ), adenopathies ( $p < 0.001$ ) and infiltrative growth pattern ( $p < 0.001$ ) were significantly predictive of malignancy. Typical findings of pleomorphic adenoma included hyperintensity on T2w images ( $p = 0.02$ ), strong contrast enhancement ( $p < 0.001$ ) and lobulated shape ( $p = 0.04$ ). Typical findings of Warthin's tumour included hyperintense components on T1w images ( $p < 0.001$ ), location in the parotid inferior process ( $p < 0.001$ ) and mild or incomplete contrast enhancement ( $p = 0.01$ ). SI on T1w and T2w images and contrast enhancement enables differential diagnosis between pleomorphic adenoma and Warthin's tumour.

KEY WORDS: Parotid gland • Neoplasms • Magnetic Resonance Imaging • Differential diagnosis • Histology

### RIASSUNTO

La finalità del nostro lavoro è di valutare le caratteristiche di risonanza magnetica (RM) tipiche dei tumori parotidici maligni e benigni. Questo studio retrospettivo si basa sulla valutazione di esami RM pre-chirurgici di 94 pazienti con tumori parotidici. I risultati istologici erano disponibili in tutti i casi; abbiamo analizzato 69 lesioni erano benigne (73%) e 25 maligne (27%): 44 adenomi pleomorfi, 18 tumori di Warthin, 7 tumori benigni di diverso istotipo, 6 carcinomi squamocellulari, 3 carcinomi ex-adenomi pleomorfi, 2 carcinomi mucoepidermoidi, 1 tumore adenoidocistico, 13 tumori maligni di diverso istotipo. Sono state valutate le seguenti caratteristiche RM: morfologia, sede, dimensioni, margini, intensità di segnale nelle sequenze T2-pesate e T1-pesate, impregnazione dopo mezzo di contrasto (mdc), intensità di segnale della porzione cistica, presenza o assenza di una capsula, diffusione perineurale, pattern di crescita extraglandolare e linfoadenopatie laterocervicali. È stata effettuata un'analisi statistica per identificare le caratteristiche RM più indicative di malignità e per definire l'aspetto tipico degli istotipi più comuni. I parametri significativamente predittivi di malignità sono risultati i margini mal-definiti ( $p < 0,001$ ), le linfoadenopatie ( $p < 0,001$ ) ed il pattern di crescita infiltrativo ( $p < 0,001$ ). Le caratteristiche tipiche dell'adenoma pleomorfo sono risultate l'iperintensità di segnale nelle immagini T2-pesate ( $p = 0,02$ ), l'intensa impregnazione dopo mdc ( $p < 0,001$ ) ed i margini lobulati ( $p = 0,04$ ). Le caratteristiche tipiche del tumore di Warthin sono risultate le componenti iperintense nelle immagini T1-pesate ( $p < 0,001$ ), la localizzazione nel processo parotideo inferiore ( $p < 0,001$ ) e l'impregnazione post-contrastografica lieve/incompleta ( $p = 0,01$ ). L'intensità di segnale nelle immagini T1-pesate e T2-pesate e l'impregnazione post-contrastografica si sono rivelate utili nella diagnosi differenziale tra adenoma pleomorfo e tumore di Warthin.

PAROLE CHIAVE: • Ghiandola parotide • Neoplasie • Imaging di Risonanza Magnetica • Diagnosi differenziale • Istologia

Acta Otorhinolaryngol Ital 2015;35:314-320

### Introduction

Parotid gland tumours account for approximately 3-6%

of all head and neck tumours, with an annual estimated global incidence of 0.4-13.5 per 100,000 persons<sup>1</sup>. About 80% of parotid tumours are benign, the

most common being pleomorphic adenomas<sup>2</sup>. Median age of onset is 45 years, with a peak of incidence for benign tumours in the fourth decade of life; for malignant tumours, the incidence peaks in the sixth or seventh decade<sup>3-5</sup>. Regarding benign tumours, there is a slight overall male preponderance (male:female ratio = 1.1:1), whereas malignant tumours are equally distributed between the two sexes<sup>1</sup>.

Most parotid tumours present as slow-growing, painless masses. Symptoms such as local pain, facial nerve palsy, skin ulceration, fast-growing masses, otalgia (related to posterior auricular nerve involvement) and cervical adenopathy should evoke a suspicion of malignancy<sup>6,7</sup>.

Because the parotid gland is easily accessible for palpation, it is often possible to characterise the lesion by fine-needle aspiration cytology (FNAC), which has a sensitivity of 0.80 and a specificity of 0.97<sup>8</sup>. The risk of dissemination of neoplastic cells along the route of the needle is considered negligible<sup>9</sup>. However, FNAC is inconclusive in almost 6% of cases because of insufficient sample size or location of the tumour in the deep parotid lobe<sup>10,11</sup>.

Preoperative imaging has assumed a to play major role in surgical planning for assessing tumour location and malignancy. In patients with benign tumours, the surgical procedure may be limited to superficial parotidectomy or extracapsular enucleation, whereas in case of malignant lesions, patients usually undergo total parotidectomy with possible facial nerve sacrifice<sup>12,13</sup>. Ultrasound (US) is accepted as the first imaging method for the assessment of lymph nodes and soft-tissue diseases in the head and neck, including the major salivary glands<sup>14</sup>. However, with US, it is often difficult to study the deep parotid lobe because of the acoustic shadow of the mandible, and it is not possible to visualise the facial nerve, retropharyngeal and deep neck adenopathies and the intracranial or skull base extent of the mass<sup>14-16</sup>. Thus, magnetic resonance imaging (MRI) is considered the most appropriate method for the evaluation of parotid gland tumours owing to its high contrast resolution for soft tissues and capability of visualising deep lobe tumours; it also provides excellent morphological and volumetric assessment, a precise definition of the relationship with adjacent structures and a panoramic view of the cervical lymph nodes<sup>6,15</sup>.

Computed tomography has limited use in the assessment of salivary gland tumours and is used only in cases of contraindication of MRI or in claustrophobic patients<sup>17</sup>.

The aim of this study was to identify the most useful MRI findings for differential diagnosis of parotid tumours.

## Materials and methods

Our study was based on retrospective assessment of pre-surgical and pre-biopsy/pre-FNAC MR examinations obtained in 94 patients (43 females and 51 males; mean age, 43.5 years; range, 15–92 years) with parotid

gland tumours and undergoing surgical resection at the Department of Otolaryngology of Catholic University of the Sacred Heart, between February 2005 and September 2014.

In all cases, the MRI protocol included a T1w sequence, a T2w sequence and a T1w sequence with fat saturation after contrast injection. The Ethics Committee approved the study, and all patients provided written, informed consent. In all patients, surgical specimens were subject to histopathological and immunohistochemical analyses and resulted in 69 benign (73%) and 25 malignant (27%) tumours, including 44 pleomorphic adenomas, 18 Warthin's tumours, 7 various benign tumours (1 haemangioma, 2 myoepitheliomas, 1 ductal cyst, 1 lipoma, 1 oncocytoma, 1 cholesteatoma), 6 squamous cell carcinomas, 3 carcinoma ex pleomorphic adenomas, 2 mucoepidermoid carcinomas, 1 adenoid cystic carcinoma, 13 various malignant tumours (1 sebaceous tumour, 1 myoepithelial carcinoma, 4 undifferentiated tumours, 5 metastases from squamous cell carcinomas of the skin and 2 adenocarcinomas).

Two radiologists with 24 (TT) and 12 (SG) years of experience in head and neck imaging, respectively, examined all pre-surgical MRI results, evaluating the following MRI parameters:

- Site and number of lesions: unilateral or bilateral, single or multifocal. Location in the superficial lobe (subdivided in body, anterior and inferior processes) or deep lobe; an imaginary line drawn from the stylomastoid foramen to the lateral margin of the retromandibular vein was used as a landmark between the deep and superficial lobe.
- Overall morphology: oval, round, lobulated or irregular.
- Dimensions: size along the major axis.
- Margins: well-defined, ill-defined or spiculated; the tumour's margins were evaluated on both pre- and post-contrast T1w images.
- Extraglandular infiltrative growth pattern: invasion of adjacent tissue, including subcutaneous fat, skin, masticatory space or mandible. In patients with multiple lesions with at least one showing infiltrative characteristics, we considered the lesional growth pattern as infiltrative.
- Capsule: a hypointense rim surrounding the lesion on T1w and T2w images, with or without enhancement after contrast injection.
- MRI signal intensity (SI) and enhancement of lesions: on T1w images, lesion enhancement was determined relative to the masseter muscle as hypointense (lower intensity than that of the muscle tissue), isointense (intensity similar to that of the muscle tissue) and hyperintense (higher intensity than that of the muscle tissue); on T2w images enhancement was determined relative to the healthy parotid parenchyma as hypointense, isointense and hyperintense. Enhancement of the tumour was classified as low (less enhancement than

seen for parotid tissue), intermediate (enhancement similar to that of normal parotid tissue) or strong (more enhancement than seen for parotid tissue). Before and after contrast injection, tumour enhancement was divided into homogeneous and heterogeneous lesions. For heterogeneous lesions, the SI and enhancement of the predominant portion of the tumour were evaluated.

- SI of cystic content: based on T1w and T2w images relative to the signal of the lesion and scored as hypointense (lower to that of the lesion), isointense (similar to that of the lesion) and hyperintense (brighter than that of the lesion).

- Perineural spread: pathological enhancing mass along the cranial nerves (V and VII).
- Cervical adenopathy: rounded morphology, short axis > 1 cm, necrosis, lymph node conglomerates, extranodal extension.

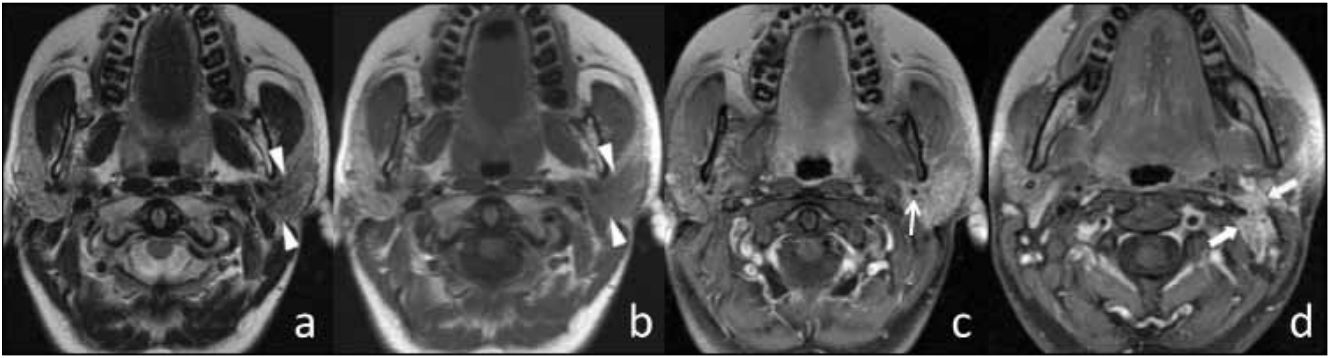
In patients with multiple lesions, we included the characteristics of the largest in our analysis.

Each MRI finding for malignant tumours was compared with that for benign tumours by Fisher's exact test (Table 1). An MRI finding with a p value < 0.05 was considered statistically significant. Using the same test, each MRI

**Table 1.** Results of statistical analysis.

Findings	Malignant Tumours (n = 25)		Benign Tumours (n = 69)		p Value, Fisher's Exact Test	PPV <sup>¶</sup>	NPV <sup>¶</sup>	Specificity	Sensitivity
	Positive	Negative	Positive	Negative					
<i>Signal Intensity<sup>‡</sup></i>									
T1-	3	22	9	60	1	0.25	0.73	0.87	0.12
T1+	15	10	35	34	0.4879	0.3	0.77	0.49	0.60
T1=	7	18	25	44	0.6229	0.22	0.71	0.64	0.28
T1*	0	25	13	56	0.0175	0	0.69	0.81	0
T2-	2	23	1	68	0.1716	0.67	0.75	0.99	0.08
T2+	20	5	63	6	0.1544	0.24	0.55	0.09	0.8
T2=	3	22	5	64	0.4346	0.38	0.74	0.93	0.12
<i>CE<sup>‡</sup></i>									
0	0	25	3	66	0.5625	0	0.73	0.96	0
1	2	23	7	62	1	0.22	0.73	0.90	0.08
2	5	20	24	45	0.2118	0.17	0.69	0.65	0.2
3	18	7	35	34	0.0987	0.34	0.83	0.49	0.72
<i>Appearance</i>									
Homogeneous	1	24	29	40	< 0.001	0.03	0.63	0.58	0.04
Inhomogeneous	24	1	40	29	< 0.001	0.38	0.97	0.04	0.58
<i>Margins</i>									
Well-defined	3	22	66	3	< 0.001	0.04	0.12	0.88	0.96
Ill-defined or spiculated	22	3	3	66	< 0.001	0.88	0.96	0.96	0.88
<i>Morphology</i>									
Round	1	24	2	67	1	0.33	0.74	0.97	0.04
Oval	11	14	39	30	0.3516	0.22	0.68	0.43	0.44
Lobulated	9	16	28	41	0.8124	0.24	0.72	0.59	0.36
Irregular	4	21	0	69	0.0041	1	0.77	1	0.16
Cysts/necrosis	10	15	21	48	0.458	0.32	0.76	0.70	0.40
<i>Sites</i>									
Body	13	12	24	45	0.1557	0.35	0.79	0.65	0.52
Lower extension	2	23	17	52	0.0885	0.11	0.69	0.75	0.08
Anterior extension	1	24	14	55	0.0633	0.07	0.7	0.80	0.04
Parapharyngeal extension	5	20	7	62	0.2919	0.42	0.76	0.90	0.20
<i>More sites</i>									
Superficial lobe	4	21	7	62	0.4752	0.36	0.75	0.90	0.16
Deep lobe	10	15	47	22	0.0020	0.18	0.59	0.32	0.40
Single lesion	15	10	22	47	0.0020	0.41	0.82	0.40	0.32
Multifocal	20	5	65	4	0.0530	0.24	0.44	0.06	0.80
	5	20	4	65	0.0530	0.56	0.76	0.80	0.06
Adenopathy	12	13	1	68	< 0.001	0.92	0.84	0.99	0.48
Perineural spread	1	24	0	69	0.2660	1	0.74	1	0.04
Infiltrative grown pattern	17	8	0	69	< 0.001	1	0.9	1	0.68

<sup>‡</sup> T1- hypointensity with respect to masseter muscle, T1+ hyperintensity with respect to masseter muscle, T1= isointensity with respect to masseter muscle, T1\* cysts hyperintense on T1 with respect to lesion, T2- hypointensity with respect to parotid tissue, T2+ hyperintensity with respect to parotid tissue, T2= isointensity with respect to parotid tissue; <sup>¶</sup> 0 = no contrast enhancement, 1: low contrast enhancement, 2: intermediate contrast enhancement, 3: strong contrast enhancement; <sup>¶</sup> PPV: positive predictive value, NPV: negative predictive value.



**Fig. 1.** Squamous carcinoma of the left parotid gland. (a) Axial T2w image, (b) axial T1w image and (c and d) axial T1w fat-sat image after contrast injection. The left intraparotid tumour appeared hypointense on T2w and isointense on T1w images (arrowheads) with ill-defined margins. After contrast injection (on T1w fat-sat image), the tumour showed a strong enhancement, encasing the external carotid artery (arrow). Cervical adenopathies were also evident in levels IIa and IIb on the left side (thick arrows).

finding of the most frequent benign tumours (pleomorphic adenomas and Warthin's tumours) was compared with MRI findings from the rest of the benign lesions. The independent samples *t*-test was used for numeric variables such as age and size, whereas the chi-square test was used for gender.

## Results

Malignant tumours were more frequent in men (M:F = 2.1:1), whereas benign tumours were equally distributed between the two genders (M:F = 1.02:1); however, a statistical correlation between gender and malignancy was not demonstrated ( $p = 0.09$ ). Among benign lesions, Warthin's tumour was significantly ( $p = 0.012$ ) more common in men (M:F = 4.5:1), whereas pleomorphic adenomas showed the opposite trend (M:F = 1:1.4). The mean age for diagnosis of with malignant tumours was 65.2 years (range, 25–92 years), whereas for benign tumours, it was 50.7 years (range, 15–89 years), with a tendency for malignant lesion to occur in older patients ( $p < 0.001$ ). Patients with pleomorphic adenomas had a lower mean age (44.6 years; range 15–89 years) than patients with Warthin's tumours (60.5 years; range, 47–82 years;  $p = 0.012$ ).

We found multifocal lesions in nine patients: Five cases of metastases from squamous cell carcinomas of the skin, 3 Warthin's tumours and 1 pleomorphic adenoma. In all cases, lesions were unilateral except for the pleomorphic adenoma and one of the Warthin's tumours. Both benign (24 of 69) and malignant (13 of 25) lesions were often located in the body of the parotid gland. In Warthin's tumours, we found a higher frequency of tumour localisation in the inferior process (10 of 18).

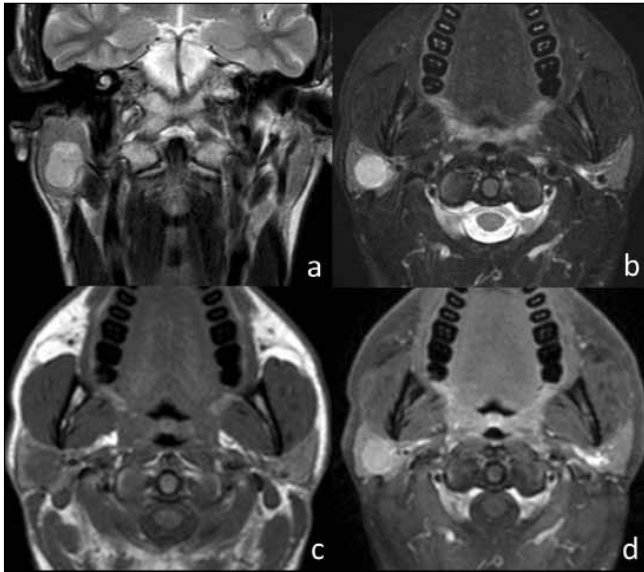
Irregular shape was found in 16% (4 of 25) of malignant tumours, whereas none of the benign lesions were characterised by irregular shape ( $p = 0.004$ ; specificity, 1; sensitivity, 0.16). Meanwhile, 100% of the benign tumours

and 84% of the malignant tumours showed a round, oval or lobulated shape (Table I). The average size of malignant and benign tumours was 38 and 28 mm, respectively ( $p = 0.012$ ). A total of 88% of malignant tumours and only 0.04% of benign tumours showed ill-defined margins ( $p < 0.001$ ; specificity, 0.96; sensitivity, 0.88; Fig. 1; Table I). Extraglandular infiltrative growth patterns were present in 17 of 25 malignant tumours ( $p < 0.001$ ; specificity, 1; sensitivity, 0.68); none of the benign tumours showed infiltrative grown patterns.

A hypointense capsule surrounding the parotid tumour was more frequent in benign than malignant lesions (56% vs 8%), and hence predictive of benignity (VPP 0.95, specificity 0.92, sensitivity 0.57,  $p < 0.001$ ). Hypointense SI on T2w images was highly specific (0.99) of malignancy, but the data was not statistically significant ( $p = 0.17$ ) and showed a low sensitivity (0.08). The majority of malignant (80%) and benign (91.3%) lesions showed high SI on T2w images; hence, the SI on T2w was not useful for differential diagnosis ( $p = 0.154$ ). Also, the inhomogeneous SI seen in lesions was not useful in the differential diagnosis, appearing in 96% of malignant and 58% of benign tumours ( $p < 0.001$ ; specificity, 0.04; sensitivity, 0.58). Contrast enhancement did not significantly correlate with malignancy (Table I). Cystic or necrotic areas did not assist in distinguishing malignant from benign tumours, and were present in 40% of malignant and 30% of benign lesions ( $p = 0.458$ ).

Almost 50% (12 of 25) of malignant tumours showed cervical adenopathies ( $p < 0.001$ ; specificity 0.99; sensitivity 0.48), whereas perineuronal spread occurred in only one malignant lesion ( $p = 0.226$ ; specificity 1 sensitivity, 0.04). An enlarged (short axis, 2.7 cm) cervical lymph node with inhomogeneous SI was found in only one case of benign tumour (Warthin's tumour).

Pleomorphic adenomas and Warthin's tumours were the two most common histologic entities, repre-



**Fig. 2.** Pleomorphic adenoma of the right parotid gland. (a) Coronal T2w image, (b) axial T2w fat-sat image, (c) axial T1w image and (d) axial T1w fat-sat image after contrast injection. The right intraparotid tumour appeared as an oval lesion, hyperintense on T2w images, and isointense on T1w images, with sharp margins and homogeneous SI. After contrast injection, the lesion showed strong enhancement that was higher than that seen in normal parotid tissue.

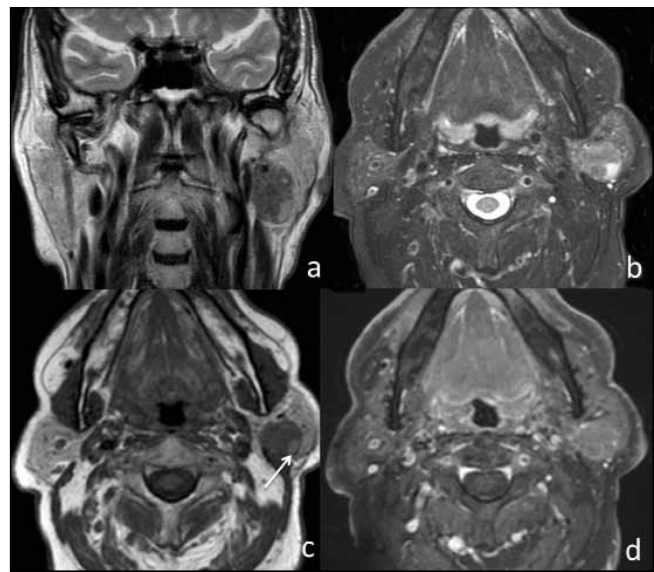
sented by 44 and 18 cases, respectively, accounting for almost 90% of benign parotid tumours. The typical MR findings for pleomorphic adenomas included strong enhancement ( $p < 0.001$ ), high signal on T2w images ( $p = 0.02$ ), oval or lobulated shape ( $p = 0.02$  and  $p = 0.04$ , respectively) and well-defined margins ( $p = 0.04$ ; Fig. 2). For Warthin's tumours, typical MRI findings included cystic areas that were hyperintense on T1w images ( $p < 0.001$ ), low or incomplete contrast enhancement ( $p = 0.01$ ) and location in the inferior process ( $p = 0.01$ ; Fig. 3).

Other histologic entities were present only to a limited extent, yielding non-significant results in statistical analyses.

## Discussion

Most studies consistently report that malignant parotid tumours show ill-defined margins, inhomogeneous SI and low SI on T2w images; concomitant cervical adenopathies or perineural spread may be present. Instead, benign tumours are characterised by well-defined margins, a high SI on T2w images and location in the superficial lobe<sup>6 17-19</sup>.

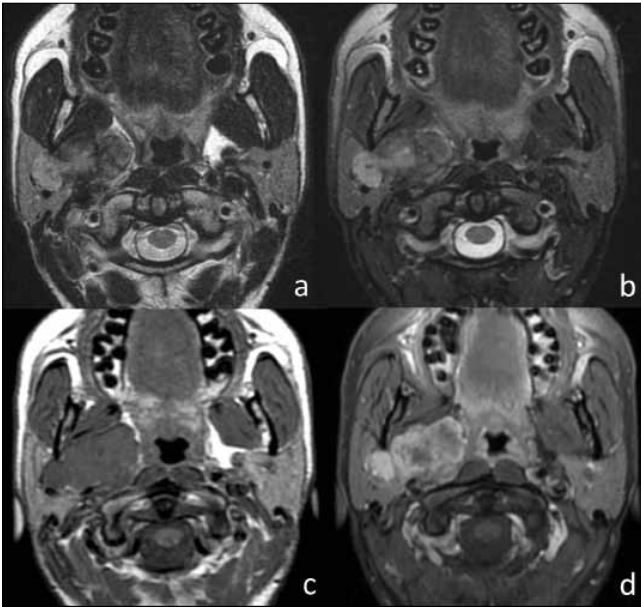
Our experience confirmed that the most useful MRI finding in differential diagnosis between benign and malignant lesions was ill-defined margins (before and after intravenous contrast administration,  $p < 0.001$ ; specificity, 0.96; sensitivity, 0.88)<sup>17 18</sup>.



**Fig. 3.** Warthin's tumour of the left parotid gland. (a) Coronal T2w image, (b) axial T2w fat-sat image, (c) axial T1w image and (d) axial T1w fat-sat image after contrast injection. The left intraparotid tumour appeared as an oval lesion with well-defined margins and hypointense on T2w images. T1w images showed a hyperintense cystic area (arrow) within the lesion. After contrast injection, the lesion showed only focal contrast enhancement.

However, ill-defined margins are not completely specific of malignancy, but are rarely present in benign tumours with adjacent inflammatory phenomena, as we found in two Warthin's tumours and one haemangioma, leading to possible erroneous diagnostic hypotheses. It has already been reported that this aspect is more frequent in cystadenolymphoma, and inflammatory phenomena could be related to exogenous bacterial contamination or primary infarction of a Warthin's tumour, with subsequent release of intraluminal preformed crystals and inflammation of a foreign body reaction type<sup>20-22</sup>.

In contrast, malignant intralesional degeneration is a possible event in lesions with well-defined margins and is common in pleomorphic adenomas, with rates up to 25%<sup>6 17 23</sup>. We encountered three cases of carcinoma ex pleomorphic adenoma with small foci of carcinomatous elements (two adenocarcinoma NOS and one mucoepidermoid carcinoma) that were hardly detectable on MRI and revealed during histological analysis. Pathological cervical adenopathies ( $p < 0.001$ ) and perineural spread ( $p = 0.266$ ) were reliable signs of malignancy, although the p value of perineural spread did not reach statistical significance because it was found in only one case. In one case, we found a Warthin's tumour with adenopathy (inhomogeneous enhancement and a short axis of 2.8 cm) at the V level, which pathologically resulted as a lymph node location of Warthin's tumour. In the literature, there are only few reports on the occurrence of extraglandular Warthin's tumours in cervical lymph nodes, which could



**Fig. 4.** Atypical pleomorphic adenoma of the right parotid gland. (a) Axial T2w image, (b) axial T2w fat-sat image, (c) axial T1w image and (d) axial T1w fat-sat image after contrast injection. The lobulated tumour involved both the superficial and the deep lobe of the right parotid gland, showing sharp margins and inhomogeneous SI on T2w images. After contrast injection, the lesion showed strong inhomogeneous enhancement.

be related to heterotopia of salivary tissue in extra-parotid lymph nodes<sup>24</sup>.

Another MRI finding suggestive of malignancy was extraglandular infiltrative growth into surrounding tissue ( $p < 0.001$ ; specificity, 1; sensitivity, 0.68). In fact, it was present only in malignant tumours (68%), whereas none of the benign lesions showed it. Nevertheless, inflammatory lesions could have an infiltrative growth pattern mimicking malignant tumours, and so anamnestic knowledge is essential<sup>19,20</sup>. The dimensions of the lesion also appear to correlate with malignancy (average, 38 mm in malignant lesions vs 28 mm in benign lesions,  $p = 0.012$ ).

The SI of solid lesions was less useful in the differential diagnosis between malignant and benign tumours ( $p = 0.154$ ). Contrary to data from other studies, in 80% of malignant and 91.3% of benign tumours the SI on T2-weighted images was higher than in healthy parotid parenchyma. Nevertheless, a hypointense SI on T2w images is highly specific of malignancy (0.99), but in our series, it was present in too few cases to be able to demonstrate statistical significance ( $p = 0.17$ ) and with a low sensitivity (0.08)<sup>17,18</sup>.

Moreover, the inhomogeneous SI of the lesion was not useful in differential diagnosis, appearing in 96% of malignant and 58% of benign tumours; this MRI finding showed a very low specificity of malignancy (0.04). Furthermore, the SI of benign lesions depends on its dimensions; in fact, we found a higher frequency of inhomogeneous SI in larger lesions, which could be explained

by necrotic areas, haemorrhages and cystic degeneration (Fig. 4)<sup>6,17</sup>. In our experience, cysts or haemorrhagic areas within lesions were not useful for differential diagnosis between malignant and benign tumours. However, hyperintense cysts on T1w images in lesions with sharp margins (indicative of benign lesion) appear to be strongly suggestive of Warthin's tumour ( $p < 0.001$ ; specificity, 1.0; sensitivity, 0.72), which has never been found in pleomorphic adenomas, the other most common benign lesion. This finding appears to be related with proteinaceous, haemorrhagic, or cholesterol accumulation<sup>19,25,26</sup>. Contrast injection enabled better definition of lesional margins on T1w fat-saturated images and evaluation of intralesional components (solid vs cystic portions), but the degree of tumour enhancement did not enable the distinction between benign and malignant tumours. However, the degree of contrast enhancement differed significantly between pleomorphic adenomas and Warthin's tumours, being strong or complete in the former ( $p < 0.001$ ) and low or incomplete in the latter ( $p = 0.01$ ). These data have already been reported and appear to correlate with the scarce interstitial spaces in Warthin's tumours<sup>18,27,28</sup>.

The site of the lesion was not a predictor of malignancy. In fact, the body of the parotid gland was the most frequent site in both malignant and benign tumours. As previously reported, the inferior process of the parotid gland was the most common site of onset of Warthin's tumour (55%,  $p = 0.01$ )<sup>17</sup>.

One limitation of our study was that DWI and perfusion sequences were not routinely performed or considered. These new imaging techniques could add additional information to better characterise parotid lesions<sup>29-32</sup>. Moreover, we mainly observed benign lesions, particularly pleomorphic adenomas ( $N = 44$ ) and Warthin's tumours ( $N = 18$ ), whereas malignant tumours were few and histologically heterogeneous; consequently it was not possible to identify typical MRI findings for each malignant pathological entity.

## Conclusions

MRI should be considered the most appropriate imaging modality for parotid gland tumours. In our experience, careful evaluation of lesion margins, SI of cystic content, extraglandular infiltrative growth pattern, cervical lymph nodes and eventual perineural spread may lead to a correct differentiation between malignant and benign parotid lesions. In particular, ill-defined margins are highly predictive of malignancy. Meanwhile, well-defined margins or a hypointense capsule are characteristic of benign lesions.

## References

- Tian Z, Li L, Wang L, et al. Salivary gland neoplasms in oral and maxillofacial regions: a 23-year retrospective study of 6982 cases in an eastern Chinese population. *Int J Oral Maxillofac Surg* 2010;39:235-42.



- <sup>2</sup> Nagler RM, Laufer D. *Tumors of the major and minor salivary glands: review of 25 years of experience*. *Anticancer Res* 1997;17:701-7.
- <sup>3</sup> Eveson JW, Cawson RA. *Salivary gland tumours. A review of 2410 cases with particular reference to histological types, site, age and sex distribution*. *J Pathol* 1985;146:51-8.
- <sup>4</sup> Takahama Junior A, de Almeida OP, Kowalski LP. *Parotid neoplasms: analysis of 600 patients attended at a single institution*. *Braz J Otorhinolaryngol* 2009;75:497-501.
- <sup>5</sup> Aparecida de Oliveira F, Barroso Duarte EC, Teixeira Taveira C, et al. *Salivary gland tumor: a review of 599 cases in a Brazilian population*. *Head Neck Pathol* 2009;3:271-5.
- <sup>6</sup> Lee YY, Wong KT, King AD, et al. *Imaging of salivary gland tumors*. *Eur J Radiol* 2008;66:419-36.
- <sup>7</sup> Guzzo M, Locati LD, Prott FJ, et al. *Major and minor salivary gland tumors*. *Crit Rev Oncol Hematol* 2010;74:134-48.
- <sup>8</sup> Schmidt RL, Hall BJ, Wilson AR, et al. *A systematic review and meta-analysis of the diagnostic accuracy of fine-needle aspiration cytology for parotid gland lesions*. *Am J Clin Pathol* 2011;136:45-59.
- <sup>9</sup> Gal R. *Fine needle aspiration of the salivary glands: a review*. *Oper Tech Otolaryngol Head Neck Surg* 1996;7:323-6.
- <sup>10</sup> Yabuuchi H, Fukuya T, Tajima T, et al. *Salivary gland tumors: diagnostic value of gadolinium-enhanced dynamic MR imaging with histopathologic correlation*. *Radiology* 2003;226:345-54.
- <sup>11</sup> Colella G, Cannavale R, Flamminio F, et al. *Fine-needle aspiration cytology of salivary gland lesions: a systematic review*. *J Oral Maxillofac Surg* 2010;68:2146-53.
- <sup>12</sup> Tweedie DJ, Jacob A. *Surgery of the parotid gland: evolution of techniques, nomenclature and a revised classification system*. *Clin Otolaryngol* 2009;34:303-8.
- <sup>13</sup> Chulam TC, Noronha Francisco AL, Goncalves Filho J, et al. *Warthin's tumour of the parotid gland: our experience*. *Acta Otorhinolaryngol Ital* 2013;33:393-7.
- <sup>14</sup> Bialek EJ, Jakubowski W, Zajkowski P, et al. *US of the major salivary glands: anatomy and spatial relationships, pathologic conditions, and pitfalls*. *Radiographics* 2006;26:745-63.
- <sup>15</sup> Yousem DM, Kraut MA, Chalian AA. *Major salivary gland imaging*. *Radiology* 2000;216:19-29.
- <sup>16</sup> Luczewski L, Golusinski P, Pazdrowski J, et al. *The ultrasound examination in assessment of parotid gland tumours: the novel graphic diagram*. *Eur Arch Otorhinolaryngol* 2013;270:2129-33.
- <sup>17</sup> Som M, Curtin HD. *Head and Neck Imaging*. 5<sup>th</sup> ed. Mosby Inc.; 2011. p. 2449-609.
- <sup>18</sup> Christe A, Waldherr C, Hallett R, et al. *MR imaging of parotid tumors: typical lesion characteristics in MR imaging improve discrimination between benign and malignant disease*. *Am J Neuroradiol* 2011;32:1202-7.
- <sup>19</sup> Kinoshita T, Ishii K, Naganuma H, et al. *MR imaging findings of parotid tumors with pathologic diagnostic clues A pictorial essay*. *Clin Imaging* 2004;28:93-101.
- <sup>20</sup> Mantsopoulos K, Psychogios G, Agaimy A, et al. *Inflamed benign tumours of the parotid gland: Diagnostic pitfalls from a potentially misleading entity*. *Head Neck* 2015;37:23-9.
- <sup>21</sup> Patey DH, Thackray AC. *Infected adenolymphoma: a new parotid syndrome*. *J Surg* 1970;57:569-72.
- <sup>22</sup> Rossle M, Winter W, Ihrler S. *A rare cause of subacute parotitis. The pathogenetic role of crystals from an infarcted Whartin's tumour?* *HNO* 2005;53:969-72.
- <sup>23</sup> Motoori K, Yamamoto S, Ueda T, et al. *Inter- and intratumoral variability in magnetic resonance imaging of pleomorphic adenoma*. *J Comput Assist Tomogr* 2004;28:233-46.
- <sup>24</sup> Naujoks C, Sproll C, Deep Singh D, et al. *Bilateral multifocal Warthin's tumors in upper neck lymph nodes. report of a case and brief review of the literature*. *Head Face Med* 2012;3:8-11.
- <sup>25</sup> Ikeda M, Motoori K, Hanazawa T, et al. *Warthin tumor of the parotid gland: diagnostic value of MR imaging with histopathologic correlation*. *Am J Neuroradiol* 2004;25:1256-62.
- <sup>26</sup> Kato H, Kanematsu M, Watanabe H, et al. *Salivary gland tumors of the parotid gland: CT and MR imaging findings with emphasis on intratumoral cystic components*. *Neuroradiology* 2014;56:789-95.
- <sup>27</sup> Suenaga S, Indo H, Noikura T. *Diagnostic value of dynamic magnetic resonance imaging for salivary gland diseases: a preliminary study*. *Dentomaxillofac Radiol* 2001;30:314-8.
- <sup>28</sup> Hisatomi M, Asaumi J, Yanagi Y, et al. *Diagnostic value of dynamic contrast-enhanced MRI in the salivary gland tumors*. *Oral Oncol* 2007;43:940-7.
- <sup>29</sup> Eida S, Sumi M, Nakamura T. *Multiparametric magnetic resonance imaging for the differentiation between benign and malignant salivary gland tumors*. *J Magn Reson Imaging* 2010;31:673-9.
- <sup>30</sup> Espinoza S, Halimi P. *Interpretation pearls for MR imaging of parotid gland tumor*. *Eur Ann Otorhinolaryngol Head Neck Dis* 2013;130:30-5.
- <sup>31</sup> Celebi I, Mahmutoglu AS, Ucgul A, et al. *Quantitative diffusion-weighted magnetic resonance imaging in the evaluation of parotid gland masses: a study with histopathological correlation*. *Clin Imaging* 2013;37:232-8.
- <sup>32</sup> Yabuuchi H, Matsuo Y, Kamitani T, et al. *Parotid gland tumors: can addition of diffusion-weighted MR imaging to dynamic contrast enhanced MR imaging improve diagnostic accuracy in characterization?* *Radiology* 2008;249:909-16.

Received: April 23, 2015 - Accepted: May 6, 2015

Address for correspondence: Tommaso Tartaglione, Department of Radiological Sciences, Università Cattolica del Sacro Cuore, "A. Gemelli" Hospital, largo A. Gemelli 8, 00168 Rome, Italy. Tel. +39 06 30156054. Fax +39 06 35501928. E-mail: tommaso.tartaglione@gmail.com

BASIC RESEARCH IN OTORHINOLARYNGOLOGY

# Macrophageal infiltration and microvessel density in laryngeal carcinoma: study of 52 cases

## *Infiltrazione macrofagica e densità capillare nel carcinoma della laringe. Studio su 52 casi*

T.M. POPOV<sup>1</sup>, T. DIKOV<sup>3</sup>, T.E. GORANOVA<sup>2</sup>, G. STANCHEVA<sup>2</sup>, R.P. KANEVA<sup>2</sup>, S. TODOROV<sup>1</sup>, O. STOYANOV<sup>1</sup>, J. RANGACHEV<sup>1</sup>, T. MARINOV<sup>1</sup>, D.P. POPOVA<sup>1</sup>, V.I. MITEV<sup>2</sup>, D. KONOV<sup>1</sup>

<sup>1</sup> Department of ENT, Medical University of Sofia, Bulgaria; <sup>2</sup> Department of Medical Chemistry and Biochemistry and Molecular Medicine Center, Medical University of Sofia, Bulgaria; <sup>3</sup> Department of Pathology, Medical University of Sofia, Bulgaria

### SUMMARY

Angiogenesis is one of the six originally constituted hallmarks of cancer that has been extensively studied in the last two decades. The aim of our study is to assess the microvessel and macrophageal density in laryngeal carcinoma and its clinicopathological correlations. We immunohistochemically assessed microvessel density (CD34) and macrophage count (CD68) using microarray techniques and then looked for clinicopathological correlations. The mean micro-vessel density in the study group was  $14.27 \pm 12.92$  vessels in a  $\times 200$  field with a mean macrophageal infiltration density of  $5.19 \pm 4.32$ . Median microvessel density was significantly higher in patients with metastasis than in patients without metastasis. Additionally, linear regression established that macrophageal infiltration density could predict microvessel density in laryngeal carcinoma. We found no association between either factor and recurrence rate or other clinical characteristics. Our study adds additional data to a problem that has been widely studied during the last two decades, even if controversies in this area still remain.

KEY WORDS: Laryngeal carcinoma • Macrophage count • Micro-vessel density • CD31 • CD68

### RIASSUNTO

*L'angiogenesi è uno dei sei principali meccanismi alla base del cancro, ed è stato studiato approfonditamente negli ultimi 20 anni. L'obiettivo del presente studio è stato quello di determinare sia la densità capillare sia l'infiltrato macrofagico nei campioni di carcinoma laringeo e di determinarne la correlazione con gli aspetti clinici e patologici. Sia la densità capillare (CD34) sia l'infiltrato macrofagico (CD68) sono stati determinati con metodiche immunostochimiche mediante microarray. Il nostro campione ha mostrato una densità capillare media di  $14,27 \pm 12,92$  vasi su campo ingrandito a  $200\times$ , e l'infiltrato macrofagico medio è stato di  $5,19 \pm 4,32$ . La densità capillare si è dimostrata superiore nei pazienti metastatici. Inoltre uno studio di regressione lineare ha mostrato che l'entità dell'infiltrato macrofagico poteva predire la densità capillare del campione di carcinoma laringeo preso in esame. Non abbiamo invece individuato una correlazione fra ambo i fattori studiati e l'incidenza delle recidive o gli altri fattori clinici presi in esame. Il nostro studio aggiunge dati ad un problema che per quanto studiato a fondo negli ultimi 20 anni resta nella sostanza controverso.*

PAROLE CHIAVE: Carcinoma della laringe • Conta macrofagica • Densità capillare • CD31 • CD68

Acta Otorhinolaryngol Ital 2015;35:321-324

## Introduction

Angiogenesis is one of the six originally constituted hallmarks of cancer that has been extensively studied in the last two decades<sup>1</sup>. It is an intricate multistep process of endothelial migration and proliferation, capillary maturation, anastomosis and lumen development along with extracellular matrix remodelling<sup>2,3</sup>. Numerous studies have demonstrated that highly vascularised tumours show a higher potency to produce metastases compared to less angiogenic neoplasms<sup>4-6</sup>. Angiogenesis requires the activation of many receptors by their respective cognate

ligands. These include vascular endothelial growth factors (VEGF), placental growth factor (PlGF), fibroblast growth factors (FGF-1 and -2), platelet-derived growth factor (PDGF), hepatocyte growth factor (HGF), angiopoietins (Ang-1 and -2), epidermal growth factor/transforming growth factor- $\alpha$  (EGF/TGF- $\alpha$ ) and others. VEGF is known to play the most important role in angiogenesis. The most common antibodies used for microvessel staining at present are against Von Willebrand Factor (Factor VIII), CD31 and CD34. Macrophages with other inflammatory cell types provide

growth factors, cytokines, proteolytic enzymes, proteoglycan, lipid mediators and prostaglandins. All of these factors cause marked changes in inflammatory loci by interacting with epithelial, mesenchymal and vascular endothelial cells<sup>7</sup>. Almost 150 years ago, Rudolf Virchow first indicated the concept that lymphoreticular infiltration reflects the origin of cancer at sites of chronic inflammation, suggesting a close connection between inflammation and the development of cancer. Nowadays, the features shared by cancer and inflammation have been highlighted by proposing novel therapeutic strategies targeting the inflammatory responses in tumour stroma. A recent study demonstrated that stromal interactions between malignant cells and inflammatory cells may be closely associated with angiogenesis and progression of cancer<sup>8</sup>.

The aim of our study was to assess microvessel and macrophageal density in laryngeal carcinoma and its clinicopathological correlations.

## Materials and methods

### *Patient recruitment and assessment*

The study was carried out in the ENT department of University Hospital "Queen Jovanna", Sofia, Bulgaria in cooperation with the Molecular Medicine Center at Medical University of Sofia over the period 2010-2013. Fifty-two patients with histopathologically verified carcinoma of the larynx were enrolled in the study. Informed consent was obtained from all patients and the protocol of the study was approved by the Ethics committee of Medical University of Sofia. A standardised clinical history was obtained for each patient. Detailed descriptions of the endoscopic/microscopic direct laryngoscopy findings were recorded along with the results of CT scans. All patients were followed for at least two years after their operation and any locoregional recurrences and death events were recorded.

### *Tissue microarray construction and immunohistochemistry*

In this study, paraffin tissue microarray construction was conducted as routine method. Briefly, a section was cut from each paraffin block and stained with haematoxylin and eosin (H&E). Each donor block was overlaid with the corresponding H&E slide and observed by experienced pathologists. The area in the donor block for tissue microarray sampling was verified according to the H&E slide and marked. An automatic tissue arrayer (Beecher Instruments Inc., USA) was used for array construction. Three representative 1.0-mm cores were removed from each donor block and transferred to a premolded recipient paraffin block with designated orientation. Monoclonal antibody CD31 was used for visualisation of microvessel density and CD68 for macrophageal infiltration density (Dako, Agilent Technologies Inc.). Visualisation was

performed with an EnVision FLEX, Mini Kit, High pH (Dako, Agilent Technologies Inc.).

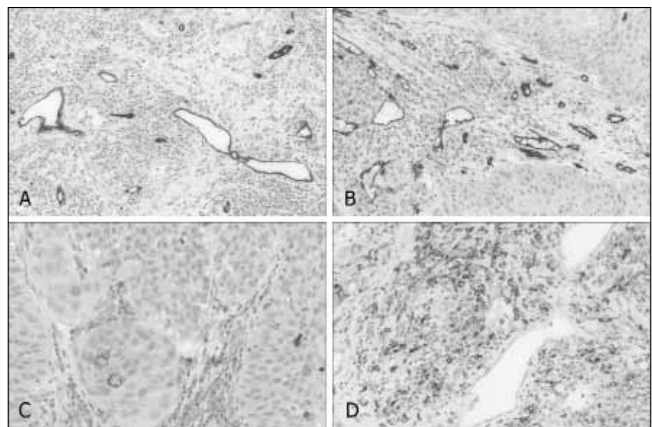
### *Assessment of tumour microvessel density and macrophageal infiltration*

Microvessel density scoring was based on modification of the method described by Weidner et al.<sup>10</sup> in which large microvessels and any single brown-staining endothelial cell clearly separated from adjacent microvessels, tumour cells and other connective tissue elements were considered a single, countable microvessel. Branching structures were counted as 1, unless there was a break in the continuity of the vessel, in which case it was counted as 2 distinct vessels. Microvessel density was scored by counting the number of vessels in three  $\times 200$  fields. Positivity for CD68 was scored quantitatively according to the number of positive stromal cells by an experienced pathologist without knowledge of patient characteristics.

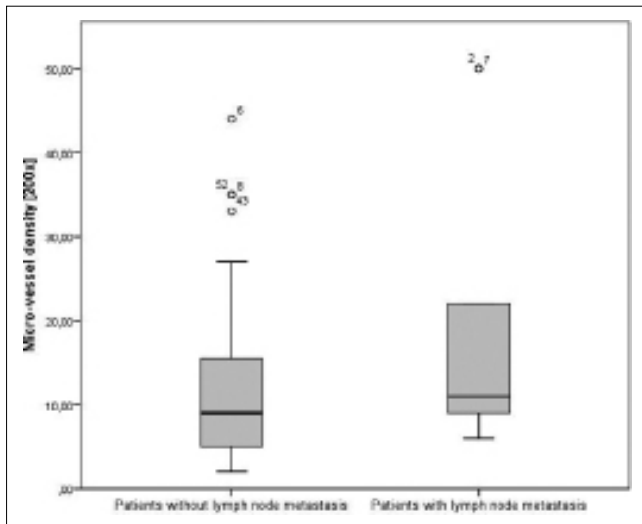
## Results

The mean age of the study group was  $60.15 \pm 7.4$  years (range 41-76). There were two female patients. All patients had histologically verified squamous cell carcinoma of the larynx. Distribution according to TNM classification was as follows: one patient was staged T1 (1.92%), six T2 (11.54%), 19 T3 (36.5%) and 26 T4 (50%). Thirteen patients (25%) had histologically verified lymph node metastases at the time of surgery.

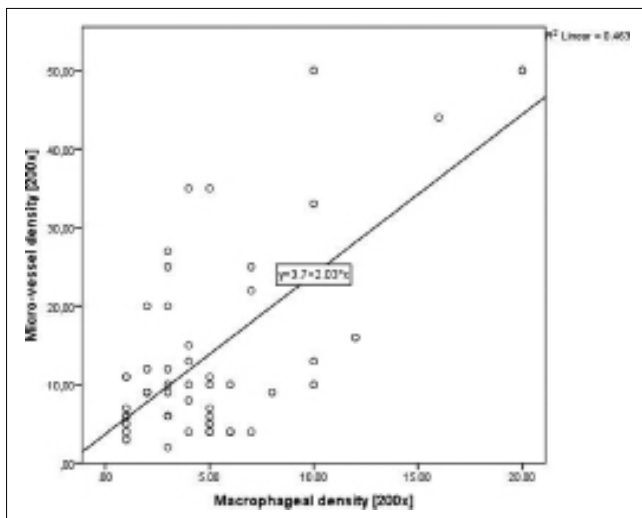
The mean microvessel density in the entire study group was  $14.27 \pm 12.92$  vessels,  $\times 200$  field, and the mean macrophageal infiltration density was  $5.19 \pm 4.32$  (Fig. 1). There was no statistically significant difference for in vessel densities between the different tumour stages ( $p = 0.268$ ,  $p = 0.441$ ). A Mann-Whitney U test was run to determine if there were differences in microvessel density between patients with



**Fig. 1.** CD31+ immunohistochemical visualisation of microvessel density in laryngeal carcinoma (A, B). CD68+ immunohistochemical visualisation of macrophageal infiltration density in laryngeal carcinoma (C, D).



**Fig. 2.** Microvessel density in patients with and without lymph node metastasis at the time of surgery.



**Fig. 3.** Linear correlation between microvessel and macrophageal infiltration density in laryngeal carcinoma.

histologically verified metastasis and patients without metastasis at the time of surgery. Median microvessel density was significantly higher in patients with metastasis (33.04 mean rank) than in those without metastasis (24.32 mean rank),  $U = 338.5$ ,  $p < 0.05$  (Fig. 2).

Spearman's rank-order correlation was run to assess the relationship between microvessel density and macrophageal infiltration density in the studied group. The relationship was monotonic, as assessed by visual inspection of a scatterplot. There was significant positive correlation between both variables,  $r_s = 0.333$ ,  $p < 0.05$ .

Additionally, linear regression established that macrophageal infiltration density could statistically significantly predict microvessel density in laryngeal carcinoma (Fig. 3),  $F(1, 50) = 43.034$ ,  $p < 0.0005$  and macrophageal

infiltration density accounted for 46.3% of the explained variability in micro-vessel density ( $R^2 = 0.463$ ). The regression equation was: microvessel density =  $-3.704 + 2.035 \times (\text{macrophageal density})$ .

We found no association between recurrence rate or other clinical characteristics and microvessel or macrophageal density.

## Discussion

The role of the immune system as an important factor that significantly influences the process of tumour neovascularisation, is well-established<sup>2</sup>. Despite this fact, we could not find any studies that report data on microvascular density and macrophageal tumour density in laryngeal carcinoma. The results from our study undeniably suggest that the tumour-associated macrophages in laryngeal carcinoma have a significant role in inducing the process of angiogenesis described in other malignancies<sup>10</sup>.

When we consider the density of tumour angiogenesis as a prognostic clinical factor, three potential associations should be discussed. (1) Correlation between microvessel density and primary lesion stage (T-stage); (2) Correlation between micro-vessel density and the process of metastasis; (3) Correlation between microvessel density and locoregional recurrences. This is a widely studied area of interest in oncology and after a thorough research of the published literature we have found 15 publications that report results for microvessel density in laryngeal carcinoma. For all three associations, we have found controversial findings. The results from our study suggest that there is no relationship between microvessel density and T-stage, which is supported by the findings of Hagedorn<sup>11</sup> et al. and Tse et al.<sup>12</sup>. Kyzas P et al.<sup>13</sup>, Lentsch et al.<sup>14</sup> and Zvrko et al.<sup>15</sup> reach the opposite conclusion, showing that higher T-staged tumours also have a higher density of microvessels. Similarly, conflicting evidence have been reported regarding the correlation between microvessel density and dissemination of metastasis. In our study group, patients with higher microvessel density also showed a higher percentage of metastasis at the time of surgery, which was also reported by Murray et al.<sup>16</sup>. Later, Tse et al.<sup>12</sup> and Kyzas et al.<sup>13</sup> found no such associations in their studies. The prognostic value of neovascularisation is one of the most studied prognostic factors for locoregional recurrences, which according to our results have no relationship with tumour vessel density. Published studies are divided on this aspect. Hagedorn et al.<sup>11</sup> and Tse et al.<sup>12</sup> confirm our findings, whereas Teknos et al.<sup>17</sup> and Marioni<sup>18</sup> suggest that higher rate of neovascularisation is a poor predictor of locoregional recurrence.

## Conclusions

Our study adds additional data to a problem that has been widely studied during the last two decades. Despite this,

the controversies in this area remain and additional studies are necessary.

## Acknowledgements

Part of this study was funded by a grant from the Medical University of Sofia 13-D/2013.

## References

- <sup>1</sup> Hanahan D, Weinberg RA. *The hallmarks of cancer*. Cell 2000;100:57-70.
- <sup>2</sup> Folkman J. *What is the evidence that tumors are angiogenesis dependent?* J Natl Cancer Inst 1990;82:4-6.
- <sup>3</sup> Folkman J. *Angiogenesis in cancer, vascular, rheumatoid and other disease*. Nat Med 1995;1:27-31.
- <sup>4</sup> Zetter BR. *Angiogenesis and tumor metastasis*. Annu Rev Med 1998;49:407-424.
- <sup>5</sup> Klijanienko J, el-Naggar AK, de Braud F, et al. *Tumor vascularization, mitotic index, histopathologic grade, and DNA ploidy in the assessment of 114 head and neck squamous cell carcinomas*. Cancer 1995;75:1649-56.
- <sup>6</sup> Beatrice F, Cammarota R, Giordano C, et al. *Angiogenesis: prognostic significance in laryngeal cancer*. Anticancer Res 1998;18:4737-40.
- <sup>7</sup> Ono M. *Molecular links between tumor angiogenesis and inflammation: inflammatory stimuli of macrophages and cancer cells as targets for therapeutic strategy*. Cancer Sci 2008;99:1501-6.
- <sup>8</sup> Lin WW, Karin M. *A cytokine-mediated link between innate immunity, inflammation, and cancer*. J Clin Invest 2007;117:1175-83.
- <sup>9</sup> Wicki A, Christofori G. *The Angiogenic Switch in Tumorigenesis*. In: Marme D, Fusenig N, editors. *Tumor Angiogenesis*. 1<sup>st</sup> ed. Heidelberg: Springer-Verlag; 2008. p. 79-80.
- <sup>10</sup> Leek RD, Lewis CE, Whitehouse R, et al. *Association of macrophage infiltration with angiogenesis and prognosis in invasive breast carcinoma*. Cancer Res 1996;56:4625-9.
- <sup>11</sup> Hagedorn HG, Nerlich AG. *Microvessel density and endothelial basement membrane composition in laryngeal squamous cell carcinomas*. Acta Otolaryngol 2000;120:891-8.
- <sup>12</sup> Tse GM, Chan AW, Yu KH, et al. *Strong immunohistochemical expression of vascular endothelial growth factor predicts overall survival in head and neck squamous cell carcinoma*. Ann Surg Oncol 2007;14:3558-65.
- <sup>13</sup> Kyzas PA, Stefanou D, Batistatou A, et al. *Prognostic significance of VEGF immunohistochemical expression and tumor angiogenesis in head and neck squamous cell carcinoma*. J Cancer Res Clin Oncol 2005;131:624-30.
- <sup>14</sup> Lentsch EJ, Goudy S, Sosnowski J, et al. *Microvessel density in head and neck squamous cell carcinoma primary tumors and its correlation with clinical staging parameters*. Laryngoscope 2006;116:397-400.
- <sup>15</sup> Zvrko E, Mikic A, Vuckovic L. *CD105 expression as a measure of microvessel density in supraglottic laryngeal squamous cell carcinoma*. Euro Archiv Otorhinolaryngol 2009;266:1971-6.
- <sup>16</sup> Murray JD, Carlson GW, McLaughlin K, et al. *Tumor angiogenesis as a prognostic factor in laryngeal cancer*. Am J Surg 1997;174:523-6.
- <sup>17</sup> Teknos TN, Cox C, Barrios MA, et al. *Tumor angiogenesis as a predictive marker for organ preservation in patients with advanced laryngeal carcinoma*. Laryngoscope 2002;112:844-51.
- <sup>18</sup> Marioni G, Ottaviano G, Giacomelli L, et al. *CD105-assessed micro-vessel density is associated with malignancy recurrence in laryngeal squamous cell carcinoma*. Eur J Surg Oncol 2006;32:1149-53.

Received: February 2, 2015 - Accepted: April 30, 2015

Address for correspondence: Todor Popov, Department of ENT, Sofia Medical University, Adriana Budevskas str 10, BG-1463 Sofia, Bulgaria. Tel. +359 889 987877. E-mail: popov@todorpopov.com

SALIVARY GLANDS

# Learning curve in diagnostic and interventional sialendoscopy for obstructive salivary diseases

## *Curva di apprendimento nella scialoendoscopia diagnostica e interventistica per le patologie salivari ostruttive*

P. FARNETI<sup>1</sup>, G. MACRÌ<sup>2</sup>, G. GRAMELLINI<sup>2</sup>, M. GHIRELLI<sup>3</sup>, F. TESEI<sup>3</sup>, E. PASQUINI<sup>3</sup>

<sup>1</sup> Department of Experimental, Diagnostic and Specialty Medicine, Dimes, Bologna University Medical School, Ear, Nose and Throat Unit of "Sant'Orsola-Malpighi" Hospital, Bologna, Italy; <sup>2</sup> Ear, Nose and Throat Unit of "Sant'Orsola-Malpighi" Hospital, Bologna, Italy; <sup>3</sup> Ear, Nose and Throat Metropolitan Unit, Surgical Department, AUSL Bologna, Italy

### SUMMARY

Sialendoscopy is a new diagnostic and surgical tool for management of salivary gland diseases that offers the opportunity to treat selected pathologies less invasively and with better results compared to previous techniques. As with any new technique, an adequate training programme involving a gradual learning curve is mandatory to quickly obtain results similar to those reported in the literature. This includes an appropriate diagnostic programme, correct patient selection and knowledge of possible pitfalls. In this retrospective study, the outcomes of the first 141 procedures (74 on the parotid gland and 67 on the submandibular gland) performed with this technique in our Department from 2009 to 2013 were compared with those reported in the literature. Patients were divided into three groups: Group A (the first 49 procedures performed), Group B (the next 50 procedures), and Group C (the last 42 procedures). There were no statistically significant differences relative to mean procedure times, recurrence of symptomatology after treatment, need for further treatments and rates of minor complications between groups. No major complications were seen. The increase in experience resulted in an increased number of interventional sialendoscopies performed under local anaesthesia instead of general anaesthesia (51% vs 18% vs 14%). In only three of 130 glands treated (2.3%) was gland resection required. We also evaluated which technique had been used for stone removal and rate of failure, which was similar in all groups (13.6% vs 15% vs 15%). Our results do not substantially differ from those reported in the literature. Initial difficulties in catheterising the papilla could be overcome with practise on fresh human specimens or fresh pig heads. Lack of precision regarding diagnostic imaging techniques was remedied by improving the competence of the surgeon in performing pre- and postoperative ultrasound. The creation of specialised centres capable of treating up to 1 to 2 million people would be desirable in order to better stratify pathologies, validate the investment in equipment and gain the necessary experience in the various surgical techniques.

KEY WORDS: Sialendoscopy • Learning curve • Training programme

### RIASSUNTO

La scialoendoscopia è un nuovo strumento diagnostico e chirurgico che offre l'opportunità di trattare alcune patologie delle ghiandole salivari con procedure non invasive e con risultati potenzialmente superiori alle precedenti tecniche. Come per tutte le nuove tecniche, per raggiungere rapidamente risultati paragonabili a quelli riportati in letteratura, è indispensabile un corretto programma di formazione che segua una graduale curva di apprendimento. Questo include un appropriato programma diagnostico, una corretta selezione dei pazienti e la conoscenza delle possibili insidie operatorie. Abbiamo eseguito uno studio retrospettivo confrontando le prime 141 procedure (74 parotidiche e 67 sottomandibolari) eseguite con questa tecnica nel nostro Dipartimento dal 2009 al 2013 con analoghe esperienze riportate in letteratura. I pazienti sono stati divisi in 3 gruppi: Gruppo A (le prime 49 procedure effettuate), gruppo B (le successive 50), Gruppo C (le ultime 42 procedure effettuate). Fra i tre gruppi non sono state evidenziate differenze statisticamente significative nei tempi medi di durata delle procedure, nella percentuale di ricorrenza della sintomatologia dopo il trattamento, nel numero di pazienti che hanno necessitato di più trattamenti e nell'incidenza di complicanze minori. Non sono state riportate complicanze maggiori. Con l'acquisizione di una maggiore esperienza da parte dei chirurghi si è evidenziato un progressivo calo del numero di interventi eseguiti in anestesia generale rispetto a quelli in anestesia locale (51% vs 18% vs 14%). Solo in tre casi su 130 ghiandole trattate (2.3%) è stato necessario eseguire un'asportazione ghiandolare. Per i calcoli salivari è stato valutato il tipo di tecnica utilizzato per l'estrazione e la percentuale d'insuccesso che era analoga nei tre gruppi (13.6% vs 15% vs 15%). I nostri risultati non differiscono sostanzialmente da quelli riportati in letteratura. Abbiamo risolto la difficoltà iniziale nella cateterizzazione del dotto con esercizi chirurgici su cadavere o su teste di maiale. La mancanza di precisione degli strumenti diagnostici radiologici può essere migliorata autonomizzando il chirurgo nell'esecuzione delle ecografie pre e post-operatorie. Viene infine sottolineata l'opportunità di creare dei centri di scialoendoscopia con un bacino di utenza di circa 1 o 2 milioni di abitanti in modo da concentrare le patologie, far fronte agli elevati costi della strumentazione necessaria e poter guadagnare la necessaria esperienza nella gestione delle varie tecniche chirurgiche.

PAROLE CHIAVE: Scialoendoscopia • Curva di apprendimento • Programma di formazione

## Introduction

Obstructive sialadenitis is the most common non-neoplastic disease of the salivary glands. The most frequent cause of obstructive sialadenitis is sialolithiasis (approximately 66%), which is found more commonly in the submandibular gland (80-90%) than in the parotid gland (5-10%) and sublingual and minor salivary glands (0-5%)<sup>1</sup>. Other aetiologies of salivary duct obstruction include stenoses, mucous plugs, anatomic ductal abnormalities, scar tissue and other foreign bodies<sup>2</sup>.

Since its introduction into clinical practice more than a decade ago, the modern technique of sialendoscopy has been used in clinical applications and has become the diagnostic tool and treatment of choice for ductal disorders of the salivary glands<sup>3</sup>. The natural evolution of proper technical instrumentation and sialoendoscopes has made it a safe, easy and indispensable technique.

Sialendoscopy is a minimally invasive procedure that can be carried out under local anaesthesia. The procedure can be performed in an outpatient setting since complication rates are low and recovery time is short<sup>3,4</sup>.

The successful application of sialendoscopy, as with all minimally invasive procedures, requires a well-organised training programme. This includes appropriate diagnostic work-up, operative setting and patient selection. It is also important to understand the possible pitfalls.

Since sialendoscopy requires specific expertise, the surgeon's level of training and experience are key factors in achieving a successful outcome. Learning curves for other endoscopic procedures have already been widely reported; however, the first reports regarding sialendoscopy are very recent<sup>3,5,6</sup>. Our objective was to review our experience, compare our outcomes to those of other groups using this technique and present our learning curve in diagnostic and interventional sialendoscopy for obstructive salivary diseases.

## Materials and methods

We designed a retrospective study involving 118 patients with symptoms of obstructive sialadenitis who underwent one or more sialendoscopies in our Department from January 2009 to December 2013. We followed the indications that Nahlieli first outlined in detail regarding the diagnosis and treatment of obstructive salivary gland diseases<sup>7</sup>. Sialendoscopies were performed by two different surgeons at the Ear, Nose and Throat (ENT) Unit of Sant'Orsola-Malpighi Hospital, Bologna, Italy and the ENT Metropolitan Unit, AUSL Bologna. Both surgeons attended a practical training course on pig heads before starting their surgical sialoendoscopic activity. They also had long-term experience in advanced endoscopic sinus surgery. Assistance by an experienced surgeon was provided at the beginning of their experience for the most

difficult cases, especially for large salivary stone removal using combined techniques.

Our equipment included:

- 0.8, 1.1 and 1.6 Karl Storz semiflexible sialoendoscopes;
- Storz Stone Extractor, diameter 0.4 mm, basket with 4 wires;
- foreign body forceps, diameter 0.8 mm;
- progressive salivary duct probes from size 0000 to size 6;
- conic dilatator for salivary ducts;
- full HD Image1 Storz camera.

Statistical analysis was carried out using SAS® Version 9.3. (SAS, Inc., Cary, NC). The Kruskal-Wallis, chi-square and Fisher's exact tests were used to compare the groups. Differences were considered significant at a  $p < 0.05$ .

All patients were evaluated using preoperative and post-operative ultrasound examination to diagnose sialadenitis and evaluate the outcomes of treatment.

Patients were treated with both local (LA) and general (GA) anaesthesia. Those treated with LA were prepared with lidocaine 10 g/100 ml spray before performing salivary duct dilatation. Once the instrument was introduced, the duct was rinsed with 2% lidocaine and 0.9% sodium chloride at a ratio of 1:1. Local infiltrations with 2% mepivacaine with 1:200,000 epinephrine were performed only when a papillotomy was needed or in the case of a combined technique for salivary stone removal.

At the end of each procedure, a rinsing solution with hydrocortisone 1 g/20 ml in 0.9% sodium chloride in 20 ml syringes was utilised.

Stenoses were dilated with the passage of the sialoendoscope or with forceps as balloon dilatators were not available in our Departments. Mucous plugs were removed by irrigation or by forceps.

Stones were removed using a stone extractor when possible or with a combined technique in cases of larger or impacted stones.

Neither extracorporeal shock-wave lithotripsies (ESWLs) nor laser intra-corporeal lithotripsies were performed due to the absence of these devices in our Departments.

We followed the algorithm proposed by Koch et al. for treatment of obstructive sialadenitis<sup>8</sup>. All patients who were candidates for ESWL were sent to another institution with which we collaborate.

The following demographic and clinical data were collected: age, sex, type of treated gland, pre- and post-operative radiological data, pre- and postoperative diagnosis, intraoperative findings and treatment procedure used. Persistence and healing or worsening of the symptomatology for each gland were also analysed.

## Results

During the first 5 years of our experience, 118 patients were treated. In these, 71 parotid glands and 59 subman-

**Table I.** Number of glands treated, mean procedure time and standard deviation (SD) for each group, number of complications, number of gland resections, number of cases where failure to catheterise the papilla was reported.

	Group A	Group B	Group C
Glands treated	49	50	42
Mean times (min)	49.73 (15-110) SD 26.53	46.90 (15-189) SD 34.11	47.00 (10-180) SD 36.72
Complications	3	4	2
Gland resection	2	0	1
Failure to catheterise the papilla	1	2	2

dibular glands were treated involving a total of 141 sialendoscopic procedures: 74 sialendoscopies on the parotid gland and 67 on the submandibular gland. The mean age of patients was 48.9 years (range 6 to 99). Forty-six patients were male (39%) and 72 were female (61%).

Patients were divided into three groups to compare outcomes. Group A (the first 49 procedures performed from 2009 to 2011), Group B (the second 50 procedures performed in 2012) and Group C (the third 42 procedures performed in 2013).

The mean follow-up was 17 months (range: 1-36 months) for Group A, 11 months (range: 0-22 months) for Group B and 6 months (range: 0-13 months) for Group C. Only two patients were lost to follow-up.

The average time for procedures in each group was compared using the Kruskal-Wallis test.

The comparison was not statistically significant: Group A vs Group B vs Group C ( $p = 0.3480$ ), Group A vs Group B ( $p = 0.2347$ ), Group B vs C ( $p = 0.7896$ ) Group A vs C ( $p = 0.1979$ ).

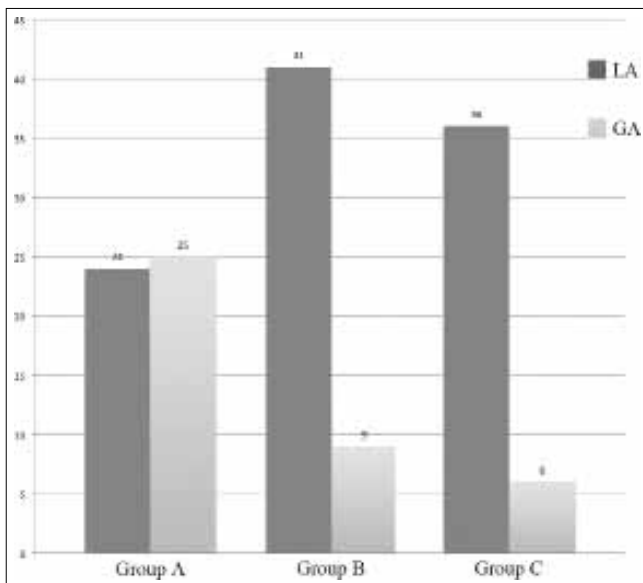
No major complications occurred in any group. Only 3 minor complications were reported in Group A (two infections, one wire basket breaking), 4 in Group B (one wire

basket breaking, one transient paresis of the VII cranial nerve, one distal stenosis, one syncope) and 2 in Group C (one lingual paraesthesia, one infection) (Table I).

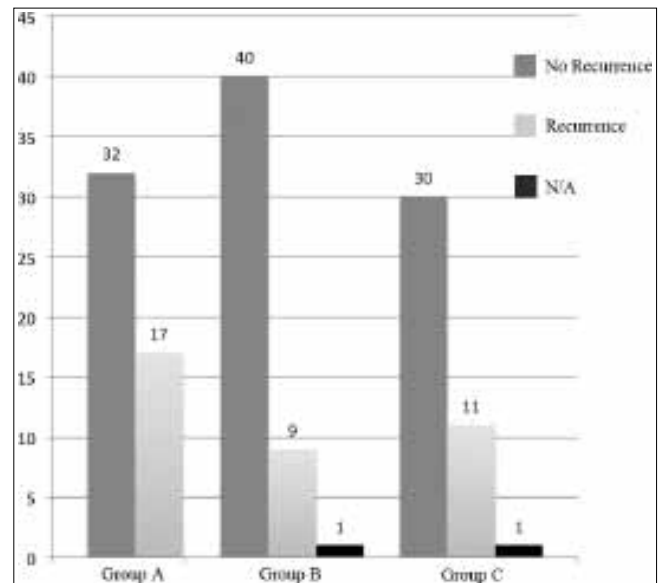
Submandibular gland resection was required in only three of 130 glands treated (2.3%): one for persistent microlithiasis and two for recurrence of an intraparenchymal stone. Failure to catheterise the papilla was reported in only 5 cases (in one case, it was a parotid gland and in 4 cases a submandibular gland).

The number of patients treated with GA (Fig. 1) was higher in Group A (51% vs 18% vs 14%,  $p < 0.0001$ ) compared to Groups B and C. Using the chi-square test, Group A vs Group B ( $p = 0.0005$ ) and Group A vs Group C ( $p = 0.0002$ ) were statistically significant, while Group B vs Group C was not ( $p = 0.6310$ ).

Patients were asked at the last follow-up check-up or in a telephone interview if they had any recurrence of preoperative symptoms. Even if a higher recurrence of symptoms after treatment (Fig. 2) was reported in Group A, there was no significant difference between the three groups (34.7% vs 18.4% vs 26.8%:  $p = 0.1878$ ) [Group A vs Group B ( $p = 0.0672$ ), Group B vs Group C ( $p = 0.3362$ ), Group A vs Group C ( $p = 0.4222$ )].

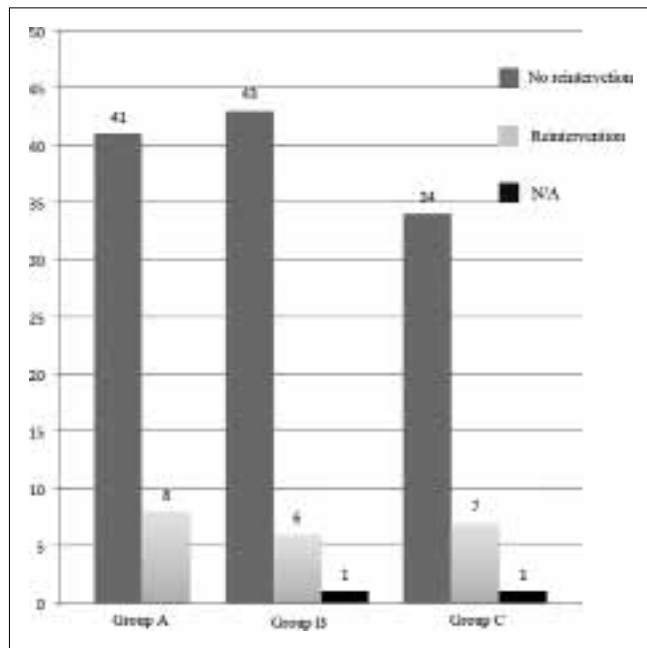


**Fig. 1.** Comparison of patients who underwent LA vs GA (LA: local anaesthesia; GA: general anaesthesia).



**Fig. 2.** Comparison of cases with recurrence of symptoms (N/A: data not available).





**Fig. 3.** Comparison of cases where further intervention was needed (N/A: data not available).

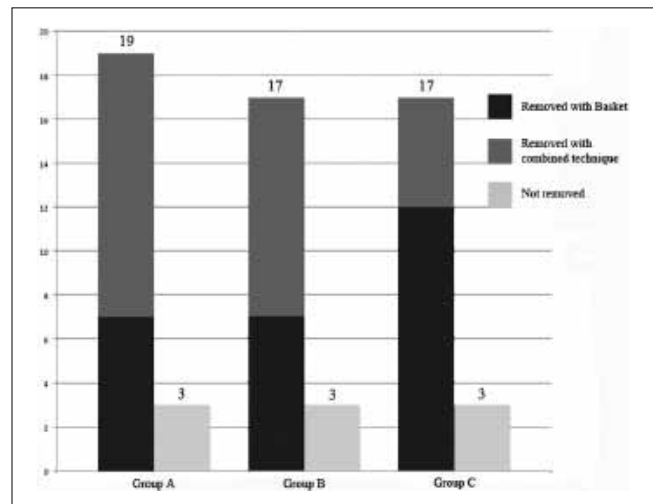
With the chi-square test, there was no significant difference among cases who needed further intervention (medical or surgical) between groups (16.3% vs 12.2% vs 17.1%:  $p = 0.7814$ ) (Fig. 3) [Group A vs Group B ( $p = 0.5637$ ) Group B vs Group C ( $p = 0.5164$ ) Group A vs Group C ( $p = 0.9246$ )].

*Sialolithiasis*

Sixty-two (44%) glands in 55 patients were treated for a salivary stone: 18 parotid (29%) and 44 submandibular (71%). Twenty-three patients were male (42%) and 32 were female (58%).

In 9 cases, (3 parotid and 6 submandibular), removal of the stones was not possible at the first attempt. In three cases, only a partial removal of the stones was obtained, and in 50 cases (15 parotid, 35 submandibular) complete removal at the first attempt was obtained.

Among the 9 cases in which the procedure failed, 3 underwent a second surgical operation under GA (1 parotid and 2 submandibular) with complete stone removal; in one case, microlithiasis was found (the patient underwent submandibular gland resection one year later), 4 cases are still waiting for removal and one case had spontaneous removal of the stone after a papillotomy of the parotid gland. In the 53 remaining patients, the stones were re-



**Fig. 4.** Comparison of salivary stone removal outcomes.

moved using a basket in 26 cases and with combined techniques in 27 cases (Fig. 4). Endoscopic removal of the stone or a combined approach was carried out in 7 cases vs 12 in Group A (36.8%), 7 vs 10 in Group B (41.2%) and 12 vs 5 in Group C (70.6%), respectively ( $p = 0.0949$ ) [Group A vs Group B ( $p = 0.7900$ ), Group B vs Group C ( $p = 0.0842$ ) and Group A vs Group C ( $p = 0.0429$ )]. The techniques adopted for combined removal were: transoral duct slitting (for 21 submandibular glands), opening of the duct over the surface of the stone (for 5 submandibular glands) and endoscopically-assisted transcutaneous stone retrieval (for 1 parotid gland).

Using Fisher's exact test, there was no significant difference among the outcomes of stone removal between groups (86.4% vs 85% vs 85%:  $p = 1.0000$ ) [A vs B ( $p = 1.0000$ ) A vs C ( $p = 1.0000$ ), B vs C ( $p = 1.0000$ )]. Using the Kruskal-Wallis test, there was a decrease in operative time between Group A and Group C even if this was not statistically significant ( $p = 0.3480$ ) (Table II).

*Other causes*

Twenty-eight glands were treated for ductal stenoses: 17 parotid (12%) and 11 (7.8%) submandibular. In 3 cases, a salivary stone was associated. One stenosis of a parotid gland was due to a previous stone extraction using a basket. Patients had recurrence of symptoms in 4 cases of 8 in Group A, 1 case of 9 in Group B and in 3 cases of 11 in Group C. Using Fisher's exact test, there was no significant difference between the three groups: A vs B ( $p = 0.1312$ ), A vs C ( $p = 0.3765$ ), B vs C ( $p = 0.5913$ ).

**Table II.** Number of glands treated, mean procedure time and standard deviation (SD) for each group.

	Group A	Group B	Group C
Glands treated	22	20	20
Mean time (min)	69.82 (33-110) SD 24.27	66.15 (20-189) SD 41.53	61.70 (10-180) SD 42.16

In 3 cases, a ductal stent was positioned to avoid restenosis.

In 15 cases, mucous plugs were found (6 were isolated, 5 were associated with a ductal stenosis, 3 with sialolithiasis and 1 with a polyp involving the duct wall).

Four patients were also treated for juvenile recurrent parotitis (2 cases were bilateral). One patient had no additional episodes of sialadenitis after the first treatment, 2 patients had recurrences but less frequently, while the last is scheduled for another treatment due to persistence of the symptomatology.

Forty cases were classified as diagnostic sialendoscopies.

## Discussion

The management of salivary obstruction has changed dramatically over the past 20 years<sup>9</sup>. The pertinent data suggest that the current standard of practice, which is gland resection, will not be tenable in the future<sup>9</sup>. Sialendoscopy is useful since it is less invasive and has a lower morbidity compared to other techniques.

Studies in animals and humans have demonstrated how obstruction of the proximal duct does not cause irreversible damage to the salivary glands<sup>10</sup>. Recovery of secretory function after stone removal with sialendoscopy is guaranteed in most cases<sup>11</sup> as reported by scintigraphic examination<sup>12</sup> and normalisation of the histological pattern<sup>13</sup>.

There are few reports in the literature regarding the learning curve for this new technique.

Conversely, learning curves for other endoscopic procedures have been reported, especially endoscopic sinus surgery<sup>3</sup>. Marks has argued that, with rigorous training of the physician, the learning curve can, for the most part, be completed during residency training, allowing the new practitioner to perform endoscopic sinus surgery safely with good results<sup>14</sup>. Sialendoscopy, like all endoscopic techniques, requires specific skills. According to Luers, a shorter learning curve can be expected because otolaryngologists are commonly experienced with endoscopic procedures in general, and an experienced supervisor can support the process by direct feedback and practical help<sup>3</sup>. However, sialendoscopy differs from other endoscopic procedures in many ways (e.g., smaller endoscopes, newer instruments, endoscopy in a fluid-filled branched system and local anaesthesia)<sup>3</sup>.

The actual endpoint of the individual learning curve, with performance results, operating times and rate of complications similar to those reported in the literature, could be identified in approximately 50 cases<sup>3,5</sup>.

As with any new technology, there are several barriers for beginning a successful sialendoscopy programme<sup>2</sup>.

Kroll, with a statistical survey regarding the prevalence of sialendoscopy in ENT clinics, documented how, in 2009, it was performed in only a minority (24%) of ENT

Departments in Germany. Its diffusion was hampered by technical problems, lack of cost benefit, lack of adequate instrumentation and a limited number of patients<sup>15</sup>.

To reach levels comparable to those reported in the literature, it is necessary to:

- have a good knowledge of the anatomy and physiology of the salivary glands and the floor of the mouth<sup>16</sup>;
- have adequate instrumentation;
- participate in hands on courses, conferences and live surgery;
- take advantage of an experienced supervisor using direct feedback and practical help, especially during the initial procedures;
- gain experience in surgical techniques for canalising and dilating the duct, and in the use of appropriate endoscopes with fresh human specimens or fresh pig heads;
- have competence in managing any potential complications and be comfortable with major salivary gland resection, if required<sup>16</sup>.

For the most part, obstructive sialadenitis (66%) is associated with sialolithiasis. However, the frequency of salivary gland stones is higher as documented by postmortem findings (1.2% of the general population)<sup>17</sup>. Escudier calculated that 59 patients/million in the general population are hospitalised annually for up to 3 days each year with obstructive salivary gland diseases (stones and chronic sialadenitis)<sup>18</sup>. According to Kroll, the range of pathologies that can be treated with sialendoscopy affects 2% of the general population<sup>15</sup>. For this reason, it can be assumed that, in the near future, complete removal of a salivary gland that could have been treated with sialendoscopy will be less sustainable<sup>15</sup>. Based on these data, it can be calculated that treatment of obstructive salivary stones will probably have to be centralised for populations of about 1 to 2 million<sup>9,10</sup>.

The presence of approximately 30 specialised centres in Italy would therefore be desirable, evenly divided in accordance with an appropriate catchment area in order to:

- centralise diseases;
- validate investment in staff and equipment to provide the service<sup>10</sup>;
- gain the necessary experience in the various minimally invasive methods.

In fact, there can be many treatment options (sialendoscopy, ESWL, intracorporeal shock wave lithotripsy<sup>19</sup>, laser intra-corporeal lithotripsy, interventional radiology, video-assisted conservative surgical removal of parotid and submandibular calculi, and botulinum therapy)<sup>11,20</sup>. Each of these techniques may be used as a single therapeutic modality or in combination with one or more of the above-mentioned options<sup>11</sup>. Only a centre with an almost complete range of treatment options could therefore have an adequate rate of success in cases of obstructive sialadenitis.

At the outset, the first difficulty encountered with this new technique is represented by the elevated initial cost of the sialoendoscopes and related equipment<sup>2,15</sup>.

Sialendoscopy should therefore be initiated after having secured a catchment area which allows amortising the expense.

Technically, the first problem to be encountered is related to difficulties in canalising and dilating the duct to allow for appropriate endoscopic use, bypassing and dilating strictures<sup>2</sup>.

In our department, this first obstacle was overcome by organising practical courses on fresh pig heads. The salivary duct anatomy of these animals is similar to that of humans and allows for good preoperative training. The experience of our group, gained with endoscopic dacryocystorhinotomy and tear duct probing, also explains the low rate of failure in our series in locating and dilating the papilla. The five cases reported in Table I (3.6%) include one in Group A, 2 in Group B and 2 in Group C, and cannot be considered as related to lack of experience (in one case, it was due to a distal stenosis). When initial identification and dilatation of the punctum seems challenging, it may be useful to perform it under magnification with loupes or, as reported by other authors, with a microscope<sup>2</sup>. In our experience, we preferred to start this part of the procedure using a conic dilatator since, unlike progressive probes, they are less traumatic and lead to a lower risk of creating false paths.

Sialoendoscopic treatment of salivary stones without the need for gland resection may be performed more frequently with increased surgical experience as confirmed by our and other series<sup>6</sup>.

There was the same number of cases in each group in which it was not possible to remove the stone (3 cases in each group). In our department, additional improvement and a less frequent need to perform a combined approach can be guaranteed by the introduction of an extracorporeal shock-wave lithotritor and a laser for intra-corporeal lithotripsy.

Another parameter in the advancement of the learning curve is the need to perform the sialoendoscopic procedure under general anaesthesia increasingly less frequently. In Group A, the number of patients operated on under general anaesthesia was almost the same as those operated on under local anaesthesia with a statistically significant improvement in Groups B and C. The first obstacles and difficulties, common to any new procedure, can easily be overcome by performing the first procedures under general anaesthesia, which will help in achieving the learning curve faster. According to Vairel et al., with an increase in experience, an increased number of interventional sialendoscopies could be performed under local anaesthesia, limiting the use of general anaesthesia to more complex cases or to non-compliant patients<sup>5</sup>.

Considering our results, there are no statistically sig-

nificant differences among procedure times, number of complications or rate of success among and after the first 30-50 cases, which were considered the endpoint of the learning curve. According to our experience, we found it more difficult to plan a correct approach for each individual case rather than to perform the surgical procedure itself. This was mainly due to the fact that, in many cases, it was not possible to rely on preoperative radiological findings and, consequently, to accurately predict surgical timing. Nahlieli et al. reported that, of 22 patients treated for submandibular sialolithiasis, 7 (32%) were undetected by imaging techniques (conventional radiography, sialography and ultrasound) and of 10 patients with sialoliths in the parotid gland, 7 (70%) sialoliths were not detected<sup>21</sup>. In our experience, in 20 cases in which a stone was detected with echography, there was no evidence of it with sialendoscopy; in only 4 of these cases did additional examination demonstrate the presence of the stones in the salivary duct system. In 47 cases, echography was positive for a salivary stone as confirmed by sialendoscopy but, in 9 cases (6.4%), it was undetected and found only with sialendoscopy.

The large variability in the timing of each case due to the lack of pre-operative information can cause problems in planning interventions or in deciding whether to use general or local anaesthesia.

A possible solution would be to increase the competence of the surgeon in carrying out pre- and postoperative ultrasound. This is already the case in German and Swiss centres. This could help in acquiring more experience in preoperative diagnostics and, more precisely, in defining salivary stone position, dimension and relationship with respect to the ductal walls.

## Conclusions

In order to achieve good results with sialendoscopy, it is mandatory to carry out complete surgical training with practical courses and/or supervision by an expert surgeon. Previous knowledge of endoscopic sinus surgery can facilitate the first learning phase. Adequate experience with traditional surgery on salivary glands is also required to manage cases of failure involving the endoscopic procedure. Operating on the first cases under general anaesthesia may be helpful in avoiding patient discomfort due to longer procedure times. An aid in reducing false positives and negatives in preoperative imaging is autonomy in pre- and postoperative ultrasound execution, or direct collaboration with the radiologist.

## Acknowledgements

We would like to thank Elisa Carretta for carrying out the statistical analysis.

## References

- <sup>1</sup> Bodner L. *Salivary gland calculi: diagnostic imaging and surgical management*. Compendium 1993;14:572-86.
- <sup>2</sup> Maresh A, Kutler DI, Kacker A. *Sialoendoscopy in the diagnosis and management of obstructive sialadenitis*. Laryngoscope 2011;121:495-500.
- <sup>3</sup> Luers JC, Damm M, Klussmann JP, et al. *The learning curve of sialoendoscopy with modular sialoendoscopes: a single surgeon's experience*. Arch Otolaryngol Head Neck Surg 2010;136:762-65.
- <sup>4</sup> Nahlieli O, Nakar LH, Nazarian Y, et al. *Sialoendoscopy: a new approach to salivary gland obstructive pathology*. J Am Dent Assoc 2006;137:1394-400.
- <sup>5</sup> Vairel B, De Bonnecaze G, Al Shehri S, et al. *Courbe d'apprentissage en sialoendoscopie: nos 101 premières procédures*. Rev Laryngol Otol Rhinol 2012;133,4:177-81.
- <sup>6</sup> Modest MC, Galinat L, Rabinowitz M, et al. *Learning progression in the use of sialoendoscopy for sialolithiasis: effect on gland preservation*. Otolaryngol Head Neck Surg 2014;151:240-5
- <sup>7</sup> Nahlieli O, Baruchin AM. *Endoscopic technique for the diagnosis and treatment of obstructive salivary gland diseases*. J Oral Maxillofac Surg 1999;57:1394-401.
- <sup>8</sup> Koch M, Zenk J, Iro H. *Algorithms for treatment of salivary gland obstructions*. Otolaryngol Clin North Am 2009;42:1173-92.
- <sup>9</sup> Mc Gurk M, Brown J. *Alternatives for the treatment of salivary duct obstruction*. Otolaryngol Clin North Am 2009;42:1073-85.
- <sup>10</sup> Iro H, Zenk J, Escudier MP, et al. *Outcome of minimally invasive management of salivary calculi in 4,691 patients*. Laryngoscope 2009;119:263-8.
- <sup>11</sup> Capaccio P, Torretta S, Ottaviani F, et al. *Modern management of obstructive salivary diseases*. Acta Otorhinolaryngol Ital 2007;27:161-72
- <sup>12</sup> Yoshimura Y, Morishita T, Sugihara T. *Salivary gland function after sialolithiasis: scintigraphic examination of submandibular glands with 99m Tc-pertechnetate*. J Oral Maxillofac Surg 1989;47:704-10.
- <sup>13</sup> Marchal F, Kurt AM, Dulguerov P, et al. *Histopathology of submandibular gland removed for sialolithiasis*. Ann Otol Rhinol Laryngol 2001;110:464-9.
- <sup>14</sup> Marks SC. *Learning curve in endoscopic sinus surgery*. Otolaryngol Head Neck Surg 1999;120:215-8.
- <sup>15</sup> Kroll T, Finkensieper M, Hauk H, et al. *Sialoendoscopy-learning curve and nation-wide survey in German ENT-departments*. Laryngorhinotologie 2012;91:561-8.
- <sup>16</sup> Wilson M, McMullen K, Walvekar R. *Sialoendoscopy: endoscopic approach to benign salivary gland diseases*. In: Iancu C, editor. *Advances in endoscopic surgery*. Rijeka, Croatia: InTech; 2011. p. 101-16.
- <sup>17</sup> Ruach S, Gorlin RJ. *Diseases of the salivary glands*. In: Gorlin RJ, Goldman HM, editors. *Oral Pathology*, 6<sup>th</sup>. St Louis, MO: Mosby; 1970. p. 997-1003.
- <sup>18</sup> Escudier MP, McGurk M. *Symptomatic sialoadenitis and sialolithiasis in the English population, an estimate of the cost of hospital treatment*. Br Dent J 1999;186:463-6.
- <sup>19</sup> Serbetci E, Sengor GA. *Sialoendoscopy: experience with the first 60 glands in Turkey and a literature review*. Ann Otol Rhinol Laryngol 2010;119:155-64.
- <sup>20</sup> Capaccio P, Torretta S, Pignataro L. *The role of adenectomy for salivary gland obstruction in the era of sialoendoscopy and lithotripsy*. Otolaryngol Clin North Am 2009;42:1161-71.
- <sup>21</sup> Nahlieli O, Baruchin AM. *Sialoendoscopy: three years' experience as a diagnostic and treatment modality*. J Oral Maxillofac Surg 1997;55:912-8.

Received: August 1, 2014 - Accepted: February 2, 2015

SLEEP DISORDERS

# Which cephalometric analysis for maxillo-mandibular surgery in patients with obstructive sleep apnoea syndrome?

## *Quale analisi cefalometrica per la chirurgia maxillo-mandibolare in pazienti con sindrome delle apnee ostruttive notturne?*

B. BREVI<sup>1</sup>, A. DI BLASIO<sup>2</sup>, C. DI BLASIO<sup>1</sup>, F. PIAZZA<sup>3</sup>, L. D'ASCANIO<sup>3</sup>, E. SESENNA<sup>1</sup>

<sup>1</sup> Department of Maxillo-Facial Surgery, University Hospital of Parma, Italy; <sup>2</sup> Department of Dentistry, University Hospital of Parma, Italy; <sup>3</sup> Department of Otolaryngology-Head & Neck Surgery, "Carlo Poma" Civil Hospital of Mantova, Italy

### SUMMARY

Maxillo-mandibular advancement MMA is considered an efficacious treatment for patients affected by severe obstructive sleep apnoea syndrome (OSAS). Even though OSAS improvement is the main goal of MMA, excessive maxillo-mandibular protrusion should be avoided to guarantee pleasant postoperative facial aesthetics. In order to attain such a result, the amount of MMA should be planned preoperatively by both aesthetic and cephalometric analyses. Steiner and Delaire cephalometric analyses are commonly used in the preoperative planning of orthognathic surgery for dentofacial deformities, however controversies still exist about the basis and postoperative aesthetic results of such cephalometric analyses in OSAS patients candidate for MMA. Forty-eight patients affected by severe OSAS were submitted to MMA. Pre- and post-operative Steiner and Delaire cephalometric tracings were assessed in each subject. For Steiner analysis, the variation in the SNA and SNB angles was measured, while for Delaire tracings the variation in the C3/FM-CPA and C3/FM-Me angles was assessed. Mean MMA was 6.9 + 3.8 mm for the maxilla and 13.6 + 5 mm for the mandible. After surgery, an improvement of the apnoea-hypopnoea index was recorded (40.47 + 7.64 preoperative vs. 12.56 + 5.78 postoperative). In all patients, both cephalometric analyses showed pre-surgical bimaxillary retrusion. After surgery, the mean value of Steiner's SNA angle increased from 78.18° to 85.58° (p < 0.001), while mean Delaire's C3/FM-CPA angle increased from 81.19° to 89.71° (p < 0.001). The mean value of Steiner's SNB angle increased from 74.33° to 80.73° (p < 0.001), while Delaire's C3/FM-Me angle increased from 80.10° to 87.29° (p < 0.001). Postoperatively, both the maxilla and mandible were in a more protrusive position (p < 0.001) according to Steiner analysis compared with Delaire tracing. Basing MMA on Delaire cephalometric analysis leads to an increased advancement of the maxillo-mandibular complex than Steiner tracing. The consequences of this aspect on facial aesthetics should be considered during surgical planning and preoperative informed consent in OSAS patients candidate for MMA.

KEY WORDS: Cephalometry • OSAS • Maxillo-mandibular surgery • Steiner analysis • Delaire analysis

### RIASSUNTO

*L'avanzamento maxillo-mandibolare (AMM) è un trattamento efficace per pazienti affetti da sindrome delle apnee ostruttive notturne (OSAS) di grado severo. Sebbene il miglioramento dell'OSAS sia l'obiettivo principale di tale chirurgia, è necessario evitare un avanzamento maxillo-mandibolare eccessivo per garantire un gradevole risultato in termini di estetica facciale. A tale scopo, è necessario programmare preoperatoriamente l'entità dell'AMM mediante un'analisi estetica e cefalometrica. Le analisi cefalometriche di Steiner e Delaire vengono comunemente impiegate nella programmazione della chirurgia ortognatica per deformità dentofacciali, tuttavia resta controverso il ruolo di tali analisi nei pazienti con OSAS candidati a AMM. Quarantotto pazienti con OSAS severa sono stati sottoposti a AMM. Abbiamo effettuato le analisi cefalometriche di Steiner e Delaire in tutti i soggetti. Per il tracciato di Steiner, abbiamo misurato la variazione degli angoli SNA e SNB, mentre per l'analisi di Delaire, abbiamo misurato la variazione degli angoli C3/FM-CPA e C3/FM-Me. L'AMM medio è stato di 6,9 + 3,8 mm per il mascellare superiore e 13,6 + 5 mm per la mandibola. Dopo l'intervento abbiamo riscontrato un miglioramento dell'Indice di Apnea-Ipopnea (40,47 + 7,64 preoperatoriamente vs. 12,56 + 5,78 postoperatoriamente). In tutti i pazienti, entrambe le tecniche cefalometriche hanno dimostrato una retrusione bimaxillare preoperatoria. Dopo l'intervento, l'angolo SNA medio è aumentato da 78,18° a 85,58° (p < 0,001), mentre l'angolo C3/FM-CPA medio è aumentato da 81,19° a 89,71° (p < 0,001). Il valore medio dell'angolo SNB è aumentato da 74,33° a 80,73° (p < 0,001), mentre l'angolo medio C3/FM-CPA è passato da 80,10° a 87,29° (p < 0,001). Postoperatoriamente, sia il mascellare superiore che la mandibola risultavano in una posizione più protrusa (p < 0,001) se analizzati secondo l'analisi di Steiner rispetto al tracciato di Delaire. L'utilizzo dell'analisi cefalometrica di Delaire nella programmazione dell'AMM in pazienti con OSAS comporta un avanzamento maxillo-mandibolare superiore rispetto al tracciato di Steiner. È opportuno considerare le conseguenze di tale risultato sull'estetica facciale durante la programmazione chirurgica e nel consenso informato preoperatorio in pazienti con OSAS candidati a AMM.*

PAROLE CHIAVE: Cefalometria • OSAS • Chirurgia maxillo-mandibolare • Analisi di Steiner • Analisi di Delaire

Acta Otorhinolaryngol Ital 2015;35:332-337

## Introduction

Maxillo-mandibular advancement (MMA) surgery is often indicated for the correction of dento-facial deformities. The ability of MMA to produce an increase in pharyngeal diameters is the anatomic-physiologic rationale of MMA for the surgical treatment of severe obstructive sleep apnoea syndrome (OSAS)<sup>1-7</sup>. In such cases, the surgical goal is to attain the maximal advancement of the maxillo-mandibular complex – and therefore improvement of the apnoea-hypopnoea index (AHI) – while preserving pleasant postoperative facial aesthetics<sup>1-3</sup>.

Patients affected by OSAS usually display a class II malocclusion and a retrusive profile<sup>4-5, 8</sup>. In these subjects, MMA surgery is usually well-accepted from an aesthetic viewpoint, since the advancement of the maxillo-mandibular complex also leads to improvement of the retrusive profile. In selected situations, such as the aging face, a mild degree of skeletal overprotrusion (with respect to the theoretical cephalometric position) is usually well tolerated. Nevertheless, if the final protrusion is excessive, especially in Caucasian patients, the facial aesthetics may be less pleasing. In general, it is difficult to predict the post-surgical soft tissue profile and decide the limit that should not be exceeded to avoid unpleasant aesthetic results.

Several authors have suggested the need for cephalometric analysis in OSAS patients to provide comprehensive information regarding the postoperative harmony of the facial skeleton<sup>1-5, 8-16</sup>. However, even harmonious skeletal support does not always result in an aesthetically

desirable profile of facial soft tissues<sup>14-16</sup>. Despite these limitations, the use of cephalometric analyses in surgical planning for OSAS patients is common<sup>1-5, 8-11</sup>. Most plannings use the planes and angles derived from Steiner cephalometric analysis<sup>1, 2, 9, 11, 17-19</sup>, whereas other authors suggest using Delaire analysis<sup>20-23</sup>. Even though both Steiner and Delaire cephalometric analyses describe the ideal relationship of the facial skeleton in the sagittal and vertical dimensions, some differences between them exist: in Steiner analysis, the sella-nasion (SN) line is used as the reference plane, while SNA and SNB angles are measured to assess the maxillary and mandibular anterior positions (Fig. 1). In Delaire cephalometric analysis, the C3 plane is used as the horizontal reference, while maxillary and mandibular anterior positions are assessed by FM-CPA and FM-Me (with respect to C3 plane) (Fig. 2). Even though the cephalometric principles of Steiner and Delaire analyses in orthognathic surgery for dentofacial deformities are well known, controversies still exist about the basis and postoperative aesthetic results of such cephalometric analyses in OSAS patients who are candidates for MMA.

The aim of this prospective study is to compare the outcomes of these two methods of analysis based on a broad sample of surgical OSAS cases. This paper addresses the following questions: do Steiner and Delaire preoperative cephalometric analyses provide the same skeletal and soft tissue facial assessment? Do they lead to any difference in surgical planning and results? And if so, which analysis is advisable when planning MMA surgery in OSAS patients?

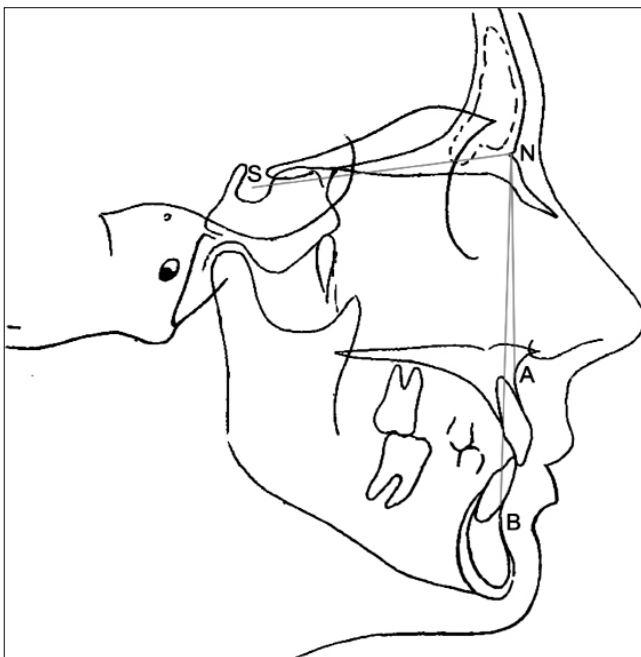


Fig. 1. Steiner cephalometric analysis: maxilla and mandible evaluations.

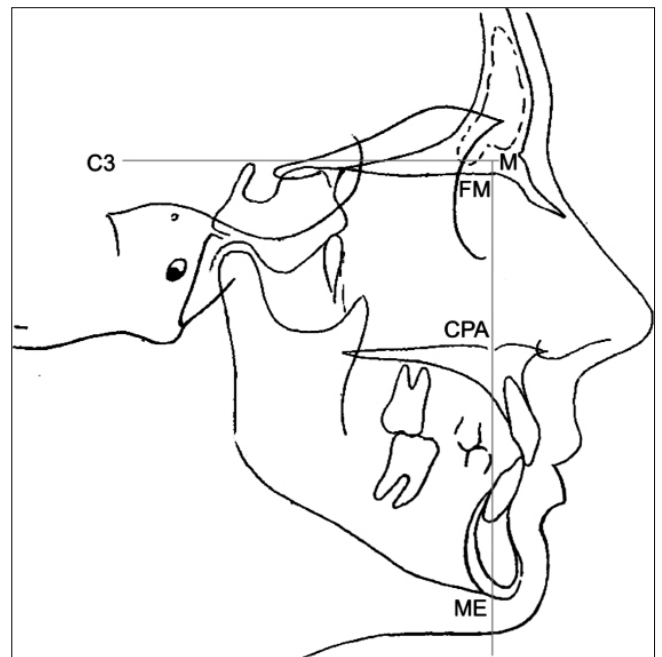


Fig. 2. Delaire cephalometric analysis: maxilla and mandible evaluations.

## Materials and methods

A prospective analysis of 48 consecutive OSAS patients submitted to maxillo-mandibular surgery between 2000 and 2013 was carried out. All patients were male and had a mean age of 45.7 years (range: 21-67). The patients were submitted to MMA for severe OSAS at the Department of Maxillofacial Surgery, Parma University Hospital. Inclusion criteria were: 1) preoperative severe OSAS (AHI  $\geq$  30) diagnosed by polysomnography; 2) availability of good quality pre- and post-surgical lateral telerradiographies of the cranium; 3) patients' ability to understand and sign a written informed consent to be submitted to MMA.

The updated version of AASM Manual for Scoring Sleep and Associated Events was used to correctly assess the AHI index. According to the AASM, an apnoea/hypopnoea event is defined as a decrease in airflow of  $\geq$  30% (by a valid measure of airflow) lasting  $\geq$  10 sec, associated with either  $\geq$  3% desaturation from the pre-event baseline or an arousal<sup>24-28</sup>.

The aesthetic balance of facial profile was evaluated according to Rosen's criteria<sup>29</sup>. In Rosen's surgical strategy, when a final biprotrusion is necessary, an acceptable aesthetic outcome is defined as the appropriate balance among the relative projection of subnasal, upper and lower vermilions and chin points<sup>29</sup>.

All patients were submitted to MMA. Preoperative antibiotic prophylaxis (amoxicillin/clavulanate 2.2 g i.v.) was administered. Analgesic therapy (ketoprofen) and steroids (dexamethasone) were administered as needed. The amount of MMA surgery was planned preoperatively in agreement with the aesthetical considerations of facial skeletal expansion criteria proposed by Rosen<sup>29</sup>.

Anatomical tracings of the pre- and post-surgical (6 months postoperatively) radiographs were drawn by an expert operator. All anatomical tracings were digitised and differences in image magnification, when present, were eliminated using appropriate software (Corel Photo-paint 11.0). On the magnification-normalised anatomical tracings, the same expert tracer carried out measurements according to Steiner and Delaire analyses to assess the antero-posterior positions of the maxilla and mandible.

For Steiner analysis, we measured:

- Maxilla. SNA: the angle between the sella/nasion plane and the nasion/A plane (normal value at the end of growth  $82 \pm 2^\circ$ ). This angle assesses the antero-posterior position of the maxilla relative to the upper cranial structures.
- Mandible. SNB: the angle between the sella/nasion plane and nasion/B plane (normal value at the end of growth  $80 \pm 2^\circ$ ). This angle assesses the antero-posterior position of the mandible relative to the upper cranial structures.

For Delaire analysis, we measured:

- Maxilla. The angle between C3 and FM-CPA line. In this analysis, C3 represents the ideal horizontal plane: it is drawn between M point (nose-fronto-maxillary suture point) and posterior clinoid apophysis, and is parallel to the ethmoid's lamina cribra. The fronto-maxillary (FM) point is located along C3 plane immediately above the anterior lacrimal crest and under the bony crest in the frontal sinus floor. The CPA point is located at the anterior edge of the upper limit of the nose-palatal foramen. Normally, at the end of growth, this angle is  $90^\circ$  in males and  $85^\circ$  in females. This angle assesses the position of the maxilla and the pre-maxilla in relation to the upper cranial structures.
- Mandible. The angle between C3 and FM-Me line. The Me point is located at the junction between the image of the symphysis and mandibular body. Normally, at the end of growth, this angle is  $90^\circ$  in males and  $85^\circ$  in females. This angle assesses the position of the mandible relative to the upper cranial structures.

Statistical analyses were performed using the Statistical Package for Social Sciences Software (SPSS 10.0 for Windows; SPSS, Inc., Chicago, IL) and STATA 7 (Stata Corp., College Station, TX). Data are shown as mean and standard deviation (SD). Parametric (Student's t-test) test was used to compare different values. Statistical significance was considered when  $p < 0.05$  (two tailed).

## Results

All 48 patients submitted to MMA were discharged 3 to 5 days after surgery. No complications (i.e. bleeding, plate fractures, etc.) were noticed. In our sample, the mean MMA was  $6.9 + 3.8$  mm for the maxilla and  $13.6 + 5$  mm for the mandible. After surgery, we observed statistically significant ( $p < 0.001$ ) improvement of the AHI index vs. preoperative conditions with a final score under 20 in all patients.<sup>23</sup> In particular, mean AHI decreased from  $40.47 + 7.64$  preoperatively to  $12.56 + 5.78$  postoperatively. When comparing Steiner and Delaire cephalometric analyses, several differences between pre- and post-surgical assessment and skeletal balance were noted.

### Pre-surgical analysis

- Maxillary position.* In our sample, the mean pre-surgical value of SNA according to Steiner analysis was  $78.18^\circ$ . The  $3.82^\circ$  difference with regards to mean normal value ( $82 \pm 2^\circ$ ) reveals a maxillary displacement of approximately two standard deviations behind the ideal position. The mean value of CPA-FM to C3 angle according Delaire analysis was  $81.19^\circ$ : an  $8.81^\circ$  difference with regards to normal values ( $90^\circ$ ), indicating severe maxillary posterior displacement.
- Mandibular position.* Among our patients, the mean pre-surgical SNB value was  $74.33^\circ$ . The  $5.67^\circ$  differ-

**Table I.** Pre- and post-surgical position of the maxilla and mandible assessed with Steiner and Delaire analyses. According to Steiner tracing, maxillary and mandibular positions were determined with SNA and SNB angles, respectively. Basing on Delaire analysis, maxillary and mandibular positions were determined with C3/FM-CPA and C3/FM-Me angles, respectively. The statistical (t-test) comparison between pre- and post-operative maxillary and mandibular position is reported for each cephalometric analysis.

	Steiner analysis			Delaire analysis		
	Preoperative (degrees)	Postoperative (degrees)	p	Preoperative (degrees)	Postoperative (degrees)	P
Maxilla	78.18 + 2.75	85.58 + 3.79	< 0.001*	81.19 + 3.59	89.71 + 3.49	< 0.001*
Mandible	74.33 + 4.73	80.73 + 3.89	< 0.001*	80.10 + 4.86	87.29 + 4.46	< 0.001*

\* Statistically significant.

ence compared with mean normal value ( $80 \pm 2^\circ$ ) reveals severe mandibular posterior displacement. The mean value of Me-FM to C3 angle was  $80.10^\circ$ : a  $9.90^\circ$  difference with regards to normal values ( $90^\circ$ ), indicating severe mandibular posterior displacement (Table I).

#### Post-surgical analysis

- a) *Maxillary position.* After surgery, the mean value of Steiner's SNA angle increased from  $78.18^\circ$  to  $85.58^\circ$ , with a  $7.40^\circ$  increase. Mean Delaire's CPA-FM to C3 angle increased from  $81.19^\circ$  to  $89.71^\circ$ , with an  $8.52^\circ$  angular advancement. A statistically significant increase was seen according to both cephalometric analyses (Table I). When comparing postoperative maxillary position with respect to the ideal parameters according to Steiner and Delaire analyses, the maxilla is in a more protrusive position ( $p < 0.001$ ) with Steiner analysis than with Delaire tracing (Table II).
- b) *Mandibular position.* After surgery, the mean value of Steiner's SNB angle increased from  $74.33^\circ$  to  $80.73^\circ$ , with a  $6.4^\circ$  advancement. Delaire's Me-FM to C3 angle increased from  $80.10^\circ$  to  $87.29^\circ$ , with a  $7.19^\circ$  advancement. A statistically significant increase was seen by both cephalometric analyses (Table I). When comparing postoperative mandibular position with respect to the ideal parameters according to Steiner and Delaire analyses, the mandible is in a more protrusive position ( $p < 0.001$ ) according to Steiner analysis with respect to Delaire tracing (Table II).

**Table II.** Evaluation of postoperative maxilla and mandible position with respect to the ideal parameters according to Steiner and Delaire analyses. Maxillary and mandibular positions were determined with SNA and SNB angles, respectively, for Steiner tracing. For Delaire analysis, maxillary and mandibular positions were determined with C3/FM-CPA and C3/FM-Me angles, respectively. The difference between postoperative maxillary/mandibular position and their ideal location according to the different cephalometric analysis was calculated (t-test). Notice the postoperative more protrusive position of the maxilla and mandible according to Steiner analysis compared with Delaire tracing; \* statistically significant.

	Steiner analysis (degrees)	Delaire analysis (degrees)	p
Maxilla	3.58 + 3.79	-0.29 + 3.49	< 0.001*
Mandible	0.73 + 3.90	-2.71 + 4.46	< 0.001*

## Discussion

Maxillo-mandibular advancement has proven to be effective for surgical treatment of severe OSAS thanks to its ability to produce tongue advancement and an increase in pharyngeal diameters<sup>1-7</sup>. In these patients, the surgical goal is to attain the maximal advancement of the maxillo-mandibular complex while preserving pleasant facial aesthetics<sup>1-3</sup>.

Despite the efficacy of MMA to improve the AHI, controversies still exist about the amount of advancement required and preoperative planning in OSAS patients. In our common practice, the MMA surgical planning is generally based on Rosen's aesthetic criteria, since no cephalometric analysis has been shown to constantly predict postoperative aesthetical outcomes of soft tissues<sup>30-33</sup>. According to this approach, the amount of MMA is determined on the basis of the maximal biprotrusion attainable while preserving a pleasant facial soft tissue profile according to Rosen's criteria<sup>29</sup>. Since the definition of a pleasant profile as a surgical target can make preoperative planning difficult and subjective, in our study we drew pre- and post-operative Steiner and Delaire cephalometric tracings in all our patients submitted to MMA to compare the results with aesthetic planning based on Rosen's criteria. No significant difference between Steiner and Delaire analyses was found in pre-surgical diagnoses: both Steiner and Delaire tracings revealed a class II biretrusive starting position in our patients. The defect was evaluated as slightly more severe for Delaire than for Steiner analysis for both the maxilla and mandible. When examining post-surgical maxilla position, Steiner analysis showed a mean maxillary overcorrection by  $3.56^\circ$ , while according to Delaire analysis it was within the normal range. The final position of the mandible, in contrast, was normal for Steiner analysis, while according to Delaire tracing, the chin could have tolerated a mean further advancement of  $2.71^\circ$  with respect to normal values. These results suggest that the final position of the maxillo-mandibular complex was judged as slightly protrusive by Steiner and retrusive for Delaire analysis. Therefore, when related to Rosen's aesthetical criteria, the surgical limit suggested by Steiner tracing was more protrusive than that obtained with Delaire cephalometry. These different results may be relat-



ed to the fact that, even though both Steiner and Delaire cephalometric analyses describe the ideal relationship of the facial skeleton in the sagittal and vertical dimensions, their cultural bases were different<sup>1 2 9 11 17-23</sup>:

- a) Steiner and Delaire published in different times and environments: Steiner in the USA between 1950 and 1960, while Delaire worked in France between 1970 and 1980. The concept of the aesthetically ideal face was slightly more protrusive in the 70-80s than in 50-60s. Therefore, they adopted different normal values.
- b) Steiner's and Delaire's professional backgrounds were different: Steiner was an orthodontist, whereas Delaire was a maxillofacial surgeon. This may explain the difference in key points, angles and planes considered by the two authors. In particular, they used different horizontal ideal planes (SN for Steiner vs. C3 for Delaire) and measured maxillary/mandibular positions by analysing different points (surface points A and B for Steiner vs. deeper areas CPA and Me for Delaire).

These differences do not affect the ability of either cephalometric analysis to provide diagnostic and treatment support in OSAS patients, although Steiner analysis is more adherent to the final aesthetic balance proposed by Rosen<sup>29</sup>. In MMA surgery, the risk consists in excessive bimaxillary advancement. According to our results, the adoption of Delaire analysis leads to a higher risk to attain this undesirable result than Steiner tracing. For this reason, we suggest avoiding Delaire analysis in preoperative planning for MMA. On the contrary, our results suggest that basing MMA planning on Steiner cephalometry offers more predictable results from an aesthetic viewpoint and can simplify the surgeon's decisions. Finally, our experience confirms the efficacy of MMA in attaining improvement in the AHI in severe OSAS patients. It also underlines the close connection between aesthetics and function in OSAS subjects submitted to MMA surgery. As already shown by three-dimension cephalometry, the posterior airway space (PAS) is related to maxillomandibular position, which influences the aesthetic appearance of the face as well: function and aesthetics are concomitant consequences of the same surgical procedures in these subjects<sup>32-33</sup>. Maxillomandibular advancement surgery in OSAS patients causes both a PAS volume increase and variations of facial profile<sup>34</sup>. This aspect should be considered by the physician and patient when planning OSAS surgery.

## Conclusions

Basing MMA preoperative planning on Steiner tracing leads to more predictable and desirable postsurgical facial aesthetics than Delaire analysis. Therefore, Steiner tracing is preferable to Delaire analysis when planning MMA in OSAS patients.

## References

- <sup>1</sup> Partinen M, Guilleminault C, Quera-Salva MA, et al. *Obstructive sleep apnea and cephalometric roentgenograms. The role of anatomic upper airway abnormalities in the definition of abnormal breathing during sleep.* Chest 1998;93:1199-205.
- <sup>2</sup> Giarda M, Bruccoli M, Arcuri F, et al. *Efficacy and safety of maxillomandibular advancement in treatment of obstructive sleep apnoea syndrome.* Acta Otorhinolaryngol Ital 2013;33:43-6.
- <sup>3</sup> Goodday R. *Diagnosis, treatment planning, and surgical correction of obstructive apnoea.* J Oral Maxillofac Surg 2009;67:2183-96.
- <sup>4</sup> George LT, Barber HD, Smith BM. *Maxillomandibular advancement surgery: an alternative treatment option for obstructive sleep apnoea.* Atlas Oral Maxillofac Surg Clin North Am 2007;15:163-77.
- <sup>5</sup> Goodday R. *Treatment of obstructive sleep apnoea by immediate surgical lengthening of the maxilla and mandible.* In: Bell WH, Guerrero CA, editors. *Distraction Osteogenesis of the Facial Skeleton.* Hamilton, ON, Canada: Decker; 2007. p. 438.
- <sup>6</sup> Bianchi B, Ferri A, Brevi B, et al. *Orthognathic surgery for the complete rehabilitation of Moebius patients: Principles, timing and our experience.* J Craniomaxillofac Surg 2013;41:1-4.
- <sup>7</sup> Di Blasio A, Cassi D, Di Blasio C, et al. *Temporomandibular joint dysfunction in Moebius syndrome.* Eur J Paediatr Dent 2013;14:295-8.
- <sup>8</sup> Boyd SB. *Management of obstructive sleep apnoea by maxillomandibular advancement.* Oral Maxillofac Surg Clin North Am 2009;21:447-57.
- <sup>9</sup> DeBerry-Borowiecki B, Kurkwa A, Blanks RH. *Cephalometric analysis for diagnosis and treatment of obstructive sleep apnoea.* Laryngoscope 1988;98:226-34.
- <sup>10</sup> Zucconi M, Ferini-Strambi L, Palazzi S, et al. *Habitual snoring with and without obstructive sleep apnoea: the importance of cephalometric variables.* Thorax 1992;47:157-61.
- <sup>11</sup> Susarla SM, Abramson ZR, Kaban LB. *Cephalometric measurement of upper airway length correlates with the presence and severity of obstructive sleep apnoea.* J Oral Maxillofac Surg 2010;68:2846-55.
- <sup>12</sup> Fairburn SC, Waite PD, Vilos G, et al. *Three-dimensional changes in upper airways of patients with obstructive sleep apnoea following maxillomandibular advancement.* J Oral Maxillofac Surg 2007;65:6-12.
- <sup>13</sup> Mantovani M, Minetti A, Torretta S, et al. *The velo-uvulo-pharyngeal lift or "roman blinds" technique for treatment of snoring: a preliminary report.* Acta Otorhinolaryngol Ital 2012;32:48-53.
- <sup>14</sup> Arnett GW, Jelic JS, Kim J, et al. *Soft tissue cephalometric analysis: diagnosis and treatment planning of dentofacial deformity.* Am J Orthod Dentofacial Orthop 1999;116:239-53.
- <sup>15</sup> Arnett GW, Bergman RT. *Facial keys to orthodontic diagnosis and treatment planning.* Part I. Am J Orthod Dentofacial Orthop 1993;103:299-312.
- <sup>16</sup> Arnett GW, Bergman RT. *Facial keys to orthodontic diagno-*

- sis and treatment planning--Part II. *Am J Orthod Dentofacial Orthop* 1993;103:395-411.
- <sup>17</sup> Steiner CC. *Cephalometrics for you and me*. *Am J Orthod* 1953;39:729-55;.
- <sup>18</sup> Steiner CC. *Cephalometrics in clinical practice*. *The Angle Orthodontist* 1959;29:8-29;.
- <sup>19</sup> Steiner CC. *The use of cephalometrics as an aid to planning and assessing orthodontic treatment*. *Am J Orthod* 1960;46(;721-54.
- <sup>20</sup> Delaire J. *Architectural and structural telerradiographic analysis of the face*. *Orthod Fr* 1971;42:411-27.
- <sup>21</sup> Delaire J. *L'analyse architecturale et structurale cranio-faciale (de profil). Principes théoriques. Quelques exemples d'emploi en chirurgie maxillo-faciale*. *Revue de Stomatol Paris* 1978;79:1-33.
- <sup>22</sup> Delaire J. *Architectural and structural craniofacial analysis (lateral view). Theoretical principles. Some example of its use in maxillofacial surgery (translation)*. *Rev Stomatol Chir Maxillofac* 1978;79:1-33.
- <sup>23</sup> Delaire J, Schendel SA, Tulasne JF. *An architectural and structural craniofacial analysis: a new lateral cephalometric analysis*. *Oral Surg Oral Med Oral Pathol* 1981;52:226-38.
- <sup>24</sup> Redline S, Budhiraja R, Kapur V, et al. *The scoring of respiratory events in sleep: reliability and validity*. *J Clin Sleep Med* 2007;3:169-200.
- <sup>25</sup> Ruehland WR, Rochford PD, O'Donoghue FJ, et al. *The new AASM criteria for scoring hypopneas: impact on the apnea hypopnea index*. *Sleep* 2009;32:150-7.
- <sup>26</sup> BaHamam AS, Obeidat A, Barataman K, et al. *A comparison between the AASM 2012 and 2007 definitions for detecting hypopnea*. *Sleep Breath* 2014;18:767-73.
- <sup>27</sup> Salamanca F, Costantini F, Bianchi A, et al. *Identification of obstructive sites and patterns in obstructive sleep apnoea syndrome by sleep endoscopy in 614 patients*. *Acta Otorhinolaryngol Ital* 2013;33:261-6.
- <sup>28</sup> De Corso E, Fiorita A, Rizzotto G, et al. *The role of drug-induced sleep endoscopy in the diagnosis and management of obstructive sleep apnoea syndrome: our personal experience*. *Acta Otorhinolaryngol Ital* 2013;33:405-13.
- <sup>29</sup> Rosen HM. *Facial skeletal expansion: treatment strategies and rationale*. *Plast Reconstr Surg* 1992;89:798-808.
- <sup>30</sup> Goga D, Battini J, Belhaouari L, et al. *Improving the aesthetic results and patient satisfaction in orthognathic surgery*. *Rev Stomatol Chir Maxillofac Chir Orale* 2014;115:229-3.
- <sup>31</sup> Boutault F, Cadenat H. *Decision strategy in orthognathic surgery. Part 2: The aesthetic choice in orthognathic surgery--practical applications*. *Rev Stomatol Chir Maxillofac* 1992;93:287-97.
- <sup>32</sup> Burkhard JP, Dietrich AD, Jacobsen C, et al. *Cephalometric and three-dimensional assessment of the posterior airway space and imaging software reliability analysis before and after orthognathic surgery*. *J Craniomaxillofac Surg* 2014;42:1428-36.
- <sup>33</sup> Furuhashi A, Yamada S, Shiomi T, et al. *Effective three-dimensional evaluation analysis of upper airway form during oral appliance therapy in patients with obstructive sleep apnoea*. *J Oral Rehabil* 2013;40:582-9.
- <sup>34</sup> Ronchi P, Cinquini V, Ambrosoli A, et al. *Maxillomandibular advancement in obstructive sleep apnea syndrome patients: a retrospective study on the sagittal cephalometric variables*. *J Oral Maxillofac Res* 2013;1;4:e5.

Received: September 19, 2014 - Accepted March 8, 2015

## OTOLOGY

# Cartilage ossiculoplasty in cholesteatoma surgery: hearing results and prognostic factors

## *Risultati uditivi e fattori prognostici nell'ossiculoplastica con cartilagine in pazienti affetti da otite cronica colesteatomatosa*

N. QUARANTA, S. TALIENTE, F. COPPOLA, I. SALONNA

UOC Otorinolaringoiatria Universitaria, Azienda Ospedaliero-Universitaria Policlinico di Bari, Italy

## SUMMARY

Cartilage tympanoplasty is an established procedure for tympanic membrane and attic reconstruction. Cartilage has been used as an ossiculoplasty material for many years. The aim of this study was to evaluate hearing results of costal cartilage prostheses in ossicular chain reconstruction procedures in subjects operated on for middle ear cholesteatoma and to determine the presence of prognostic factors. Candidates for this study were patients affected by middle ear cholesteatoma whose ossicular chain was reconstructed with a chondroprosthesis. 67 cases of ossiculoplasty with total (TORP) or partial (PORP) chondroprosthesis were performed between January 2011 and December 2013. Follow-up examination included micro-otoscopy and pure tone audiometry. The guidelines of the Committee on Hearing and Equilibrium of the American Academy of Otolaryngology Head and Neck Surgery were followed and pure-tone average (PTA) was calculated as the mean of 0.5, 1, 2 and 4 kHz thresholds. Statistical analysis was performed with ANOVA tests and regression models. Average air-bone gap (ABG) significantly improved from 39.2 dB HL (SD 9.1 dB HL) to 25.4 dB HL (SD 11 dB HL) ( $p < 0.001$ ). Linear regression analysis showed that the only prognostic factor was the type of operation ( $p = 0.02$ ). In fact, patients submitted to ICWT presented better post-operative ABG compared to CWDT. None of the other variables influenced the results. The present study proposes costal cartilage as material of choice when autologous ossicles are not available. The maintenance of the posterior canal wall was the only prognostic factor identified.

KEY WORDS: Ossiculoplasty • Cholesteatoma • Ossicular Prosthesis • Surgery

## RIASSUNTO

La cartilagine è comunemente utilizzata per la ricostruzione della membrana timpanica e dell'attico in corso di timpanoplastica. Nella nostra esperienza la cartilagine costale omologa è stata utilizzata per molti anni per la creazione di protesi ossiccolari. Scopo di questo studio è stato quello di valutare i risultati funzionali dell'ossiculoplastica con condroprotesi e di identificare fattori prognostici. Abbiamo valutato pazienti affetti da otite media cronica colesteatomatosa la cui catena ossiculare è stata ricostruita mediante condroprotesi. 67 soggetti sono stati sottoposti a ossiculoplastica totale (TORP) o parziale (PORP) tra gennaio 2011 e dicembre 2013. Per la valutazione dei risultati uditivi sono state utilizzate le Linee Guida della "Committee on Hearing and Equilibrium" dell'American Academy of Otolaryngology Head and Neck. L'analisi statistica dei risultati è stata eseguita con test ANOVA e modelli di regressione lineare. Il gap via aerea-via ossea (ABG) migliorava significativamente dopo ossiculoplastica da 39,2 dB HL (DS 9,1 dB HL) a 25,4 dB HL (DS 11 dB HL) ( $p < 0,001$ ). L'analisi statistica ha dimostrato che l'unico fattore prognostico è stato il tipo di tecnica chirurgica utilizzata. Infatti, i pazienti sottoposti a timpanoplastica chiusa hanno presentato miglior ABG postoperatorio rispetto alla timpanoplastica aperta ( $p = 0,02$ ). Tutte le altre variabili analizzate non hanno influenzato i risultati uditivi. La cartilagine costale è il nostro materiale scelta per la creazione di protesi ossiccolari quando gli ossicini autologhi non sono disponibili. La tecnica chirurgica (timpanoplastica chiusa) si è dimostrata quale unico fattore prognostico positivo.

PAROLE CHIAVE: Ossiculoplastica • Colesteatoma • Protesi Ossiculare • Chirurgia

Acta Otorhinolaryngol Ital 2015;35:338-342

## Introduction

The reconstruction of the ossicular chain was first described by Zöllner<sup>1</sup> in 1955, since then several attempts have been made and several materials, biologic and synthetic, have been proposed for ossiculoplasty. The use of synthetic prosthesis in ossiculoplasty procedures is related to the fact that in cholesteatoma surgery autologous

ossicles are rarely available for the reconstruction of the ossicular chain. Recently, Albera et al.<sup>2</sup> reported that 82% of patients affected by cholesteatoma present resorbed ossicles during surgery. Although ossicles can be safely utilised without the risk of cholesteatoma recurrence<sup>3</sup>, in our experience they can rarely be used to sculpt valid ossicular prostheses.

Among synthetic materials, titanium has been used in os-

siculoplasty, and the results obtained with partial and total titanium prosthesis in intact canal wall tympanoplasty (ICWT) have been recently reported by our group. At 2 years follow-up, mean postoperative air-bone gap (ABG) was 24.1 dB HL in partial chondroprosthesis (PORP) and 27.2 dB HL in total chondroprosthesis (TORP), 5.1% of the prosthesis extruded and 10.5% of the patients required revision ossiculoplasty<sup>4</sup>.

The most frequent problem encountered with titanium prostheses is the risk of extrusion. Recently, Pringle et al.<sup>5</sup> reported an extrusion rate of 6,8%, while Yung and Smith<sup>6</sup> reported that 8 of 38 titanium prostheses extruded at 24 months even with cartilage interposition.

As a biological alternative to ossicles, cartilage has been extensively used in tympanoplasty and ossiculoplasty<sup>7</sup>. Autologous tragal and/or conchal cartilage are, however, not always suitable for ossicular chain reconstruction, especially in cases where the stapes arch is missing since they do not have the required mass, stiffness and thickness. Ossicular prostheses made from blocks of homologous costal cartilage were introduced in ear surgery by Carlo Zini in 1984 (personal communication). In 2000, the long-term results obtained with homologous costal cartilage prostheses in subjects affected by cholesteatoma undergoing ICWT were reported by Quaranta et al.<sup>8</sup>. The authors reported no extrusion at 10 years follow-up with stable functional results over the years.

The aim of this study is to evaluate the factors influencing hearing results when cartilage prostheses were used for ossicular chain reconstruction in a group of patients affected by middle ear and mastoid cholesteatoma and operated by the same surgeon.

## Materials and methods

Between January 2011 and December 2013, 67 ossiculoplasty procedures were performed in our department. Candidates for this study were patients affected by middle ear and mastoid cholesteatoma (both primary and recurrent) whose ossicular chain was reconstructed with homologous costal cartilage.

The study group consisted of 67 patients. Mean patient age was 45 years (range 7-79 years); 34 were males and 33 females. The ossiculoplasty was performed during the first or the second stage of tympanoplasty in 41 patients undergoing primary surgery, during revision ossiculoplasty in 13 patients and during the first or the second stage of revision tympanoplasty in 13 patients affected by recurrent cholesteatoma. The ossicular chain was reconstructed with a PORP when the stapes arch was present or with a TORP when the stapes arch was missing. The follow-up examination included micro-otoscopy and pure tone audiometry. The guidelines of the Committee on Hearing and Equilibrium of the American Academy of Otolaryngology Head and Neck Surgery<sup>9</sup> were followed and pure-tone average




Fig. 1. T-shaped partial ossicular replacement prostheses.

(PTA) was calculated as the mean of 0.5, 1, 2 and 4 kHz thresholds. ABG were calculated from air conduction (AC) and bone conduction (BC) thresholds determined in each study. Postoperative hearing gain was calculated from the PTA before the ossiculoplasty and at last follow-up examination. The change in the postoperative bone conduction was calculated as the preoperative minus the postoperative pure tone bone conduction average, obtained 6 weeks after surgery, at 1, 2 and 4 kHz. Minimum follow-up was 6 months. All patients signed an informed consent form and the work was performed in accordance with the principles of the 1983 Declaration of Helsinki.

### *Surgical technique*

1 × 1 cm costal cartilage blocks were obtained by the “Banca del Tessuto Muscolo-Scheletrico” of the Istituto Ortopedico Rizzoli, Bologna, Italy. The prosthesis is sculpted from the cartilage block as previously described<sup>8</sup>. Briefly, after the exact distance between the tympanic membrane (TM) and the stapes or the footplate has been determined, a T shaped chondroprosthesis is prepared (Fig. 1). When the stapes is present and mobile, a PORP is sculpted with a small indentation for stapes capitulum (1 mm wide and 0.5-1 mm in depth) at the end of the shaft. When the stapes superstructure is absent, a TORP is prepared. The end of the shaft is placed on the footplate, while the head, as for the PORP, is in contact with the TM or the graft used for its repair (Fig. 2). When the prosthesis is in its appropriate position, it can be stabilised with fibrin glue or a gelatin sponge. In the present series, in all cases the prostheses was placed under the malleus handle, but always parallel to it when it was present.



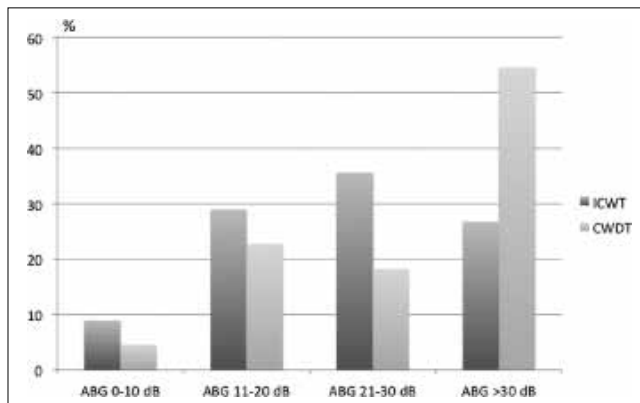
**Fig. 2.** T-shaped total ossicular replacement prostheses.

*Statistical analysis*

Multiple linear regression analysis was performed on the entire group. Post-operative ABG was considered the dependent variable, while independent variable were: type of surgery (primary vs revision); type of tympanoplasty (ICWT vs canal wall down-CWDT), staging (yes vs no), pre-operative ABG; type of prosthesis (PORP vs TORP), side (right vs left), age (< 60 yr vs > 60 yr), sex (male vs female). In addition, patients were split in three groups according to the type of surgery. The ANOVA test was used to compare the three groups and paired t-test was used to evaluate the significance of post-operative hearing change. Statistical software (Statistica 8.0) was used for analysis.

**Results**

In the entire group, average ABG significantly improved from 39.2 dB HL (SD 9.1 dB HL) to 25.4 dB HL (SD 11 dB HL) ( $p < 0.001$ ). Linear regression analysis showed that the only prognostic factor was the type of surgery ( $p = 0.02$ ). In fact, patients submitted to ICWT presented better post-operative ABG than CWDT. The pre-operative ABG was 37.9 dB HL (SD 8.9 dB HL) in patients submitted to ICWT and 38.6 dB HL (SD 9.4 dB HL) in patients submitted to CWDT. The mean postoperative ABG was, respectively, 23.3 dB HL (SD 10 dB HL) and 29.6 dB HL (SD 12 dB HL). Chi-square analysis showed



**Fig. 3.** Percentage of patients with different air-bone gap according to the technique used. CWDT: canal wall down tympanoplasty; ICWT: intact canal wall tympanoplasty.

**Table I.** Regression analysis of the factors influencing post-operative air bone gap.

Independent variable	p value
Type of tympanoplasty (ICWT vs canal wall down-CWDT)	0.02
Type of prosthesis (PORP vs TORP)	> 0.05
Pre-operative ABG	> 0.05
Type of surgery (primary vs revision)	> 0.05
Staging (yes vs no)	> 0.05
Side (right vs left)	> 0.05
Age (< 60 yr vs > 60 yr)	> 0.05
Sex (male vs female)	> 0.05

that the number of patients submitted to ICWT with a post-operative ABG 0-20 dB was significantly higher than patients submitted to CWDT ( $p = 0.02$ ) (Fig. 3). None of the other variables influenced post-operative ABG in regression analysis (Table I). Statistical analysis showed a significant improvement of the hearing in both groups ( $p < 0.001$ ) and no effect of the type of prosthesis on post-operative hearing results.

*Postoperative bone conduction change*

The average postoperative high frequency bone conduction change in all ossiculoplasty procedures was 3.1 dB HL (SD 7.8 dB HL). In 7 cases (10.4%), the average bone conduction threshold decreased by more than 10 dB HL, in 2 cases (2.9%) by more than 20 dB and in 58 cases (85.5%) remained stable or improved. No post-operative dead ears were encountered.

*Failures after the second stage operation*

At short-term follow-up, no cases of extrusion or anatomical failures were recorded.

## Discussion

Our results show that in patients affected by middle ear and mastoid cholesteatoma the use of homologous costal cartilage prosthesis is associated with a significant improvement of postoperative hearing and a low incidence of failures. Goode and Nishihara<sup>10</sup> reported that the “ideal” ossiculoplasty should have the following characteristics: (a) prostheses mass < 40 mg; (b) proper tension of the prostheses; (c) angle between TM and the stapes < 45°; (d) prostheses with a head angulated at about 30° to increase the surface area connected to the TM. As previously reported<sup>8</sup>, costal cartilage prostheses allows ossicular chain reconstruction procedures that fulfil all these requirements. T shaped cartilage prostheses, in fact, have a weight that does not exceed 40 mg and can be sculptured in the required shape and length with extreme ease according to the intra-operative findings. The angle with the stapes footplate or superstructure often approximate 0° when the head of the prostheses is placed under the TM, and the angle between the head and the shaft can be varied according to the intraoperative findings. Finally, the proper tension of the prostheses is obtained by trimming the shaft.

In this study, we have also evaluated the presence of prognostic factors in cartilage ossiculoplasty in a homogeneous population of patients affected by middle ear and mastoid cholesteatoma. Multiple linear regression showed that maintenance of the posterior canal wall was the only prognostic factor. Several authors have reported better hearing results in ICWT than in CWDT<sup>11-13</sup>, while others have reported similar results in both techniques when the ossicular chain was reconstructed<sup>14-16</sup>. Recently, Fayad et al.<sup>17</sup> showed that in the absence of the stapes superstructure the presence of a “cavity” was associated with poorer hearing results. In the present series, although most of the patients submitted to CWDT were affected by recurrent cholesteatoma, statistical analysis showed that the average hearing results in primary and revision surgery were not significantly different, and therefore the surgical technique was the only prognostic factor. The difference between ICWT and CWDT has been often ascribed to poorer eustachian tube function and greater severity of disease in cases requiring a CWD procedures<sup>17</sup>. We think that considering these reasons, the anatomy of a small middle ear cleft renders the prosthesis less effective, especially when the stapes superstructure is absent.

In the present series, the presence of the stapes superstructure did not influence post-operative hearing. The presence of the stapes superstructure has been proposed as a significant predictor by some authors<sup>18-20</sup>, while other authors did not find a significant correlation with hearing outcome<sup>21,22</sup>. In our experience, the presence of the stapes does not influence short- or long-term hearing results<sup>8</sup>. Although the presence of the malleus handle has been reported to be the most important determinant in ossicu-

loplasty success<sup>18 21-23</sup>, in the present series we could not evaluate this factor since the prosthesis we use is placed parallel to the malleus handle and not under the handle. In addition, all subjects were affected by cholesteatoma, and the handle was missing in most cases.

The rate of complications described in this series was very low. No cases of dead ear, probably due to the elasticity of the cartilage that rarely traumatises the inner ear, and no cases of extrusions were encountered. The extrusion rate of titanium prosthesis has been reported to be between 5% and 20%<sup>4,6</sup>. Chole<sup>24</sup>, in a series of 187 ossiculoplasties performed with cartilage prosthesis, reported no extrusions. We have previously reported no cases of extrusion at long-term (10 years) follow-up<sup>8</sup>. Unlike ossicles, that do not extrude, cartilage does not fix the scutum, the promontory, or the facial nerve with subsequent worsening of hearing<sup>25</sup>.

The safety of ossicular homografts has been questioned, especially concerning the transmission of acquired immunodeficiency syndrome and the Creutzfeld-Jakob Disease<sup>26</sup>. The cartilages we use are provided by a tissue bank approved by the Italian Ministry of Health that meet all the required regulations for infectious disease prevention.

## Conclusions

The present study proposes costal cartilage as the material of choice when autologous ossicles are not available. In terms of hearing improvement, the maintenance of the posterior canal wall was the only prognostic factor identified.

## References

- Zollner F. *The principles of plastic surgery of the sound conducting apparatus*. J Laryng 1955;69:637.
- Albera R, Canale A, Piumetto E, et al. *Ossicular chain lesions in cholesteatoma*. Acta Otorhinolaryngol Ital 2012;32:309-13.
- Attanasio G, Gaudio E, Mammola CL, et al. *Autograft ossiculoplasty in cholesteatoma surgery: a histological study*. Acta Otolaryngol 2014;134:1029-33.
- Quaranta N, Zizzi S, Quaranta A. *Hearing results using titanium ossicular replacement prosthesis in intact canal wall tympanoplasty for cholesteatoma*. Acta Otolaryngol 2011;131:36-40.
- Pringle MB, Sunkaraneni VS, Tann N. *Is cartilage interposition required for ossiculoplasty with titanium prostheses?* Otol Neurotol 2014;35:482-8.
- Yung M, Smith P. *Titanium versus nontitanium ossicular prostheses—a randomized controlled study of the medium-term outcome*. Otol Neurotol 2010;31:752-8.
- Yung M. *Cartilage tympanoplasty: literature review*. J Laryngol Otol 2008;122:663-72.
- Quaranta N, Fernandez-Vega Feijoo S, Piazza F, et al. *Closed tympanoplasty in cholesteatoma surgery: long-term (10 years) hearing results using cartilage ossiculoplasty*. Eur Arch Otorhinolaryngol 2001;258:20-4.

- <sup>9</sup> Committee on Hearing and Equilibrium. *Committee on Hearing and Equilibrium guidelines for the evaluation of results of treatment of conductive hearing loss*. Otolaryngol Head Neck Surg 1995;113:186-7.
- <sup>10</sup> Goode R, Nishihara S. *Experimental model of ossiculoplasty*. Otolaryngol Clin North Am 1994;27:663-75.
- <sup>11</sup> Tos M, Lau T. *Hearing after surgery for cholesteatoma using various techniques*. Auris Nasus Larynx. 1989;16:61-73.
- <sup>12</sup> Martin AD, Harner SG. *Ossicular reconstruction with titanium prosthesis*. Laryngoscope 2004;114:61-4.
- <sup>13</sup> Redaelli de Zinis LO. *Titanium versus hydroxyapatite ossiculoplasty in canal wall down mastoidectomy*. Arch Otolaryngol Head Neck Surg 2008;134:1283-7.
- <sup>14</sup> Quaranta A, Cassano P, Carbonara G. *Cholesteatoma surgery: open vs closed tympanoplasty*. Am J Otol 1988;9:229-31.
- <sup>15</sup> Iñiguez-Cuadra R, Alobid I, Borés-Domenech A, et al. *Type III tympanoplasty with titanium total ossicular replacement prosthesis: anatomic and functional results*. Otol Neurotol 2010;31:409-14.
- <sup>16</sup> Kim MB, Choi J, Lee JK, et al. *Hearing outcomes according to the types of mastoidectomy: a comparison between canal wall up and canal wall down mastoidectomy*. Clin Exp Otorhinolaryngol 2010;3:203-6.
- <sup>17</sup> Fayad JN, Ursick J, Brackmann DE, et al. *Total ossiculoplasty: short- and long-term results using a titanium prosthesis with footplate shoe*. Otol Neurotol 2014;35:108-13.
- <sup>18</sup> Mishiro Y, Sakagami M, Adachi O, et al. *Prognostic factors for short-term outcomes after ossiculoplasty using multivariate analysis with logistic regression*. Arch Otolaryngol Head Neck Surg 2009;135:738-41.
- <sup>19</sup> Mills RP. *The influence of pathological and technical variables on hearing results in ossiculoplasty*. Clin Otolaryngol Allied Sci 1993;18:202-5.
- <sup>20</sup> Wilson KF, London NR, Shelton C. *Tympanoplasty with intact canal wall mastoidectomy for cholesteatoma: long-term hearing outcomes*. Laryngoscope 2013;123:3168-71.
- <sup>21</sup> Albu S, Babighian G, Trabalzini F. *Prognostic factors in tympanoplasty*. Am J Otol 1998;19:136-40.
- <sup>22</sup> Dornhoffer JL, Gardner E. *Prognostic factors in ossiculoplasty: a statistical staging system*. Otol Neurotol 2001;22:299-304.
- <sup>23</sup> Bared A, Angeli SI. *Malleus handle: determinant of success in ossiculoplasty*. Am J Otolaryngol 2010;31:235-40.
- <sup>24</sup> Chole RA, Kim HJ. *Ossiculoplasty with presculpted banked cartilage. Operative Techniques*. Otolaryngol Head Neck Surg 1996;7:38-44.
- <sup>25</sup> Farrior JB, Nichols SW. *Long-term results using ossicular grafts*. Am J Otol 1996;17:386-92.
- <sup>26</sup> Glasscock ME, Jackson CG, Knox GW. *Can Acquired Immunodeficiency Syndrome and Creutzfeld-Jakob Disease be transmitted via otologic homografts?* Arch Otolaryngol Head Neck Surg 1988;114:1252-5.

Received: February 2, 2015 - Accepted: June 8, 2015

Address for correspondence: Nicola Quaranta, UOC Otorinolaringoiatria Universitaria, Azienda Ospedaliero-Universitaria Policlinico di Bari, piazza Giulio Cesare 11, 70124 Bari. Tel. +39 080 5478850. Fax +39 080 5478752. E-mail: nicolaantonioadolfo.quaranta@uniba.it

AUDIOLOGY

# Binaural squelch and head shadow effects in children with unilateral cochlear implants and contralateral hearing aids

## *Gli effetti squelch binaurale e ombra nei bambini con impianto cocleare monolaterale e protesi acustica controlaterale*

H. DINCER D'ALESSANDRO<sup>1</sup>, G. SENNAROĞLU<sup>2</sup>, E. YÜCEL<sup>2</sup>, E. BELGIN<sup>3</sup>, P. MANCINI<sup>1</sup>

<sup>1</sup> Department of Sensory Organs, Sapienza Università di Roma, Italy; <sup>2</sup> Department of Audiology and Speech Pathology, Hacettepe University, Ankara, Turkey; <sup>3</sup> Department of Audiology and Speech Pathology, Başkent University, Ankara, Turkey

### SUMMARY

The aim of this study was to investigate the amount of binaural squelch effect (BSE) and head shadow effect (HSE) in children who use unilateral cochlear implants (CI) and contralateral hearing aids (HA). The study group consisted of 19 CI recipient children who consistently wore a contralateral HA. Speech sounds were used to evaluate speech perception performance in noise. Testing was performed in three listening conditions: (1) bimodal listening with noise source on HA side; (2) CI only with noise source contralaterally (HA off); (3) CI only with noise source on the CI side. Statistical analysis revealed a significant difference between the three listening conditions and post hoc tests indicated significant differences for all pairwise comparisons ( $p < 0.001$ ). The average BSE and HSE were 11.8% and 17.1% respectively. The majority of bimodal CI users showed BSE and HSE with significant speech perception improvement in the presence of noise.

KEY WORDS: Cochlear implants • Children • Bimodal benefit • Binaural squelch effect • Head shadow effect

### RIASSUNTO

*Lo scopo di questo studio è stato quello di indagare il grado di effetto squelch binaurale (BSE) e di effetto ombra (HSE) nei bambini che fanno uso di impianto cocleare (CI) e protesi acustica controlaterale (HA). Sono stati arruolati 19 bambini con CI che indossavano regolarmente una HA. Per valutare la performance vocale in presenza di rumore è stato utilizzato un test di identificazione vocalica. Il test è stato eseguito in tre condizioni di ascolto: (1) ascolto bimodale con sorgente di rumore sul lato HA; (2) ascolto con CI con sorgente di rumore sul lato HA; (3) ascolto con CI con sorgente di rumore sul lato CI. I valori medi di BSE e di HSE osservati sono 11.8% e 17.1% rispettivamente. L'analisi statistica condotta ha evidenziato una differenza significativa sia nel confronto tra le tre condizioni di ascolto che per l'analisi post-hoc ( $p < 0.001$ ). In conclusione, la maggioranza dei bambini con CI hanno mostrato BSE ed HSE con un miglioramento significativo nella percezione vocale in presenza di rumore.*

PAROLE CHIAVE: *Impianto cocleare • Bambini • Beneficio bimodale • Effetto squelch • Effetto ombra*

Acta Otorhinolaryngol Ital 2015;35:343-349

## Introduction

It is well known that binaural hearing provides important benefits over monaural hearing, especially under challenging listening conditions<sup>1,2</sup>. Two basic effects that involve advantages for binaural hearing are binaural squelch effect (BSE) and head shadow effect (HSE). BSE refers to the capacity of the central auditory system to process the stimuli received from each ear and to reproduce it with a higher signal-to-noise ratio (SNR) by comparing interaural time and intensity differences. On the other hand, HSE results from the physical placement of the head which acts as an acoustic barrier and leads to an increase in SNR

in the ear far from the noise when signal and noise are spatially separate. Research in normal hearing subjects indicated a 3 dB improvement in BSE for the binaural speech recognition threshold and an average increase of 3 dB SNR for HSE which is more dominant for attenuation of high frequencies and can cause even 8 to 10 dB of improvement<sup>3</sup>.

One main advantage of binaural hearing is the improvement in speech perception in the presence of noise, which is a common downfall with cochlear implant (CI) recipients. Current CI technology offers good opportunities for formal and informal language acquisition in deaf children<sup>4,5</sup> as well as good speech understanding in quiet en-



vironments in postlingually deafened adults<sup>6</sup>, but it still remains insufficient to provide fine acoustic information especially in the low frequency (LF) domain that may contribute to better speech perception in noise<sup>7</sup>.

Over the past years, the trend in cochlear implantation has been the extension of indications to severe as opposed to uniquely profound hearing losses. On the other hand, cochlear implantation is still performed unilaterally in several countries due to economic reasons. Therefore, an increasing number of CI recipients wear a hearing aid (HA) to make use of LF residual hearing on the contralateral side. Hence, contralateral HA use offers an alternative to bilateral cochlear implantation in that unilateral CI recipients benefit from the LF cues provided through acoustic signals from contralateral HA in addition to electrical signals from the CI. This has been termed as “bimodal benefit”<sup>8</sup>.

Bimodal benefit in CI recipients has recently received much attention, and previous studies have shown its significant positive effect on speech recognition in noise and on functional performance in daily life as well as on the improvement of localisation and music perception skills<sup>3,9-11</sup>. However, these studies have been mostly carried out among adult users and there are relatively limited results in children<sup>12-14</sup> due to difficulties in testing young children under challenging listening conditions and obtaining robust outcomes: e.g. Beijen et al.<sup>13</sup> and Mok et al.<sup>15</sup> studied the bimodal benefit in children using a word recognition test in quiet and/or in noise, where both reflected significantly better outcomes under bimodal rather than CI alone listening conditions. However, in both studies the difficulty of the test task did not enable recruitment of children younger than 6 years.

On the other hand, some studies revealed findings for CI recipient adults showing, more specifically, BSE and HSE with significant improvement in speech perception in noise<sup>16-18</sup>. However, to our knowledge, so far there are only two studies that have investigated HSE in bimodal CI recipient children, with discordant outcomes. Ching et al.<sup>19</sup> indicated a significant HSE for sentence recognition in noise where speech and noise were presented separately at  $\pm 60^\circ$  azimuth, whereas Mok et al.<sup>15</sup> did not find any significant HSE for word recognition outcomes when noise was presented ipsilaterally to CI or from  $0^\circ$  azimuth. Similarly, specific outcomes for BSE in children were very limited. Ching et al.<sup>20</sup> reported limited access to binaural squelch due to the deficient capacity of current CI technology to represent timing information and limitations of CI users to make use of interaural time difference cues.

The aim of the present study was to investigate the amount of BSE and HSE in children who used unilateral CI and contralateral HA as well as study the potential predictors of outcomes such as unaided/aided audiological outcomes, duration of CI experience and duration of HA

experience prior to cochlear implantation. This study used the Auditory Speech Sounds Evaluation (A§E) test<sup>21</sup> that presented some speech sounds in the presence of noise in order to compare speech perception skills under bimodal and unilateral listening conditions.

## Materials and methods

### *Participants*

The study group consisted of 19 children (11 female and 8 male) with congenital, bilateral severe-to-profound sensorineural hearing loss. They did not have any additional disabilities. All had been full-time CI users (10-12 hrs/day) for at least 4 months (mean 20 months, range 4-51 months, SD 11.7) as well as being full-time contralateral HA wearers postoperatively and being consistent bilateral HA users preoperatively. Their ages varied from 3 to 14 years (mean age 9, SD 2.9). The mean age at implantation was 6.5 years (SD 3.1). The 12 children were implanted with an Advanced Bionics HiRes90K implant and fitted with HiRes-S sound coding strategy, whilst 6 children used Cochlear Freedom System fitted with ACE and 1 child the Med-El Combi40+ System fitted with CIS strategies. Demographic information for each subject including gender, age, aetiology of deafness, age at implantation, CI model, sound coding strategy, duration of CI experience, age at HA fitting and HA model is shown in Table I.

This study was approved by the local Ethics Committee and parents' consent was given freely.

### *Procedures*

CI maps for individual recipients were controlled prior to testing. Following a regular CI fitting session, their most comfortable levels were verified in live-speech when listening together with HA in order to avoid any discomfort due to a loudness summation effect. All children were asked to visit their HA providers shortly before their appointment in our centre, after which existing HA programs fitted by their providers were used during testing. Unaided contralateral hearing thresholds were measured via an Interacoustics AC40 audiometer and TDH39 headphones in a sound treated room at frequencies between 125-6000 Hz using a warble tone, as were aided thresholds in free field through a loudspeaker placed at  $0^\circ$  azimuth at 1 m distance from the subject. Unaided as well as aided hearing thresholds for individual subjects are given in Table I. BSE and HSE were evaluated using A§E software that was installed under NOAH onto a PC that was connected to an Aurical audiometer and 2 portable loudspeakers. The phonemes /a-i-u/, which were part of the A§E identification test onomatopoeia section, were selected as speech stimuli since they could offer a better reflection of the LF gain provided via the HA, whereas speech noise was presented as the noise stimulus. The details

**Table 1.** Demographic information and audiological outcomes in individual CI recipients.

P	Age	Gender	Aetiology	CI Ear	CI Age	CI Exp.	CI Model / Sound Coding Strategy	HA Fitting Age	HA Model	Speech Signal Intensity at AŞE Test (dB HL)	PTA (dB HL)		
											Unaided	HA	CI
1	5;6	F	Unknown	R	4;9	0;8	HiRes Bionic Ear / HiRes-S	0;8	Widex SENSO	60	98	57	25
2	9;7	M	Unknown	R	5;10	3;8	HiRes Bionic Ear / HiRes-S	2	Unitron US 80 PP	61	113	55	29
3	10;10	F	Connexin26	R	9;2	1;7	HiRes Bionic Ear / HiRes-S	1	Oticon 390PL	63	113	65	38
4	4;6	M	Unknown	R	2;10	1;7	HiRes Bionic Ear / HiRes-S	1;6	Starkey A675 SEQUEL	63	103	83	35
5	11;4	F	Unknown	L	9;7	1;8	HiRes Bionic Ear / HiRes-S	2;0	Eurion SWISS	63	120	82	40
6	14;1	F	Unknown	R	13;8	0;4	Freedom / ACE	0;8	Eurion SWISS	57	113	47	36
7	8;6	M	Unknown	R	5;7	2;10	Freedom / ACE	2;6	Phonak PPCL 4+	57	113	62	39
8	10;10	F	Unknown	R	9;5	1;4	Freedom / ACE	1;3	Widex SENSO	63	112	55	30
9	9;9	M	Connexin26	R	8;5	1;3	Freedom / ACE	1;6	Phonak SUPERO 412	65	107	42	25
10	5;9	F	Unknown	R	4;4	1;4	HiRes Bionic Ear / HiRes-S	2;6	Bernafon AF120	63	112	55	34
11	11;7	F	Unknown	R	10;2	1;4	HiRes Bionic Ear / HiRes-S	0;8	Starkey A675 SEQUEL	60	107	48	25
12	11;1	M	Unknown	R	6;9	4;3	COMBI40+ / CIS	2;6	Phonak PPCL 4+	58	100	62	29
13	8;6	M	Unknown	R	6;11	1;6	HiRes Bionic Ear / HiRes-S	0;11	Phonak PPCL 4+	72	112	65	31
14	6;6	F	Unknown	L	5	1;5	HiRes Bionic Ear / HiRes-S	1;6	Phonak PPCL 4+	60	110	62	26
15	6;10	F	Unknown	R	5;3	1;6	Freedom / ACE	0;4	Phonak PPCL 4+	60	110	62	34
16	5;10	M	Unknown	R	3;9	2	HiRes Bionic Ear / HiRes-S	1	Rionet HB-53P	68	105	53	31
17	4;3	M	Unknown	R	2;7	1;7	HiRes Bionic Ear / HiRes-S	0;8	Hansaton HP-AGC	65	105	62	33
18	10;2	F	Unknown	R	9;4	0;9	Freedom / ACE	0;11	Widex SENSO	56	115	57	25
19	3;10	F	Unknown	L	2;11	0;10	HiRes Bionic Ear / HiRes-S	2;9	Phonak SUPERO 412	70	115	55	33

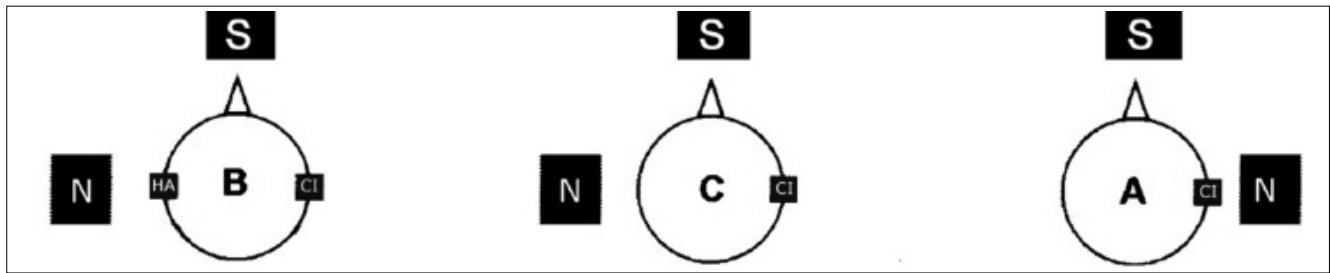
P: Participant; F: Female; M: Male; R: Right; L: Left; CI: Cochlear Implant; HA: Hearing Aid; Exp.: Experience; PTA: Pure Tone Average.

of the AŞE identification test are described by Govaerts et al.<sup>21</sup>.

AŞE was started in training mode in order to familiarise the child with the test and to minimise learning effects. Each child was explained her/his task regarding speech sound identification with a picture-pointing response. All phonemes and their corresponding pictures were introduced to the child one by one. Once the child was able to associate each phoneme with the corresponding picture under quiet listening conditions (phonemes administered at 75 dB and 70 dB HL respectively), test mode was initiated. During the test, each phoneme was administered four times in a random order by the software. Scoring was done by selecting the phoneme to which the child pointed. When the child was not able to respond due to being inattentive, the signal was repeated once again and if she/he was still unable to

identify the phoneme, it was scored as negative. The test was ended when all phonemes had been scored.

Testing was performed under three listening conditions (conditions B, C and A respectively as illustrated in Figure 1): in condition B, both CI and HA were switched on. Loudspeaker 1 where the speech signal was presented was located at 0° azimuth and Loudspeaker 2 which was assigned to the speech noise was positioned to the HA side ( $\pm 90^\circ$ ). Both loudspeakers were placed at 1 m distance from the subject's head; in condition C, HA was switched off and the test was repeated; in condition A, loudspeaker 2 was moved to the CI side ( $\pm 90^\circ$ ) and the test was repeated. The speech noise was administered at a fixed intensity of 65 dB SPL, whereas the speech signal was used at various intensities depending on the performance of the child to avoid ceiling and floor effects. The



**Fig. 1.** Illustration of the three listening conditions: (B) bimodal listening with noise source on HA side; (C) CI only listening with noise source on HA side; (A) CI only listening with noise source on CI side. S: Speech; N: Noise; CI: Cochlear Implant; HA: Hearing Aid.

initial speech signal was administered at 70 dB HL in condition B and if the child's score was  $\leq 58\%$ , the test was repeated by increasing signal intensity by 3 dB, whereas if the score was  $> 92\%$  the test was restarted by decreasing signal intensity by 5 dB. When the child scored between 59-92%, the test was carried out at the same speech signal intensity as conditions C and A, respectively.

*Data analysis*

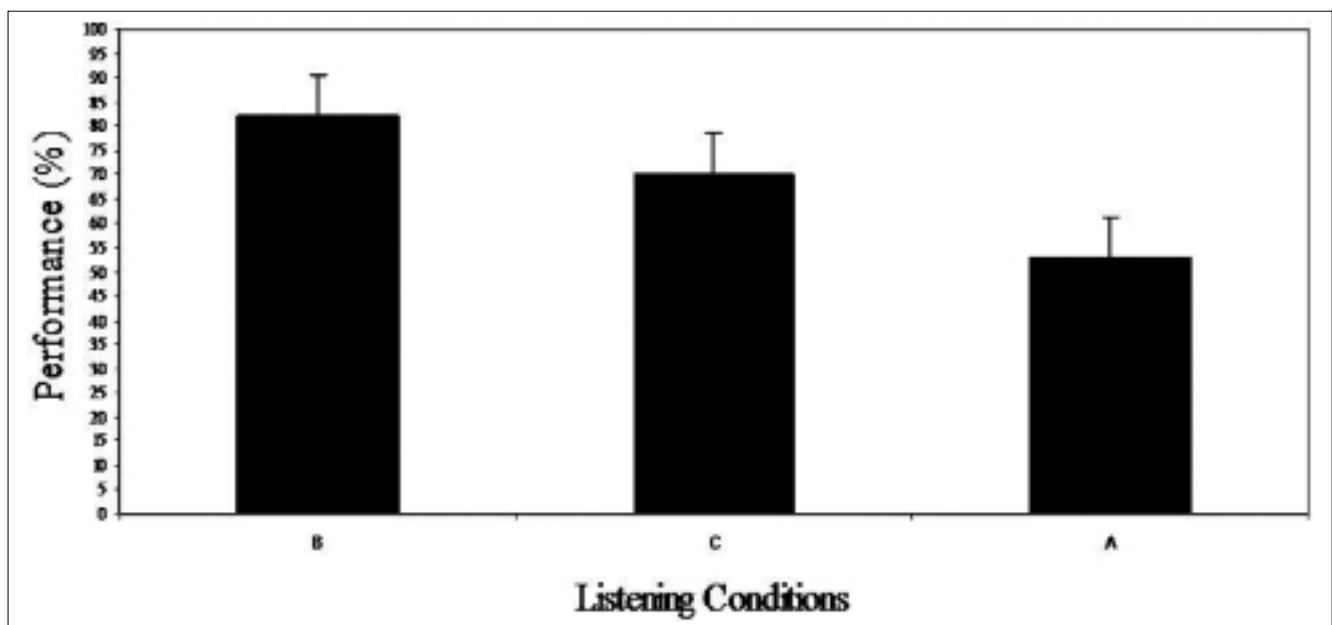
Statistical analysis was carried out using Statistical Package for Social Sciences (SPSS) version 19.0 (Chicago, IL, USA). The percentage of correct scores for speech perception outcomes in each listening condition (B, C and A) was calculated by dividing the number of correct responses by the maximum score (3 phonemes x 4 repetitions = 12). For each subject, BSE was calculated by subtracting the percentage of correct scores for condition C from that for condition B, and HSE was calculated by subtracting the percentage of correct scores for condition A from that for condition C. Differences between outcomes in listening

conditions were investigated by using repeated-measures analysis of variance, and post hoc tests were performed by using paired t-test procedures with Bonferroni correction for multiple comparison (comparison-wise alpha = 0.017). Pearson correlations were computed to investigate the correlations between the duration of CI experience, duration of HA experience prior to implantation, unaided/aided hearing thresholds, the intensity at which A&E speech signal was presented, listening conditions, BSE and HSE.

**Results**

The mean raw scores for listening conditions B, C and A, respectively, were 9.84 (range 8 to 11, SD 0.96), 8.42 (range 5 to 11, SD 1.92) and 6.37 (range 2 to 10, SD 2.06). Statistical analysis revealed a significant difference between the three conditions ( $p < 0.001$ ) and post hoc tests indicated significant differences for all pairwise comparisons ( $p < 0.001$ ).

Figure 2 shows the percentage of correct scores for all



**Fig. 2.** The average percentage of correct scores for each listening condition: (B) bimodal listening with noise source on HA side; (C) CI only listening with noise source on HA side; (A) CI only listening with noise source on CI side.

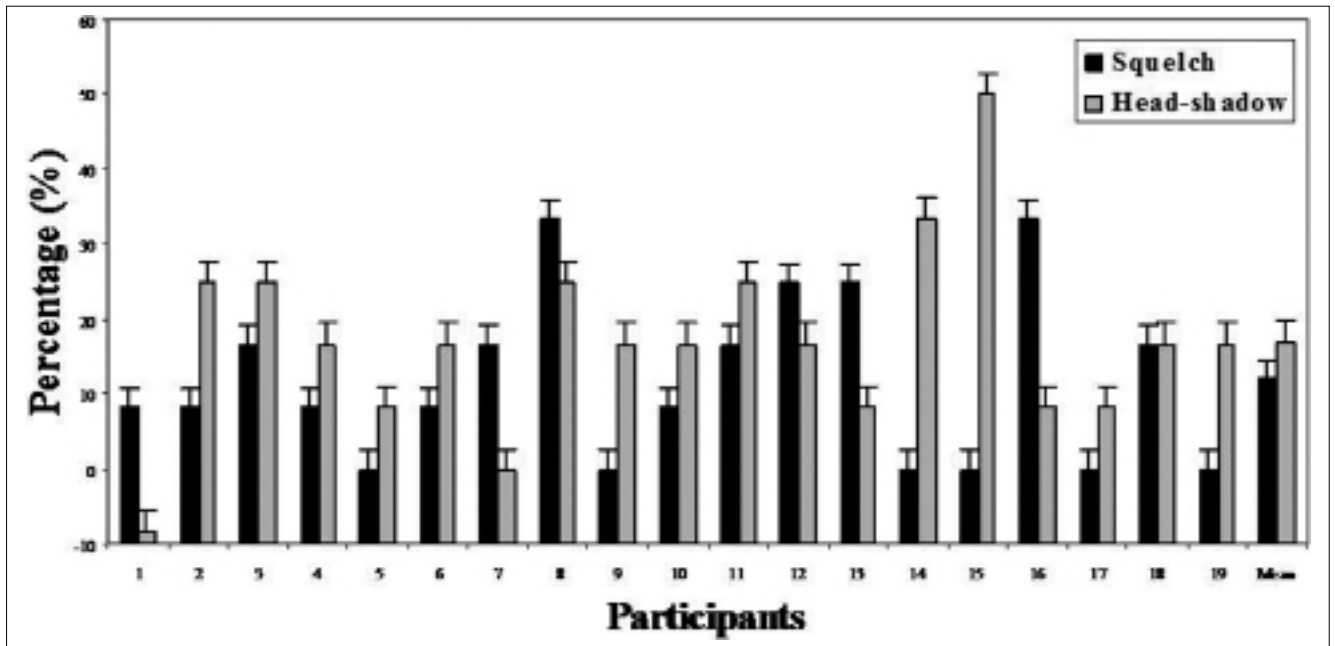


Fig. 3. Binaural squelch and head shadow effects for each subject and their average.

listening conditions. The average scores were 82% (range 67 to 92, SD 7.9), 70.2% (range 42 to 92, SD 16.0) and 53.1% (range 17 to 83, SD 17.2) for conditions B, C and A, respectively.

Figure 3 illustrates outcomes for BSE and HSE for individual subjects as well as their average. 13 of 19 children benefited for BSE, whereas 17 children showed performance improvement due to HSE. The average BSE and HSE were found to be 11.8% (range 0 to 33, SD 11.2) and 17.1% (range -8 to 50, SD 12.6), respectively. The largest performance difference was seen between B and A listening conditions: 29% in average.

The audiological outcomes such as unaided pure tone average, aided free field audiometry and speech presentation intensity in relation to 65 dB SPL noise level are shown in Table I. The correlations between the duration of CI experience, duration of HA experience prior to implantation, unaided pure tone average, aided free field audiometry, the speech signal intensity, the three listening conditions, BSE and HSE were not statistically significant ( $p > 0.05$ ).

## Discussion

The present study investigated bimodal benefits in CI recipient children. Outcomes suggested that children who use cochlear implants and contralateral hearing aids had considerable bimodal benefit and therefore, their speech perception performance in the presence of noise improved. All children showed at least one binaural advantage, although the amount of benefit reflected inter-subject variability: 13 of 19 children benefited from BSE, whereas 17 children showed improvement in performance due to

HSE. BSE findings in the majority of children pointed out that they were able to integrate poor representation of CI with better timing information of HA and to make use of interaural time difference cues. On the other hand, HSE findings were in line with Ching et al.<sup>19</sup> and not Mok et al.<sup>15</sup> who did not find any significant HSE. These discrepancies can be due to the small CI sample size of these studies or due to different study settings such as positioning of speech and noise sources. Mok et al.<sup>15</sup> positioned the noise source at 0° azimuth, whereas in our study it was placed contralaterally at  $\pm 90^\circ$  azimuth. HSE previously was shown to be largest when the noise source was at 90° azimuth to the opposite side<sup>22</sup>. Furthermore, the largest difference in performance was seen between B and A listening conditions, which indicated CI only listening with the noise source on CI side as the most difficult condition. Previous studies had discrepancies for correlations between bimodal benefit and audiological outcomes such as unaided pure tone average and aided free field audiometry as well as the duration of CI experience and the duration of HA experience prior to cochlear implantation. There were studies showing the positive effect of degree of LF residual hearing<sup>3</sup> or longer duration of HA experience prior to implantation<sup>23</sup> on bimodal benefit. Some studies even found an adverse effect of better hearing thresholds at mid-to-high frequencies<sup>8,15</sup>. However, our results were in line with the majority of previous outcomes<sup>13,19</sup> and did not reveal any significant correlations between these variables. Such findings are promising for unilateral CI recipients with profound hearing loss and with no LF residual hearing especially in countries where bilateral implantation is still not reimbursed. On the other hand, in countries without any

financial restrictions, the decision depends more on evaluation of the amount of benefit that a second CI or a contralateral HA can provide for individual subjects by taking into consideration better time-based cues that HA can convey to an ear with LF residual hearing in comparison to CI<sup>24,25</sup>. Therefore, there is an increasing need for audiological tests that are clinically applicable to young children and that can be used in the decisional process between bimodal versus bilateral CI use, which is more effective when implantation is done simultaneously or with the shortest possible time interval sequentially<sup>26</sup>. For this purpose, a test based on the identification task, which is a closed set condition, in our opinion is useful for testing young, even preverbal children older than 2.5 years of age<sup>27</sup>, and the use of phonemes instead of words is less influenced by cognitive bias<sup>21</sup>. Moreover, our selection of test phonemes has the advantage of being less time consuming when considering the limited duration of attention in children, and these phonemes are identified at earlier stages in young children<sup>27</sup>. However, the limitation of the present study was mainly the small sample size. The outcomes based on this test in larger CI populations could provide better insight into the amount of bimodal benefit as well as the effect of CI and HA fitting parameters in young children. Additionally, the test procedure could be improved by introducing optimisation strategies in bimodal fitting. Bimodal fitting optimisation is still not a common clinical practice in many CI centres, and some CI users continue to receive independent fitting service from their HA providers. Previously, Ching et al.<sup>11</sup> have described a fitting procedure to adjust CI and HA together in adults, whilst Mok et al.<sup>15</sup> performed loudness balancing in children older than 9 years. Optimising bimodal fitting can be more challenging and may need special attention in young children, especially for loudness-balancing between the two devices taking into consideration that children have difficulties in judging loudness levels. However, as a minimum principle in order to optimise performance, real-ear measurements should be used to verify the achievement of prescriptive targets, the HA frequency response should be maximised for speech understanding, the HA should amplify sounds to comfortable loudness for low, medium and high input levels and loudness summation effects should be compensated for both acoustic and electric stimulation<sup>3,19</sup>. Background noise is inevitable in real life environments such as streets, parks, kindergartens, schools and classrooms where children spend considerable time. Therefore, bimodal listening may help children's incidental learning, conversational skills and academic success by increasing the SNR and conveying better target speech cues. Moreover, it may help to prevent contralateral auditory deprivation that can be induced by the absence of auditory stimulation<sup>26</sup>. Therefore, contralateral HA use is recommended as a clinical standard whenever bilateral implantation is not possible. Our clinical experience showed that if children are asked to continue to wear their HA right after sur-

gery, they spontaneously adapt to electrical and acoustical stimulation and willingly accept regular HA use on the opposite side. However, parents' attitude plays a crucial role as well. Therefore, parents certainly need to be counselled about the advantages of bimodal use to consent to their child wearing two devices instead of only one.

## Conclusions

Present findings revealed that unilateral CI recipient children who used contralateral hearing aids showed considerable bimodal benefit, especially for the aspects taken into consideration by this study. Therefore, their speech perception performance in the presence of noise improved. At least one binaural advantage was present for all children and the amount of benefit reflected inter-subject variability. Audiological outcomes such as unaided pure tone average and aided free field audiometry as well as the duration of CI experience and the duration of HA experience prior to cochlear implantation did not have a significant effect on BSE and HSE.

## References

- 1 Cherry EC. *Some experiments upon the recognition of speech, with one and with two ears.* J Acoust Soc Am 1953;25:975-9.
- 2 Byrne D. *Clinical issues and options in binaural hearing aid fitting.* Ear Hear 1981;2:187-93.
- 3 Firszt JB, Reeder RM, Skinner MW. *Restoring hearing symmetry with two cochlear implants or one cochlear implant and a contralateral hearing aid.* J Rehabil Res Dev 2008;45:749-68.
- 4 Lederberg AR, Schick B, Spencer PE. *Language and literacy development of deaf and hard-of-hearing children: successes and challenges.* Dev Psychol 2013;49:15-30.
- 5 Nicastrì M, Filipo R, Ruoppolo G, et al. *Inferences and metaphoric comprehension in unilaterally implanted children with adequate formal oral language performance.* Int J Pediatr Otorhinolaryngol 2014;78:821-7.
- 6 Park E, Shipp DB, JM Chen, et al. *Postlingually deaf adults of all ages derive equal benefits from unilateral multichannel cochlear implant.* J Am Acad Audiol 2011;22:637-43.
- 7 Moore BJC. *The role of temporal fine structure processing in pitch perception, masking and speech perception for normal-hearing and hearing-impaired people.* J Assoc Res Otolaryngol 2008;9:399-406.
- 8 Mok M, Grayden D, Dowell RC, et al. *Speech perception for adults who use hearing aids in conjunction with cochlear implants in opposite ears.* J Speech Lang Hear Res 2006;49:338-51.
- 9 Dorman MF, Gifford RH, Spahr AJ et al. *The benefits of combining acoustic and electric stimulation for the recognition of speech, voice and melodies.* Audiol Neurootol 2008;13:105-12.
- 10 Van Hoesel RJM. *Contrasting benefits from cochlear implants and hearing aids in cochlear implant users.* Hear Res 2012;288:100-13.
- 11 Ching TYC, Incerti P, Hill M. *Binaural benefits for adults*

- who use hearing aids and cochlear implants in opposite ears. *Ear Hear* 2004;25:9-21.
- 12 Looi V, Radford CJ. *A comparison of the speech recognition and pitch ranking abilities of children using a unilateral cochlear implant, bimodal stimulation or bilateral hearing aids.* *Int J Pediatr Otorhinolaryngol* 2011;75:472-82.
  - 13 Beijen JW, Mylanus EAM, Leeuw AR et al. *Should a hearing aid in the contralateral ear be recommended for children with a unilateral cochlear implant?* *Ann Otol Rhinol Laryngol* 2008;117:397-403.
  - 14 Hegarty L, Faulkner A. *The perception of stress and intonation in children with a cochlear implant and a hearing aid.* *Cochlear Implants Int* 2013;14:S35-39.
  - 15 Mok M, Galvin KL, Dowell RC, et al. *Speech perception benefit for children with a cochlear implant and a hearing aid in opposite ears and children with bilateral cochlear implants.* *Audiol Neurotol* 2010;15:44-56.
  - 16 Dunn CC, Tyler RS, Witt SA. *Benefit of wearing a hearing aid on the unimplanted ear in adult users of a cochlear implant.* *J Speech Lang Hear Res* 2005;48:668-80.
  - 17 Morera C, Cavalle L, Manrique M, et al. *Contralateral hearing aid use in cochlear implanted patients: multicenter study of bimodal benefit.* *Acta Otolaryngol* 2012;132:1084-94.
  - 18 Kokkinakis K, Pak N. *Binaural advantages in users of bimodal and bilateral cochlear implant devices.* *J Acoust Soc Am* 2014;135:EL47-53.
  - 19 Ching TYC, Incerti P, Hill M, van Wanrooy E. *An overview of binaural advantage for children and adults who use binaural/bimodal hearing devices.* *Audiol Neurotol* 2006;11:6-11.
  - 20 Ching TYC, van Wanrooy E, Hill M, et al. *Binaural redundancy and inter-aural time difference cues for patients wearing a cochlear implant and a hearing aid in opposite ears.* *Intern J Audiol* 2005;44:677-90.
  - 21 Govaerts PJ, Daemers K, Yperman M, et al. *Auditory Speech Sounds Evaluation (ASSE®): a new test to assess detection, discrimination and identification in hearing impairment.* *Cochlear Implants Int* 2006;7:92-106.
  - 22 MacKeith NW, Coles RRA. *Binaural advantages in hearing of speech.* *J Laryngol Otol* 1971;85:213-32.
  - 23 Skubisz KC. *Responses to short-term auditory stimulation through contralateral hearing aid use in pediatric cochlear implant users (dissertation).* Virginia (US): James Madison Univ.; 2006.
  - 24 Schauwers K, Coene M, Heeren W, et al. *Perception of pitch changes in hearing impaired adults with aided and unaided hearing loss.* *J Hear Sci* 2012;2:OA25-34.
  - 25 Dincer D'Alessandro H, Filippo R, Ballantyne D, et al. *Low frequency pitch perception in children with cochlear implants in comparison to normal hearing peers.* *Eur Arch Otorhinolaryngol* 2015;272:3115-22.
  - 26 Sharma A, Dorman MF, Kral A. *The influence of a sensitive period on central auditory development in children with unilateral and bilateral cochlear implants.* *Hear Res* 2005;203:134-43.
  - 27 Daemers K, Yperman M, De Beukelaer C, et al. *Normative data of the ASSE® discrimination and identification tests in preverbal children.* *Cochlear Implants Int* 2006;7:107-116.

Received: November 11, 2014 - Accepted: June 18, 2015

CLINICAL TECHNIQUES AND TECHNOLOGY

# 3D computed tomographic evaluation of the upper airway space of patients undergoing mandibular distraction osteogenesis for micrognathia

## *Valutazione mediante tomografia assiale computerizzata 3D delle vie aeree superiori di pazienti sottoposti a distrazione osteogenetica mandibolare per micrognazia*

A. BIANCHI, E. BETTI, G. BADIALI, F. RICOTTA, C. MARCHETTI, A. TARSITANO

Maxillofacial Surgery Unit, Policlinico "S. Orsola-Malpighi", University of Bologna, Italy

### SUMMARY

Mandibular distraction osteogenesis (MDO) is currently an accepted method of treatment for patients requiring reconstruction of hypoplastic mandibles. To date one of the unsolved problems is how to assess the quantitative increase of mandible length needed to achieve a significant change in the volume of the posterior airway space (PAS) in children with mandibular micrognathia following distraction osteogenesis. The purpose of this study is to present quantitative volumetric evaluation of PAS in young patients having distraction osteogenesis for micrognathia using 3D-CT data sets and compare it with pre-operative situation. In this observational retrospective study, we report our experience in five consecutive patients who underwent MDO in an attempt to relieve severe upper airway obstruction. Each patient was evaluated before treatment (T0) and at the end of distraction procedure (T1) with computer tomography (CT) in axial, coronal, and sagittal planes and three-dimensional CT of the facial bones and upper airway. Using parameters to extract only data within anatomic constraints, a digital set of the edited upper airway volume was obtained. The volume determination was used for volumetric qualification of upper airway. The computed tomographic digital data were used to evaluate the upper airway volumes both pre-distraction and post-distraction. The mean length of distraction was 23 mm. Quantitative assessment of upper airway volume before and after distraction demonstrated increased volumes ranging from 84% to 3,087% with a mean of 536%. In conclusion, our study seems to show that DO can significantly increase the volume of the PAS in patients with upper airway obstruction following micrognathia, by an average of 5 times. Furthermore, the worse is the starting volume, the greater the increase in PAS to equal distraction.

KEY WORDS: 3D Computed tomographic evaluation • PAS • Mandibular distraction osteogenesis • Micrognathia

### RIASSUNTO

*La distrazione osteogenetica mandibolare rappresenta oggi un metodo di trattamento consolidato per i pazienti affetti da ipoplasia mandibolare. Ad oggi, un problema insoluto, nei bambini affetti da micrognazia, è la modalità di valutazione del guadagno di lunghezza mandibolare necessario ad ottenere un miglioramento significativo a livello del volume dello spazio aereo posteriore (PAS). La proposta di questo studio è la valutazione volumetrica quantitativa del PAS in giovani pazienti sottoposti a distrazione osteogenetica mandibolare per severa micrognazia, attraverso l'analisi di 'data-set' di TC pre-trattamento in comparazione ai medesimi dati post-trattamento. In questo studio retrospettivo osservazionale riportiamo la nostra esperienza relativa a cinque pazienti sottoposti a distrazione osteogenetica mandibolare. Per ciascuno dei pazienti in esame, è stata valutata la TC pre-trattamento (T0) ed al termine del trattamento (T1) nei piani assiale, coronale, sagittale e 3D a livello del PAS. Utilizzando parametri di estrazione dei dati anatomici, è stato ottenuto un modello di analisi dello spazio aereo posteriore, utilizzato per comparare le differenze volumetriche quantitative a T0 e T1. La lunghezza media di distrazione ottenuta è stata di 23 mm. L'analisi volumetrica quantitativa del PAS ha mostrato un incremento di volume, al termine del trattamento, variabile dal 84% sino 3,087% (media 536%) rispetto alla situazione pre-trattamento. Concludendo, il presente studio sembra confermare che la distrazione osteogenetica incrementa in maniera significativa il volume del PAS in pazienti con ostruzione delle vie aeree dovuta alla micrognazia. La quantificazione di tale incremento appare lineare con il guadagno ottenuto grazie alla distrazione. Nella suddetta popolazione di studio, tale guadagno è stato, in media, di 5 volte rispetto al volume di partenza. Il dato da sottolineare è che tanto minore è il volume del PAS al T0, tanto maggiore risulta il guadagno volumetrico al T1.*

PAROLE CHIAVE: Tomografia computerizzata 3D • PAS • Distrazione osteogenetica mandibolare • Micrognazia

Acta Otorhinolaryngol Ital 2015;35:350-354

### Introduction

Upper airway obstruction occurs most commonly in individuals with craniofacial anomalies associated with

micrognathia such as Pierre Robin syndrome, hemifacial microsomia, Treacher Collins and Nager syndromes<sup>1</sup>. In these disorders, the reduced size of mandible and its

retruded position cause retro-displacement of the tongue and concomitant reduction of the oropharyngeal airway that may lead to upper airway obstruction.

Patients have symptoms of obstructive sleep apnoea (OSA) that in severe cases require tracheal intubation and tracheostomy<sup>2</sup>. More than 60% of children with craniofacial abnormalities require airway intervention as part of their overall treatment<sup>2</sup>.

Tracheostomy is traditionally the safest and most effective treatment option in patients with micrognathia in Pierre Robin sequence and severe upper airway obstruction and is performed in as many as 12% of cases<sup>2</sup>. Tracheostomy, however, is associated with high cost, frequent morbidity, and occasional mortality, with an average age of 3.1 years at decannulation<sup>2</sup>. Therefore, the development of other effective methods of airway management is desirable.

Mandibular distraction osteogenesis (MDO) has become an accepted method of treatment for patients requiring reconstruction of hypoplastic mandibles and may achieve mandibular lengthening without need for bone graft<sup>2</sup>. During the past few years mandibular reconstruction by distraction osteogenesis has been demonstrated to be effective in resolving upper airway obstruction and need for tracheostomy decannulation. Mandibular distraction has also been used in respiratory-distressed neonates and infants to avoid tracheostomy<sup>2</sup>.

To date one of the unsolved problems is how to assess the quantitative increase of mandible length needed to achieve a significant change in the volume of posterior airway space (PAS) in children with mandibular micrognathia following distraction osteogenesis.

The purpose of this study is to present the quantitative volumetric evaluation of PAS in young patients having distraction osteogenesis for micrognathia using 3D-CT data sets and compared it with pre-operative situation.

### Description of clinical techniques and technology

In this observational retrospective study, we report our experience in five consecutive patients (1 with Treacher Collins syndrome, 1 with Nager syndrome, 2 with bilateral hemifacial mycosomia and 1 with severe micrognathia)

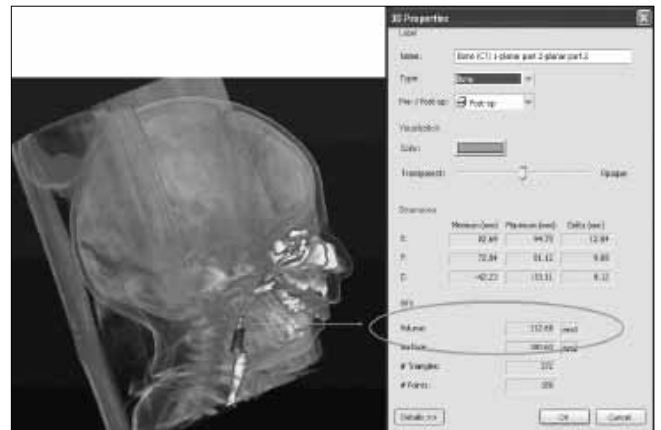

Fig. 1. Anatomic limits of upper airway in sagittal and 3D reconstructed CT scans.

who underwent mandibular DO in an attempt to relieve severe upper airway obstruction between March 2008 and May 2011 at the Maxillofacial Surgery Unit of “S. Orsola-Malpighi” University Hospital of Bologna, Italy.

Inclusion criteria were the presence of syndromic or non-syndromic mandibular hypoplasia and respiratory distress with episodes of severe desaturation (oxygen saturation below 70%).

Exclusion criteria included central apnoea, apnoea that was dependent on other levels of airway impairment, such as laryngomalacia/tracheomalacia, and previous surgical procedures.

Mandibular distraction was planned bilaterally in order to advance the mandible and to increase upper airway volume. Unidirectional extra-oral (n = 4) and intra-oral (n = 1) distraction devices were used.

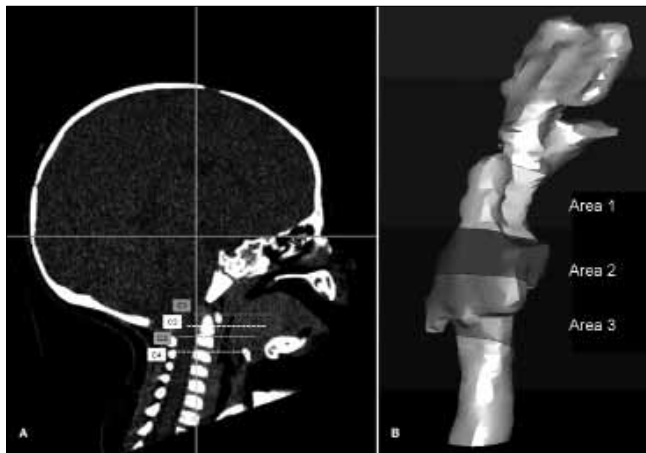
Each patient was evaluated before treatment (T0) and three months after the end of the distraction procedure (T1) with computed tomography (CT) in axial, coronal and sagittal planes and three-dimensional CT of the facial bones and upper airway.

Regarding CT scans, each child received the same protocol for three-dimensional CT of whole head, with 1 mm continuous axial slices, parallel to the Frankfurt horizontal<sup>3</sup>. The CT data were converted into DICOM (Digital Imaging and Communication in Medicine) format, after which the images were reconstructed for a 3D-model with

Table 1. Reference points and planes.

Area	Definition	Explanation
<b>AREA 1</b> (the area between the CV <sub>1</sub> and CV <sub>2</sub> planes)	CV <sub>1</sub>	Horizontal plane passing for the most anterior point of the anterior arch of the atlas
<b>AREA 2</b> (The area between the CV <sub>2</sub> and CV <sub>3</sub> planes)	CV <sub>2</sub>	Horizontal plane passing for the most anterior inferior point of the body of the 2 <sup>nd</sup> cervical vertebra
<b>AREA 3</b> (The area between the CV <sub>3</sub> and CV <sub>4</sub> planes)	CV <sub>3</sub>	Horizontal plane passing for the most anterior inferior point of the body of the 3 <sup>rd</sup> cervical vertebra
	CV <sub>4</sub>	Horizontal plane passing for the most anterior inferior point of the body of the 4 <sup>th</sup> cervical vertebra



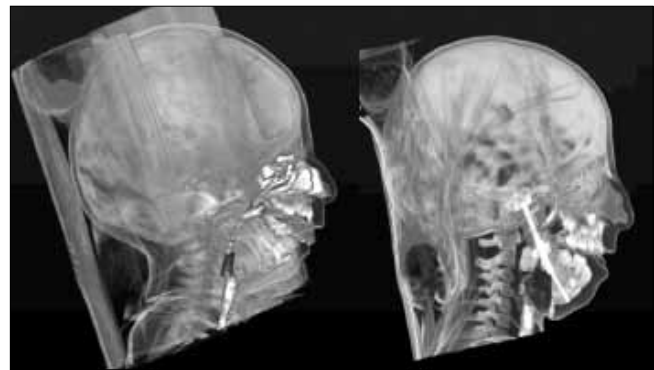

**Fig. 2.** 3D reconstructed CT scan volumetric assessment of the upper airway.

Simplant O&O (Materialise Dental, Leuven, Belgium). The automatically fixed threshold value was manually increased for each dataset until the nasopharyngeal airway was adequately depicted. The maximum value established as the reference threshold for this study of all patients thus defined was -306 and the minimum value was -1024.

Preparatory to upper airway analysis, the relevant reference planes and points were determined.

The upper airway was divided into three regions relative to the reference planes: area 1 (between the CV<sub>1</sub> and CV<sub>2</sub> plane); area 2 (between the CV<sub>2</sub> plane and CV<sub>3</sub> plane); area 3 (between the CV<sub>3</sub> and the CV<sub>4</sub> plane) (Fig. 1a, b; Table I) Using parameters to extract only the data within anatomic constraints, a digital set of the edited upper airway volume was obtained (Fig. 2). The volume determination was used for volumetric qualification of the upper airway. The digital CT data were used to evaluate upper airway volumes both pre-distraction and post-distraction (Fig. 3).



**Fig. 3.** 3D reconstructed CT scan showing pre-treatment airway volume (left side) and post-treatment increased volume (right side).

The present study is retrospective in nature. The study was conducted in accordance with the tenets of the WMA Declaration of Helsinki in the context of Ethical Principles for Medical Research Involving Human Subjects and was granted exemption by the local IRB of our Institution.

## Results

Five infants (1 boy and 4 girls) with micrognathia, glossoptosis and severe upper airway obstruction underwent bilateral mandibular DO. The mean length of distraction was 23 mm (range, 13-35 mm) (Table II). Information on patient age, type of DO performed and the exact length of distraction for each patient is detailed in Table II.

The lateral, axial, coronal and 3D CT at the end of distraction revealed forward lengthening of the mandible and hyoid bone as exemplified in Figure 3 for all patients. These resulted in forward traction of the tongue and increased

**Table II.** Clinical and volumetric data.

Patient	Age	Length of DO	Vector of DO	Pre-DO upper airway volume (mm <sup>3</sup> )	Post-DO upper airway volume (mm <sup>3</sup> )	Δ Volume (mm <sup>3</sup> )	Δ Volume (%)
#1	3	20 mm	oblique	A1: 113	A1: 1500	A1: +1387	A1: +1227%
				A2: 330	A2: 2194	A2: +1864	A2: +564%
				A3: 546	A3: 2017	A3: +1471	A3: +269%
#2	4	35 mm	oblique	A1: 0	A1: 3528	A1: +3528	A1: +352%
				A2: 148	A2: 4717	A2: +4569	A2: +3087%
				A3: 251	A3: 2527	A3: +2276	A3: +906%
#3	6	22 mm	oblique	A1: 811	A1: 3500	A1: +2689	A1: +331%
				A2: 635	A2: 1695	A2: +1060	A2: +166%
				A3: 351	A3: 1781	A3: +1430	A3: +407%
#4	5	13 mm	oblique	A1: 3106	A1: 7405	A1: +4299	A1: +138%
				A2: 2700	A2: 5582	A2: +2882	A2: +106%
				A3: 2670	A3: 7023	A3: +4350	A3: +162%
#5	5	25 mm	horizontal	A1: 3808	A1: 7035	A1: +3227	A1: +84%
				A2: 1485	A2: 3116	A2: +1631	A2: +109%
				A3: 2425	A3: 6098	A3: +3673	A3: +151%

Legend: A1: area 1; A2: area 2; A3: area 3.

pharyngeal space. 3D-CT demonstrated improved airway in all patients. The three-dimensional digital image demonstrated the increased airway in all areas (Table I). Area 1 volume increased between 1.387 mm<sup>3</sup> (pt. #1) and 4.299 mm<sup>3</sup> (pt. #3). Area 2 volume increased between 1.060 mm<sup>3</sup> (pt. #3) and 4.569 mm<sup>3</sup> (pt. #2). Area 3 volume increased between 1.430 mm<sup>3</sup> (pt. #3) and 4.350 mm<sup>3</sup> (pt. #4). The mean increased volume for all areas was 3.379 mm<sup>3</sup> (Table II).

Quantitative assessment of the upper airway volume before and after distraction demonstrated increased volume ranging from 84% to 3,087% with a mean of 536%. All variations in terms of volumetric upper airway changes between pre and post-DO situation are detailed in Table II.

Qualitative increase of upper airway volume was assessed considering the decannulation rate at the end of the DO procedure in patients undergoing tracheostomy. In fact, all patients subjected to tracheostomy before DO underwent decannulation after the end of the described procedure. This confirms the efficacy of DO in terms of airway volume increase in patients with severe micrognathia.

During the 24-36 months of follow-up none of the patients developed symptoms of OSA and none needed CPAP treatment.

## Discussion

Micrognathia is characterised by a small and retrusive mandible. Children with craniofacial anomalies associated with micrognathia, retruded position of the mandible and glossoptosis often have compromised upper airways, a condition with potential for morbidity and mortality. The degree of respiratory difficulty is dependent on the severity of the micrognathia and glossoptosis. These patients usually fail to thrive, present feeding problems, have insufficient weight gain associated with malnutrition, higher pulmonary morbidity and long-term hospitalisation<sup>1</sup>. There are a variety of options available for airway management in the micrognathic child. Certainly, it is reasonable to begin with the most conservative measures. This includes prone positioning and placement of a nasal pharyngeal airway. The use of positive pressure mask ventilation through the nasal pharyngeal airway will provide some additional benefit. Other options include glossopexy procedures, or subperiosteal release of the floor of the mouth combined with glossopexy. For the most severe cases, tracheotomy is traditionally considered to be the definitive technique in securing a stable airway for these children<sup>2</sup>. Long-standing tracheostomies are associated with high morbidity such as tracheomalacia, chronic bronchitis, laryngeal stenosis and risk of death due to the mucus plug or dislodgement of tracheostomy

tube. Patients who undergo tracheostomy require complex nursing care.

The method of DO should have a substantial advantage over all of the above mentioned techniques. It enables gradual forward advancement of the mandible and tongue that increase the pharyngeal space. The apnoea index and O<sub>2</sub> saturation should be markedly improved following distraction.

Most studies report improved airway and respiratory status in patients after DO based on polysomnography, cephalometry, decannulation rates and imaging studies. It is known from the literature that posterior airway volume can be accurately measured three-dimensionally using CT<sup>4,6</sup>. Nevertheless, few studies have measured the extent of the increase in volume of PAS as a result of DO and no study has related the extent of distraction with the increase in volume itself. Herein, we present our quantitative assessment of increase in volume of PAS using a three-dimensional method based on CT. Our results show that the increase in volume can be much more extensive than previously assessed by other studies with similar quantities of distraction. An average increase of 536% (ranging from 84 to 3,087%) is a surprisingly positive result which gives, according to the authors, a much more important value to DO in the treatment of upper airway obstruction in mandibular micrognathia. Positive discordance with previous studies could be further investigated and can be attributed to slight differences in the evaluation method, but our analysis appears to be robust and reliable.

Furthermore, there seems to be no relation between the entity of distraction and the increase in volume. In fact, the greatest distraction (35 mm) caused the best increase in PAS (356-3087%), but the other results show no proportion with the quantity of DO. Obviously, this is only an underlying trend, because five cases are too few to evaluate a statistically significant result. Nevertheless, the slight inverse proportion between the pre-operative volume and the volume increase should be noted. This, according to our previous results in adult OSAS patients<sup>5</sup>, seems to demonstrate that those with greater preoperative PAS volumes can obtain lower increase in volume, independently of the entity of DO, while patients with smaller preoperative PAS volume can obtain a greater increase in volume, also independently from the entity of DO. This could mean that the possibility to augment the PAS volume varies according to the starting volume in a non-linear manner.

In conclusion, our study seems to show that DO can significantly increase the volume of the PAS in patients with upper airway obstruction following micrognathia, by an average of 5 times; the worse the starting volume, the greater the increase in PAS to equal distraction.

## References

- <sup>1</sup> Cosman B, Crikelair GF. *Mandibular hypoplasia and the late development of glossopharyngeal airway obstruction*. *Plast Reconstr Surg* 1972;50:573-9.
- <sup>2</sup> Perkins JA, Sie KC, Milczuk H, et al. *Airway management in children with craniofacial anomalies*. *Cleft Palate Craniofac J* 1997;34:135-40.
- <sup>3</sup> Knapp RH, Vannier MW, Marsh JL. *Generation of three dimensional images from CT scans: technological perspective*. *Radiol Technol* 1985;56:391-8.
- <sup>4</sup> Bianchi A, Betti E, Tarsitano A, et al. *Volumetric three-dimensional computed tomographic evaluation of the upper airway in patients with obstructive sleep apnoea syndrome treated by maxillomandibular advancement*. *Br J Oral Maxillofac Surg* 2014;52:831-7.
- <sup>5</sup> Tarsitano A, Marchetti C. *Unusual presentation of obstructive sleep apnoea syndrome due to a giant mandible osteoma: case report and literature review*. *Acta Otorhinolaryngol Ital* 2013;33:63-6.
- <sup>6</sup> Saccomanno S, Greco F, D'Alatri L, et al. *Role of 3D-CT for orthodontic and ENT evaluation in Goldenhar syndrome*. *Acta Otorhinolaryngol Ital* 2014;34:283-7.

Received: December 24, 2014 - Accepted: March 8, 2015

Address for correspondence: Achille Tarsitano, Maxillofacial Surgery Unit, "S. Orsola" University Hospital, via G. Massarenti 9, 40100 Bologna, Italy. Tel. +39 051 6364197. E-mail: achille.tarsitano2@unibo.it

CASE SERIES AND REPORTS

# Ossifying fibromas of the paranasal sinuses: diagnosis and management

## *Fibroma ossificante dei seni paranasali: diagnosi e management*

M. CINIGLIO APPIANI<sup>1</sup>, B. VERILLAUD<sup>2</sup>, D. BRESSON<sup>3</sup>, E. SAUVAGET<sup>2</sup>, J.-P. BLANCAL<sup>2</sup>, J.-P. GUICHARD<sup>4</sup>, J.-P. SAINT MAURICE<sup>4</sup>, M. WASSEF<sup>5</sup>, A. KARLIGKIOTIS<sup>6</sup>, R. KANIA<sup>2</sup>, P. HERMAN<sup>2</sup>

<sup>1</sup> ENT Section, Department of Sensory Organs, Sapienza University of Rome, Italy; <sup>2</sup> ENT Department, Lariboisière Hospital, Assistance Publique, Hopitaux de Paris, Paris 7 University, Paris, France; <sup>3</sup> Neurosurgery Department, Lariboisière Hospital, Assistance Publique, Hopitaux de Paris, Paris 7 University, Paris, France; <sup>4</sup> Neuroradiology Department, Lariboisière Hospital, Assistance Publique, Hopitaux de Paris, Paris 7 University, Paris, France;

<sup>5</sup> Pathology Department, Lariboisière Hospital, Assistance Publique, Hopitaux de Paris, Paris 7 University, Paris, France; <sup>6</sup> Division of Otorhinolaryngology, Department of Surgical, Microsurgical and Medical Sciences, University of Sassari, Italy

### SUMMARY

Fibro-osseous benign lesions rarely affect the sinonasal tract and are divided into 3 different entities, namely osteoma, fibrous dysplasia and ossifying fibroma. They share several clinical, radiological and histological similarities, but have different behaviours. Ossifying fibroma, and in particular the “juvenile” histological subtype, may have a locally aggressive evolution and a high risk for recurrence if removal is incomplete. The purpose of the present study is to compare the clinical behaviour of ossifying fibroma with the other benign fibro-osseous lesions; highlight different behaviour between the histological subtypes; compare the advantages, limitations and outcomes of an endoscopic endonasal approach with reports in the literature. We retrospectively reviewed 11 patients treated for sinonasal ossifying fibroma at a tertiary care centre. All patients underwent CT scan, and MRI was performed in cases of cranial base involvement or recurrence. Pre-operative biopsy was performed in cases where it was possible to use an endoscopic approach. One patient underwent pre-operative embolisation with ipsilateral visual loss after the procedure. Depending on its location, removal of the tumour was performed using an endoscopic (n = 7), or an external (n = 3) or combined (n = 1) approach. Histopathologically, 5 patients presented the conventional type, 5 the juvenile psammomatoid variant, which was associated in 1 case with an aneurismal bone cyst, and 1 case presented the trabecular juvenile variant. Three patients affected by the juvenile psammomatoid histological variant presented invasion of the skull base and underwent a subtotal removal that subsequently required, due to the regrowth of the remnant, a transbasal approach. Clinical, radiological and histological findings should all be considered to establish differential diagnosis among fibrous osseous lesions. More studies are necessary to conclude if the localisation and extension of the disease at the time of diagnosis is more important than the histological variant. An endoscopic approach is the first choice in most of cases even if an external open approach may be necessary in selected patients.

KEY WORDS: Ossifying fibroma • Endoscopic surgery • Fibrous dysplasia • Osteoma • Skull base

### RIASSUNTO

*Le lesioni fibro-ossee benigne raramente colpiscono i seni paranasali e sono suddivise in 3 entità: osteoma, displasia fibrosa e fibroma ossificante. Questi presentano simili caratteristiche cliniche, radiologiche e istologiche ma hanno un comportamento diverso. Il fibroma ossificante, in particolare la variante istologica giovanile, può presentare un comportamento aggressivo con un alto rischio di recidiva se rimosso in modo incompleto. Lo scopo dello studio è quello di paragonare il comportamento clinico del fibroma ossificante con quello delle altre lesioni fibro-ossee; di evidenziare un eventuale comportamento differente tra i vari sottotipi istologici; di descrivere i vantaggi, i limiti e i risultati della chirurgia endoscopica endonasale rispetto ai dati presenti in letteratura. Abbiamo analizzato retrospettivamente 11 pazienti affetti da fibroma ossificante naso-sinusale e trattati in un centro ospedaliero di terzo livello. Tutti i pazienti sono stati sottoposti a TC. La RM è stata eseguita in caso di coinvolgimento del basicranio o in caso di recidiva. Una biopsia pre-operatoria è stata effettuata nei casi in cui la massa era raggiungibile per via endoscopica. Un paziente è stato sottoposto a embolizzazione pre-operatoria ed ha riportato una cecità monolaterale al termine della procedura. In base alla localizzazione, l'exeresi del tumore è stata eseguita con un approccio endoscopico (7 pazienti), esterno (3), combinato (1). Istologicamente 5 pazienti hanno riportato un sottotipo convenzionale, 5 la variante giovanile psammomatoide associata in un caso a cisti aneurismatica ossea, e un paziente la variante giovanile trabecolare. Tre pazienti affetti dalla variante istologica giovanile psammomatoide hanno presentato un'invasione del basicranio e sono stati sottoposti ad exeresi subtotale per via endoscopica che ha richiesto in seguito, a causa di un aumento di volume del residuo, un secondo intervento per via transbasale. I reperti clinici, radiologici e istologici dovrebbero essere considerati insieme per una accurata diagnosi differenziale tra le lesioni fibro-ossee. Ulteriori studi sono necessari per concludere se la localizzazione e l'estensione del fibroma ossificante al momento della diagnosi sono più importanti della variante istologica. L'approccio endoscopico è la prima opzione nella maggior parte dei casi anche se in alcuni selezionati pazienti l'approccio esterno risulta ancora necessario.*

PAROLE CHIAVE: Fibroma ossificante • Chirurgia endoscopica • Displasia fibrosa • Osteoma • Basicranio

## Introduction

Fibro-osseous lesions are benign tumours characterised by the replacement of normal bone by a fibrous cellular stroma containing various amounts of foci of mineralisation or ossification<sup>1</sup>. These lesions rarely affect the sinonasal tract<sup>2</sup>. They are usually divided into 3 different entities, namely osteoma, fibrous dysplasia (FD) and ossifying fibroma (OF)<sup>3</sup>. Osteoma is the most frequent subtype, followed by FD and OF<sup>4</sup>. The precise incidence of OF, however, remains unknown. These three entities share several clinical, radiological and histological similarities, but have different behaviours in the sinonasal tract<sup>5,6</sup>. Osteoma is a slow-growing tumour, and FD usually stops growing spontaneously after puberty. In the absence of local complications, surgical intervention is not needed, and a “wait and see” attitude can be advocated<sup>7-9</sup>. In contrast, OF, and in particular the “juvenile” histological subtype, may have a locally aggressive evolution and a high risk for recurrence if removal is incomplete<sup>10,11</sup>. A proper initial diagnosis of the tumour is therefore mandatory to plan appropriate therapeutic management<sup>3,5,12</sup>.

The aim of the present study is to describe the main characteristics that can help clinicians to differentiate OF from other fibro-osseous tumours; highlight different behaviour between histological subtypes; discuss the surgical management of OF, with special regard to the advantages and limitations of an endoscopic endonasal approach.

## Materials and methods

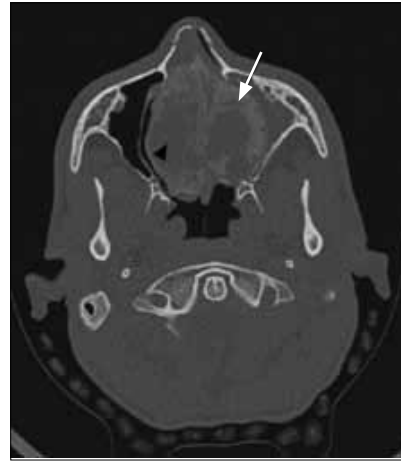
Between 2006 and 2012, 11 patients were referred to our tertiary care centre for an OF of the sinonasal tract. Patient charts were retrospectively reviewed for demographics, clinical presentation, tumour extent based on nasal endoscopy and preoperative imaging, surgical approach and follow-up. This study was approved by the institutional review board of Lariboisière Hospital.

All cases were discussed at the head and neck meeting of the centre with a dedicated radiologist and pathologist, and all patients were operated on by the same surgeon. All patients were assessed preoperatively using CT scan with contrast medium administration. MRI was performed systematically in case of skull base/orbital involvement or recurrence.

Preoperative biopsy was performed in any case where the lesion was reachable through an endoscopic procedure. Follow-up was performed with endoscopic control after 3 and 6 months and then once a year. In case of subtotal removal, a CT scan eventually followed by MRI, was performed after 3 and 6 months to assess the size of the tumour remnant.

## Results

From 2006 to 2012, 11 patients were surgically treated at our institution for an OF of the sinonasal tract. Demographic data, symptoms, tumour extension, surgical ap-



**Fig. 1.** Axial CT: OF appears as a lesion with well-defined margins showing a hypodense signal corresponding to fibrous tissue (arrowhead) with intralesional foci of hyperdensity corresponding to areas of mineralisation (arrow).

proach, surgical procedure and follow-up are summarised in Table I. The male to female ratio was 1.2:1, with a mean age at time of diagnosis of 34 years (range 12-61 years). The most frequent symptom at presentation was nasal obstruction, which was reported by 4 patients, associated in 2 cases with proptosis and in 1 case with facial pain. Other symptoms at presentation included isolated facial pain ( $n = 1$ ), headache ( $n = 1$ ) and facial deformation ( $n = 1$ ). Of note, OF was an incidental finding in 3 asymptomatic patients. One patient had undergone previous surgical intervention at another institution, with preoperative embolisation followed by partial removal of the tumour through a lateral rhinotomy approach. He was referred for management of tumour recurrence.

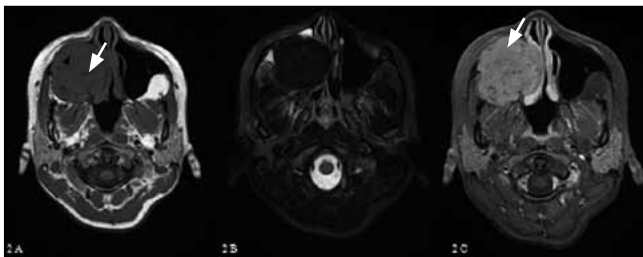
CT scan was performed pre-operatively in all patients (Fig. 1, case #11) and MRI only in the 5 patients with skull base or orbital involvement. Radiological findings were suggestive of OF in 8 cases (Fig. 2, case #8). In the 3 remaining patients, differential diagnoses were discussed, as the radiological aspect was more indicative of FD (2 cases) or primary aneurismal bone cyst (ABC) (Fig. 3, case #9). The mean maximum diameter was 35 mm (range 9-72 mm). OF was limited to the nasal cavity and paranasal sinuses in 6 cases (54%). The cranial base and/or the lamina papyracea were invaded in 5 cases (46%). Pre-operative biopsy was endoscopically performed in 9 cases, while 2 patients underwent surgery without biopsy because of the location of OF in the frontal sinus.

One patient underwent pre-operative embolisation. He was referred to our institution for a cystic mass of the sphenoid bone evocative of ABC. A pre-operative biopsy was performed and resulted in massive bleeding: pre-operative embolisation was therefore advocated for this patient. Selective angiography revealed a major feeder from the left middle meningeal artery that was

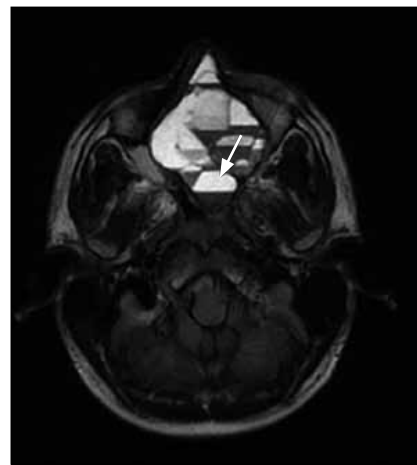
**Table I.** Paranasal ossifying fibromas: presenting signs, radiological findings, management and outcomes.

Patient	Sex (M/F)	Symptoms	Age at time of first surgery	Tumour extension	Tumour dimension (mm) (Ax × Sag × Cor)	Radiological diagnosis	Surgical approach	Surgical procedure	Pathological findings	Follow-up (months)
#1	M	Headache	32	Ant. Ethmoid.; Post. Ethmoid.	9 × 10 × 10	OF	Endonasal	Ant. Ethmoidectomy; Post. Ethmoidectomy Sphenoidotomy	Juvenile psammomatoid type	48
#2	M	Asymptomatic	35	Frontal	13 × 12 × 9	OF	External approach to frontal sinus through Caim incision	Frontal osteoplasty	Conventional type	72
#3	M	Nasal obstruction + facial pain	61	Maxillar	15 × 13 × 16	OF	Endonasal + Caldwell-Luc	Ant. Ethmoidectomy; Maxillectomy	Conventional type	60
#4	F	Facial deformity	41	Frontal	21 × 21 × 15	OF	External approach to frontal sinus through Caim incision	Frontal osteoplasty	Conventional type	20
#5	F	Follow-up after operation through lateral rhinotomy approach in another hospital	13	Ant. Ethmoid.; Post. Ethmoid.; Maxillar, Medial wall of orbit	38 × 16 × 18	OF	Endonasal	Ant. Ethmoidectomy; Post. Ethmoidectomy; medial Maxillectomy	Juvenile trabecolar type	12
#6	F	Asymptomatic	46	Post. Ethmoid.; Sphenoid, Middle cranial base; medial portion of optic nerve	33 × 24 × 28	OF or FD	Endonasal	Ant. Ethmoidectomy; Post. Ethmoidectomy; Sphenoidotomy; middle cranial base	Juvenile psammomatoid type	12
#7	F	Facial pain	29	Maxillar	51 × 49 × 46	OF	Degloving	Maxillectomy	Conventional type	50
#8	M	Asymptomatic	53	Maxillar	25 × 21 × 18	OF	Endonasal	Ant. Ethmoidectomy; Medial Maxillectomy	Conventional type	12
#9	M	Nasal obstruction + proptosis	27	Ant. Ethmoid.; Post. Ethmoid.; Medial wall of orbit; Sphenoid; Middle cranial base; Encasing optic nerve	65 × 50 × 49	ABC	Endonasal	Ant. Ethmoidectomy; Post. Ethmoidectomy; Medial Maxillectomy; Sphenoidotomy; Middle cranial base	Juvenile psammomatoid type associated with aneurysmal bone cyst	Recurrence after 6 months
#10	F	Nasal obstruction + proptosis	12	Post. Ethmoid.; Sphenoid.; Middle cranial base; Encasing optic nerve	43 × 24 × 44	FD	Endonasal	Ant. Ethmoidectomy; Post. Ethmoidectomy; Sphenoidotomy; Middle cranial base	Juvenile psammomatoid type	Recurrence after 6 months
#11	M	Nasal obstruction	20	Post. Ethmoid.; Sphenoid.; Middle cranial base; Encasing optic nerve	72 × 58 × 60	OF	Endonasal	Ant. Ethmoidectomy; Post. Ethmoidectomy; Sphenoidotomy; Middle cranial base	Juvenile psammomatoid type	Recurrence after 6 months

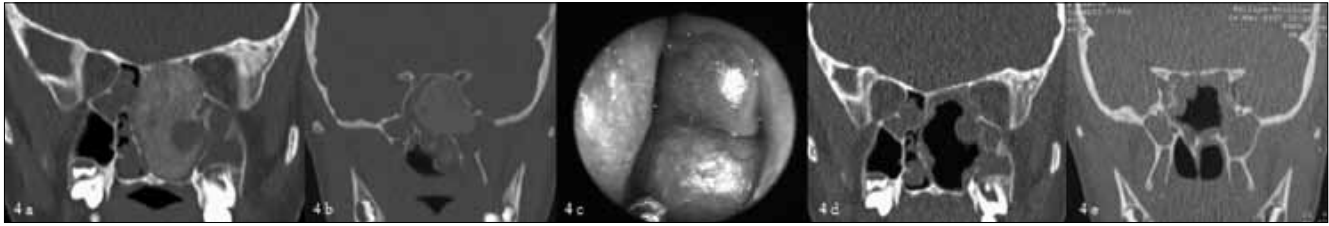
Abbreviations: M: Male; F: Female; mm: millimetres; ax: axial; sag: sagittal; cor: coronal.



**Fig. 2.** Axial MRI: on T1-weighted sequences (A) OF appears as a lesion with intermediate signal intensity, fibrous tissue (arrowhead) with small areas of hypointensity osseous areas (arrow). On T2-weighted sequences (B), ossified areas appear with low signal (arrow), while fibrous tissue exhibits an isointense signal (arrowhead). Contrast enhancement (C) is heterogeneous and is related to fibrous areas (arrow).



**Fig. 3.** On T2-weighted sequences, a multicystic lesion with "fluid-fluid" levels (arrow) suggestive for ABC is present within OF.



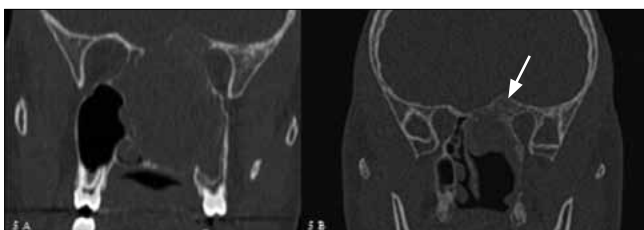
**Fig. 4.** (A) Pre-operative coronal CT scan showing the tumour at the level of the left ethmoid sinus and (B) at the level of the sphenoid. (C) Endoscopic view of the OF appearing as a submucosal mass. (D) Post-operative coronal CT scan at the level of the ethmoid sinus and sphenoid sinus.

embolised with microspheres (100-300 microns). Immediately after the procedure, the patient presented complete left visual loss. Fundoscopy exam revealed a pale papilla, while fluorescein angiography showed papillar hypoperfusion in each phase of the examination and late choroidal and retinal circulation. Atrophic bands on the periphery without areas of ischaemia were also present. These findings were consistent with central retinal occlusion.

Surgical removal of the tumour was performed through a purely endoscopic approach in 7 cases (64%) (Fig. 4, case #10), through a combined approach in 1 case (endoscopic/Caldwell-Luc) and through a midfacial degloving or a coronal approach in 1 and 2 cases, respectively. When the tumour developed on the lamina papyracea (case #5), aberrant tumour vessels feeding the neoplasm across the periorbit were observed during surgery.

Intra-operative complications occurred in 2 cases, consisting in CSF-leak after endoscopic drilling of the cribriform plate or dissection of the sheath of the optic nerve. Preoperative intratechal fluorescein was not used in any case. However, the CSF-leak was immediately evident and treated successfully at the end of the surgical procedure in both cases with application of Tachosil®. Lumbar drains were never used.

Histopathological examination confirmed a diagnosis of OF in all cases. Five patients presented the conventional type and 1 case presented the trabecular juvenile variant,



**Fig. 5.** (A) Pre-operative coronal CT of case #10 who underwent a subtotal removal of the lesion with an endoscopic approach. (B) Coronal CT scan performed 6 months after surgery showing rapid regrowth of the remnant (arrow). An external approach was subsequently performed.

while 5 patients presented the juvenile psammomatoid variant which was associated in 1 case with an ABC.

In 3 of the 7 patients first operated through an endoscopic approach, removal was incomplete since the tumour extended at the skull base beyond the optic nerve. Postoperative follow-up evidenced a rapid growth of the remnant (about 1 mm per month) (Fig. 5). A transbasal approach was performed and allowed complete removal. All these 3 patients presented a juvenile psammomatoid histological variant.

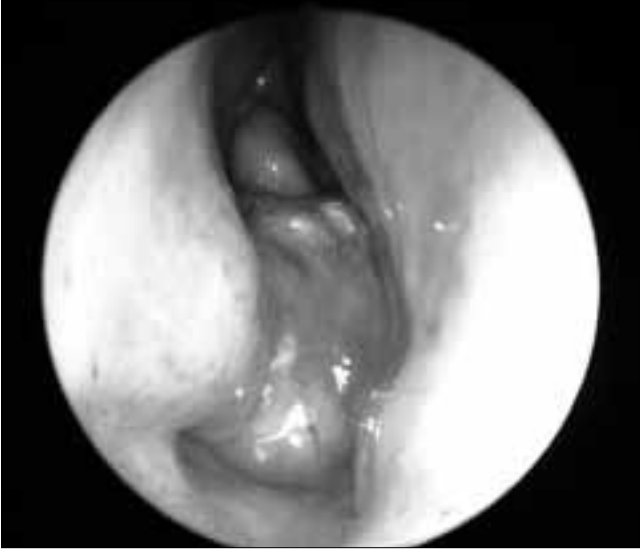To date, all patients are free of disease after a mean follow-up of 27 months (range 6-72 months). Long term complications included 1 case of stenosis of the lacrimal duct after endoscopic medial maxillectomy, successfully treated by endoscopic dacryocystorhinostomy, and 1 case of multiple mucoceles of the maxillary sinus after a midfacial degloving procedure, which was treated by endoscopic marsupialisation.

## Discussion

In this report, we have added our experience to the limited amount of data available in the literature reviewing 11 clinical cases of OF operated on at a tertiary centre.

In our series, there were no specific symptoms of OF: as for other benign fibrous osseous lesions, it can be incidentally discovered when imaging is performed for another indication, or may become symptomatic in relation to a mass effect of the tumour on adjacent structures. When the lesion protrudes in the nasal fossa, it can be visualised on endoscopy as a submucosal smooth rounded mass<sup>13</sup> (Fig. 6).

The imaging work-up relies mainly on CT scan, but in selected cases MRI should also be performed. Radiological findings can be very suggestive of OF, but, as shown in the present report, differential diagnosis with other bony lesions can be difficult. CT has distinct advantages over MRI, as it allows better bony assessment. OF presents like a tumour, with contour deformity and loss of anatomical shape, while FD consists mainly in bone hypertrophy which keeps the global shape of the bone intact<sup>14</sup>. In contrast to FD, OF does not exhibit a ground glass appearance, but rather a mixture of bone density and soft tissues with thick bony walls. The sharply defined outside margins of OF are the



**Fig. 6.** Endoscopic view of OF at the level of the right nasal fossa presenting with its typical aspect: a submucosal smooth rounded mass.

most important radiological sign for differential diagnosis with FD and malignant tumours such as sarcoma or chondrosarcoma, which present with ill-defined margins<sup>15</sup>. Contrast CT scan may show subtle enhancement corresponding to the soft tissues of OF, while osteomas are not enhanced. In our case series, CT scan was useful in pre-surgical planning to assess the precise extension of the tumour. However, while delineation of OF with soft tissues seemed sharp, dissection revealed adherence of the tumour to soft tissues, i.e. periorbit and dura mater, in contrast to osteomas.

At MRI, OF usually harbour low to intermediate signal intensity on T1 weighted imaging: the signal in fibrous areas is intermediate, while that in osseous areas is hypointense. Contrast enhancement is heterogeneous and may be related to fibrous areas<sup>16</sup>. On T2, ossified areas appear with low signal, while fibrous tissue exhibits a hypointense signal. Fluid-fluid levels have been reported, but as shown herein they seem to be associated with a secondary ABC<sup>17</sup>. While MRI, combined with CT scan, helps to make a correct diagnosis, it also allows assessment of at risk structures in the case of intracranial or intraorbital extension, and at last during follow-up to discriminate scar tissue from mucocele as in the case of the patient treated with midfacial degloving.

In consideration of the overlapping radiological and clinical features among fibro-osseous lesions, even if the imaging may be evocative for OF, we suggest pre-operative biopsy when the lesion is endoscopically accessed. In our opinion, is important to exclude malignant tumours such as sarcomas that radiologically may present with a range of findings such as intact margins, bone sclerosis, bone erosion and gross bone destruction, as well as varying degrees of internal calcified or ossified matrix that may complicate

differential diagnosis<sup>18</sup>. Preoperative biopsy may also help to differentiate other benign fibro-osseous lesions, in particular FD which may require alternative management. In our series, before biopsy three cases were presumed to be affected by FD and ABC rather than OF. However, we did not perform a preoperative biopsy in 2 patients because of the frontal sinus localisation of the tumour.

Histological classification of OF is somewhat confusing: multiple, sometimes overlapping terms are used, including ossifying fibroma, cementifying fibroma, cemento-ossifying fibroma, desmo-osteoblastoma, psammo-osteoid fibroma, psammomatoid ossifying fibroma, juvenile ossifying fibroma, juvenile aggressive ossifying fibroma, or juvenile active ossifying fibroma<sup>5</sup>. These terms partially refer to a more or less well-defined subtypes of OF but some might also be used synonymously. Herein, we used the most recent guidelines of WHO<sup>19</sup> for odontogenic tumours: conventional type OF (COF) includes a juvenile histological variant that is further subdivided in trabecular (TJOF) and psammomatoid (PJOF) types.

COF is composed of both fibrous and mineralised tissue, and exhibits a sharp delimitation from surrounding healthy tissue, in contrast to FD, and the pattern of mineralisation varies from area to area, while it is homogeneous in FD. The trabecular juvenile variant is composed of densely cellular fibrous tissue with little collagen, containing thin strand-like trabeculae of osteoid and woven bone. The psammomatoid juvenile variant is also densely cellular, but the calcifications are spherical or lamellated like typical psammomatoid bodies<sup>19</sup>. Manens et al.<sup>13</sup> in their review on 137 cases reported a similar clinical behaviour between the subtypes of OF, while Wang et al.<sup>20</sup> in their case series on 31 patients reported a higher rate of recurrence in the juvenile type. In our series, the 5 patients presenting with extensive disease at the time of diagnosis, including massive involvement of the paranasal sinus and skull base or medial orbital wall, invasion and destruction of surrounding tissue and bony erosion had the juvenile variant. Three of these patients presented extensive sphenoid involvement with an extension beyond the optic nerve and, even if an external approach would have lead to a more radical surgery, in consideration of the benign nature of the pathology, we decided to primarily perform an endoscopic approach with a subtotal resection at the level of the clinoid. A wait and see policy was then adopted that showed rapid regrowth requiring a subsequent subfrontal approach. Thus, from our case series, we had the impression that the juvenile type presented a more aggressive behaviour. To avoid recurrence, when preoperative biopsy highlights the juvenile type, we suggest total removal of the lesion.

However, due to the small series and the limited data in the literature, it is not possible to conclude if a higher percentage of recurrences is related to active behaviour due to an unknown intrinsic biologic factor associated with the juvenile variant, or to features unrelated to the histologi-



cal subtypes such as the extension into adjacent structures (orbit, optic canal, cranial fossa) at the time of diagnosis and the incomplete surgical resection performed to avoid the risk of iatrogenic lesions and excessive bone resection causing facial deformity. Thus, larger case series on this topic are needed.

Surgical removal of OF is difficult compared with osteoma: total resection is mandatory to avoid recurrences, but OF are characterised by high vascularisation and frequent adherence to the dura and periorbit<sup>4 5 12</sup>. Thus, complete removal of this benign lesion has always been challenging. As reported by Wang et al.<sup>20</sup>, to avoid recurrences, we found necessary to remove the outer lamella of the tumour and drill out pathological bone with a diamond burr until reaching smooth healthy bone that presents a less friable consistence. Traditionally, extranasal or microscopical techniques have been described to achieve complete resection. However, recent studies have reported on the endoscopic removal of OF<sup>6 10</sup>, with improved endoscopes and instruments, increased surgical experience, refinements of techniques (e.g. “four-hand-technique”) and the routine use of navigation systems.

In our series, four cases were not addressed through a purely endoscopic approach. One was operated on in 2006 using a Caldwell-Luc approach that would nowadays be amenable to an endoscopic approach. The other three cases illustrate the limitations and contraindications of an endoscopic approach: tumour extension to the anterior wall of the frontal sinus and supraorbital recess<sup>21 22</sup>, extension beyond the optic nerve and extension to the anterior wall of maxillary sinus, which should be addressed using a Cairn approach or midfacial degloving or Caldwell-Luc approaches, respectively.

In the last 20 years, pre-operative embolisation of feeding vessels has been increasingly used preoperatively for vascular head and neck tumours, such as paragangliomas and JNAs<sup>23</sup>. The most important risk when embolising the orbital region is the occlusion of the central retinal artery, which is a terminal vessel and results in blindness of the patient. Anastomotic connections between the ophthalmic artery and the external carotid artery are vestiges of embryonic configurations that may occasionally persist into adulthood as anatomic variants. In particular, the middle meningeal artery, which was embolised in the patient treated in our institute and affected by ABC secondary to OF, may present a small anastomosis, the recurrent meningeal artery, with the lacrimal branch of the ophthalmic artery<sup>24</sup> that may explain the sudden post-operative ipsilateral visual loss that occurred in our patient.

Complications of endovascular treatment are rare and well-known and may be due to reflux of embolic agent or migration through undetected external/internal carotid artery collaterals. While such complications are supposedly rare, the present work highlights that OFs with or without associated ABC are highly vascularised, and in close con-

nection with the ophthalmic arterial network. Therefore, based on this experience, and with the availability of new haemostatic agents, we would not recommend preoperative embolisation for these tumours.

## Conclusions

OF of the sinonasal tract is a rare benign fibro-osseous tumour. Clinical, radiological and histological findings should all be considered to better establish a differential diagnosis with other fibro-osseous tumours, either benign or malignant, and a pre-operative biopsy should always be performed when possible.

In the present case series, patients affected by the histological juvenile variant presented extensive localisation and rapid regrowth when subtotally removed. However, due to the small number of cases in the literature and in the present series, no conclusions can be drawn if the biological behaviour of the different histological subtypes of OF is more important than the extension of the tumour at the time of diagnosis, and larger cases series may be necessary to clarify this point.

Complete surgical removal is the only curative treatment for OF, and should be performed through an endoscopic approach as a first choice option. An external approach is still needed in cases of OF affecting the anterior wall of the frontal sinus or supraorbital recess, encasing the optic nerve or invading the skull base laterally to the optic nerve. In these tumours, even if highly vascularised, when proximal to the orbit embolisation should be avoided due to the close connection with the ophthalmic arterial network.

## References

- Speight PM, Carlos R. *Maxillofacial fibro-osseous lesions*. *Curr Diagn Pathol* 2006;12:1-10.
- Commins DJ, Tolley NS, Milford CA. *Fibrous dysplasia and ossifying fibroma of the paranasal sinuses*. *J Laryngol Otol* 1998;112:964-8.
- Eller R, Sillers M. *Common fibro-osseous lesions of the paranasal sinuses*. *Otolaryngol Clin North Am* 2006;39:585-600.
- Lund VJ, Stammberger H, Nicolai P, et al. *European position paper on endoscopic management of tumours of the nose, paranasal sinuses and skull base*. *Rhinol Suppl* 2010;22:1-143.
- Ledderose GJ, Stelter K, Becker S, et al. *Paranasal ossifying fibroma: endoscopic resection or wait and scan?* *Eur Arch Otorhinolaryngol* 2011;268:999-1004.
- Post G, Kountakis SE. *Endoscopic resection of large sinonasal ossifying fibroma*. *Am J Otolaryngol* 2005;26:54-6.
- Turri-Zanoni M, Dallan I, Terranova P, et al. *Frontoethmoidal and intraorbital osteomas: exploring the limits of the endoscopic approach*. *Arch Otolaryngol Head Neck Surg* 2012;138:498-504.
- Pons Y, Blancal JP, VÉrillaud B, et al. *Ethmoid si-*

- nus osteoma: diagnosis and management.* Head Neck 2013;35:201-4.
- 9 Pagella F, Pusateri A, Matti E, et al. *Transnasal endoscopic approach to symptomatic sinonasal osteomas.* Am J Rhinol Allergy 2012;26:335-9.
  - 10 Choi YC, Jeon EJ, Park YS. *Ossifying fibroma arising in the right ethmoid sinus and nasal cavity.* Int J Pediatr Otorhinolaryngol 2000;54:159-62.
  - 11 Pirana S, Zerati F, Voegels R, et al. *Psammomatoid ossifying fibroma.* Rhinology 2003;41:250-2.
  - 12 London SD, Schlosser RJ, Gross CW. *Endoscopic management of benign sinonasal tumors: a decade of experience.* Am J Rhinol 2002;16:221-7.
  - 13 Manes RP, Ryan MW, Batra PS, et al. *Ossifying fibroma of the nose and paranasal sinuses.* Int Forum Allergy Rhinol 2013;3:161-8.
  - 14 Engelbrecht V, Preis S, Hassler W, et al. *CT and MRI of congenital sinonasal ossifying fibroma.* Neuroradiology 1999;41:526-9.
  - 15 Sontakke SA, Karjodkar FR, Umarji HR. *Computed tomographic features of fibrous dysplasia of maxillofacial region.* Imaging Sci Dent 2011;41:23-8.
  - 16 Kendi AT, Kara S, Altinok D, et al. *Sinonasal ossifying fibroma with fluid-fluid levels on MR images.* AJNR Am J Neuroradiol 2003;24:1639-41.
  - 17 Yang BT, Wang YZ, Wang XY, et al. *Imaging study of ossifying fibroma with associated aneurysmal bone cyst in the paranasal sinus.* Eur J Radiol 2012;81:3450-5.
  - 18 Efuno G, Perez CL, Tong L, et al. *Paranasal sinus and skull base fibro-osseous lesions: when is biopsy indicated for diagnosis?* Int Forum Allergy Rhinol 2012;2:160-5.
  - 19 Slootweg PJ, El Mofty SK. *Ossifying fibroma.* In: Barnes L, Eveson JW, Reichart P, Sidransky D, editors. *World Health Organization classification of tumours. Pathology and genetics of head and neck tumours.* Lyon: IARC; 2005. p. 319-20.
  - 20 Wang H, Sun X, Liu Q, et al. *Endoscopic resection of sinonasal ossifying fibroma: 31 cases report at an institution.* Eur Arch Otorhinolaryngol 2014;271:2975-82.
  - 21 Castelnuovo P, Valentini V, Giovannetti F, et al. *Osteomas of the maxillofacial district: endoscopic surgery versus open surgery.* J Craniofac Surg 2008;19:1446-55.
  - 22 Savastano M, Guarda-Nardini L, Marioni G, et al. *The bicoronal approach for the treatment of a large frontal sinus osteoma. A technical note.* Am J Otolaryngol 2007;28:427-9.
  - 23 Smith TP. *Embolization in the external carotid artery.* J Vasc Interv Radiol 2006;17:1897-913.
  - 24 Hufendiek K, Hufendiek K, Finkenzeller T, et al. *Acute visual loss after preoperative embolization of an ethmoidal metastasis.* Int Ophthalmol 2012;32:165-9.

Received: April 2, 2015- Received: April 30, 2015

CASE SERIES AND REPORTS

# Surgical approach to isolated bilateral orbital floor fractures

## *Approccio chirurgico alle fratture isolate bilaterali del pavimento orbitario*

M. GIARDA, A. TAVOLACCINI, F. ARCURI, M. BRUCOLI, A. BENECH

Resident Department of Maxillo-Facial Surgery, Azienda Ospedaliera Maggiore della Carità, University of Piemonte Orientale "Amedeo Avogadro", Novara, Italy.

### SUMMARY

Isolated bilateral orbital floor fractures are uncommon and are rarely described in the scientific literature. They are usually seen in association with naso-ethmoidal fractures, zygomatic fractures, or fractures of the middle third. We report our experience in the management of a patient presenting bilateral isolated orbital floor fracture. The difficulties in management of these fractures are due to the lack of an uninjured contralateral side for intraoperative comparison.

KEY WORDS: Maxillofacial fracture • Orbital floor fracture • Bilateral isolated fracture

### RIASSUNTO

*Fratture isolate bilaterali del pavimento orbitario sono rare e raramente sono descritte nella letteratura scientifica. Sono osservate solitamente in associazione con fratture naso-etmoidali, fratture zigomatiche o fratture del terzo medio. Riportiamo la nostra esperienza nella gestione di un paziente che presenta frattura isolata bilaterale del pavimento orbitario. La difficoltà nella gestione di queste fratture è dovuta alla mancanza di un lato controlaterale non lesionato per il confronto intraoperatorio.*

PAROLE CHIAVE: *Frattura maxillofacciale • Frattura pavimento orbitario • Frattura isolata bilaterale*

Acta Otorhinolaryngol Ital 2015;35:362-364

## Introduction

Bilateral orbital floor fractures are in most cases associated with other facial skeletal fractures. They are usually seen in association with naso-ethmoidal fractures, zygomatic fractures or fractures of the middle third. Isolated bilateral orbital floor are uncommon and are not easy to surgical management. We report our experience in the treatment of a patient presenting bilateral isolated orbital floor fracture.

## Case report

On May 2011, a 54-year-old man was referred to the Maxillofacial Department of the Novara Major Hospital after an assault; he sustained several injuries to the face. Clinical examination showed bilateral periorbital swelling and ecchymosis, bilateral subconjunctival haemorrhages and hypoesthesia in the distribution of the infraorbital nerve. The patient did not report subjective diplopia. There was no clinical evidence of other concomitant facial fractures. The patient underwent immediate radiographic examination. The axial, coronal and sagittal computed tomography (CT) scans showed

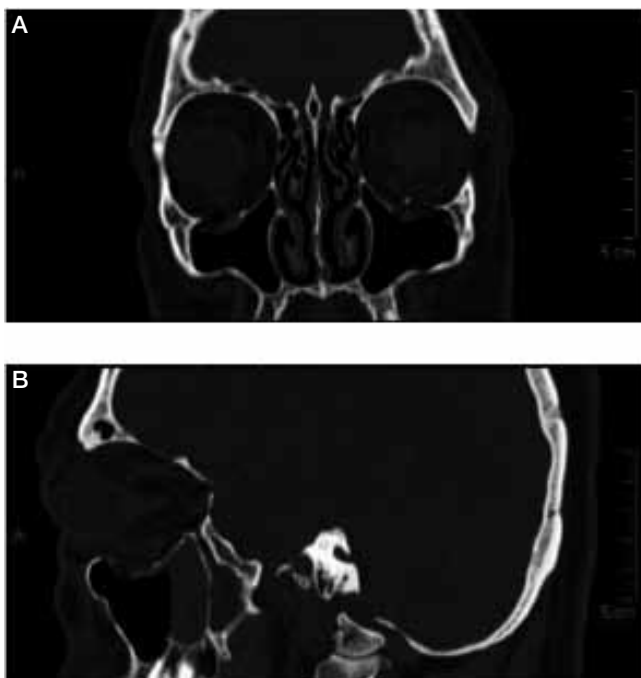
displaced bilateral orbital floor fractures. There was the absence of any other fractures to the middle third of the face. A Hess Chart revealed moderate restriction in both eyes, and abduction, restriction of elevation and depression of the left eye. Diplopia was demonstrated in all fields. At 2 days after trauma the patient underwent surgery. Under general anaesthesia both orbital floors were explored by a transconjunctival approach. Extensive fractures of the orbital floors with herniation of periorbital contents was observed bilaterally. The floor defects were reconstructed bilaterally with titanium mesh secured to the infraorbital rim with three 5-mm titanium screws. Forced abduction tests showed no restriction of eye movements. One month after the surgical procedure, CT scan demonstrated adequate osteosynthesis of the titanium mesh. The implants were placed bilaterally in a proper position, restoring the geometric anatomy of the orbital floor. Hess chart examination at 6 months showed complete restoration of ocular movements and total resolution of diplopia. There was no evidence of enophthalmos. At 3 months after surgery, we observed left scleral show that was improved by active palpebral physiotherapy and did not require surgical revision.

## Discussion

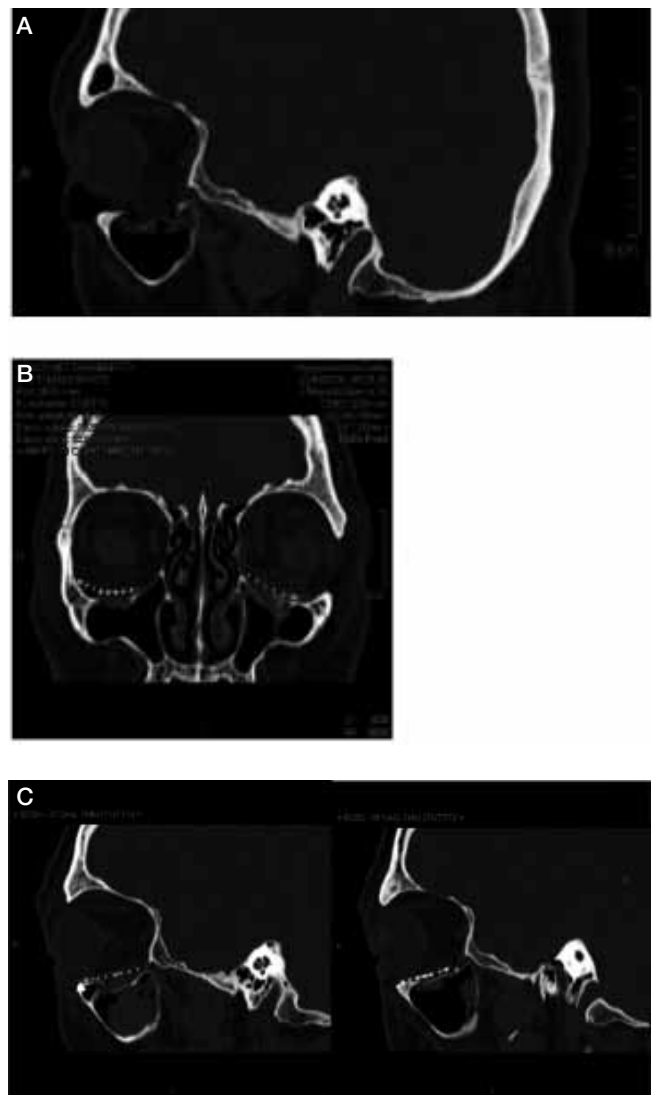
Isolated bilateral orbital floor fractures have rarely been reported in scientific literature; there are a limited number of clinical cases of bilateral orbital floor fractures not associated with other facial fractures.

Polli reported a case of isolated bilateral orbital floor fractures<sup>1</sup>; Swinson reported three cases<sup>2</sup> and another case has been described by Agir<sup>3</sup>. The analysis of 19 patients with bilateral orbital floor fractures reported by Nielsen showed that these were present with other facial fractures<sup>4</sup>. Orbital floor fractures are divided into pure, limited to the floor, and into impure, associated with fracture of the infraorbital margin. The pathogenesis of orbital fractures over the years has been discussed and explained by two theories. The first is the buckling mechanism, first postulated by Le Fort in the 1901, which implies a force to the infraorbital rim causing a ripple effect with buckling of the bone of the orbital floor<sup>5</sup>. The second is the hydraulic theory, explained by Pfeiffer in 1943, which refers to a direct force to the globe causing an increase in intraorbital pressure and fracture at the weakest point<sup>6</sup>. It is still not entirely clear which mechanism is actually responsible for these fractures, but it is likely that both mechanisms can contribute to fracture with different patterns of injury<sup>7</sup>. The majority of bilateral orbital floor fractures are result of fights, and only Agir identifies a bomb blast as the cause<sup>3</sup>. In this case, the patient was victim of an aggression in which he sustained several blows to the face. The patient could not describe exactly where he was struck. Probably, both described mechanisms played a role in the origin of these fractures. The clinical picture is similar to other midface

fractures such as periorbital swelling and ecchymosis, conjunctival chemosis, ptosis, hypoesthesia in the territory of the infraorbital nerve and diplopia. During clinical examination, we found it technically difficult to assess the enophthalmos and ocular movements due to the lack of an unaffected side for comparison. Next, ophthalmologist assessment supported by Hess Chart becomes necessary. Fine-section spiral CT scans of the orbits are essential to assess the type, location and extent of fracture; three-dimensional reconstruction also allows more accurate pre-operative planning<sup>8</sup>. However, despite the accuracy of modern imaging techniques, the size of the bone defect observed on CT appears smaller than the bone gap found intraoperatively<sup>9</sup>. Management of these fractures is technically difficult because of the lack of comparison with the contralateral globe. The failure or inadequacy of proper orbital reconstruction is frequently due to the incomplete exposure of the bone defect, especially the inferomedial orbital floor<sup>10</sup>; it is essential to get wide surgical expo-



**Fig. 1A-B.** CT scans showing the displaced bilateral orbital floor fractures in the absence of other midface fractures.



**Fig. 2A-C.** CT scans showing reduction and osteosynthesis of bilateral orbital floor fracture.

sure. The most frequent postoperative complications are diplopia, enophthalmos and infraorbital nerve dysaesthesia. The incidence of these complications depends on the type, extent and location of fracture. The purpose of surgical treatment is to restore orbital volume and to reposition herniated structures to avoid re-operation which is often unsatisfactory. According to the majority of authors, the operating time must not exceed two weeks of injury to minimise the risk of scarring events in the herniated soft tissue<sup>11</sup>. Surgical techniques are varied and include: 1) Reduction of the fracture by endosinusal hydro-pneumatic supports (endosinusal balloon)<sup>12</sup>; 2) Autologous grafts (calvarian bone, antral wall, cartilage, rib and ilium); 3) heterologous and/or alloplastic resorbable materials (polydioxanone, polyglycolic acid or to the poly L-lactide acid); 4) No resorbable materials (polyethylene or titanium)<sup>13</sup>. Titanium mesh permits accurate reconstruction of the orbital anatomy. In our case, we used titanium mesh on both sides. Titanium mesh has the advantage of being fully compatible and easily modelled<sup>14</sup>, and is also indicated in the presence of major bone defects that are difficult to reconstruct<sup>15</sup>. Recently, computer aided design/modelling (CAD/CAM) software allows preoperative “mirroring” planning and can be associated with an intraoperative navigation system. The non-fractured contralateral side is “mirrored” by pre-operative CT imaging. A titanium mesh is prefabricated on this virtual template; it is sterilized and is placed to reconstruct the orbital floor. The position is controlled intraoperatively with the aid of the pointer device of the navigation system. However, to the best of our knowledge, this approach is limited to unilateral cases and the cost is very high<sup>16</sup>. In conclusion, isolated bilateral orbital floor fractures should be approached and studied as unilateral orbital fractures, putting more attention to the precise exposure and surgical bone reconstruction. The difficulties in management of these fractures are due to the lack of an uninjured contralateral side for comparison.

## References

- <sup>1</sup> Polli NS, Guida A, Valentini C, et al. *Unusual case of bilateral blow-out fracture of orbital floor*. Radiol Med (Torino) 1998;96:628-30.
- <sup>2</sup> Swinson B, Amin M, Nair P, et al. *Isolated bilateral orbital floor fractures: a series of 3 cases*. J Oral Maxillofac Surg 2004;62:1431-5.
- <sup>3</sup> Agir H, Ustundag E, Iscen D. *Bilateral isolated orbital blow out fractures among terrorist bombing victims. A very rare entity*. Br J Plast Surg 2005;306-7.
- <sup>4</sup> Nielsen IM, Vibe P, Andersen M, et al. *Bilateral orbital floor fractures*. Scand J Plast Reconstr Surg 1985;19:189-91.
- <sup>5</sup> Le Fort R. *Etude experimentale sur les fractures de la machoire superieure*. Rev Chir 1901;23:208.
- <sup>6</sup> Pfeiffer RL. *Traumatic enophthalmos*. Arch Ophthalmol 1943;30:718.
- <sup>7</sup> Waterhouse N, Lyne J, Urdang M, et al. *An investigation into the mechanism of orbital blow out fractures*. Br J Plast Surg 1999;52:607-12.
- <sup>8</sup> Metzger MC, Hohlweg-Majert B, Schön R, et al. *Verification of clinical precision after computer-aided reconstruction in craniomaxillofacial surgery*. Oral Surg Oral Med Oral Pathol Oral Radiol Endod 2007;104:e1-10.
- <sup>9</sup> Hankovan V, Hadley DA, Moos K, et al. *Comparison of imaging techniques with surgical experience in orbital injuries. A prospective study*. J Craniomaxillofac Surg 1991;19:348-52.
- <sup>10</sup> Hammer B. *Orbital fractures: diagnosis, operative treatment. Secondary corrections*. Seattle, WA: Hoegrefe and Huber; 1995. p. 3.
- <sup>11</sup> Hossal BM, Beatty RL. *Diplopia and enophthalmos after surgical repair of blow-out fracture*. Orbit 2002;21:27-33.
- <sup>12</sup> Miki T, Wada J, Haraoka J, et al. *Endoscopic transmaxillary reduction and balloon technique of blow out fractures of the orbital floor*. Minim Invasive Neurosurg 2004;47:359-64.
- <sup>13</sup> Krishnan V, Johnson JV. *Orbital floor reconstruction with autogenous mandibular symphyseal bone grafts*. J Oral Maxillofac Surg 1997;55:327-30.
- <sup>14</sup> Schubert W, Gear A, Lee C, et al. *Incorporation of titanium mesh in orbital and midface reconstruction*. Plast Reconstr Surg 2002;110:1022-1030.
- <sup>15</sup> Wang S, Xiao J, Liu L, et al. *Orbital floor reconstruction: a retrospective study of 21 cases*. Oral Surg Oral Med Oral Pathol Oral Radiol Endod 2008;106:324-30.
- <sup>16</sup> Terzic A, Scolozzi P. *Image guided surgical navigation integrating “mirroring” computational planning based on intra-operative cone-beam CT imaging: a promising new approach for management of primary bilateral midfacial fractures*. Comput Aided Surg 2011;16:170-80.

Received: June 11, 2012 - Accepted: October 5, 2012

Address for correspondence: Mariangela Giarda, S.C.D.U. di Chirurgia Maxillo-Facciale, Ospedale Maggiore della Carità, corso Mazzini 18, 28100 Novara, Italy. Tel. +39 0321 3733893-3733783-3733895. Fax +39 0321 3733893. E-mail: mariangelagiarda@yahoo.it

CASE SERIES AND REPORTS

# Bleomycin sclerotherapy for lymphatic malformation after unsuccessful surgical excision: case report

## *Scleroterapia con bleomicina per malformazioni linfatiche dopo fallimento dell'escissione chirurgica: caso clinico*

A. VLAHOVIC<sup>1</sup>, A. GAZIKALOVIC<sup>2</sup>, O. ADJIC<sup>3</sup>

<sup>1</sup> Department of Plastic and Reconstructive Surgery and Burns, <sup>2</sup> Department of Radiology, Institute for Mother and Child Health Care of Republic Serbia, New Belgrade, Serbia; <sup>3</sup> Center for Diagnostic Imaging, Oncology Institute of Sremska Kamenica

### SUMMARY

Lymphatic malformations (LMs) are benign cystic masses resulting from the abnormal development of lymphatic channels. Lymphatic malformations occur primarily in the head and neck region. Surgical excision of lymphatic malformation is followed by high rate of recurrence and a high risk of complications. Bleomycin is an established antineoplastic drug. It can be used as a sclerosing agent in vascular anomalies. We present a child who was unsuccessfully treated with four surgical resections, with peripheral palsy of facial nerve as complication. The lymphatic malformation was successfully treated in our institution with intralesional administration of bleomycin.

**KEY WORDS:** Lymphatic malformation • Bleomycin • Sclerotherapy

### RIASSUNTO

*Le malformazioni linfatiche (LMS) sono masse cistiche benigne derivanti dallo sviluppo anormale dei canali linfatici. Le malformazioni linfatiche interessano principalmente il distretto testa-collo. L'asportazione chirurgica di malformazioni linfatiche è seguita da un alto tasso di recidiva e vi è un elevato rischio di complicanze. La bleomicina è un farmaco antineoplastico approvato. Tale farmaco può essere usato come agente sclerosante nelle anomalie vascolari. Presentiamo il caso di un bambino sottoposto a quattro interventi chirurgici senza successo, complicati da una paralisi periferica del nervo faciale. La malformazione linfatica è stata da noi trattata con successo con la somministrazione intralesionale di bleomicina.*

**PAROLE CHIAVE:** Malformazione linfatica • Bleomicina • Scleroterapia

Acta Otorhinolaryngol Ital 2015;35:365-367

### Introduction

Lymphatic malformations (LMs) are developmental anomalies of lymphatic system consisting of abnormally formed lymphatic channels and cystic spaces<sup>1,2</sup>. Lymphatic malformations occur primarily in the head and neck, accounting for 75% of all cases. They are typically detected at birth, and 90% is clinically apparent by the age of 2 years<sup>1,3</sup>. There are three morphologic types of LMs: microcystic, macrocystic and combined (combination of microcystic and macrocystic components)<sup>3</sup>. LMs in head and neck region cause pain, bleeding, infection, muscular atrophy, malocclusion, speech difficulties, feeding problems, airway obstruction and cosmetic deformities<sup>1-3</sup>. Several methods have been used to treat LMs including surgical excision, sclerotherapy, laser therapy and radiofrequency ablation<sup>1,4</sup>. Historically, first-line therapy for LM has been surgical excision. However, complete excision is usually not possible, and there is a high rate of recurrence<sup>2</sup>.

There are also postoperative complications such as nerve injury (up to 45%), airway obstruction caused by swelling, haematoma formation and wound infection<sup>2,4</sup>. Sclerotherapy has emerged as a promising alternative to surgical management for LMs in children<sup>1,2</sup>. Several different sclerosing agents and injection protocols have been documented in the literature, with varying amounts of success (OK-432, bleomycin, doxycycline, sodium tetradecyl sulfate 3%, alcoholic solution of zein, ethanol)<sup>1,4,5</sup>.

Bleomycin was first developed as an antineoplastic antibiotic, and its sclerosing effect was discovered later<sup>3,6-8</sup>. The mechanism involves damage to endothelial cells with a nonspecific inflammatory reaction and occlusion of vessels<sup>3,9-11</sup>. Intralesional bleomycin injections have been shown to be an effective treatment for haemangiomas and vascular malformation lesions<sup>5</sup>. Pulmonary fibrosis as a complication after intralesional treatment with bleomycin has never been reported<sup>1,5</sup>.

### Case report

A 6-year-old boy with left-sided swelling of the face and neck was brought to our department. He was previously treated at different institution when he was 4.5 years old. The child had had four partial resections during a 1.5 year period by different surgical teams. There were no exact data on previous diagnostic and treatment procedures. One month before he was admitted to our institution, after the last surgical resection and drainage, and the swelling had increased followed by intense pain. The child had breathing and feeding difficulties. Local status revealed peripheral palsy of facial nerve (mandible branch of fa-

cial nerve) (Fig. 1). Several scars at left side of the neck and submandibular region from previous surgical interventions were also noticed. At our department, laboratory findings were within normal range. MRI was as follows: expansive, multilocular cystic lesion at left parotid region expanding to pterygoplatinal fosa, parapharyngeal space, submandibular and carotid space on left side, surrounding large vessels. Craniocaudal diameter of single unilocular lesion was 45 mm. Distal border of lesion was at level 12 mm below mandibular margin. Cysts fluid was T2W/T1W hyperintense, with proteinic or haemorrhagic characteristics (T1W not shown). Conclusion: LM of parotid region and pterygopalatal fossa (Fig. 2).

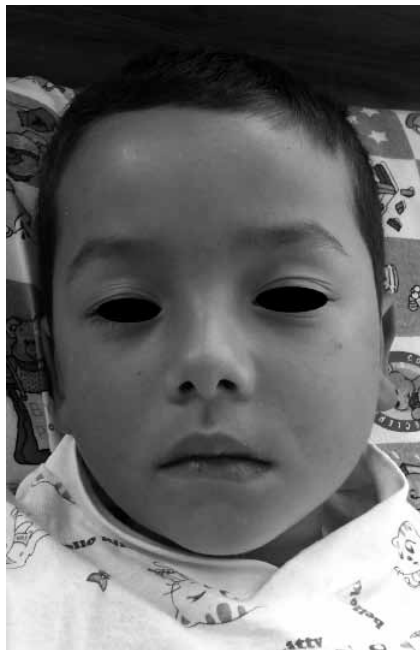

Fig. 1. Patient at admission with left-side swelling of face and neck and facial nerve peripheral palsy.

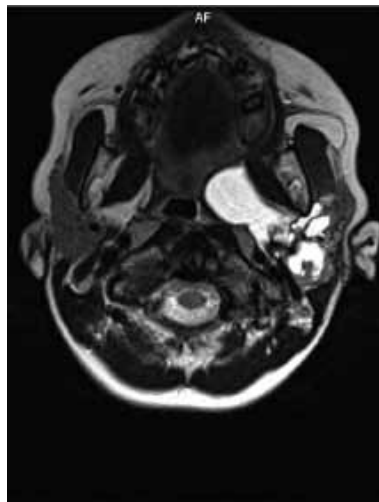


Fig. 2. NMR revealing macrocystic lymphatic malformation of left parotid region expanding to pterygopalatal fossa, parapharyngeal, submandibular and the carotid space.

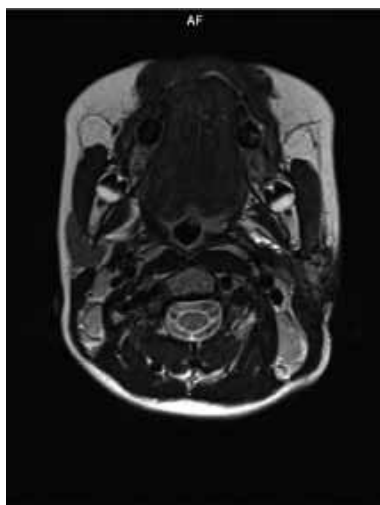


Fig. 3. Postoperative NMR showing nearly complete regression.

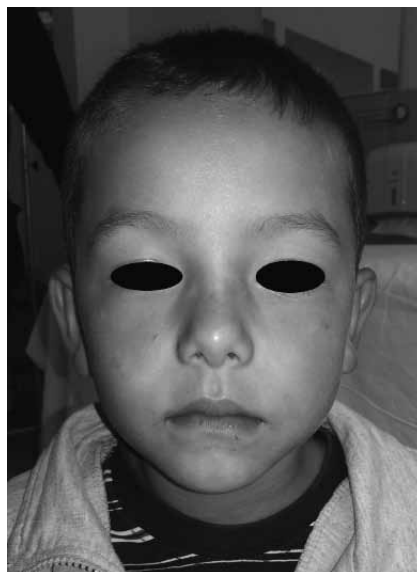

Fig. 4. Patient at five months postoperatively with good functional and aesthetic results.

Under general anaesthesia, excision of scar at the left parotid region was performed. Intralesional injection of two cysts with 20 G needle was performed, followed by aspiration of 7.5 ml and 1 ml of haemorrhagic fluid (infection and intralesional haemorrhage). The dose of bleomycin administered was 1 mg/kg body weight, 8.5 ml in total (15 mg bleomycin dissolved in 15 ml normal saline). After injection, the patient was given a course of antibiotics and analgetics. Postoperatively, side effects were minimal (transient local swelling). Eight months after bleomycin sclerosation, MRI revealed that there was nearly complete regression of LM with single cyst at parotid region 10 mm in size (Fig. 3). The child had no functional symptoms, with good aesthetic appearance (Fig. 4).

### Discussion

Lymphatic malformations are developmental anomalies of the lymphatic system that occur most commonly in the head and neck region followed by axilla and mediastinum<sup>2,3,12</sup>. The precise aetiology of LMs is still unknown<sup>1</sup>. In 50% of cases they are present at birth with 80% to 90% diagnosed within the first two years of life<sup>1,13</sup>. Initially they usually present as a painless, soft mass with wide variations in the growth rate<sup>1,2</sup>. Rapid growth can occur as a result of trauma, intralesional haemorrhage and thrombosis<sup>1</sup>. Spontaneous regression is very rare<sup>13</sup>. The management of LM is challenging because of the infiltrative nature of this lesion especially in the head and neck region<sup>1</sup>. The treatment success of LM depends on the type of the lesion, ana-

tomical location, demarcation and involvement of vital structures. Different treatment modalities for LM have been reported in the literature including surgery, sclerotherapy, laser therapy radiotherapy and radiofrequency ablation<sup>13</sup>. Historically, the primary treatment option for LM was surgical intervention<sup>14-10</sup>. Complete excision of LM is usually not possible<sup>34-12</sup>. Injuries of vital structures, such as facial palsy (up to 33%), recurrence” of a LM, dilatation of persistent anomalous channels secondary to scarring and obstruction, bleeding and other complications can occur after surgical treatment<sup>12</sup>. Our patient had four previous unsuccessful surgical excisions of LM under general anaesthesia at other institutions. There was no documentation explaining these attempts. The child had scars on the left side of the neck and left submandibular region, with facial nerve damage on the left side as a complication. Laser therapy is effective for superficial microcystic malformation, so it was not a treatment option for our patient<sup>1</sup>. Since the anatomical location of LM was extremely unfavourable, and there were several previous unsuccessful attempts at surgical excision, we decided to use a sclerotherapy as a treatment option.

In the past few decades, sclerosing therapy has emerged as a promising alternative to surgical management<sup>2</sup>. Sclerotherapy is the mainstay for treatment of macrocystic LM. Surgery is usually used as complementary therapy<sup>1</sup>. Various sclerosing agents have been tried including ethibloc, corticosteroids, hypertonic glucose solution, sodium morrhuate, doxycycline, quinine, bleomycin and OK-432<sup>12</sup>. Bleomycin is anti-tumour agent, discovered by Umezawa in 1966. Treatment response of lymphomas and testicular tumours established its chemotherapeutic use<sup>5</sup>. Bleomycin has a specific sclerosing effect on vascular endothelium<sup>11</sup>. This effect was successfully therapeutically used by Jura et al. in 1977 for treatment of LM by intralesional bleomycin injection<sup>5-11</sup>. There are several reports of successful treatment of haemangioma and vascular malformations with bleomycin<sup>35-69-11</sup>. The known adverse effects are pulmonary fibrosis, anaphylaxis and hyperpigmentation<sup>9</sup>. The pulmonary manifestation of bleomycin toxicity is dose dependent, and pathogenesis of this effect is not known<sup>7</sup>. Pulmonary fibrosis after intralesional injection of bleomycin has never been reported<sup>12-11</sup>. Our choice for treatment of this patient was bleomycin because it is easy available, inexpensive and has well known effectiveness. A single treatment with bleomycin was sufficient for successful treatment of our patient with negligible side effects. This intervention caused less stress to parents compared to previous treatments, with minimal scarring, and only two days hospitalisation. Eight and a half months of follow-up was unremarkable.

## Conclusions

A number of treatment methods are available for LMs of the head and neck region. Surgical treatment of LMs can be associated with significant morbidity. Intralesional injection of bleomycin has minimal and controllable local and systemic adverse effects. Sclerosation of LMs with bleomycin in our case was highly effective compared to several surgical resections.

## References

- Zhou Q, Zheng JW, Mai HM, et al. *Treatment guidelines of lymphatic malformations of the head and neck*. Oral Oncology 2011;47:1105-9.
- Churchill P, Otal D, Pemberton J, et al. *Sclerotherapy for lymphatic malformations in children: a scoping review*. J Ped Surg 2011;46:912-22.
- Yang Y, Sun M, Ma Q, et al. *Bleomycin A5 sclerotherapy for cervicofacial lymphatic malformations*. J Vasc Surg 2011;53:150-5.
- Perkins JA, Manning SC, Tempero RM, et al. *Lymphatic malformations: review of current treatment*. Otolaryngol Head Neck Surg 2010;142:795-803.
- Muir T, Kirsten M, Fourie P, et al. *Intralesional bleomycin injection (IBI) treatment for haemangiomas and congenital vascular malformations*. Am J Pediatr Surg Int 2004;19:766-73.
- Sung MW, Chang SO, Choi JH, et al. *Bleomycin sclerotherapy in patients with congenital lymphatic malformation in the head and neck*. Am J Otolaryngol 1995;16:236-41.
- Atwa K, Abuhasna S, Shihab Z, et al. *Acute pulmonary toxicity following intralesional administration of bleomycin for a lymphovenous malformation*. Pediatr Pulm 2010;45:192-6.
- Shen CY, Wu MC, Tyan YS, et al. *Preliminary experience of percutaneous intralesional bleomycin injection for the treatment of orbital lymphatic venous malformation refractory to surgery*. Clin. Radiol 2012;67:182-4.
- Karavelioğlu A, Temuçin ÇM, Tanyel FC, et al. *Sclerotherapy with bleomycin does not adversely affect facial nerve function in children with cervicofacial cystic lymphatic malformation*. J Pediatr Surg 2010;45:1627-32.
- Mathur NN, Rana I, Bothra R, et al. *Bleomycin sclerotherapy in congenital lymphatic and vascular malformations of head and neck*. Int J Pediatr Otolaryngol 2005;69:75-80.
- Sainsbury CGD, Kessell G, Fall AJ, et al. *Intralesional bleomycin injection treatment for vascular birthmarks: a 5-year experience at a single United Kingdom Unit*. Plast Reconstr Surg 2011;127:2031-44.
- Pdwa BL, Hayward PG, Ferraro NF, et al. *Cervicofacial lymphatic malformation: clinical course, surgical intervention, and pathogenesis of skeletal hypertrophy*. Plast Reconstr Surg 1995;95:951-60.
- Fliegelman LJ, Friedland D, Brandwein M, et al. *Lymphatic malformation: predictive factor for recurrence*. Otolaryngol Head Neck Surg 2000;123:706-10.

Received: May 23, 2013- Accepted: December 1, 2014

Address for correspondence: Aleksandar Vlahovic, Department of Plastic and Reconstructive Surgery and Burns, Institute for Mother and Child Health Care of Republic Serbia, Radoja Dakica 6-8 street, 11070, New Belgrade, Serbia. E-mail: aleksandarvlahovic@yahoo.com



## In Memoriam of Prof. Andrea Bosatra

Professor Andrea Bosatra passed away peacefully last June. He studied at that incredible scientific research workshop that was the ENT University Clinic of Padova, under the direction of Professor Michele Arslan, and was later and for a long time the Director of the ENT University Clinic in Trieste and of the Schools of Specialisation in ENT and Audio-Phoniatrics. He was Director of the degree course in medicine and Head of the Faculty of Medicine at the University of Trieste from 1987 to 1990. In the last years before his retirement, he took on the role of Director of the Division of Clinical Laryngology and Otology in Treviso (University of Padova).

A learned man, blessed with a lively and inquiring mind, he was gifted with great communication skills and a subtle sense of humour, which earned him the favour and respect of whoever met him, be it colleagues, students, or patients. He was a skilled and neat surgeon, especially in neck surgery and ear microsurgery, a fine researcher mainly in audiology, a brilliant and clear teacher and a skilled organiser of the activities of the Clinic and the schools of specialisation, but not only. Indeed, he distinguished himself for his dedication in assisting his patients. He was extremely precise when attending to them and demanded the same level of care from all staff. He was gifted with a remarkable ability to perceive and understand patients' expectations and fears, which allowed him to form special, enduring relationships with them, based on trust and friendship.

He began his medical studies in 1952 at the ENT Clinic in Padova under the direction of Professor Michele Arslan, the most important man in his life, as Professor Bosatra himself later confessed. Under his guidance, he began his research activity and teaching experience. During the first years of his career, he had very important work experiences, both in Italy and abroad: he worked as a research assistant at the Institute of Laryngology and Otology of the University of London, associated with the Royal National Throat, Nose and Ear Hospital, run by Professor Ormerod in 1955/56. During the same period, in London, he was part of the Otological Research Unit of the Medical Research Council, run by Professor Hallpike. In 1960/61 he worked at the Psychology Institute at the Università Cattolica del Sacro Cuore in Milan and at the connected Phonetics laboratory, which had been founded by Father Gemelli and, in those years, was run by Professor Ancona. In 1969, it was part of the Department of Otolaryngology of Massachusetts General Hospital, run by Professor Schuknecht, and of the Presbyterian Hospital of New York run by Professor Conley. He authored 150 publications on

microscopic anatomy, physiology and pathophysiology of the hearing system, ear and larynx surgical techniques. He conducted special, in-depth research on subjects related to audiology, such as pathophysiology and cochlear semeiotics and central auditory canals, and correlations between the hearing system and phonation. Many of these publications were written with the collaboration of his beloved wife Edith Spiller, professor at the renowned School for Interpreters of the University of Trieste. Regarding oncology, he conducted a massive research – one of the first on the subject – on synchronous and metachronous cancers in upper respiratory and digestive tract neoplasms, which culminated in an international medical congress held in Trieste.

He held conferences and lectures in many countries: at the Karolinska Sjukhuset in Stockholm, at the Universities of Ljubljana, Zagreb, Boston, New York, Copenhagen, Bonn, Oxford, Lyon, Paris, Erlangen and Perth.

He was member of SIO (Italian Association of Otolaryngologists) and SIAF (Italian Association of Audiology and Phoniatrics), the International Society of Physicians in Audiology, the Royal Society of Medicine of London, the American Association for the advancement of Sciences and the New York Academy of Sciences.

In addition to his accomplished scientific carrier, we should also remember Professor Bosatra's human qualities. He deeply loved his family, his wife Edith and their sons Marco, Francesco and Leonardo, and had many passions: sailing, which led him to sail throughout the entire Dalmatian region; fly-fishing, which he perhaps learned in Great Britain, but honed on the Piave river banks; and his city, Asiago, where he had his old family home renovated and where he often took refuge after his retirement. Occasionally, he would share his memories, such as that of his uncle Arturo Ferrarin, an expert aviator during the First World War, who, in 1922, was the first man ever to fly from Rome to Tokyo, where he was welcomed by the Japanese Emperor. He also spoke of his cousin Silvio Ceccato, philosopher, cyberneticist and researcher of mental processes, who probably had a great influence in his psychological training.

Thanks to his personality, Professor Bosatra was worshipped and loved by all the Clinical staff. His charisma was the catalyst that peacefully brought together doctors and interns, who wished to share their experiences and competence spontaneously, and were proud to feel part of a great school and be taught by a great teacher.

*M. Spanio, A. Semeraro*

# Calendar of events – Italian and International Meetings and Courses

Acta Otorhinolaryngol Ital 2015;35:369-370

Information, following the style of the present list, should be submitted to the Editorial Secretariat of Acta Otorhinolaryngologica Italica (actaitalicaorl@rm.unicatt.it).

**In accordance with the Regulations of S.I.O. and Ch.C.-F. (Art. 8) Members of the Society organising Courses, Congresses or other scientific events should inform the Secretary of the Association (A.U.O.R.L., A.O.O.I.) within the deadlines set down in the respective Statutes and Regulations.**

## OCTOBER-DECEMBER 2015

### INTERNATIONAL WORKSHOP “OPEN PARTIAL HORIZONTAL LARYNGECTOMIES (OPHL) VERSUS TRANSORAL LASER MICROSURGERY (TLM) IN LARYNX CANCER”

*October 8-10, 2015 • Castel Brando (TV) – Italy*

Chairman: G. Rizzotto – Email: mail@nordestcongressi.it – Websites: www.nordestcongressi.it, www.oncolarynx.it

### XXXIX CONVEGNO NAZIONALE AOOI (ASSOCIAZIONE OTORINOLARINGOLOGI OSPEDALIERI ITALIANI) • *October 16-17, 2015 • Genova – Italy*

President: Felice Scasso – E-mail: nec@nordestcongressi.it – Website: www.nordestcongressi.it

### 7<sup>th</sup> INTERNATIONAL SYMPOSIUM ON MENIERE’S DISEASE AND INNER EAR DISORDERS

*October 17-20, 2015 • Rome – Italy*

Website: meniere2015.eu

### VII INTERNATIONAL SYMPOSIUM ON RECENT ADVANCES IN RHINOSINUSITIS AND NASAL POLYPOSIS

*October 22-25, 2015 • Panama*

Information: congresors2015@gmail.com

### SESTO CONGRESSO NAZIONALE AICEF RCF • *October 23-24, 2015 • Rome – Italy*

Chairmen: Fabrizio Ottaviani, Gaetano Paludetti and Pier Giorgio Giacomini – Scientific Secretariat: pggiacomini@tiscali.it. Tel. +39 049 8601818 – Fax +39 0498602389

### CURSO DE DISECCIÓN ENDOSCÓPICA DE LOS SENOS PARANASALES ENDOSCOPIC SINUS SURGICAL DISSECTION COURSE N. 49

*October 29-31, 2015 • Barcelona – Spain*

Info: Sra. Isabel – Tel. 93 205 02 04 – Fax 93 205 43 67 –E-mail: fundacion@iogi.org

### 3<sup>rd</sup> VIS (SOCIETÀ ITALIANA DI VESTIBOLOGIA) CONGRESS • *October 30-31, 2015 • Modena – Italy*

Website: www.vestibologyitaliansociety.com

### SIOP (SOCIETÀ ITALIANA DI OTORINOLARINGOIATRIA PEDIATRICA) NATIONAL CONGRESS

*November 5-7, 2015 • Rome – Italy*

E-mail: info@formazioneeventisrl.it – Website: www.formazioneeventisrl.it

### CURSO DE MICROCIRUGÍA DEL OÍDO Y DISECCIÓN DEL HUESO TEMPORAL TEMPORAL BONE SURGICAL DISSECTION COURSE N. 118 • *November 18-20, 2015 • Barcelona – Spain*

Info: Sra. Conchi Castilla – Tel. 93 205 02 04 – Fax 93 205 43 67 – E-mail: entsecretaria@hotmail.es, info@iogi.org

**XXXV CONGRESSO NAZIONALE SIAF – AGGIORNAMENTI IN AUDIOLOGIA INFANTILE****December 16-18, 2015 • Milan – Italy**Chairman: Antonio Cesarani – Website: [www.sia-f.it](http://www.sia-f.it)**JANUARY-DECEMBER 2016****CORSO DI DISSEZIONE OTOLOGICA, OTONEUROLOGICA e IMPLANTOLOGIA Uditiva****January 5-7, 2016 • Paris – France**Course Directors: Olivier Sterkers, Daniele Bernardeschi. Info: [daniele.bernardeschi@aphp.fr](mailto:daniele.bernardeschi@aphp.fr)**INFLAMMATION – WINTER SYMPOSIUM • January 24-27, 2016 • Miami – USA**Directors: Sylvia Daunert, Angelo Azzi, Joseph Kissil, Stephen Nimer, Claes Wahlestedt, William J. Whelan – Website: [www.miamiwintersymposium.com](http://www.miamiwintersymposium.com)**6° CONGRESSO NAZIONALE CO.R.TE. • March 10-12, 2016 • Rome – Italy**President: Nicolò Scuderi – Tel. +39 06 35497114 – E-mail: [corte@jaka.it](mailto:corte@jaka.it)**VI INTERNATIONAL WORKSHOP ON ENDOSCOPIC EAR SURGERY****April 7-9, 2016 • Modena and Verona – Italy**Course Directors: Livio Presutti and Daniele Marchioni – E-mail: [Italy-ear-surgery@hotmail.com](mailto:Italy-ear-surgery@hotmail.com) – Website: [www.nordestcongressi.it](http://www.nordestcongressi.it)**7<sup>th</sup> INTERNATIONAL SYMPOSIUM ON SENTINEL NODE BIOPSY IN HEAD AND NECK CANCER****April 8-9, 2016 • Rome - Italy**Organised by: M.G. Vigili and G. Tartaglione – Website: [www.seventhsnb.com](http://www.seventhsnb.com)**15<sup>th</sup> INTERNATIONAL MEETING OF THE MEDITERRANEAN SOCIETY OF OTOLGY AND AUDIOLOGY****April 28-30, 2016 • Cappadocia – Turkey**President: S. Armagan Incesulu – Website: [www.msoa2016.org](http://www.msoa2016.org)**ENDOCHICAGO 7<sup>th</sup> WORLD CONGRESS FOR ENDOSCOPIC SURGERY OF THE SKULL BASE AND BRAIN • May 15-18, 2016 • Chicago (IL) – USA**Course Directors: Amin B. Kassam, Martin Corsten, Ricardo L. Carrau, Daniel M. Prevedello, Vijay Anand, Theodore H. Schwartz – Website: [www.endoworld.org/d-1\\_7TH\\_WORLD\\_CONGRESS](http://www.endoworld.org/d-1_7TH_WORLD_CONGRESS)**103° CONGRESSO NAZIONALE SIO SOCIETA ITALIANA DI OTORINOLARINGOLOGIA E CHIRURGIA CERVICO-FACCIALE • May 25-28, 2016 • Rome – Italy**President: Roberto Filipo – Website: [www.sioechcf.it](http://www.sioechcf.it)**HEAL (HEARING ACROSS THE LIFESPAN): “EARLY INTERVENTION: THE KEY TO BETTER HEARING CARE” • June 2-4, 2016 • Lake Como – Italy**Website: [www.heal2016.org](http://www.heal2016.org) – E-mail: [meet@meetandwork.com](mailto:meet@meetandwork.com) – Tel. +39 049 8601818 – Fax +39 0498602389**CORSO PRATICO DI ANATOMIA CHIRURGICA E DISSEZIONE SPERIMENTALE OTOLOGICA 2° LIVELLO - XXVII EDIZIONE • June 6-10, 2016 • Sanremo (IM) – Italy**

A cura di: A. Tombolini, F. Baricalla – Coordinato da: A. Tombolini

**26<sup>th</sup> CONGRESS OF THE EUROPEAN RHINOLOGIC AND THE 35<sup>TH</sup> INTERNATIONAL SYMPOSIUM OF INFECTION AND ALLERGY OF THE NOSE & 17<sup>th</sup> CONGRESS OF THE INTERNATIONAL RHINOLOGIC SOCIETY (ERS 2016) • July 3-7, 2016 • Stockholm – Sweden**President: Pär Stjärne – Website: [www.ers-isian2016.com](http://www.ers-isian2016.com)**INSTRUCTIONAL WORKSHOP EUROPEAN ACADEMY OF OTOLGY AND NEURO-OTOLGY September 28 - October 1, 2016 • İzmir, Turkey**President: O. Nuri Ozgirgin – Website: [www.eaono.org](http://www.eaono.org)