

## Interstitial Lung Diseases

RSPT 2310

## Pneumoconiosis

- Interstitial lung disease refers to a broad group of inflammatory lung disorders (ILD)
  - AKA pneumoconiosis, diffuse interstitial lung disease, fibrotic interstitial lung disease, pulmonary fibrosis
- Includes more than 180 disease entities characterized by acute, sub-acute, or chronic inflammatory infiltration of alveolar walls by cells, fluid, and connective tissue

## Pneumoconiosis

- If left untreated, the inflammatory process can progress to irreversible pulmonary fibrosis
- The ILD group comprises a wide-range of illnesses with varied causes, treatments, and prognoses
- ILDs all reflect similar anatomic alterations of the lungs and cardiopulmonary clinical manifestations

## Pneumoconiosis

- Normally pneumoconiosis is a restrictive disease
- Obstruction can occur with accumulation of dust and
- Particulate matter in small airways which may produce:
  - Chronic inflammation
  - Swelling
  - Bronchial obstruction

## Anatomic Alterations of the Lungs

- Destruction of alveoli and adjacent pulmonary capillaries
- Fibrotic thickening of resp. bronchioles, alveolar ducts, and alveoli
- Granulomas
- Honeycombing and cavity formation
- Fibrocalcific pleural plaques (asbestosis)

## Anatomic Alterations of the Lungs


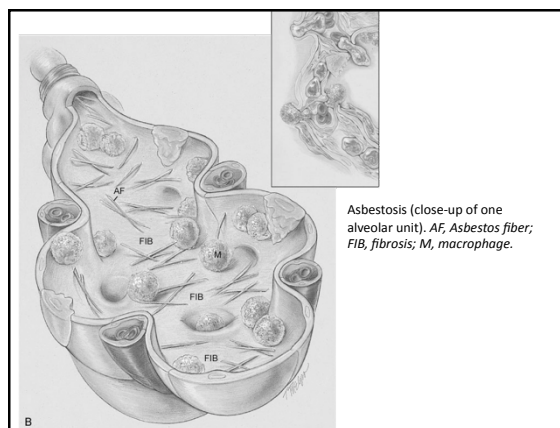
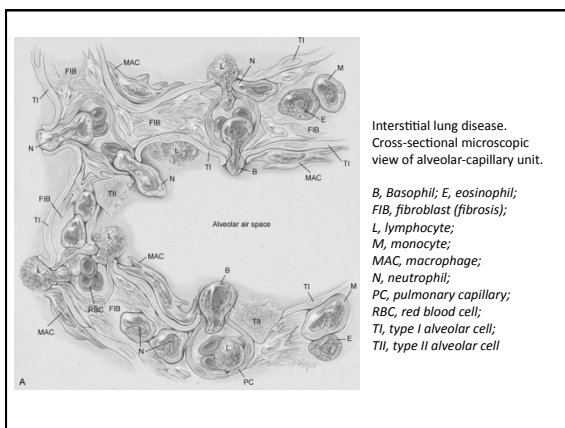
- Bronchospasm
- Airway obstruction caused by inflammation and bronchial constriction
- Bronchial carcinoma
- Mesothelioma (asbestosis)

### Anatomic Alterations of the Lungs

- Normally pneumoconiosis is a *restrictive* disease
- **Obstruction** can occur with accumulation of dust and particulate matter in small airways which may produce:
  - Chronic inflammation
  - Swelling
  - Bronchial obstruction

### Anatomic Alterations of the Lungs

- Severity depends on
  - The size of the inhaled particles (0.3 - 0.5  $\mu\text{m}$ )
  - Chemical nature of inhaled particle
  - Concentration
  - Length of exposure
  - Individual susceptibility



### Etiology

Occupational, Environmental and Therapeutic Exposures

Inorganic Particulate (dust) Exposure

## Asbestos

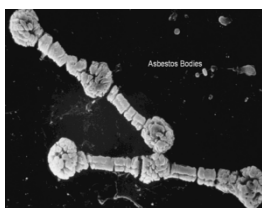- Asbestosis
  - A common form of ILD
  - Asbestos fibers are a mixture of fibrous minerals composed of hydrous silicates of magnesium, sodium, and iron in various proportions
  - There are two primary types
    - Amphiboles (crocidolite, amosite, and anthophyllite)
    - Chrysotile (most commonly used in industry)
  - Asbestos fibers typically range from 50 to 100  $\mu\text{m}$  in length and are about 0.5  $\mu\text{m}$  in diameter
    - The chrysotiles have the longest and strongest fibers.

## Asbestos

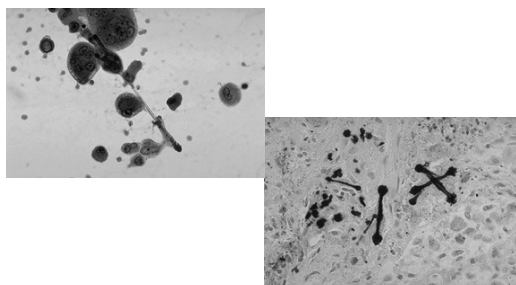
Common Sources of Asbestos Fibers	
Acoustic products	Firefighting suits
Automobile undercoating	Fireproof paints
Brake lining	Insulation
Cements	Roofing materials
Clutch casings	Ropes
Floor tiles	Steam pipe material

## Asbestos

- Asbestos fibers can be seen by microscope within the thickened septa as brown or orange baton-like structures
  - The fibers characteristically stain for iron with Perl's stain
- The pathologic process may affect only one lung, a lobe, or a segment of a lobe
  - The lower lobes are most commonly affected
- Pleural calcification is common and diagnostic in patients with an asbestos exposure history



## Asbestos



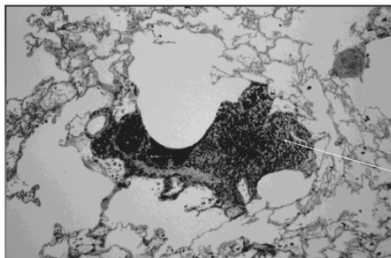
## Coal Dust

- Coal Worker's Pneumoconiosis (CWP)
  - The pulmonary deposition and accumulation of large amounts of coal dust
  - Also known as coal miner's lung and black lung
  - Miners who use cutting machines at the coal face have the greatest exposure, but even relatively minor exposures may result in the disease
  - Indeed, cases have been reported in which coal miners' wives developed the disease, presumably from shaking the dust from their husbands' work clothes

## Coal Dust

- Simple CWP
  - Characterized by the presence of pinpoint nodules called coal macules (black spots) throughout the lungs
  - The coal macules often develop around the first- and second-generation respiratory bronchioles and cause the adjacent alveoli to retract
- This condition is called focal emphysema

## Coal Dust

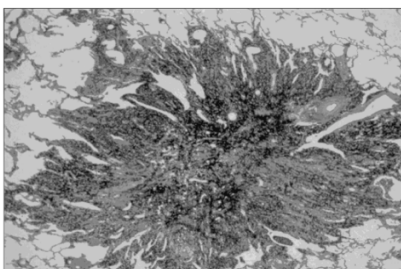


Coal dust  
macule

## Coal Dust

- Complicated CWP or progressive massive fibrosis (PMF)
  - Characterized by areas of fibrotic nodules greater than 1 cm in diameter
  - Nodules generally appear in the peripheral regions of upper lobes and extend toward the hilum with growth
    - Composed of dense collagenous tissue with black pigmentation
- Coal dust by itself is chemically inert
  - The fibrotic changes in CWP are usually caused by silica

## Coal Dust

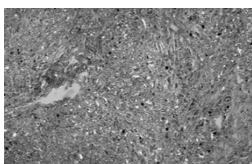


Coal dust  
nodule

## Silica

- Silicosis (grinder's disease or quartz silicosis)
  - Caused by the chronic inhalation of crystalline, free silica, or silicon dioxide particles
  - Silica is the main component of more than 95% of the rocks of the earth
  - It is found in sandstone, quartz (beach sand is mostly quartz), flint, granite, many hard rocks, and some clays

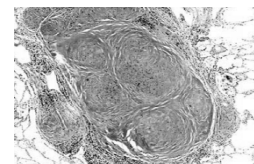
## Silica



- Simple silicosis
  - Characterized by small rounded nodules scattered throughout the lungs
  - No single nodule is greater than 9 mm in diameter
  - Patients with simple silicosis are usually symptom-free

## Silica

- Complicated silicosis
  - Characterized by nodules that coalesce and form large masses of fibrous tissue, usually in the upper lobes and perihilar regions
  - In severe cases the fibrotic regions may undergo tissue necrosis and cavitate



## Silica

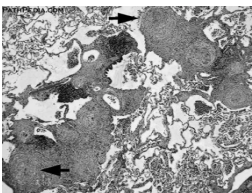
### Common Occupations Associated with Silica Exposure

Tunneling	Abrasives work
Hard-rock mining	Brick making
Sandblasting	Paint making
Quarrying	Polishing
Stonecutting	Stone drilling
Foundry work	Well drilling
Ceramics work	

## Beryllium

- Beryllium
  - A steel-gray, lightweight metal found in certain plastics and ceramics, rocket fuels, and x-ray tubes
  - Not hazardous as raw ore
  - Processed into the pure metal or one of its salts, however, it may cause a tissue reaction when inhaled or implanted into the skin

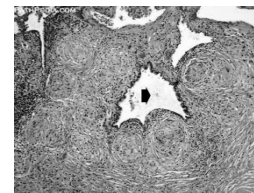
## Beryllium



- The acute inhalation of beryllium fumes or particles may cause a toxic or allergic pneumonitis
  - Sometimes accompanied by rhinitis, pharyngitis, and tracheobronchitis

## Beryllium

- The more complex form of berylliosis
  - Characterized by the development of granulomas and a diffuse interstitial inflammatory reaction



## Additional Inorganic Causes of Interstitial Lung Disease

- Aluminum
  - Ammunition workers
- Baritosis (barium)
  - Barite millers and miners
  - Ceramics workers
- Kaolinosis (clay)
  - Brick makers and potters
  - Ceramics workers
- Siderosis (iron)
  - Welders
- Talcosis (certain talcs)
  - Ceramics workers
  - Papermakers
  - Plastics and rubber workers

## Etiology

Organic Materials Exposure

## Organic Materials Exposure

- Hypersensitivity pneumonitis
  - Also called allergic alveolitis or extrinsic allergic alveolitis) is a cell-mediated immune response of the lungs caused by the inhalation of a variety of offending agents or antigens
  - Such antigens include grains, silage, bird droppings or feathers, wood dust (especially redwood and maple), cork dust, animal pelts, coffee beans, fish meal, mushroom compost, and molds that grow on sugar cane, barley, and straw.

## Organic Materials Exposure

- Hypersensitivity pneumonitis
  - The immune response to these allergens causes production of antibody and an inflammatory response
  - The lung inflammation, or pneumonitis, develops after repeated and prolonged exposure to the allergen
    - The term hypersensitivity pneumonitis (or allergic alveolitis) is often renamed according to the type of exposure that caused the lung disorder
    - For example, the hypersensitivity pneumonitis caused by the inhalation of moldy hay is called farmer's lung

Antigen	Exposure Source	Disease (Syndrome)
<b>Bacteria, Thermophilic:</b>		
<i>Saccharomyces castellii</i>	Moldy hay, silage	Farmer's lung
<i>Thermoactinomyces vulgaris</i>	Moldy sugarcane	Bagassosis
<i>Thermoactinomyces sacchari</i>	Mushroom compost	Mushroom worker's lung
<i>Thermoactinomyces vesiculosus</i>	Heated water reservoirs	Air conditioner lung
<b>Bacteria, Nonthermophilic:</b>		
<i>Bacillus subtilis</i> , <i>Bacillus cereus</i>	Water, detergent	Humidifier lung, washing powder lung
<b>Fungi</b>		
Aspergillus species	Moldy hay	Farmer's lung
Aspergillus chrysogani	Water	Ventilation pneumonitis
Aspergillus fumigatus	Barley	Mill worker's lung
Penicillium casei	Cheese	Cheese worker's lung
Penicillium raoultii?		
Alternaria species	Wood pulp	Woodworker's lung
Campylobacter concinnus	Wood bark	Maple bark stripper's lung
<i>Coccidioides immitis</i> , <i>Coccidioides posadasii</i>	Wood dust	Sequelosis
<i>Mucor</i> species	Rotting wood	Dry rot lung
<i>Penicillium brevicornis</i>	Cork dust	Suberosis
<i>Aspergillus fumigatus</i>	Water	Humidifier lung
<i>Clostridium botulinum</i>	Hot tub mist	Hot tub HP?
<i>Thalassiosira weissflogii</i>	Damp wood and mud	Japanese summer-type HP?
<b>Animals</b>		
<i>Neisseria proteus</i>	Contaminated water	Humidifier lung
<i>Acetabacterium poeppigii</i>	Contaminated water	Humidifier lung
<i>Acetabacterium casei</i>	Contaminated water	Humidifier lung
<b>Animal Proteins</b>		
Avian proteins	Bird droppings, feathers	Bird breeder's lung
Urine, serum, pelts	Furs, gerbils	Animal handler's lung
<b>Chemicals</b>		
Isocyanates, trimethylolpropane diisocyanate	Paints, resins, plastics	Chemical worker's lung
Copper sulfate	Bordeaux mixture	Vineyard sprayer's lung
Hydrochloric acid	Heated epoxy resin	epoxy resin lung
Sodium diacetarsenate sulfate	Chromatography reagent	Paul's reagent alveolitis
Pyridium	Pesticide	Pyridium HP?

From Schuman M. Hypersensitivity pneumonitis. In Schwartz ML, Kim TL, eds. Interstitial lung disease. ed 4. Hamilton, 2003. WJ Decker.

© 1997, Hypersensitivity pneumonitis.

## Organic Materials Exposure

- Medications and illicit drugs
  - As the number of medications and illicit drugs continues to grow, so does the list of possible side effects
  - The lungs are major target organs affected by these side effects
  - Impossible to discuss in detail the various lung-related side effects of every drug

## Organic Materials Exposure

- Medications and illicit drugs
  - The chemotherapeutic (anticancer agents) are by far the largest group of agents associated with ILD
  - Nitrofurantoin – antibacterial for UTIs
  - Gold and penicillamine – rheumatoid arthritis
  - Excessive long-term administration of oxygen

## Organic Materials Exposure

- Medications and illicit drugs
  - As a general rule, the risk of these drugs causing an interstitial lung disorder is directly related to the cumulative dosage
    - Drug-induced interstitial disease may be seen as early as 1 month to as late as several years after exposure to these agents
  - The precise cause of drug-induced ILD is not known
    - Diagnosis is confirmed by an open lung biopsy
    - When interstitial fibrosis is found with no infectious organisms, a drug-induced interstitial process must be suspected

## Organic Materials Exposure

- Radiation Therapy
  - Radiation therapy in the management of cancer may cause ILD
  - Radiation-induced lung disease is commonly divided into the following two major phases
    - the acute pneumonitic phase
    - the late fibrotic phase
  - Acute pneumonitis rarely is seen in patients who receive a total radiation dose of less than 3500 rad

## Organic Materials Exposure

- Radiation Therapy
  - Doses in excess of 6000 rad over 6 weeks almost always cause ILD in and near the radiated areas
  - The acute pneumonitic phase develops approximately 2 to 3 months after exposure
  - Chronic radiation fibrosis is seen in all patients who develop acute pneumonitis

## Organic Materials Exposure

- Radiation Therapy
  - The late phase of fibrosis may develop
    - immediately after the development of acute pneumonitis
    - without an acute pneumonitic period, or
    - after a symptom-free latent period
  - When fibrosis does develop, it generally does so 6 to 12 months after radiation exposure
    - Pleural effusion often is associated with the late fibrotic phase.

## Organic Materials Exposure

- Irritant Gases
  - The inhalation of irritant gases may cause an acute chemical pneumonitis and, in severe cases, ILD
  - Most exposures occur in an industrial setting

## Organic Materials Exposure

Gas	Industrial setting
Chlorine	Chemical and plastic industries; water disinfection
Ammonia	Commercial refrigeration; smelting of sulfide ores
Ozone	Welding
Nitrogen dioxide	May be liberated after exposure of nitric acid to air
Phosgene	Used in the production of aniline dyes

## Systemic Diseases

- Scleroderma
  - Characterized by chronic hardening and thickening of the skin caused by new collagen formation
    - May occur in a localized form or as a systemic disorder (called systemic sclerosis)
  - Progressive systemic sclerosis (PSS) is a relatively rare autoimmune disorder that affects the blood vessels and connective tissue
    - Causes fibrous degeneration of the connective tissue of the skin, lungs, and internal organs, especially the esophagus, digestive

## Systemic Diseases

- Scleroderma
  - Scleroderma of the lung appears as ILD and fibrosis
    - Of all the collagen vascular disorders, scleroderma is the one in which pulmonary involvement is most severe and most likely to cause significant scarring of the lung parenchyma
    - Complications include diffuse interstitial fibrosis, severe pulmonary hypertension, pleural disease, and aspiration pneumonitis
    - May also involve the small pulmonary blood vessels and appears to be independent of the fibrotic process involving the alveolar walls
    - The disease most commonly is seen in women 30 to 50 years of age

## Systemic Diseases

- Rheumatoid arthritis
  - primarily an inflammatory joint disease
  - May involve the lungs in the form of
    - Pleurisy, with or without effusion
    - Interstitial pneumonitis
    - Necrobiotic nodules, with or without cavities
    - Caplan's syndrome
    - Pulmonary hypertension secondary to pulmonary vasculitis

## Systemic Diseases

- Systemic Lupus Erythematosus
  - Multisystem disorder that mainly involves the joints and skin
  - May cause serious problems in numerous other organs, including the kidneys, lungs, nervous system, and heart
  - Involvement of the lungs appears in about 50% to 70% of the cases

## Systemic Diseases

- Systemic Lupus Erythematosus
  - Pulmonary manifestations are characterized by
    - Pleurisy with or without effusion
    - Atelectasis
    - Diffuse infiltrates and pneumonitis
    - Diffuse ILD
    - Uremic pulmonary edema
    - Diaphragmatic dysfunction
    - Infection

## Systemic Diseases

- Sarcoidosis
  - Chronic disorder of unknown origin characterized by the formation of tubercles of nonnecrotizing epithelioid tissue
  - Common sites are the lungs, spleen, liver, skin, mucous membranes, and lacrimal and salivary glands, usually with the involvement of the lymph glands

## Systemic Diseases

- Sarcoidosis
  - The lung is the most frequently affected organ, with manifestations generally including ILD, enlargement of the mediastinal lymph nodes, or a combination of both
  - One of the clinical hallmarks of sarcoidosis is an increase in all three major immunoglobulins (IgM, IgG, and IgA)



### Systemic Diseases

- Sarcoidosis
  - More common among African-Americans and appears most frequently in patients 10 to 40 years of age, with the highest incidence at 20 to 30 years of age
  - Women are affected more often than men, especially among African-Americans

### Systemic Diseases

- Idiopathic Interstitial Pneumonia
  - Many patients with ILD do not have a readily identified specific exposure, a systemic disorder, or an underlying genetic cause
  - Such instances of ILD are commonly placed in the idiopathic interstitial pneumonia (IIP) group or the group with specific pathology

### Systemic Diseases

- Idiopathic Pulmonary Fibrosis
  - Progressive inflammatory disease with varying degrees of fibrosis and, in severe cases, honeycombing
  - Precise cause is unknown
  - AKA acute interstitial fibrosis of the lung, cryptogenic fibrosing alveolitis, Hamman-Rich syndrome, honeycomb lung, interstitial fibrosis, and interstitial pneumonitis

### Systemic Diseases

- Pulmonary Alveolar Proteinosis
  - Condition of unknown cause in which the alveoli become filled with protein and lipids similar pulmonary surfactant
  - Alveolar macrophages generally are dysfunctional in this disorder
  - The disease most commonly is seen in adults 20 to 50 years of age
  - Men are affected twice as often as women

### Diffuse Interstitial Lung Diseases

- Goodpasture's Syndrome
  - Disease of unknown cause that involves two organ systems—the lungs and the kidneys
    - In the lungs there are recurrent episodes of pulmonary hemorrhage and in some cases pulmonary fibrosis, presumably as a consequence of the bleeding episodes
    - In the kidneys there is a glomerulonephritis characterized by the infiltration of antibodies within the glomerular basement membrane (GBM)

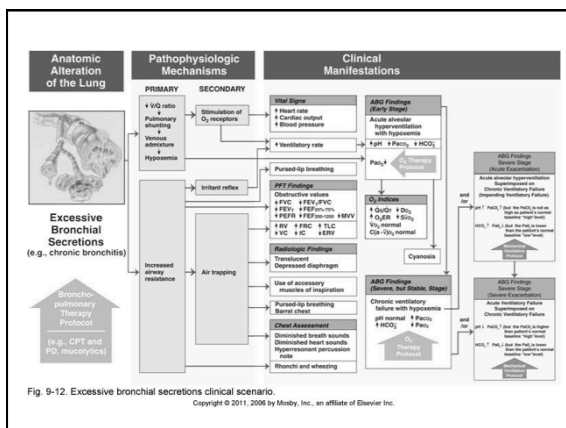
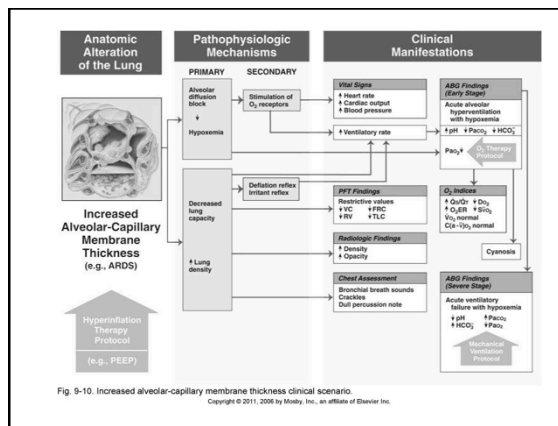
### Diffuse Interstitial Lung Diseases

- Goodpasture's Syndrome
  - Usually is seen in young adults
  - Average survival period after diagnosis is about 15 weeks
  - About 50% of the patients die from massive pulmonary hemorrhage, and about 50% die from chronic renal failure

Overview of the Cardiopulmonary Clinical Manifestations Associated with Interstitial Lung Diseases

The following clinical manifestations result from the pathophysiologic mechanisms caused (or activated) by

- Increased Alveolar-Capillary Membrane Thickness
- Excessive Bronchial Secretions



Clinical Data Obtained at the Patient's Bedside

The Physical Examination

- Vital Signs
  - Increased
    - Respiratory rate (tachypnea)
    - Heart rate (pulse)
    - Blood pressure

The Physical Examination

- Cyanosis
- Digital clubbing
- Peripheral edema and venous distension
  - Distended neck veins
  - Pitting edema
  - Enlarged and tender liver

### The Physical Examination

- Nonproductive cough
- Chest Assessment Findings
  - > Increased tactile and vocal fremitus
  - > Dull percussion note
  - > Bronchial breath sounds
  - > Crackles, rhonchi
  - > Pleural friction rub
  - > Whispered pectoriloquy

### Clinical Data Obtained from Laboratory Tests and Special Procedures

### Pulmonary Function Test Findings

Moderate to Severe ILD  
(Restrictive Lung Pathophysiology)

#### Forced Expiratory Flow Rate Findings

<b>FVC</b>	<b>FEV<sub>T</sub></b>	<b>FEV<sub>1</sub>/FVC ratio</b>	<b>FEF<sub>25%-75%</sub></b>
↓	N or ↓	N or ↑	N or ↓
<b>FEF<sub>50%</sub></b>	<b>FEF<sub>200-1200</sub></b>	<b>PEFR</b>	<b>MVV</b>
N or ↓	N or ↓	N or ↓	N or ↓

### Pulmonary Function Test Findings

Moderate to Severe ILD  
(Restrictive Lung Pathophysiology)

#### Lung Volume & Capacity Findings

<b>VT</b>	<b>IRV</b>	<b>ERV</b>	<b>RV</b>	<b>VC</b>
N or ↓	↓	↓	↓	↓
<b>IC</b>	<b>FRC</b>	<b>TLC</b>	<b>RV/TLC ratio</b>	
↓	↓	↓	N	

### Decreased Diffusion Capacity

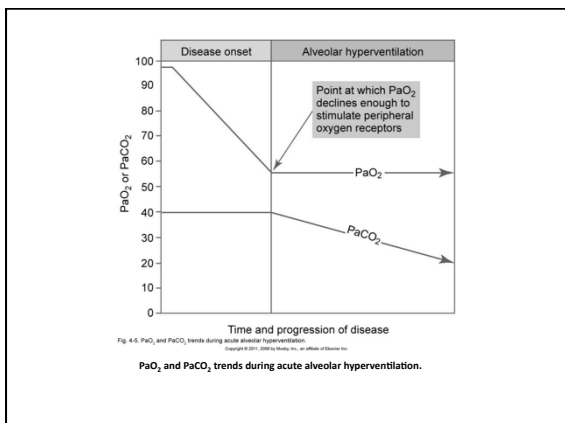
- There is an exception to the expected decreased diffusion capacity in the following two interstitial lung diseases:
  - Goodpasture's syndrome
  - Idiopathic pulmonary hemosiderosis
- The DL<sub>CO</sub> is often elevated in response to the increased amount of blood retained in the alveolar spaces that is associated with these two disorders.

### Arterial Blood Gases

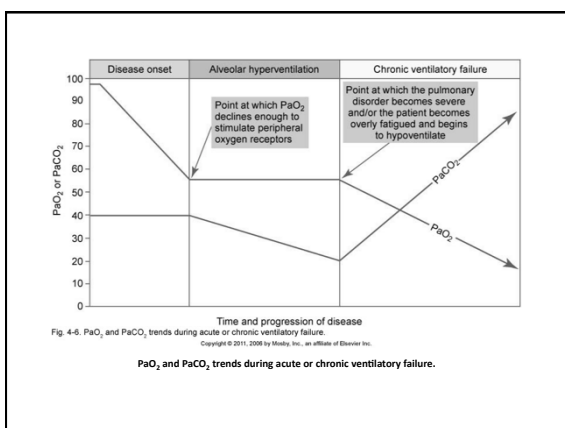
Mild to Moderate ILD

Acute Alveolar Hyperventilation with Hypoxemia  
(Interpretation?)

<b>pH</b>	<b>PaCO<sub>2</sub></b>	<b>HCO<sub>3</sub></b>	<b>PaO<sub>2</sub></b>
↑	↓	↓ (slightly)	↓



Arterial Blood Gases Severe chronic ILD			
Chronic Ventilatory Failure with Hypoxemia (Interpretation?)			
<b>pH</b>	<b>PaCO<sub>2</sub></b>	<b>HCO<sub>3</sub></b>	<b>PaO<sub>2</sub></b>
<b>N</b>	<b>↑</b>	<b>↑ (Significantly)</b>	<b>↓</b>




Arterial Blood Gases
Acute Ventilatory Changes Superimposed On Chronic Ventilatory Failure
<ul style="list-style-type: none"> <li>Because acute ventilatory changes are frequently seen in patients with chronic ventilatory failure, the respiratory care practitioner must be familiar with and alert for the following:                             <ul style="list-style-type: none"> <li>Acute alveolar hyperventilation superimposed on chronic ventilatory failure</li> <li>Acute ventilatory failure (acute hypoventilation) superimposed on chronic ventilatory failure</li> </ul> </li> </ul>

Oxygenation Indices Moderate to Severe Stage ILD					
<b>Q<sub>S</sub>/Q<sub>T</sub></b>	<b>DO<sub>2</sub></b>	<b>VO<sub>2</sub></b>	<b>C(a-v)O<sub>2</sub></b>	<b>O<sub>2</sub>ER</b>	<b>SvO<sub>2</sub></b>
<b>↑</b>	<b>↓</b>	<b>N</b>	<b>N</b>	<b>↑</b>	<b>↓</b>

Hemodynamic Indices Severe ILD					
<b>CVP</b>	<b>RAP</b>	<b>PA</b>	<b>PCWP</b>	<b>CO</b>	<b>SV</b>
<b>↑</b>	<b>↑</b>	<b>↑</b>	<b>N</b>	<b>N</b>	<b>N</b>
<b>SVI</b>	<b>CI</b>	<b>RVSWI</b>	<b>LVSWI</b>	<b>PVR</b>	<b>SVR</b>
<b>N</b>	<b>N</b>	<b>↑</b>	<b>N</b>	<b>↑</b>	<b>N</b>

<h3>Abnormal Laboratory Tests and Procedures</h3>
<ul style="list-style-type: none"> <li>● Hematology             <ul style="list-style-type: none"> <li>➢ Increased hematocrit and hemoglobin (polycythemia)</li> </ul> </li> </ul>


<h3>Radiologic Findings</h3>
<ul style="list-style-type: none"> <li>● Chest Radiograph             <ul style="list-style-type: none"> <li>➢ Bilateral reticulonodular pattern</li> <li>➢ Irregularly shaped opacities</li> <li>➢ Granulomas</li> <li>➢ Cavity formation</li> <li>➢ Honeycombing</li> <li>➢ Pleural effusion</li> </ul> </li> </ul>



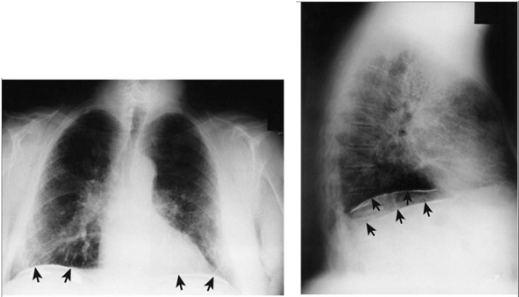
From Rosalind DM, Aronow P, Lurie DA, Nishimura RP, eds. *Imaging of disease of the chest*, ed 4. Philadelphia, 2005, Elsevier.

Fig. 25.2. Reticulonodular pattern of interstitial pulmonary fibrosis in a patient with scleroderma.

**Reticulonodular pattern of interstitial pulmonary fibrosis in a patient with scleroderma.**



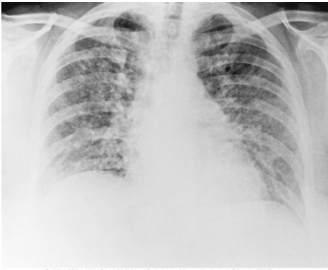
**Chest x-ray film of a patient with asbestosis.**



From Rosalind DM, Aronow P, Lurie DA, Nishimura RP, eds. *Imaging of disease of the chest*, ed 4. Philadelphia, 2005, Elsevier.

Fig. 25.5. Acute farmer's lung. Chest radiograph shows diffuse parenchymal ground-glass pattern with some areas of consolidation. The severity of parenchymal opacification in this case is unusual.

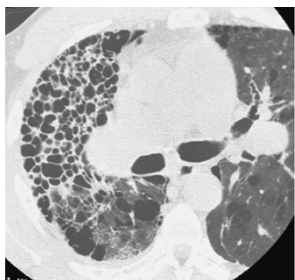
Calcified pleural plaques on the superior border of the diaphragm (arrows) in a patient with asbestosis. Thickening of the pleural margins also is seen along the lower lateral borders of the chest. A, Anteroposterior view. B, Lateral view.



From Rosalind DM, Aronow P, Lurie DA, Nishimura RP, eds. *Imaging of disease of the chest*, ed 4. Philadelphia, 2005, Elsevier.

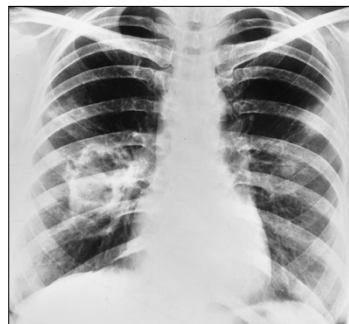
Fig. 25.5. Acute farmer's lung. Chest radiograph shows diffuse parenchymal ground-glass pattern with some areas of consolidation. The severity of parenchymal opacification in this case is unusual.

Acute farmer's lung. Chest radiograph shows diffuse parenchymal ground-glass pattern with some areas of consolidation. The severity of parenchymal opacification in this case is unusual.



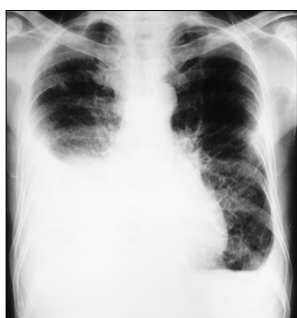From Henschke CH, Hwang JF, Lanza DA, Winkler M. The impact of treatment of the chest with a Pilonidal and Bariatric.  
 Fig. 204 Honeycomb cysts in sarcoidosis. HRCT through the right midlung shows profuse clustered honeycomb cysts. The cysts are larger than the typical honeycomb cysts seen in usual interstitial pneumonia. Cysts are much less extensive in the left lung.

Honeycomb cysts in sarcoidosis. HRCT through the right midlung shows profuse clustered honeycomb cysts. The cysts are larger than the typical honeycomb cysts seen in usual interstitial pneumonia. Cysts are much less extensive in the left lung.



Wegener's granulomatosis. Numerous nodules with a large (6-cm) cavitary lesion adjacent to the right hilus. Its walls are thick and irregular.

Wegener's granulomatosis. Numerous nodules with a large (6-cm) cavitary lesion adjacent to the right hilus. Its walls are thick and irregular.



Pleural effusion in rheumatoid disease. Bilateral pleural effusions are present with mild changes of fibrosing alveolitis. The effusions were painless, and the one on the right had been present, more or less unchanged, for 5 months. Note the bilateral "meniscus signs."

Pleural effusion in rheumatoid disease. Bilateral pleural effusions are present with mild changes of fibrosing alveolitis. The effusions were painless, and the one on the right had been present, more or less unchanged, for 5 months. Note the bilateral "meniscus signs."

## General Management of ILD

- Oxygen Therapy Protocol
- Bronchopulmonary Hygiene Therapy Protocol
- Mechanical Ventilation Protocol

## General Management of ILD

- Plasmapheresis
  - Treatment of Goodpasture's syndrome is directed at reducing the circulating anti-GBM antibodies that attack the patient's glomerular basement membrane
  - Plasmapheresis, which directly removes the anti-GBM antibodies from the circulation, has been of some benefit