

What is the normal range of motion for hip flexion in adults?

- A) 0–180 degrees
- B) 45–90 degrees
- C) 0–30 degrees
- D) 0–120 degrees

- Zero starting position is the thigh in line with the trunk.
- In measuring hip extension, the contralateral limb should be held in flexion to eliminate lumbar spine motion.
- Hip flexion is typically measured by bringing both thighs into flexion.

Which of the following is NOT a joint of the pelvic girdle?

- A) Femoroacetabular (hip) joint
- B) The pubic symphysis
- C) Bilateral sacroiliac (SI) joints
- D) Lumbosacral joint

Pelvic Girdle

Bones	Ilium
	Ischium
	Pubis
Joints	Sacroiliac joint
	Acetabulum
	Pubic symphysis

What are the signs of a positive Trendelenburg test?

- A) When the pelvis on the unsupported side stays the same height
- B) When the pelvis on the unsupported side is elevated slightly
- C) When the pelvis on the unsupported side descends
- D) When the pelvis on the supported side stays level

		<ul style="list-style-type: none"> • The Trendelenburg sign tests for gluteus medius weakness. The strength of the gluteus medius (which acts as an abductor) is assessed. • If the unsupported side descends, this is a positive test. • For example, pelvic drop on the right side in a patient standing on left leg indicates left gluteus medius weakness.
<p>Weak Gluteus Medius on Right → Drop of pelvis on Left</p>	<p>Weak Gluteus Medius on Left → Drop of pelvis on Right</p>	

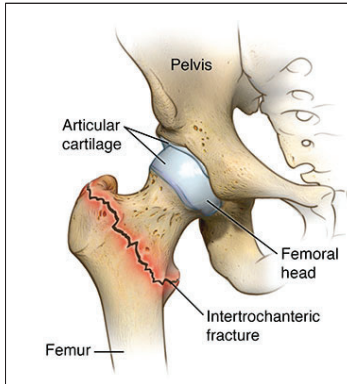
What is the pathophysiology behind avascular necrosis of the femoral head?

- A) Sepsis
- B) Crystalline deposits
- C) Interruption of the vascular supply
- D) Friction

<p>Avascular Necrosis ↓ The death of bone tissue due to a lack of blood supply.</p>		<ul style="list-style-type: none"> • Also known as osteonecrosis of the hip or aseptic necrosis of the hip, this condition is characterized by destruction of the femoral head without sepsis. • <u>Interruption of the vascular supply</u> is the defining common pathway of the disease process. • The most common causes in adults are <u>steroid</u> use or <u>alcohol</u> abuse
---	--	---

What is not true about hip fractures?

- A) Females are more likely than males to sustain a hip fracture
- B) Most common underlying cause is weakened bone from metastatic disease
- C) Approximately 25% of patients over age 50 with hip fractures die within 1 year
- D) About 50% of hip fracture patients require some form of assistive device

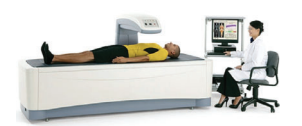

- The most common cause of hip fractures is due to **osteoporosis**. In the vast majority of cases, a hip fracture is a fragility fracture due to a fall or minor trauma in someone with weakened, osteoporotic bone.
- They are classified as **intracapsular**, which includes femoral head and neck fractures, or **extracapsular**, which includes trochanteric, intertrochanteric, and subtrochanteric fractures.

Intracapsular	Extracapsular
femoral head, femoral neck	trochanteric, intertrochanteric, subtrochanteric

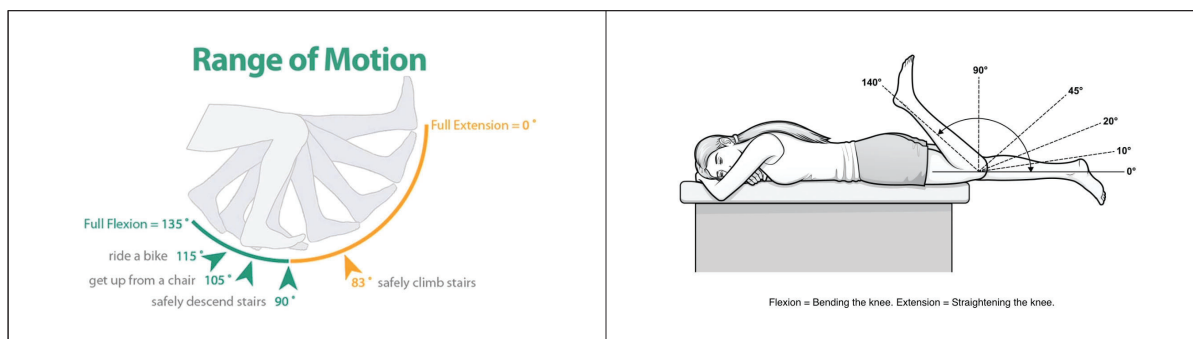
- The location of the fracture and the amount of angulation and comminution play integral roles in the overall morbidity of the patient, as does the preexisting physical condition of the individual.

A dual energy X-ray absorptiometry (DEXA) scan, also called a bone density scan, is a common technique used to measure bone density. This completely painless procedure is easily performed and exposes the patient to minimal radiation.



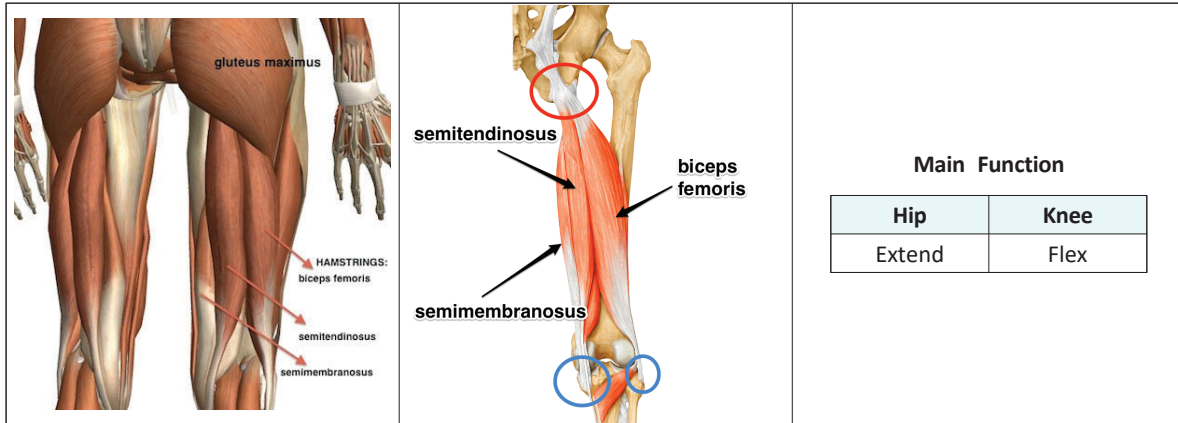
Normal range of motion for the knee is:

- A) 0–90 degrees
- B) 0–135 degrees
- C) 10–30 degrees
- D) 0–180 degrees



A hamstring is one of the three posterior thigh muscles in between the hip and the knee. The hamstrings are quite susceptible to injury. Which of the following muscles does **NOT** compose the hamstring?

- A) Semimembranosus
- B) Semitendinosus
- C) Biceps femoris
- D) Rectus femoris



The hamstrings play a crucial role in many daily activities such as walking, running, jumping, and controlling some movement in the trunk. In walking, they are most important as an antagonist to the quadriceps in the deceleration of knee extension. What is the function of hamstring muscle group?

- A) Extend the hip, Extend the knee
- B) Flex the hip, Flex the knee
- C) Extend the hip, Flex the knee
- D) Flex the hip, Extend the knee

Function of Hamstrings

- The hamstrings cross and act upon two joints - the hip and the knee, and as such are termed biarticular muscles.

True hamstring		
Semitendinosus	Semimembranosus	Biceps femoris – long head

- **Semitendinosus** and **semimembranosus** extend the hip when the trunk is fixed; they also flex the knee and medially (inwardly) rotate the lower leg when the knee is bent.

Hip	Knee	Leg
Extend	Flex	Medially rotate

- The **long head of the biceps femoris** extends the hip, as when beginning to walk; both short and long heads flex the knee and laterally (outwardly) rotate the lower leg when the knee is bent.

Hip	Knee	Leg
Extend	Flex	Laterally rotate

Which of the following points is located on the medial side of the popliteal fossa, between the tendons of Semitendinosus and Semimembranosus?

- A) He-Sea point of Foot Taiyang
- B) He-Sea point of Foot Shaoyin
- C) He-Sea point of Foot Jueyin
- D) He-Sea point of Foot Taiyin

NOTE: Since 'valley' was the delicate term to refer to the genital area, "Yin Valley" undoubtedly refers to female genitalia. This point treats gynecological disorders such as vaginitis, inflammation of the uterus, leukorrhea or genital itching.

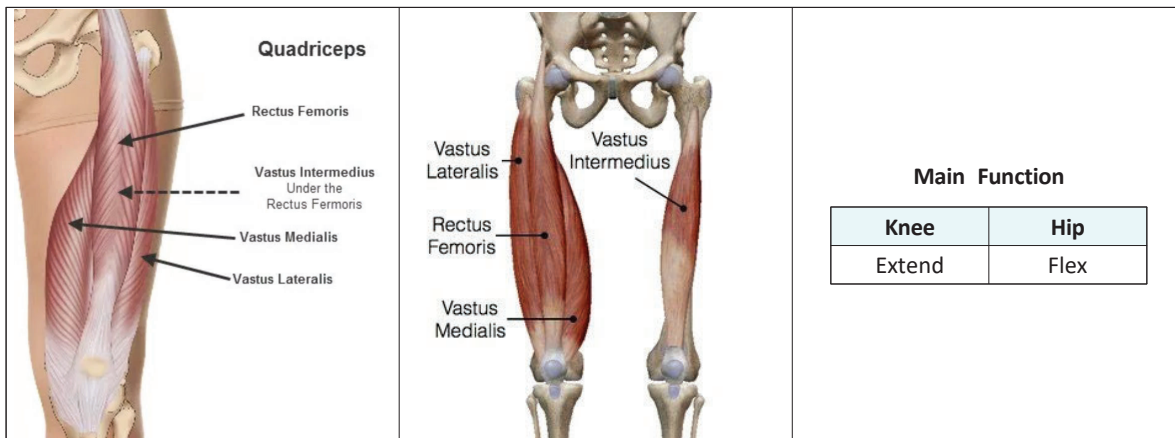
POINTS WITH "GU" (valley) IN THE NAME									
LI4	ST43	SP7	SI2	SI5	UB66	KD2	KD10	KD20	GB8
Union Valley	Sunken Valley	Leaking Valley	Front Valley	Yang Valley	Passage Valley	Blazing Valley	Yin Valley	Open Valley	Leading Valley

Minibook p.110

Quadriceps femoris Muscle, large fleshy muscle group covering the front and sides of the thigh. Which of the following is **NOT** part of the Quadriceps femories?

- A) Vastus lateralis
- B) Vastus intermedius
- C) Vastus medialis
- D) Rectus femoris
- E) Biceps femoris

Quadriceps femoris = Quadriceps extensor = Qudriceps = Quads



Which muscle is a knee flexor?

- A) Rectus femoris
- B) Biceps femoris
- C) Vastus lateralis
- D) Vastus medialis

Rectus femoris	Biceps femoris
Quads	Hamstring

Which muscle is a knee extensor?

- A) Semitendinosus
- B) Semimembranosus
- C) Vastus intermedius
- D) Biceps femoris

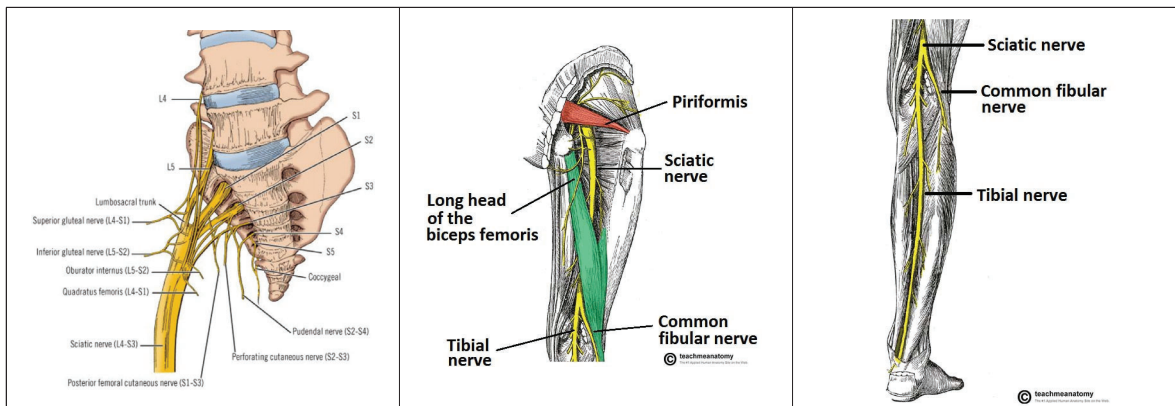
Biceps brachii	Biceps femoris
Flex elbow	Flex knee

Which muscle is a hip flexor?

- A) Vastus lateralis
- B) Vastus intermedius
- C) Vastus medialis
- D) Rectus femoris

The gastrocnemius muscle is supplied by which nerve?

- A) Femoral nerve
- B) Obturator nerve
- C) Common peroneal nerve
- D) Tibial nerve



Which of the following points is located directly below the belly of m. gastrocnemius, on the line joining BL40 and the tendo calcaneus, about 8 cun below BL40?

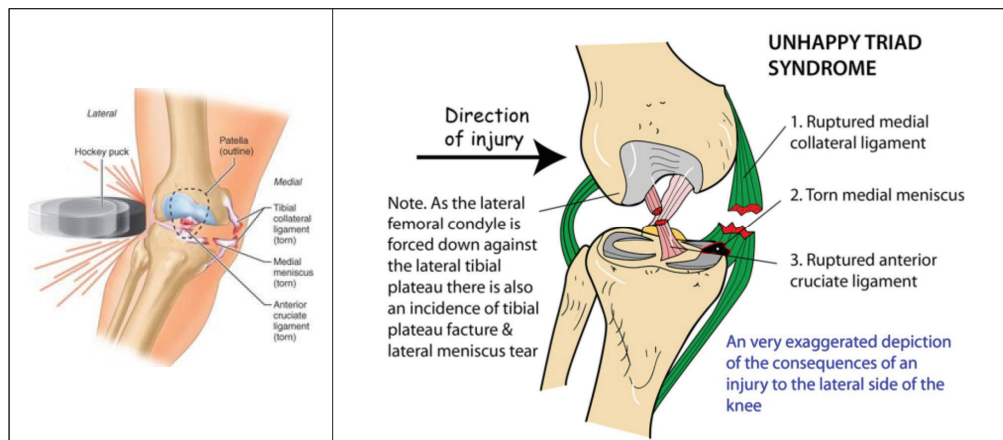
- A) UB55
- B) UB56
- C) UB57
- D) UB58

UB57 Cheng Shan 承 Support 山 Mountain ⊥ 0.8-1.2	Directly below the belly of m. gastrocnemius, on the line joining UB40 & the tendon calcaneus, about 8 cun below UB40	E Lower back pain, gastrocnemius spasm, hemorrhoids, constipation, beriberi
	ACTIONS: Clear Heat, relax the sinews & muscles, remove obstructions from the channel, invigorate the Blood, benefit hemorrhoids NOTE: There are two reasons why UB57 is good for treating hemorrhoids. One reason is the location resembles the buttocks, the second is because it can treat disorders involving tissue protrusion like hemorrhoids, and clinically uterine myoma or nasal polyps.	W Pain of the lower back & leg, sciatica, hemorrhoids, spasm of the gastrocnemius muscle, paralysis of the lower limb, prolapsed anus

Minibook p.105

The "Unhappy triad", also known as a blown knee among other names, is an injury to the:

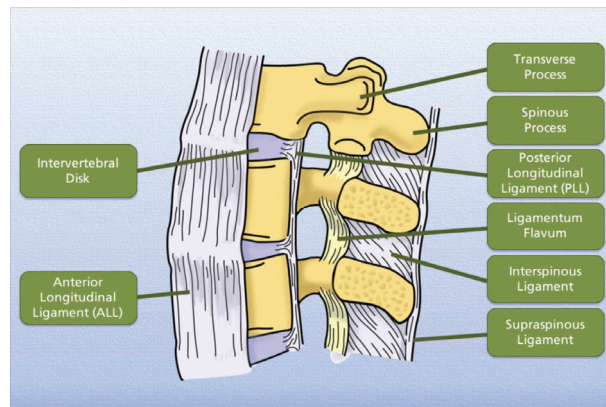
- A) Medial meniscus + Lateral meniscus + ACL
- B) ACL + MCL + Medial meniscus
- C) ACL + PCL + Lateral meniscus
- D) ACL + MCL + PCL



- Analysis during the 1990s indicated that this 'classic' O'Donoghue triad is actually an unusual clinical entity among athletes with knee injuries. Some authors mistakenly believe that in this type of injury, "combined anterior cruciate and medial collateral ligament (ACL- MCL) disruptions that were incurred during athletic endeavors" always present with concomitant medial meniscus injury.
- However, the 1990 analysis showed that lateral meniscus tears are more common than medial meniscus tears in conjunction with sprains of the ACL.

Which ligament of the spine resists extension?

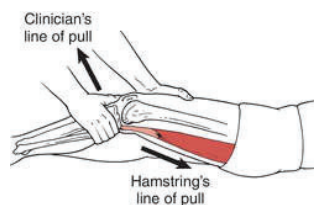
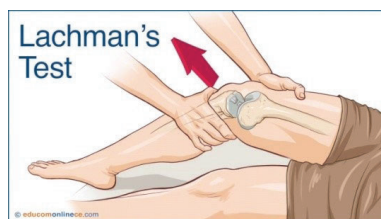- A) Posterior longitudinal ligament
- B) Ligamentum flavum and facet joint capsule
- C) Anterior longitudinal ligament
- D) Interspinous and supraspinous ligaments



The anterior longitudinal ligament runs anteriorly and vertically attaching to the front of each vertebra. It traverses all of the vertebral bodies and intervertebral discs.

Which test helps determine if a patient has an anterior cruciate ligament injury?

- A) McMurray's test
- B) Apley grind test
- C) Lachman test
- D) Bakody's test



Lachman test

- The Lachman test is a clinical test used to diagnose injury of the anterior cruciate ligament (ACL).
- Lachman test is the most sensitive test for ACL injury or laxity. It is recognized as reliable, sensitive, and usually superior to the anterior drawer test.

Description

- The test is performed with the patient in a supine position and the injured knee flexed to 30°. → The practitioner stabilizes the distal femur with one hand, grasps the proximal tibia in the other hand and then attempts to sublux the tibia anteriorly.
- Lack of a clear end point indicates a (+) Lachman test

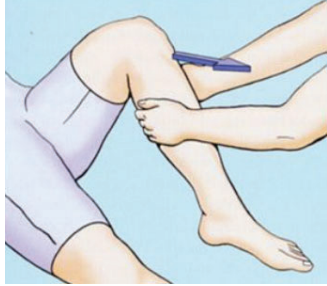

The drawer test is used in the initial clinical assessment of suspected rupture of the cruciate ligaments in the knee. Match each drawer test to the correct injury.

Anterior drawer test ■

ACL (anterior cruciate ligament) tear

Posterior drawer test ■

PCL (posterior cruciate ligament) tear

Anterior Drawer Test	Posterior Drawer Test
	
<p>_____ tear → can draw tibia anteriorly</p>	<p>_____ tear → can push tibia posteriorly</p>

Match each one to the correct definition.

Genu varum ■


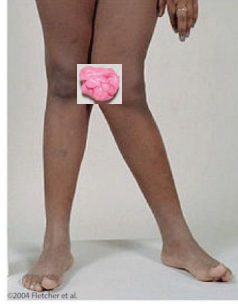
"Bow legged"

Genu valgum ■

"Knock kneed"

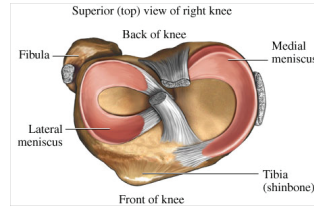
What is the medical term for "knock-kneed"?

- A) Genu varum
- B) Genu valgum
- C) Genu recurvatum
- D) Genu anterium

GENU VARUM	GENU VALGUM
	
<p>"RUM" makes your knees spread apart.</p>	<p>"GUM" makes your knees stick together.</p>


Which meniscus is more circular?

- A) Medial meniscus
- B) Anterior meniscus
- C) Lateral meniscus
- D) Posterior meniscus



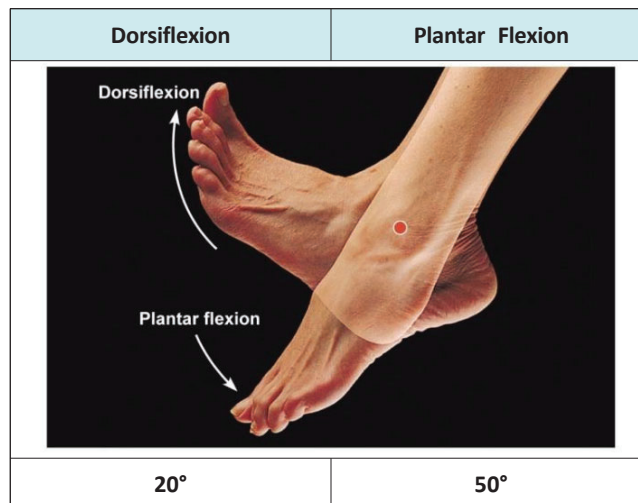
Which of the following test(s) are used to determine the presence of a meniscal tear within the knee?

- A) McMurray test
- B) Appley compression test
- C) Lachman test
- D) A and B
- E) B and C




What the normal range of motion for plantar flexion of the ankle?

- A) 5 degrees
- B) 20 degrees
- C) 50 degrees
- D) 90 degrees



An Achilles tendon injury is most likely to occur with what action?

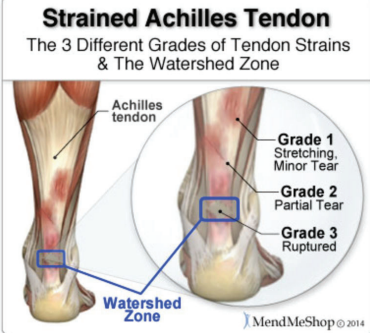
- A) Sudden pivoting
- B) Internal rotation of the ankle
- C) Abruptly starting a sprint
- D) Walking uphill



The Achilles tendon attaches the gastrocnemius to the heel. As the muscle shortens, the tendon plantarflexes the foot. An acute injury occurs when a healthy tendon is subjected to a sudden, unexpected force, such as pushing off for a sprint or landing from a jump.

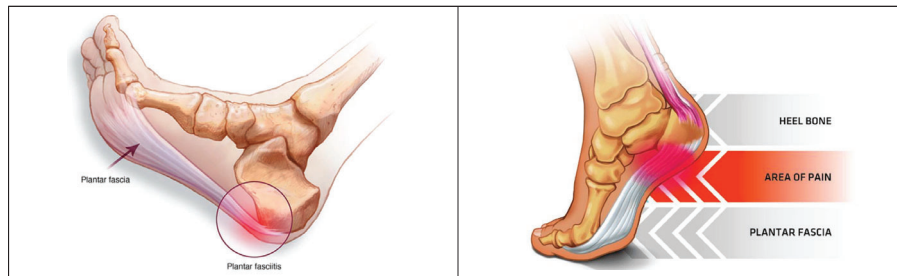
Where is the most common location of an Achilles tendon rupture?

- A) At the attachment to the calcaneus
- B) At the aponeurosis of the gastrocnemius
- C) 2–5 cm proximal to tendon insertion at calcaneus
- D) Near the soleus

Most rupture occurs in watershed zone	Watershed zone
 <p>Strained Achilles Tendon The 3 Different Grades of Tendon Strains & The Watershed Zone</p> <p>Achilles tendon</p> <p>Grade 1 Stretching, Minor Tear</p> <p>Grade 2 Partial Tear</p> <p>Grade 3 Ruptured</p> <p>Watershed Zone</p> <p>MendMeShop © 2014</p>	<ul style="list-style-type: none"> • The “watershed zone” of the Achilles is in the substance of the tendoachilles, approximately 2 to 5 cm above the calcaneal insertion of the tendon. • This is an area of hypovascularity (poor blood supply) and where most ruptures occur.

Which is not a characteristic of plantar fasciitis?

- A) Affects females more than males
- B) Tenderness over lateral aspect of the heel
- C) Pain is worse in the morning
- D) Heel spurs may contribute to the etiology



- Plantar fasciitis is one of the most common causes of heel pain. It involves inflammation of a thick band of tissue that runs across the bottom of your foot and connects the heel bone to the toes (plantar fascia).
- Plantar fasciitis commonly causes stabbing pain that usually occurs with the first steps in the morning. As one gets up and moves more, the pain normally decreases, but it might return after long periods of standing or after rising from sitting.
- Plantar fasciitis is more common in runners. In addition, people who are overweight and those who wear shoes with inadequate support have an increased risk of plantar fasciitis.