

Endoscopic removal of a bleeding colonic polypoid angiodysplasia : case report

A. Kobeissy¹, M. Mallat¹, F. Jamali², S. Yaghi¹, M. Jabbour³, N. Shabb³, A. Soweid¹

(1) Internal Medicine Department, American University of Beirut Medical Center ; (2) Surgery Department, American University of Beirut Medical Center ; (3) Pathology Department, American University of Beirut Medical Center, Beirut, Lebanon.

Abstract

Arteriovenous malformations are common causes of lower gastrointestinal bleeding in the elderly. Among them, angiodysplasia is one subtype that appears on endoscopy as red, flat superficial lesions, and sometimes slightly elevated. Colonic angiodysplasia is very rarely seen as a polypoid lesion. The present case describes a bleeding large polypoid colonic angiodysplasia in a 60 year-old man. It was removed endoscopically using a PolyLoop® ligature device without complications. (*Acta gastroenterol. belg.*, 2010, 73, 406-408).

Key word : Arteriovenous malformation, polypoid angiodysplasia, polypectomy

Introduction

Arteriovenous malformations (AVM) are among common causes of acute and chronic lower gastrointestinal (GI) bleeding. The GI vascular lesions are classified according to the most affected vascular structures (artery, vein, arteriovenous, capillary) and their location within the bowel wall. AVM enclose three groups : angiodysplasia where the arteriovenous communications are present in the mucosa and submucosa, hereditary hemorrhagic telangiectasia where the vessels are distributed in all the layers of the bowel, and gastric antral vascular ectasia- watermelon stomach- where the vessels (tortuous capillaries and veins) are found in the mucosa and submucosa (1). We report an extremely rare presentation of a colonic angiodysplasia as a large pedunculated polyp.

Case report

A 60 year-old man, previously healthy, presented with a two-month history of intermittent hematochezia without other GI symptoms. His physical exam was normal. Laboratory tests showed no evidence of anemia in addition to normal liver function tests. Colonoscopy revealed a large (around 4 cm) pedunculated polypoid lesion in the sigmoid (Fig. 1) with minimal oozing of blood from its tip. After the stalk was injected with epinephrine (1:10000 dilution), a PolyLoop® (Olympus Medical Systems Corp., Japan) was deployed and the polyp was then snared and removed. Histologic evaluation showed a polypoid mass lined by hyperplastic colonic mucosa. The *muscularis mucosae* was thickened. There were numerous dilated thin walled blood vessels in the lamina propria and numerous large tor-

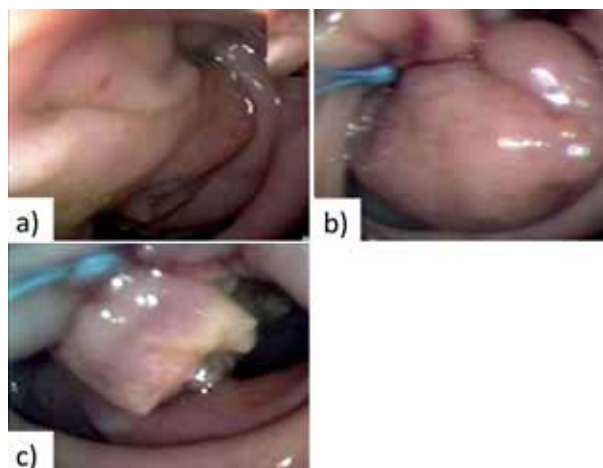


Fig. 1. — a) Colonoscopic view of a large, sigmoid polypoid lesion with a thick stalk. b) The PolyLoop® deployed at the stalk after epinephrine injection. c) The base of the stalk after snare removal of the polyp.

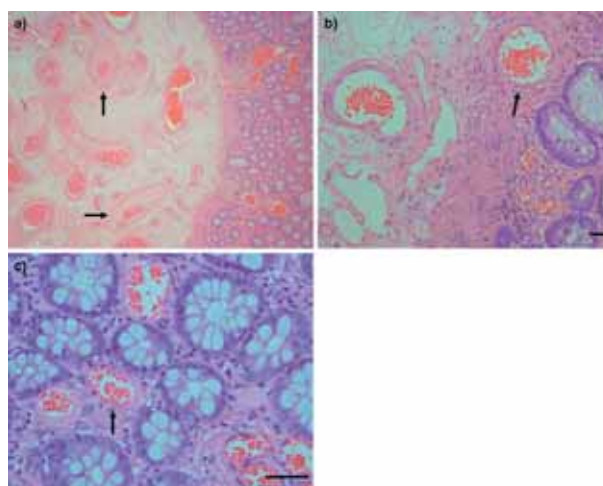


Fig. 2. — Histopathologic findings of the excised polypoid lesion. a) Multiple large congested arterial and venous vascular channels (see arrows) in the lamina propria extending into the submucosa (b) and mucosa (c). (hematoxylin and eosin stain, original magnification $\times 20, 200, 400$ respectively, scale = 50 μm).

Correspondence to : Assaad M. Soweid, MD, FASGE, American University of Beirut – Medical Center, P.O. Box 11-0236, Riad El Solh 1107 2020, Beirut, Lebanon. Phone : +961-1-350000 Extension 5341. Fax : +961-1-370814. E-mail : as25@aub.edu.lb

Submission date : 19/08/2009
Acceptance date : 04/01/2010

tuously thick walled arteries and veins in the submucosa (Fig. 2). In multiple areas the abnormal vessels disrupted the *muscularis mucosae*. The findings were consistent with polypoid angiodysplasia. After the removal of the lesion, the patient had no recurrence of hematochezia over a follow up period of six months.

Discussion

Colonic angiodysplasia, also known as vascular ectasia, is defined as the presence of dilated blood vessels in the mucosa and the submucosa (2) without any involvement of the muscularis propria or serosa. Up to one third of cases of lower GI bleeding are due to colonic angiodysplasias (3). They are usually multiple and mainly seen in the elderly (4). The most common location of these lesions is the right colon. Endoscopically, colonic angiodysplasias are described as red ectatic vascular mucosal lesions with a diameter ranging between few millimeters to few centimeters. They are usually flat, but may be slightly elevated in some cases. Histologically, the capillaries, veins, and arteries are abnormally thin-walled, dilated, and are usually seen in the mucosa and the submucosa (5). Thick-walled arteries are typically present in congenital AVM.

The etiology of angiodysplasia is still unknown. Roskell *et al.* (4) suggested the presence of a deficiency in the collagen type IV in the vessels of the mucosa that will predispose the development of angiodysplasia. Another study conducted by Junquera *et al.* (6) found that angiogenic factors such as basic fibroblast growth factor (bFGF) and vascular endothelial growth factor (VEGF) are highly expressed in patients with angiodysplasia and thus play a very important role in their pathogenesis. Colonic angiodysplasia have been associated with chronic renal failure, aortic stenosis, liver cirrhosis or von Willebrand's disease (7,8,9,10,11).

Polypoid angiodysplasias are extremely rare in the colon. Only a few cases have been described in the liter-

ature over the past 50 years (Table 1) (12-21). The age at presentation ranged from 24 to 84 years. Their sizes ranged from 0.5 to 6.0 cm and they were evenly distributed throughout the entire colon.

Colonic polypoid AVM's had been mistaken for adenomatous polyps and their diagnosis was made after polypectomy was performed. Due to their hypervascular structures, it is assumed that they would carry a significant potential risk for bleeding upon removal, especially if the vessels within are more than 1 mm in diameter (22). The size below which such lesions can be safely endoscopically transected is yet to be determined. However, it would be prudent to use a detachable snare (PolyLoop®) prior to the removal of large lesions.

Based on our literature review, the current case reports the largest (base diameter about 4 cm) colonic polypoid angiodysplasia that has been successfully and safely removed by endoscopy using a PolyLoop® ligation device.

References

- GORDON F.H., WATKINSON A., HODGSON H. Vascular malformations of the gastrointestinal tract. *Best Pract. Res. Clin. Gastroenterol.*, 2001, **15** : 41-58.
- ZUCKERMAN G.R., PRAKASH C. Acute lower intestinal bleeding. Part II : etiology, therapy, and outcomes. *Gastrointest. Endosc.*, 1999, **49** : 228-38.
- SUZUKI N., AREBI N., SAUNDERS B.P. A novel method of treating colonic angiodysplasia. *Gastrointest. Endosc.*, 2006, **64** : 424-7.
- ROSKELL D.E., BIDDOLPH S.C., WARREN B.F. Apparent deficiency of mucosal vascular collagen type IV associated with angiodysplasia of the colon. *J. Clin. Pathol.*, 1998, **51** : 18-20.
- POUNDER D.J., ROWLAND R., PIETERSE A.S., FREEMAN R., HUNTER R. Angiodysplasias of the colon. *J. Clin. Pathol.*, 1982, **35** : 824.
- JUNQUERA F., SAPERAS E., DE TORRES I., VIDAL M.T., MALAGELADA J.R. Increased expression of angiogenic factors in human colonic angiodysplasia. *Am. J. Gastroenterol.*, 1999, **94** : 1070-6.
- LEFRANÇOIS C., DUBUS L., MAUREL J., CHICHE L., LAVERGNE J.M., BOREL-DERLON A. Digestive hemorrhage disclosing an angiodysplasia and von Willebrand disease type 2. *Ann. Fr. Anesth. Reanim.*, 1997, **16** : 978-81.
- ARCIDIACONO G., DE DOMENICO C., BATTAGLIA E., BORDIGNON E., ASMUNDO G.O., ZINGALI C., LONGHITANO A., CUSCUNÀ S.,

Table I. — Summary of reported colonic polypoid angiodysplasia

Case (year)	Age/Gender	Presentation	Location	Maximal Diameter (cm)	Gross finding	Treatment
Koziara et al. (11)(1996)	84/F	Hematochezia	Sigmoid	3.5	Pedunculated	Snare polypectomy
	58/M	Iron deficiency anemia	Transverse colon	1.5	Pedunculated	Snare polypectomy
Park et al. (12)(2000)	41/M	Hematochezia	Descending colon	1.0	Pedunculated	Snare polypectomy
D'Arienzo et al. (13)(2001)	53/M	Hematochezia	Sigmoid	2.0	Pedunculated	Snare polypectomy
McKevitt et al. (14)(2002)	24/M	Hematochezia	Rectum	0.7	Pedunculated	Snare polypectomy
Nasseri-Moghaddam et al. (15) (2004)	26/M	Hematochezia	Sigmoid	3.0	Pedunculated	Snare polypectomy
Kakushima et al. (16) (2004)	59/M	Hematochezia	Colon - not specified	1.5	Pedunculated	Snare polypectomy
Maeng et al. (17) (2004)	59/F	Hematochezia	Transverse colon	6.0	Pedunculated	Surgery
Ji et al. (18) (2005)	81/M	Hematochezia	Transverse colon	3.5	Semi-Pedunculated	Snare polypectomy
Lin et al. (19) (2007)	69/M	Abdominal discomfort	Ascending colon	2.5	Pedunculated	Snare polypectomy
Kim et al. (20) (2009)	66/F	Screening	Cecum	0.5	Semi-Pedunculated	Cold biopsy
Present case	60/M	Hematochezia	Sigmoid	4.0	Pedunculated	Snare polypectomy

- GURGONE E., VIGO G., OSSINO A.M., DI MAURO C. Angiodysplasia of the right colon and aortic stenosis. A case report. *Minerva Cardioangiol.*, 1996, **44** : 173-7.
9. TRENDELL-SMITH N.J., WARREN B.F., SHEFFIELD E.A., DURDEY P. An unusual case of colonic angiodysplasia. *J. Clin. Pathol.*, 1995, **48** : 272-5.
 10. SATOH Y., KITA H., KIHIRA K., MUTOH H., OSAWA H., SATOH K., IDO K., SAKATA Y., SUGANO K. Gastrointestinal angiodysplasia in a patient with type 2 von Willebrand's disease and analysis of exon 28 of the von Willebrand factor gene. *Am. J. Gastroenterol.*, 2004, **99** : 2495-8.
 11. OGANO M., IWASAKI Y.K., TAKANO H., TAKAYAMA M., TAKANO T., FUKUDA Y. Successful colectomy for the treatment of repetitive bleeding from colonic angiodysplasia in a patient with Heyde syndrome. *Intern. Med.*, 2006, **45** : 355-8.
 12. KOZIARA F.J., BRODMERKEL G.J., BOYLAN J.J., CIAMBOTTI G.F., AGRAWAL R.M. Bleeding from polypoid colonic arteriovenous malformations. *Am. J. Gastroenterol.*, 1996, **91** : 584-6
 13. PARK E.R., YANG S.K., JUNG S.A., SHIM K.N., JUNG H.Y., KIM H.R., HONG W.S., MIN Y.I. A case of pedunculated arteriovenous malformation presenting with massive hematochezia. *Gastrointest. Endosc.*, 2000, **51** : 96-7.
 14. D'ARIENZO A., MANGUSO F., D'ARMIENTO F.P., BENNATO R., SOMMA P., PISANI A., PANARESE A., MAZZACCA G. Colonoscopic removal of a polypoid arteriovenous malformation. *Digest. Liver Dis.*, 2001, **33** : 435-7.
 15. MCKEVITT E.C., ATTWELL A.J., DAVIS J.E., YOSHIDA E.M. Diminutive but dangerous : a case of a polypoid rectal arteriovenous malformation. *Endoscopy*, 2002, **34** : 429.
 16. NASSERI-MOGHADDAM S., MOHAMADNEJAD M., MALEKZADEH R., TAVANGAR S.M. Gastrointestinal polypoid arteriovenous malformation of the colon. *J. Gastroenterol. Hepatol.*, 2004, **19** : 1419.
 17. KAKUSHIMA N., FUJISHIRO M., YAHAGI N., OKA M., KOBAYASHI K., HASHIMOTO T., MIYOSHI H., MORIYAMA Y., ENOMOTO S., IGUCHI M., ICHINOSE M., OMATA M. An unusual case of polypoid angiodysplasia. *Endoscopy*, 2004, **36** : 379.
 18. MAENG L., CHOI K.Y., LEE A., KANG C.S., KIM K.M. Polypoid arteriovenous malformation of colon mimicking inflammatory fibroid polyp. *J. Gastroenterol.*, 2004, **39** : 575-8.
 19. JI J.S., CHOI K.Y., LEE B.I., KIM B.W., CHOI H., CHO S.H., CHUNG W.C., LEE I.S., LEE K.M., CHAE H.S., CHUNG I.S., KIM K.M. A large polypoid arteriovenous malformation of the colon treated with a detachable snare : case report and review of literature. *Gastrointest. Endosc.*, 2005, **62** : 172-175.
 20. LIN I.T., CHANG W.H., SHIH S.C., LIN S.C., CHEN Y.J., WANG H.Y., CHU C.H., WANG T.E., LIOU T.C., SHYUNG L.R., BAIR M.J. Endoscopic polypectomy for colonic vascular ectasia. *Endoscopy*, 2007, **39** : E253-4.
 21. KIM B.K., HAN H.S., LEE S.Y., KIM C.H., JIN C.J. Cecal polypoid arteriovenous malformations removed by endoscopic biopsy. *J. Korean Med. Sci.*, 2009, **24** : 342-5.
 22. TIO T.L., TYTGAT G.N.J. Endoscopic ultrasonography of an arteriovenous malformation in a gastric polyp. *Endoscopy*, 1986, **18** : 156-8.