

<https://doi.org/10.17221/24/2018-VETMED>

Lungworm infections in dogs from Central Europe

V. CABANOVA^{1*}, Z. HURNIKOVA¹, M. MITERPAKOVA¹, K. DIRBAKOVA²,
A. BENDOVA², P. KOCAK³

¹Institute of Parasitology, Slovak Academy of Sciences, Kosice, Slovak Republic

²Private Veterinary Practice, Rimavska Sobota, Slovak Republic

³Private Veterinary Practice, Michalovce, Slovak Republic

*Corresponding author: cabanova@saske.sk

ABSTRACT: *Angiostrongylus vasorum* and *Crenosoma vulpis* are parasites in the respiratory tract of domestic and wild carnivores. Recently, an increasing number of lungworm infections in dogs has been recognized in Europe. In this report, the results of the first copro-epidemiological study of *A. vasorum* and *C. vulpis* in dogs from Slovakia are presented. The Baermann technique and the modified flotation method with zinc sulphate solution (specific gravity 1.2) was used for lungworm detection. In addition, conventional PCR was performed for species confirmation. The majority of lungworm infections were found in the eastern part of the country. A relatively high prevalence (4.13%) of *A. vasorum* was detected in different parts of Slovakia. Infection was detected most frequently incidentally in asymptomatic dogs. Within this study, crenosomosis was detected for the first time in dogs from Slovakia. Since one infected dog had no travel history, the case is considered autochthonous. An autochthonous case report of angiostrongylosis in a Hanoverian hound puppy from central Slovakia is also described.

Keywords: *Angiostrongylus vasorum*; *Crenosoma vulpis*; angiostrongylosis; crenosomosis; dog

Canine angiostrongylosis is a cardiorespiratory disease of dogs and wild carnivores. Infection is caused by the metastrongylid nematode, *Angiostrongylus vasorum* (Baillet 1866), usually known as the “French heartworm”. Adult parasites dwell in pulmonary arteries and the right ventricle of the heart (Willesen et al. 2007) and may cause severe disease, characterised by respiratory distress (Colella et al. 2016a). Clinical signs such as cough, dyspnoea, depression, exercise intolerance and haemorrhage are usually connected with the disease. Untreated, the infection can be fatal (Willesen et al. 2007).

Another metastrongylid worm, *Crenosoma vulpis* (Dujardin 1845) also called the “fox lungworm”, is the causative agent of crenosomosis mainly in red foxes, but an increasing number of canine infections has been observed in Europe recently. In dogs,

the disease in general is not life-threatening, but presents with various degrees of respiratory disorder, mainly chronic cough, and occasionally vomiting (Bihl and Conboy 1999; Colella et al. 2016b; Matos et al. 2016).

The life cycle of both lungworms is indirect. Various species of slugs and snails play the role of intermediate host. Molluscs with infective third-stage larvae (L3) and their secretions on grass or pet toys are the source of infection. After ingestion by dogs, the L3 larvae penetrate the gut wall and migrate to abdominal lymph nodes, where they moult two times. *A. vasorum* worms mature in the right ventricle and pulmonary arteries, whereas *C. vulpis* develop to the adult stage in bronchioles, bronchi and trachea. Females produce eggs that hatch in the respiratory system and after being swallowed, the L1 larvae are voided with faeces into the environment

Supported by the Science Grant Agency VEGA (Project No. 2/0018/16), Slovak Research and Development Agency and by the project “Centre of Excellence for Parasitology” (code ITMS: 26220120022), supported by the Research and Development Operational Programme funded by the ERDF (0.5).

(Di Cesare and Traversa 2014; Colella et al. 2016a). The prepatent period varies between 35–60 days for angiostrongylosis and 18–21 days for crenosomosis (Colella et al. 2016a; Colella et al. 2016b).

Different treatment programs are known for angiostrongylosis, mainly based on benzimidazoles and macrocyclic lactones (Di Cesare and Traversa 2014). Therapy of crenosomosis has often been based on fenbendazole or levamisole, but medication protocols using milbemycin oxime/praziquantel and imidacloprid/moxidectin combinations are also effective (Willesen et al. 2007; Husnik et al. 2010; Conboy et al. 2013).

Recently, the number of clinical cases caused by canine lungworms has increased in Europe (Traversa et al. 2010). In Slovakia, the first autochthonous case of canine angiostrongylosis was described in 2013 from south-eastern Slovakia (Kosice region) (Hurnikova et al. 2013). The occurrence of *C. vulpis* was already confirmed in 1960' in red foxes from the country (Mituch 1962) and a relatively high prevalence of *A. vasorum* (5.43%) and *C. vulpis* (17.51%) was recently detected in red foxes (Cabanova et al. 2018). However, to the best of our knowledge, no autochthonous crenosomosis in dogs has been reported to date from Slovakia. For this reason, our study was aimed at understanding the epidemiology of angiostrongylosis and crenosomosis in dogs from Slovakia.

MATERIAL AND METHODS

From January 2013 to August 2017, 339 canine faecal samples from different districts of Slovakia were examined for the presence of the lungworms *A. vasorum* and *C. vulpis*. The samples were collected in private veterinary practices, dog shelters and by

dog owners. All faeces were sampled directly after defecation and were delivered fresh or frozen to the Institute of Parasitology in Kosice. In 17 cases, dogs were referred to veterinary practitioners with several clinical signs, mainly with chronic cough, dyspnoea, breathing disorder, nasal discharge, bronchitis, pulmonary hypertension, eosinophilia, diarrhoea, conjunctival hyperaemia, weakness, anorexia and weight loss. Additionally, the clinical picture of autochthonous angiostrongylosis in a young female Hanoverian hound is described in detail.

ArcGIS 10.3.1 (ESRI 2015) was used to display localities according to origin of infected dogs in the map of Slovakia (Figure 1).

Fresh sample examination. Fresh faeces were gathered within three days immediately after defecation. The Baermann technique previously described by Olsen et al. (2003) was used. About 5 g of faeces were covered by water and incubated at room temperature. After 48 h, the supernatant was discarded and L1 larvae were examined in the sediment under a Leica M125 stereo microscope (Leica Microsystems GmbH, Germany).

Frozen sample examination. A modified flotation method with zinc sulphate solution (specific gravity 1.2) was performed in cases when samples were frozen (Schnyder et al. 2011). For better sensitivity, the tubes were filled by flotation solution to the top and covered with a coverslip. After 10 minutes, the coverslip was placed on the microscope slide and samples were examined using a Leica DM4000B light microscope (Leica Microsystems GmbH, Germany).

Morphological and molecular determination. First-stage larvae were identified based on morphometric and characteristic morphological features of the caudal end (McGarry and Morgan 2009) (Figure 2). The photographs were taken using a

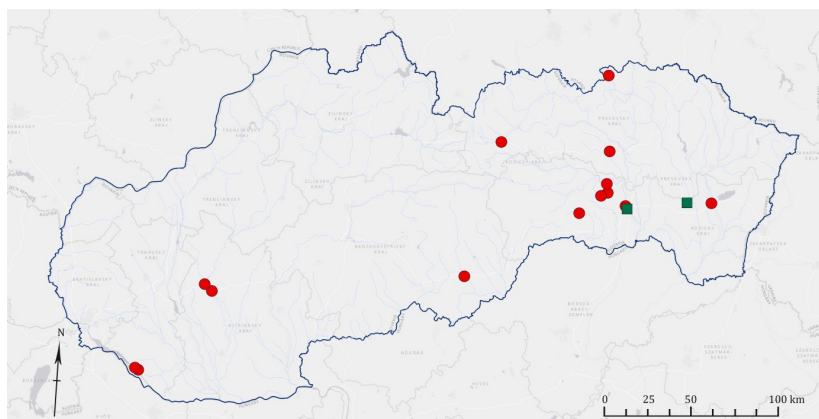


Figure 1. Locations of dogs infected with *Angiostrongylus vasorum* (red circles) and *Crenosoma vulpis* (green squares) from Slovakia

<https://doi.org/10.17221/24/2018-VETMED>

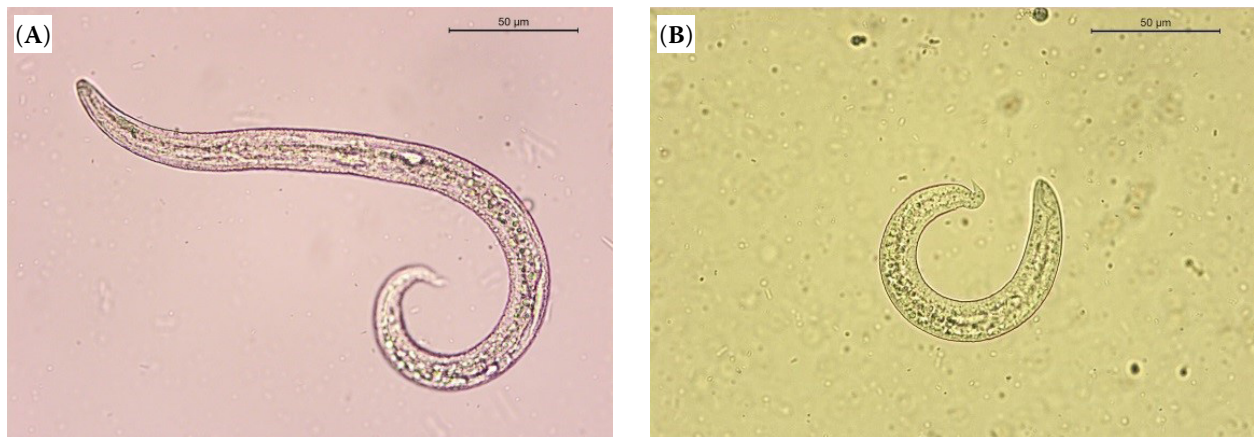


Figure 2. First-stage larvae of lungworms captured during coprological examination: *Angiostrongylus vasorum* (A), *Crenosoma vulpis* (B)

Leica DM4000B light microscope, a Leica DFC 290 HD camera and the Leica Application Suite V 3.8.0 software (Leica Microsystems GmbH, Germany).

Molecular analyses were performed for species confirmation of faecal samples positive for *A. vasorum* and *C. vulpis*. Nematode DNA (deoxyribonucleic acid) was isolated using the commercially available QiAamp DNA Stool Mini Kit (Qiagen®, Germany). Briefly, 200 mg of faeces together with 5 mm stainless beads and 1.4 ml ASL buffer were placed into a 2-ml Eppendorf tube and homogenised for 20 s/15 Hz in Qiagen TissueLyser II (Qiagen®, Germany). After homogenisation, the protocol was carried out according to the manufacturer’s instructions. A fragment of the 18S rDNA ribosomal gene (small ribosomal subunit) was amplified in a conventional PCR (polymerase chain reaction) assay using the primer set NC18SF1/NC5BR designed by Latrofa et al. (2015). DNA of *A. vasorum* obtained from a positive fox was used as a positive control, while nuclease-free water was included as a negative control. Amplification was performed under thermal conditions described in a previous study (Cabanova et al. 2018). Positive templates were purified using NucleoSpin® Gel and a PCR clean-up kit (Macherey-Nagel GmbH & Co.,

KG, Germany) and sequenced by Sanger sequencing in both directions. Sequences were manually edited in Mega 7 and compared by BLAST (Basic Local Alignment Search Tool) with sequences available in GenBank.

RESULTS

First-stage larvae of *A. vasorum* were detected in 14 faecal samples (4.13%) of dogs originating from different parts of Slovakia (Figure 1). French heartworm was diagnosed mainly in clinically healthy dogs ($n = 9$), but in five cases the infections were connected with cough, breathing disorder, bilateral conjunctival hyperaemia and loss of appetite (Table 1). The age of six positive dogs ranged between five and 15 months. Two dogs were older, three and four years of age, respectively. Angiostrongylosis was confirmed in different dog breeds: Maltese pinch, Bernese mountain dog, American Staffordshire terrier, Miniature spitz and Hanoverian hound. Three of the positive dogs never left the country, and thus in those cases, angiostrongylosis is considered as autochthonous (a detailed clinical picture of one of them is described

Table 1. Health status of dogs infected by *Crenosoma vulpis* and *Angiostrongylus vasorum*

Health status	<i>C. vulpis</i> -infected dogs		<i>A. vasorum</i> -infected dogs	
	number of positive	clinical signs observed	number of positive	clinical signs observed
Clinically healthy dogs	0		9	cough, breathing disorder, bilateral conjunctival, hyperaemia, loss of appetite
Dogs with clinical signs	2	cough, respiratory difficulties, anorexia	5	
Total	2		14	

below). No data about age, breed and travel history are known for these six dogs.

Typical morphological features – tail with dorsal and ventral spine and cephalic bottom in the anterior part of the body – were visible in all larvae of *A. vasorum* (Figure 2). Species confirmation was achieved by conventional PCR targeting the ribosomal 18S rDNA gene. Obtained sequences showed 96% similarity with *A. vasorum* isolates from red foxes from Canada and the United Kingdom (AJ920365, EF514916).

C. vulpis was found in two dogs from south-eastern Slovakia (Kosice region) and the prevalence of canine crenosomosis in Slovakia reached 0.59% (Figure 1). In both dogs, cough and other respiratory difficulties were observed; in one dog these were also related with anorexia (Table 1). The first positive dog, a male German shorthaired pointer from Parchovany (unknown age) was regularly used for hunting. Owing to the lack of travel history abroad, the case is considered the first autochthonous case of crenosomosis recorded in a dog from Slovakia. The second dog, a two-year-old female of mixed breed, was adopted from a shelter in the western part of the country and moved to the city of Kosice three months before the first clinical signs appeared. Due to this fact, the age and travel history of the dog are unknown.

In both cases, larvae were identified by morphology. *C. vulpis* larvae had a characteristic digitiform tail and their body was C-shaped (Figure 2). Due to the low number of larvae in faeces, the PCR analysis did not provide any data. No mixed infection by both lungworms was detected within our study.

Case report of angiostrongylosis in a young female Hanoverian hound

A four-month-old Hanoverian hound puppy from Rimavska Sobota (central Slovakia) was diagnosed in several private veterinary practices with strong, irritating cough, bilateral conjunctival hyperaemia, weakness, syncope and anorexia. The dog never travelled abroad. Bronchoscopy revealed a mucopurulent exudate affecting the trachea and bronchi. Bronchoalveolar lavage did not detect the presence of parasites. Cultivation of fluid confirmed only coccobacillus infection by *Pasteurella multocida*. After three months of unsuccessful treatment with antibiotic therapy (amoxicillin, azithromycin, en-

rofloxacin), the radiographic examination of the thorax showed pneumonia. The haematological profile revealed high eosinophilia (13%). Within the differential diagnosis, coprological examination was performed in a commercial laboratory, but only mild infection with *Isospora* spp. was found. A single dose of imidacloprid 10%/moxidectin 2.5% solution was not effective for treatment and the clinical symptoms persisted. Three months after the first clinical signs appeared, a fresh faecal sample was delivered to the Institute of Parasitology in Kosice due to suspected lungworm infection. Using a modified flotation method, a small number of first-stage larvae (LPG, larvae per gram < 5) was detected. According to the morphological features of the tail, the larvae were identified as *A. vasorum*. The species was confirmed also by conventional PCR. The dog was promptly administered six doses of imidacloprid 10%/moxidectin 2.5% spot-on solution applied at 14-day-intervals. Treatment resulted in a resolution of all symptoms.

DISCUSSION

Recently, an increasing number of cardiopulmonary nematodes has been observed in Europe (Traversa et al. 2010; Colella et al. 2016b). Although canine lungworms represent a serious risk for canine health, the most common causative agents in Europe, *A. vasorum* and *C. vulpis*, are still neglected by many veterinary practitioners and dog owners. While crenosomosis is in general non-fatal for dogs, untreated angiostrongylosis can lead to the death of infected animals (Willesen et al. 2007; Conboy et al. 2013).

In our study, more than 330 dog faecal samples were examined for the presence of *A. vasorum* and *C. vulpis*. Despite the short history of angiostrongylosis in Slovakia, the prevalence of the infection reached a relatively high percentage – 4.13%. Surprisingly, the majority of infected dogs were asymptomatic and samples were collected for the purpose of preventive parasitological examination. In positive cases, where symptoms were present, mainly cough and breathing difficulties were observed. Angiostrongylosis was detected in different dog breeds of various ages, but the majority of positive dogs were younger than 15 months. In three cases, dogs never left the country and the infections are thus considered as autochthonous.

<https://doi.org/10.17221/24/2018-VETMED>

Infected dogs originated from different parts of Slovakia, but most frequently came from the eastern region of the country (Figure 1), the same area where the very first case of angiostrongylosis was recorded (Hurnikova et al. 2013). No infections with *A. vasorum* were detected in the northern part of Slovakia (Figure 1).

Crenosomosis may play a significant role as an agent of chronic respiratory diseases in dogs in Europe (Conboy et al. 2013). In our study, two cases of crenosomosis in dogs were detected in the south-eastern part of the country. The first positive dog, a male German shorthaired pointer from Parchovany (Kosice region), never travelled outside the country. To the best of our knowledge, this is the first autochthonous case of crenosomosis described in a dog from Slovakia. Moreover, the dog was regularly used for hunting, and common contact with wildlife might be a source of infection with the fox lungworm. In both positive dogs, clinical signs such as cough, and in one case anorexia, were observed. Due to unspecific clinical signs, a significant number of canine crenosomosis infections can be misdiagnosed as allergic or respiratory diseases (Bihl and Conboy 1999). However, no asymptomatic infection was found casually during our copro-epidemiological investigation (Table 1).

In this study, a case report of canine angiostrongylosis in a puppy from central Slovakia was presented. Strong irritating cough persisted in this young female for more than three months. After unsuccessful treatment with antibiotics and the longstanding presence of symptoms of respiratory disease, parasitic infection was also considered within the differential diagnosis. Coprological examination revealed the presence of *A. vasorum* and subsequently the dog was successfully treated with several doses of imidacloprid and moxidectin. According to Di Cesare and Traversa (2014), a single application of this spot-on solution has 85.2% efficacy. In our case, however, treatment with a single dose of the combination failed. With respect to this, the number of dosages and the intervals should be considered taking into account the intensity of infection and severity of clinical signs.

Herein, the results of the first epidemiological survey on *A. vasorum* and *C. vulpis* occurrence in dogs from Slovakia were presented. The majority of *A. vasorum*-infected dogs and the two cases of canine crenosomosis were found in the eastern part of Slovakia. These findings correlate with the

epidemiological situation detected in red foxes, since the first case of canine angiostrongylosis also came from the same area (Hurnikova et al. 2013; Cabanova et al. 2018). It is clear that eastern Slovakia constitutes a favourable habitat for both lungworm species. Several cases of angiostrongylosis were also found in other, mainly southern regions of Slovakia. Additionally, the presented clinical case of autochthonous angiostrongylosis from central Slovakia confirmed that lungworms infection is still neglected by many veterinary practitioners, and extensive education is needed to increase their awareness of pulmonary dog parasites.

Acknowledgement

The authors are grateful to the employees of the Sloboda Zvierat dog shelter for their assistance with sampling and to Prof. David Bruce Conn for proofreading the manuscript.

REFERENCES

- Bihl T, Conboy GA (1999): Lungworm (*Crenosoma vulpis*) infection in dogs on Prince Edward Island. *Canadian Veterinary Journal* 40, 555–559.
- Cabanova V, Miterpakova M, Druga M, Hurnikova Z, Valentova D (2018): GIS-based environmental analysis of fox and canine lungworm distribution: an epidemiological study of *Angiostrongylus vasorum* and *Crenosoma vulpis* in red foxes from Slovakia. *Parasitology Research* 117, 521–530.
- Colella V, Lia RP, Premont J, Gilmore P, Cervone M, Latrofa MS, D'Anna N, Williams D, Otranto D (2016a): *Angiostrongylus vasorum* in the eye? New case reports and a review of the literature. *Parasites and Vectors* 9, 161.
- Colella V, Mutfchiev Y, Cavalera MA, Giannelli A, Lia RP, Dantas-Torres F, Otranto D (2016b): Development of *Crenosoma vulpis* in the common garden snail *Cornu aspersum*: implications for epidemiological studies. *Parasites and Vectors* 9, 208.
- Conboy G, Bourque A, Miller L, Seewald W, Schenker R (2013): Efficacy of Milbemax (milbemycin oxime + praziquantel) in the treatment of dogs experimentally infected with *Crenosoma vulpis*. *Veterinary Parasitology* 198, 319–324.
- Di Cesare A, Traversa D (2014): Canine angiostrongylosis: recent advances in diagnosis, prevention and treatment. *Veterinary Medicine: Research and Reports* 5, 181–192.

<https://doi.org/10.17221/24/2018-VETMED>

- ESRI – Environmental Systems Research Institute (2015): ArcGIS Desktop Release 10.3.1, Redlands.
- Hurnikova Z, Miterpakova M, Mandelik R (2013): First autochthonous case of canine *Angiostrongylus vasorum* in Slovakia. *Parasitology Research* 112, 3305–3508.
- Husnik R, Sloboda M, Kovarikova S, Koudela B (2010): Infection with *Crenosoma vulpis* lungworm in a dog in the Czech Republic. *Helminthologia* 48, 56–58.
- Latrofa MS, Lia RP, Giannelli A, Colella V, Santoro M, D'Alessio N, Campbell BE, Parisi A, Dantas-Torres F, Matufchiev Y, Veneziano V, Otranto D (2015): *Crenosoma vulpis* in wild and domestic carnivores from Italy: a morphological and molecular study. *Parasitology Research* 114, 3611–3617.
- Matos B, Colella V, Alho AM, Otranto D, Doyle R, Madeira de Carvalho L (2016): *Crenosoma vulpis* infection in a four-month old puppy. *Helminthologia* 53, 276–280.
- McGarry JW, Morgan ER (2009): Identification of first-stage larvae of metastrongyles from dogs. *Veterinary Record* 165, 258–261.
- Mituch J (1962): Contribution to the knowledge of the helminthofauna in the red fox (*Vulpes vulpes crucigera* L.) in Slovakia (in Slovak). *Veterinarni Medicina* 7, 227–238.
- Olsen SN, Schumann T, Pedersen A, Eriksen L (2003): Recovery of live immature cyathostome larvae from the faeces of horses by Bearmann technique. *Veterinary Parasitology* 16, 259–263.
- Schnyder M, Maurelli MP, Morgolione ME, Kohler L, Deplazes P, Torgerson P, Cringoli G, Rinaldi L (2011): Comparison of faecal techniques including FLOTAC for copromicroscopic detection of first stage larvae of *Angiostrongylus vasorum*. *Parasitology Research* 109, 63–69.
- Traversa D, Di Cesare A, Conboy G (2010): Canine and feline cardiopulmonary parasitic nematodes in Europe: Emerging and underestimated. *Parasites and Vectors* 3, 62.
- Willesen JL, Kristensen AT, Jensen AL, Heine J, Koch J (2007): Efficacy and safety of imidacloprid/moxidectin spot/on solution and fenbendazole in the treatment of dogs naturally infected with *Angiostrongylus vasorum* (Baillet 1866). *Veterinary Parasitology* 147, 258–264.

Received: February 11, 2018

Accepted after corrections: May 23, 2018