

Airway Management in Adults after Cervical Spine Trauma

Edward T. Crosby, M.D., F.R.C.P.C.*

CME This article has been selected for the *Anesthesiology* CME Program. After reading the article, go to <http://www.asahq.org/journal-cme> to take the test and apply for Category 1 credit. Complete instructions may be found in the CME section at the back of this issue.

Cervical spinal injury occurs in 2% of victims of blunt trauma; the incidence is increased if the Glasgow Coma Scale score is less than 8 or if there is a focal neurologic deficit. Immobilization of the spine after trauma is advocated as a standard of care. A three-view x-ray series supplemented with computed tomography imaging is an effective imaging strategy to rule out cervical spinal injury. Secondary neurologic injury occurs in 2–10% of patients after cervical spinal injury; it seems to be an inevitable consequence of the primary injury in a subpopulation of patients. All airway interventions cause spinal movement; immobilization may have a modest effect in limiting spinal movement during airway maneuvers. Many anesthesiologists state a preference for the fiberoptic bronchoscope to facilitate airway management, although there is considerable, favorable experience with the direct laryngoscope in cervical spinal injury patients. There are no outcome data that would support a recommendation for a particular practice option for airway management; a number of options seem appropriate and acceptable.

THE provision of acute medical care to patients with cervical spinal injuries (CSIs) is a complex, challenging, and rewarding task. It is also an anxiety-provoking endeavor because care is provided in a milieu where there is constant concern about medical interventions resulting in the conversion of a spinal injury without neurologic sequelae to one in which the two are now concurrent. It is also a topic of continuous debate because care providers struggle in an environment of limited data and incomplete answers to try to craft clinical care paradigms designed to optimize preservation and return of neurologic function, while minimizing the risk of creating additional injury and neurologic compromise. Many questions regarding the initial care of these patients, particularly as they relate to airway management, remain

unresolved, but there has been great effort, energy, and enthusiasm expended during the past two decades searching for these answers. This article reviews the literature that has been generated on the topic of airway management after CSI, particularly that published in the past 10 yr, identifying new areas of knowledge and evolving practice patterns. It also attempts to address and resolve controversy surrounding areas of care that have proven more contentious, most particularly the use of the direct laryngoscope to facilitate direct tracheal intubation in these patients.

The Adult Cervical Spine: Stability, Injury, and Instability

Movement and Stability of the Upper Cervical Spine

Flexion-extension occurs in the upper cervical spine at both the atlanto-occipital and atlantoaxial articulations, and a combined 24° of motion may be achieved.¹ Flexion is limited by contact between the odontoid process and the anterior border of the foramen magnum at the atlanto-occipital articulation and by the tectorial membrane and posterior elements at the C1–C2 level. Extension is limited by the contact of the posterior arch of the atlas with the occiput superiorly and with the arch of the axis inferiorly. The distance from the posterior arch of the atlas to the occiput is termed the *atlanto-occipital gap*, and a narrow atlanto-occipital gap has been cited as being a cause of difficult intubation.² Nichol and Zuck² suggested that attempts to extend the head in patients with a narrow atlanto-occipital gap results in anterior bowing of the cervical spine, forward displacement of the larynx, and a poor view during laryngoscopy. This concept, although offering an elegant anatomical explanation for the clinical experience of difficult laryngoscopy, has yet to be validated, and the truth may be simpler. Calder *et al.*³ have reported that limited separation of the occiput from the atlas and the atlas from the axis yields an immobile upper spine and reduces both cervical spine extension and mouth opening, resulting in difficult direct laryngoscopy.

The ligaments contributing to the stability of the upper complex are the *transverse, apical, and alar ligaments* as well as the superior terminations of the *anterior and posterior longitudinal ligaments* (fig. 1). In adults, the *transverse ligament* normally allows no more than 3 mm of anteroposterior translation between the *dens* and

* Professor.

Received from the Department of Anesthesiology, University of Ottawa, Ottawa, Ontario, Canada. Submitted for publication March 10, 2005. Accepted for publication October 24, 2005. Support was provided solely from institutional and/or departmental sources.

Address correspondence to Dr. Crosby: Department of Anesthesiology, The Ottawa Hospital-General Campus, Room 2600, 501 Smyth Road, Ottawa, Ontario, Canada, K1H 8L6. ecrosby@sympatico.ca. Individual article reprints may be purchased through the Journal Web site, www.anesthesiology.org.

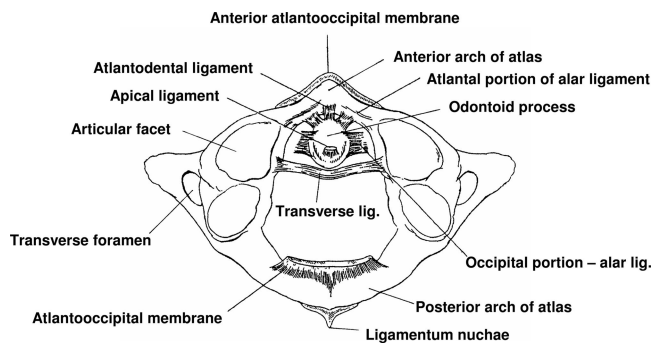


Fig. 1. Ligaments of the atlantoaxial joint. View is from above, with the skull removed.

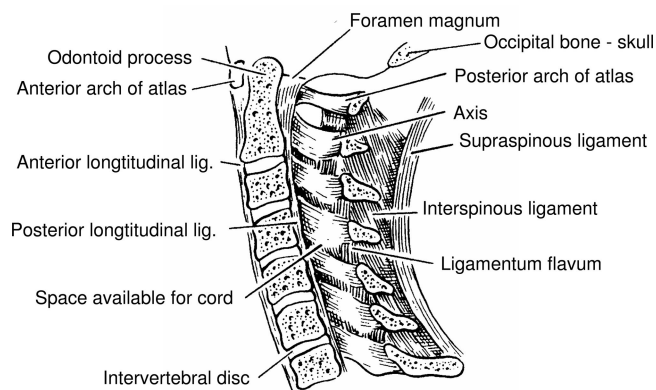


Fig. 2. The ligaments of the lower cervical spine, sagittal section.

the anterior arch of the *atlas*. This may be measured on lateral radiographs of the neck and is termed the *atlas-dens interval*. If the transverse ligament alone is disrupted and the alar and apical ligaments remain intact, up to 5 mm of movement may be seen. If all the ligaments have been disrupted, 10 mm or more of displacement may be seen. Destruction of these ligaments is a common consequence of severe and long-standing rheumatoid arthritis.⁴

Significant posterior displacement of the dens reduces the space available for the spinal cord (SAC) in the vertebral column. The SAC is defined as the diameter of the spinal canal measured in the anteroposterior plane, at the C1 level, that is not occupied by the *odontoid process*. The SAC represents the area composed of both cord and space. The area of the spinal canal at C1 may be divided into one third odontoid, one third cord, and one third "space." The one third space allows for some encroachment of the spinal lumen without cord compromise. However, when this margin of safety has been exhausted, compression of neural elements will occur; persistent compression will eventually lead to myelopathy and neurologic deficit. The cord occupies a greater proportion of the available SAC in the subaxial spine; at the C6 level, approximately 75% of the SAC is occupied by the cord.⁵

Movement and Stability of the Lower Cervical Spine

A further 66° of flexion-extension may be achieved in the lower cervical spine, with the C5-C7 segments contributing the largest component. There is an inverse relation between age and range of motion, *i.e.*, as age increases, mobility decreases. However, most of the decrease occurs at the C5-C7 motion segments, and this usually does not have a significant impact on the ease of direct laryngoscopy. With the head in the standard sniffing position, the cervical spine below C5 is relatively straight; there is increasing flexion from C4 to C2, and the occipitoatlantoaxial complex is at or near full extension.

In the lower cervical spine, the structures contributing

to stability include, from anterior to posterior, the *anterior longitudinal ligament*, the *intervertebral discs*, the *posterior longitudinal ligament*, the *facet joints* with their capsular ligaments and the *intertransverse ligaments*, the *interspinous ligament*, and the *supraspinous ligaments* (fig. 2). The *posterior longitudinal ligament* and the structures anterior to it are grouped as the *anterior elements* or *anterior column* (fig. 3). The *posterior elements* or *posterior column* are those grouped behind the posterior ligament. *Motion segments* are defined as two adjacent vertebrae and the intervening soft tissue elements.

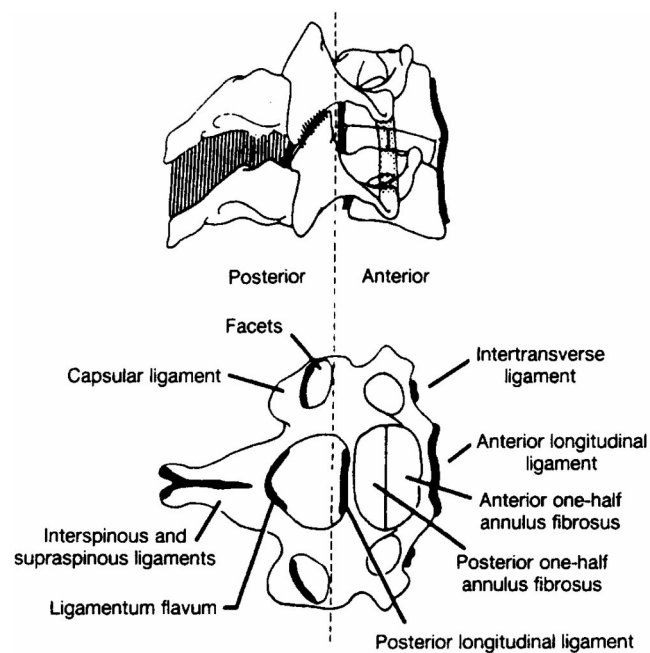
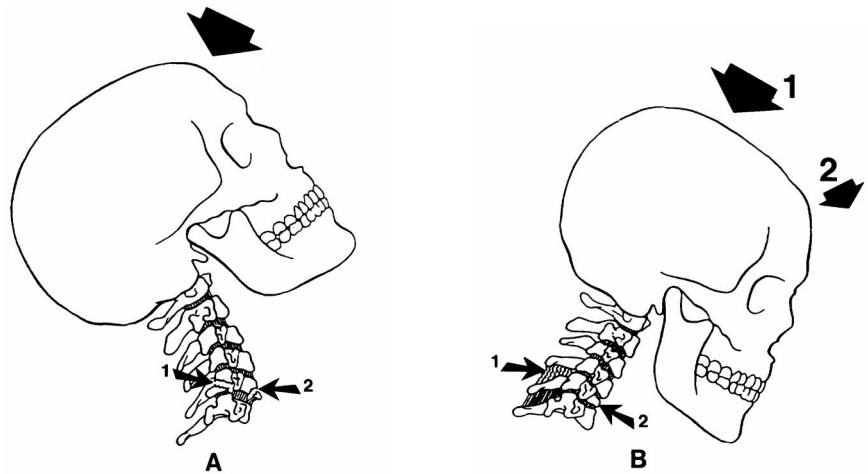


Fig. 3. Schematic representation of the two column concept of the spine. From White AA III, Panjabi MM: *Clinical biomechanics of the spine*. Philadelphia, JB Lippincott, 1978; used with permission.

Fig. 4. Injuring force mechanisms and resulting lesions. In A, a compression hyperextension force has resulted in distraction of the anterior column and compression of posterior column elements; an avulsion fracture from the anterior-inferior margin of the vertebral body (small arrow 2) and a fracture of the articular process (small arrow 1) have resulted. In B, a flexion (large arrow 2), compression (large arrow 1) force has produced a wedge fracture of the vertebral body (small arrow 2) and an incomplete disruption of the interspinous and supraspinous ligaments (small arrow 1).



Cervical Spinal Instability after Injury: Mechanisms and Consequences

White *et al.*⁶ have defined stability as “the ability of the spine to limit its pattern of displacement under physiologic loads so as not to allow damage or irritation of the spinal cord or nerve roots.” Instability occurs when physiologic loading causes patterns of vertebral displacement that jeopardize the spinal cord or nerve roots.⁷ Instability may result from congenital anomalies, acquired conditions related to chronic disease, and acutely after trauma. The following discussion will primarily relate to traumatic instability.

One element in the injured column must be preserved to achieve spinal stability. Clinically, to ensure a margin of safety, preservation of elements in the injured column cannot be assumed, and the spine must be considered to be potentially unstable until proven otherwise. The anterior column contributes more to the stability of the spine in extension, and the posterior column exerts its major forces in flexion. Therefore, the anterior elements tend to be disrupted in hyperextension injuries, and the posterior elements tend to be disrupted in hyperflexion injuries. With extreme flexion or extension or if either a compressive or rotational force is added, both columns may be disrupted.

Flexion injuries usually cause compression of the anterior column and distraction of the posterior column (fig. 4).⁵ Pure flexion trauma may result in wedge fracture of the vertebral body without ligamentous injuries. These injuries are stable and are rarely associated with neurologic injuries. With more extreme trauma, elements of the posterior column are disrupted as well, and facet joint dislocation may result. These injuries are unstable and are associated with a high incidence of cord damage. *Flexion-rotation injuries* also commonly disrupt the posterior ligamentous complex and may also produce facet joint dislocation. They tend to be stable and are not usually associated with spinal cord injury, although cervical root injury is common. *Hyperextension injuries* cause compression of the posterior column

and distraction of the anterior column (fig. 4). Hyperextension combined with compressive forces (e.g., diving injury) may result in injury to the lateral vertebral masses, pedicles, and laminae. Because both anterior and posterior columns are disrupted, this injury is unstable and is associated with a high incidence of cord injury. Violent hyperextension, with fracture of the pedicles of C2 and forward movement of C2 on C3, produces a traumatic spondylolisthesis of the axis, or hangman’s fracture. The fracture is unstable, but the degree of neurologic compromise is highly variable, because the bilateral pedicular fractures serve to decompress the spinal cord at the site of injury.

Burst fractures are caused by compressive loading of the vertex of the skull in the neutral position and are not as common as flexion–extension injuries. Compression forces in the lower cervical spine result in the explosion of intervertebral disc material into the vertebral body. Depending on the magnitude of the compression loading and associated angulating forces, the resulting injury ranges from loss of vertebral body height with relatively intact margins, to complete disruption of the vertebral body. Posterior displacement (retropulsion) of comminuted fragments may result, producing cord injury; the spine is usually stable. Pure *distraction injuries* are uncommon but, if severe, may result in ligamentous disruption causing both cord trauma and an unstable spine.

Determining Stability of the Cervical Spine after Injury

Because spinal instability usually results in vertebral displacement, it may be detected in many instances by radiography. White and Panjabi⁸ identified the upper limit of vertebral displacement and that which is beyond the physiologic range. They concluded that a normal adult spine would not permit horizontal motion greater than 2.7 mm between vertebrae. Therefore, if horizontal displacement exceeding 3.5 mm (corrected for x-ray magnification) or 20% of the vertebral body width was

found on lateral radiographs of the neck (or with flexion-extension views or dynamic fluoroscopy), this motion was deemed abnormal and the spine was considered unstable. With respect to angular displacement, the upper limit of physiologic angular displacement of a vertebral body compared with adjacent vertebrae was 11°. If there is greater angulation of the vertebra in question demonstrated on imaging studies, the spine is deemed unstable at the site of the excessively rotated vertebra.

The ligamentous structures, intervertebral discs, and osseous articulations have been extensively studied, and their major role in determining clinical stability has been demonstrated.⁷ Although the muscles in the neck exert some stabilizing forces, the contribution that they make toward clinical stability has not been studied. The repeated observation that secondary neurologic injuries occur frequently in spine-injured patients who are not immobilized suggests that muscle splinting is not highly protective after injury.^{9,10}

Not all cervical spine injuries result in clinical instability. Generally, fractures are considered to be clinically insignificant if failing to identify them would be unlikely to result in harm to the patient or, alternatively, recognizing the injury would prompt no specific treatment. Two groups have categorized, by expert consensus, a number of injuries as not clinically important.^{11,12} The National Emergency X-Radiography Utilization Study (NEXUS) group identified the following injuries as not clinically significant: spinous process fractures, wedge compression fractures with loss of 25% or less of body height, isolated avulsion fractures without ligament injury, type 1 odontoid fractures, end-plate fractures, isolated osteophyte fractures, trabecular fractures, and isolated transverse process fractures.¹¹ Similarly, the Canadian CT Head and Cervical Spine Study group identified the following injuries as not significant: simple osteophyte fractures, transverse process fractures, spinous process fractures, and compression fractures with loss of less than 25% of body height.¹²

Mechanisms of Spinal Cord Injury

There are a number of mechanisms implicated in primary spinal cord injuries. Immediate neural damage may result from shear, compressive, ballistic, or distracting forces, which primarily avulse and devitalize tissues. Persistent cord compression from fracture-dislocation may lead to ischemia. The cord may be injured by bone fragment or missile injury with resultant laceration, contusion or concussion.¹³ Secondary and progressive injury may also result from local perfusion deficits due to vascular compression by deranged anatomy (e.g., tissue damage or edema) or from global perfusion compromise caused by systemic hypotension. In addition, tissue hypoxemia leading to secondary injury may also occur as a result of hypoventilation caused by head or cord injury

or by primary lung trauma. Finally, there are multiple mechanisms at the cellular and subcellular level that may result in exacerbation of the injury resulting in an extension of the clinical deficit.¹⁴

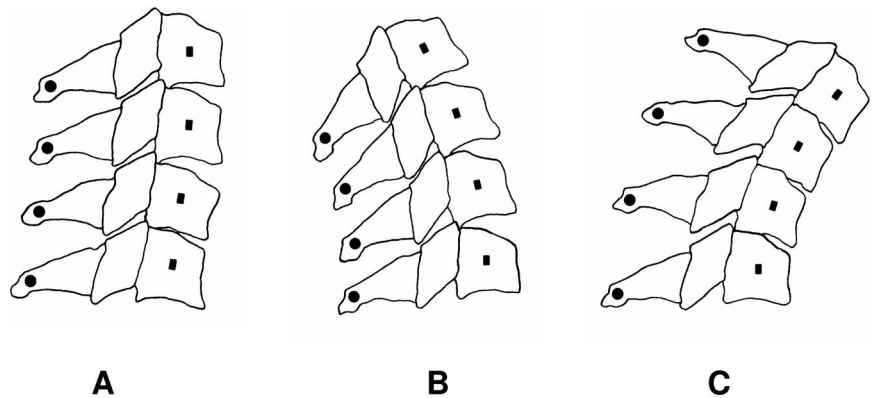
The impact of persistent cord compression and the benefits of urgent decompression of injured cord have been assessed by a number of authors. Carlson *et al.*¹⁵ determined the relation between the duration of sustained spinal cord compression and the extent of spinal cord injury and the capacity for functional recovery after immediate decompression. Sixteen dogs underwent spinal cord compression for 30 or 180 min. Sustained cord compression was associated with a gradual decline in the amplitude of evoked potentials. Within 1 h of decompression, dogs that had experienced 30 min of compression had recovery of the evoked potentials, but no animal that had been subjected to 180 min of compression had similar recovery. Motor tests demonstrated rapid recovery of hind-limb function in the 30-min group, but there was considerable impairment in the 180-min group, and this impairment was persistent. In a similar model, Delamarter *et al.*¹⁶ demonstrated that neurologic recovery after 1 h of cord compression occurred after immediate decompression but not when cord compression persisted for 6 h or more.

Despite the basic science support for early decompression after spinal cord injury, two recent reviews have concluded that the evidence supports decompression as a practice option only.^{17,18} The authors of these reviews concluded that the data assessing the impact of early decompression on neurologic outcomes was limited, consisted of primarily class III (case series, retrospective reviews, and opinion) and limited class II (prospective cohort studies or controlled studies with comparison cohorts) evidence, and demonstrated a possible benefit to patients with incomplete injury only. Both early decompression and conservative management were associated with neurologic improvement in some patients and deterioration in others. Both groups of authors acknowledged the need for randomized, controlled trials to better delineate the role of surgery in the management of acute spinal cord injury.^{17,18}

Biomechanics of the Spinal Cord and Canal

For proper functioning of the spinal cord, a minimum canal lumen is required, both at rest and during movement. Cord compromise will result if the canal space is less than that required for cord function; neurologic injury will occur if this reduction in canal space is persistent. The neurologic injury results from sustained mechanical pressure on the cord leading to both anatomical deformation and ischemia. A reduction in canal size is often seen with age-related changes in spinal anatomy such as disc degeneration, osteophyte formation, hypertrophy of the ligaments of the spinal column, and the vertebral subluxations common in the chronic arthriti-

Fig. 5. The Poisson effect: schematic representation. The axis of rotation is indicated by the *small squares* superimposed on the vertebral bodies. In the neutral position (A), the gentle arc of the normal lordotic curve is transcribed. In extension (B), the elements posterior to the bodies, including the canal, transcribe the arc of a smaller circle than that of the vertebral bodies, indicated by the *small circles*. In flexion (C), the opposite effect is seen, and the arc of a larger circle is transcribed by the posterior elements. The Poisson effect dictates that as the length increases (the arc is of a larger circle), the cross-sectional area (lumen) of the column will decrease.



des. Canal size may also be reduced acutely with traumatic injury to the spinal column. Although neurologic deficits do not directly correlate with the degree of posttraumatic reduction of the spinal canal, canal impingement is more commonly observed in patients with both spinal injury and neurologic deficit than in patients who do not have a deficit after spinal injury.¹⁹

The functional size of the spinal canal may be further reduced with movement. The spinal canal is a column of relatively fixed volume.²⁰ As it lengthens, its cross-sectional area will be reduced, and as it is shortened, its area will be increased; this behavior is termed the *Poisson effect*. With flexion, the canal length is increased and its area is reduced; the cord is stretched. This occurs because the axis of rotation of the spine is centered in the vertebral body.²¹ As the spine flexes, the rotation points will transcribe an arc; posterior spinal elements, including the canal, will also transcribe an arc, but that of a larger circle and will axially lengthen (fig. 5).²² The Poisson effect dictates that both the lumen of the canal and the spinal cord will narrow as they lengthen. The cord will tolerate a degree of elastic deformation while maintaining normal neurologic function.²⁰ It may be further stretched and deformed if there is a local anomaly such as an osteophyte, prolapsed disc, or subluxed vertebral body projecting into the canal. These deformations may, over time, result in the application of strain and shear forces to the cord and ultimately result in axonal injury and myelopathy.²³

With extension, the canal length is decreased and its area is increased; the cord is shortened. Again, this is an effect of the axis of rotation being centered in the vertebral bodies and the posterior spinal elements including the canal now transcribing the arc of a smaller circle; the Poisson effect will dictate canal widening. However, the shortening and folding of the cord when the spine is in extension may result in a relative increase in the ratio of cord size to canal lumen, despite the potential increase in the lumen. As well, there is posterior protrusion of the disc annulus and buckling of the ligamentum flavum in extension, which may further reduce canal dimensions and the space available for the cord at any given verte-

bral level. A number of age-related pathologic processes, including osteophyte formation and ossification of the posterior longitudinal ligament, may lead to further impingement on the canal lumen; these typically manifest a greater impact during spinal extension.

Ching *et al.*²⁴ measured the impact of different positioning on canal occlusion in a cervical spine burst fracture model. Extension increased the canal occlusion to levels normally associated with the onset of neurologic injury. Flexion did not result in a significant increase in canal occlusion. These observations run counterintuitive to what might be expected on the basis of the Poisson effect and are likely manifestations of both the soft tissue buckling and bone fragment retropulsion which occur during extension. Prone positioning is also often associated with modest degrees of extension, and there is evidence that canal stenosis is increased with patients with cervical myelopathy who are positioned prone compared with supine positioning.²⁵ Again, this is likely a manifestation of the soft tissue encroachment on the spinal canal with extension and aggravated by the preexistent canal compromise. The clinical relevance of these findings is that a persistent malposition of an abnormal neck may result in a degree of cord compression. If the abnormality is modest, it is likely that the malposition will need to be of greater magnitude and more prolonged to cause harm; as the anatomical derangement is increased, the duration of positional stress required to cause harm is shortened.^{15,26} Prone positioning is also associated with increases in vena caval pressures that may further reduce cord blood flow already compromised by cord compression.²⁷

Dominguez *et al.*²⁸ reported the occurrence of irreversible tetraplegia in a 21-yr-old woman without cervical pathology whose neck was maintained in extreme flexion after tracheal reconstruction; a magnetic resonance imaging (MRI) study was consistent with cord infarction. Deem *et al.*²⁹ reported the occurrence of quadriplegia in a 60-yr-old man with severe cervical stenosis after thoracolumbar surgery in the prone position. The patient's trachea was intubated, and he was positioned prone while still awake; anesthesia was in-

duced after his cervical spinal positioning was ascertained to be near neutral, and neurologic examination results were deemed normal. When he awoke from anesthesia after 6 h of surgery, there was evidence of a central cord syndrome. The authors acknowledge the possibility that, even though extreme degrees of flexion and extension were avoided, more subtle degrees of malpositioning may have been present. Unfortunately, cord injury may occur when positions detrimental to canal architecture are persistent; the greater the degree of underlying spinal pathology is, the lesser the magnitude of malpositioning required to cause harm is. The prone position may be especially threatening in these instances for the reasons already outlined.

Patients with severe cervical spondylosis may manifest such severe positional intolerance that they develop symptoms of cord compromise with degrees of malpositioning that may be imperceptible to the caregivers. Miller *et al.*³⁰ described exacerbation of neurologic symptoms in a 74-yr-old woman with an osseous bar at C3–C4 who presented with signs of cord compression and was booked for cervical laminectomy. On the first surgical occasion, after awake tracheal intubation accomplished with sedation, she was considerably weaker than before intubation. Surgery was cancelled, and her trachea was extubated; her neurologic condition returned to baseline within 2 h. Four days later, she presented for surgery in halo traction, and after sedation with intravenous diazepam, her neurologic condition deteriorated. A joint decision was made to induce anesthesia and proceed with tracheal intubation and surgical laminectomy at the C3–C5 spinal levels. Although she awoke with signs of neurologic deterioration, she recovered to her baseline condition by the fourth hour. The authors of this report postulated that the increased neurologic symptoms were an effect of the medications administered to facilitate awake intubation. Whether the drugs actually caused deterioration in the patient's neurologic status or made the neurologic assessment less reliable is not certain. Equally unknown is whether, in general, patients might be more likely to overlook or underreport neurologic changes that occur if they were sedated during awake intubation. The reliability of a neurologic assessment in a sedated patient might be questioned, especially if one is seeking evidence of subtle changes.

Bejjani *et al.*³¹ reported the case of a 54-yr-old woman with cervical spondylosis and canal stenosis from C4 to C7 who developed signs of cord compression while her head was restrained in a plastic head-holder for the purpose of cerebral angiography. Approximately 45 min after the procedure had begun, she reported neck pain and upper extremity weakness; her symptoms were attributed to anxiety, and she was sedated. At the termination of the procedure, she was hemiparetic on the left side; an MRI study revealed a high-signal lesion consistent with edema. She recovered completely over the

next 6 weeks. The potential for general anesthesia to permit positioning for MRI in postures not tolerated by awake patients with resultant neurologic injury has also been reported.³²

Magnaes³³ measured cerebral spinal fluid pressure with the neck in the extended position for tracheal intubation, in eight patients with a compromised spinal canal due to cervical spondylosis. Pressures up to approximately 140 cm H₂O were recorded. Longitudinal skeletal traction with the tong placed frontally significantly reduced the pressure on the spinal cord in all patients. This finding would suggest that there is likely a benefit, in terms of decreased intracanal pressures, in maintaining the compromised cervical spine in as close to the neutral position as possible at all times after injury. As has already been noted, it may be very difficult to determine neutral position in some patients.

Persistent severe malpositioning at the extremes of the spinal range of motion has the potential to cause harm even in the normal spine-cord complex. In patients with disease processes that result in spinal canal compromise, minor degrees of malpositioning may also result in severe stress to the cord. If these positions are enforced, especially for prolonged periods, neurologic injury may result. As well, the use of sedation or anesthesia to allow patients to be maintained in positions that are neurologically intolerable to them while awake may also result in neurologic injury.

Cervical Spine Trauma: Epidemiology and Clinical Characteristics

The Incidence of Cervical Spinal Injury after Blunt Trauma

The incidence of CSI in victims of blunt trauma is estimated to be 0.9–3%, with a weighted average of 1.8%.³⁴ Many of these previously published studies evaluating CSI after blunt trauma involved data from individual institutions or limited populations of trauma victims; there have been few data available regarding injury patterns at a national level. A substudy of NEXUS was designed to provide such data regarding the prevalence, spectrum, and distribution of CSI after blunt trauma.³⁵ A total of 34,069 patients with blunt trauma undergoing cervical spine radiography at 21 US institutions were enrolled. Consistent with past reports, 818 (2.4%) of trauma victims had a total of 1,496 distinct CSIs. The second cervical vertebra (C2) was the most common level of injury (24.0% of all fractures), and 39.3% of fractures occurred in the two lowest cervical vertebrae (C6, C7). The vertebral body was the most frequent anatomical site of fracture; nearly one third of all injuries (29.3%) were considered clinically insignificant.

Cervical Spine Injury and Associated Craniocerebral Trauma

Although it has been reported that patients with craniocerebral trauma had an incidence of CSI similar to that of the general trauma population, review of the large databases evolving at major trauma centers now dispute this finding. Holly *et al.*³⁶ reviewed 447 consecutive, moderately to severely head-injured patients presenting to two level 1 trauma centers. Twenty-four patients (5.4%) had a CSI; patients with an initial Glasgow Coma Scale (GCS) score less than 8 were more likely to sustain both a CSI and a cord injury than those with higher scores. Demetriades *et al.*³⁷ conducted a similar review of all CSI patients admitted over a 5-yr period at a major trauma center. During the study period, there were 14,755 admissions and 292 patients with CSI, for an overall incidence of 2.0%. Again, the incidence of CSI varied with the GCS score, being 1.4% if the GCS score was 13–15, 6.8% when it was 9–12, and 10.2% when it was less than 8. Hackl *et al.*³⁸ used a large computerized database to assess the association between CSI and facial injuries in 3,083 patients with facial injuries. Two hundred six (6.7%) of these patients had experienced a concomitant CSI, an incidence substantially higher than would be expected after blunt trauma. Blackmore *et al.*³⁹ reviewed their institutional experience with 472 patients with trauma (168 with cervical fractures, 302 without fractures) to delineate the clinical characteristics of trauma patients with cervical fracture. The clinical predictors of cervical spine injury included severe head injury (odds ratio, 8.5; 95% confidence interval [CI], 4–17) and focal neurologic deficit (odds ratio, 58; 95% CI, 12–283). In patients with head injury, those who were persistently unconscious had an even higher likelihood of spinal injury (odds ratio, 14; 95% CI, 6–35) than those with head injury who were not unconscious. Therefore, new evidence has emerged that consistently suggests a higher incidence of cervical injury in patients who have experienced craniocerebral trauma, especially among those with increasing severity of craniocerebral injury as determined by low GCS score and unconsciousness. The finding of a focal neurologic deficit has been identified as a highly important clinical finding predicting spinal injury.³⁹

Systemic Injuries Associated with Cervical Spine Injury

The majority of patients with CSI also have other injuries; in only 20% of instances are traumatic injuries restricted to the cervical spine.⁴⁰ Although 2–10% of patients with craniocerebral trauma have CSI, 25–50% of patients with CSI have an associated head injury. Patients with additional injuries are more likely to experience hypoxia and hypotension, both of which may not only prompt urgent airway intervention, but may also predispose to secondary neurologic injury. There is data to

suggest reduced neurologic recovery and increased mortality in cord-injured patients who have concurrent injury. It is not clear whether these patients experienced more severe primary injury or whether they are more likely to experience secondary injury leading to the poorer outcome.

Defining the Low-risk Trauma Patient

The National Emergency X-Radiography Utilization Study. The majority of patients who have experienced a blunt traumatic injury do not have a CSI. Enormous resources are currently expended to clear the spine (determine the absence of injury when injury does not exist) in these patients. The NEXUS project attempted to derive a set of clinical criteria to identify blunt trauma victims at low risk for CSI.⁴¹ The decision instrument required patients to meet five criteria to be classified as having a low probability of injury: (1) no midline cervical tenderness; (2) no focal neurologic deficit; (3) normal alertness; (4) no intoxication; and (5) no painful, distracting injury. Distracting injuries were defined as including long bone fractures; visceral injuries requiring surgical consultation; large lacerations; burns; degloving or crush injuries; or any injury that might impair the patient's ability to participate in a general physical, mental, or neurologic examination. The decision instrument was applied to 34,069 patients and identified as high risk all but 8 of the 818 patients who had a CSI (sensitivity, 99%; 95% CI, 98–99.6%). The negative predictive value was 99.8% (95% CI, 99.6–100%), the specificity was 12.9%, and the positive predictive value was 2.7%. Only two of the eight patients missed by the screening protocol had a clinically significant injury. In the NEXUS study, plain radiographs alone revealed 932 injuries in 498 patients but missed 564 injuries in 320 patients.⁴² The majority of missed injuries (436 injuries in 237 patients) occurred in cases in which plain radiographs were interpreted as abnormal (but not diagnostic of injury) or inadequate. However, 23 patients had 35 injuries (including three potentially unstable injuries) that were not visualized on adequate plain film imaging. In the absence of all five clinical risk factors identified by the NEXUS study as predicting an increased risk of CSI, the likelihood of a significant injury is low. The practice of withholding imaging for patients who meet these exclusionary criteria has been endorsed by recent neurosurgical guidelines.⁴³

The Canadian C-Spine Rule for Radiography after Trauma. The Canadian CT Head and Cervical Spine Study Group attempted to derive an optimally sensitive clinical decision rule to allow for selectivity in the use of radiography in alert and stable trauma patients.¹² A prospective cohort study was conducted in 10 large Canadian hospitals and included 8,924 consecutive adult patients presenting to emergency departments after

sustaining acute blunt trauma to the head or neck. Patients were eligible for enrollment if they were alert (GCS of 15), if they had stable vitals signs, and if they had either neck pain after injury or had no neck pain but visible injury above the clavicles after a dangerous mechanism of injury. The patients were assessed using 20 standardized clinical findings from the history, general physical examination, and an assessment of neurologic status. Patients then underwent diagnostic imaging at the discretion of the treating physician; this imaging consisted of a minimum of three views of the cervical spine.

Among the study sample, 151 patients (1.7%) had an important cervical injury. The resultant rule that was derived comprises three questions: (1) Is there any high-risk factor present that mandates radiography? (2) Are there low-risk factors that would allow a safe assessment of a range of motion? and (3) Is the patient able to actively rotate the neck 45° to the left and to the right? When applied to the study population, the derived rule had 100% sensitivity and 42.5% specificity for identifying patients with clinically important injuries. The rule also identified 27 of 28 patients with clinically unimportant cervical injuries (primarily avulsion fractures), defined as those not requiring stabilization or follow-up.

The NEXUS Low-Risk Criteria were compared prospectively with the Canadian C-Spine Rule in 8,283 patients presenting to Canadian hospital emergency departments after trauma.⁴⁴ Two percent of patients had clinically important cervical injuries, and the C-Spine Rule was both more sensitive than the NEXUS criteria (99.4% *vs.* 90.7%) and more specific (45.1% *vs.* 36.8%) for injury. The C-Spine Rule would have missed one patient, and the NEXUS criteria would have missed 16 patients with important injuries.

Strategies to define a low-risk clinical population continue to evolve. It must be emphasized that the primary focus and utility of these strategies is to allow for selective use of diagnostic imaging in patients who have a low-risk of injury, thus reducing imaging use and patient exposure, conserving resources, and allowing for expedited and simplified care for this patient group. A criticism leveled at the NEXUS protocol is that application would have a limited impact in reducing imaging because only 12.9% of patients presenting after trauma would be deferred; most would not meet at least one deferral criteria.⁴⁵ Application of the C-Spine Rule would allow for the exclusion of 42.5% of trauma patients from radiographic imaging. The original rationale for the derivation of the protocols, to provide more efficient care and conserve imaging resources, is satisfied to a very limited degree by the NEXUS protocol but to a greater degree by the C-Spine Rule. Application of either protocol will still demand imaging in a large portion of the trauma patient population at low risk for CSI.

There will be a small population of patients presenting

for urgent surgical intervention after minor injury who are fully evaluable using either the NEXUS criteria (12.9%) or the C-Spine Rule (42.5%); it is likely not necessary to delay surgery to clear the cervical spine of these patients with detailed imaging. Unfortunately, many patients presenting for urgent operative interventions after trauma will manifest more severe injuries; it will not be possible to clinically rule out injury in this patient cohort, and they will still require diagnostic imaging. As well, application of these protocols is complicated by the fact that there is a lack of agreement on the definitions of both *distracting injury* and *intoxication*. Failure to appreciate the degree of both distraction and intoxication may reduce the clinical index of suspicion for injury, resulting in missed diagnosis.

Patterns of Practice in Evaluating and Clearing the Cervical Spine after Trauma

Two authors have recently reported descriptions of patterns of practice in the United States and the United Kingdom obtained through postal surveys regarding evaluation and clearance of the cervical spine after trauma.^{46,47} Grossmann *et al.*⁴⁶ surveyed 165 US trauma centers and reported that between 26 and 73% had written protocols for cervical spine clearance after trauma. It was more common for level I and academic centers to have protocols. In most instances where a protocol existed, it also described the radiographic approach to clearance; most centers did not consider that either computerized tomography (CT) or MRI was the standard of care in this setting. The use of a five-view series was moderately prevalent in response to specific scenarios, and the problem of visualizing the cervicothoracic junction was dealt with in most centers (68%) using an axillary/swimmer's radiographic view. For patients with a head injury who are comatose or who have altered mental status and who have normal plain films, 21% of level II and 10% of level I centers advocated removal of the cervical collar without further testing beyond a five-view series.

Jones *et al.*⁴⁷ surveyed 27 United Kingdom neurosurgical and spine injury units to determine the methods of cervical spine clearance used in unconscious, adult trauma patients and the point at which immobilization was discontinued. Most centers did not have either a written protocol to perform clearance or one regarding discontinuing cervical immobilization (78%). All units relied to some degree on plain radiography for clearance; 10 units (37%) performed only a single lateral view as the initial evaluation, and the remainder performed two more views. Five units routinely used CT imaging, and 17 units (63%) made no use of CT to screen for cervical injury. If the initial investigations were normal, 12 units (44%) would discontinue immobilization, and 10 units continued it until the patient could be evaluated

clinically irregardless as to the results of the screening imaging.

The Eastern Association for the Surgery of Trauma recently reported the results of a survey of 31 large American and Canadian trauma centers.[†] Centers were asked to identify their routine practice for determining cervical spinal stability in obtunded or comatose patients. Twenty-four centers (77%) reported using three views of the cervical spine (lateral, odontoid, and antero-posterior views) supplemented by CT through suspicious or poorly visualized areas. Three centers (9.7%) relied on three views only, and three centers (9.7%) added a swimmer's view to visualize the lower cervical spine and the cervicothoracic junction.

There is considerable variation in the approach that different centers take in the performance of radiographic evaluation of at-risk patients, making the determination that the spine has been cleared, and reaching the decision that immobilizing devices can be safely removed. The most common pattern of practice in North American centers is to rely on multiple (at least three views) plain radiographs; the use of supplementary CT is also common.

Radiographic Assessment after Blunt Trauma: Evolving a Best Practice

An evaluative approach that would provide timely and accurate assessment of cervical stability in patients who may not be reliably examined clinically so that immobilizing devices can be safely removed is desirable. This would minimize the potential for sequelae related to prolonged immobilization. The reader is referred to three excellent reviews on the topic of evaluating and clearing the cervical spine in high-risk patients; these reviews form the basis of the subsequent discussion.^{45,48,49}

The cross-table lateral radiograph, of acceptable quality and interpreted by an expert, will disclose the majority of injuries. However, the sensitivity of the cross-table view is such that up to 20% of patients with cervical injury will have a normal study. Half of cross-table views are deemed inadequate to properly assess the entire cervical anatomy; injuries at both the craniocervical and the cervicothoracic junctions are often not well visualized in the cross-table view. Too many injuries are missed when only a cross-table view is used for it to be considered an acceptable study to rule out injury in a high-risk patient. The sensitivity of three views (cervical series) approximates 90%; the cervical series was long regarded as an acceptable radiologic evaluation in patients deemed at risk for CSI. Similar technical concerns

apply to the cervical series as to the cross-table lateral view with respect to both anatomical limitations at the cervical junctions and inadequate studies being issues. It is estimated that 1% of clinically important injuries will be missed even with a technically adequate cervical series.

A three-view cervical series supplemented by CT through areas that are either difficult to visualize or suspicious on plain radiography will detect most spinal injuries. The negative predictive value of this combination of studies is reported to be 99–100% in several class II and III evidence studies.^{45,48,49} In the obtunded patient with a normal cervical series and appropriate supplemental CT of the cervical spine, the incidence of significant spine injury is less than 1%. High-resolution CT scanning with sagittal reconstruction of the entire cervical spine rather than directed scanning of only at-risk areas may be even more effective in capturing virtually all injuries.

The use of MRI in addition to plain radiography and supplemental CT has been advocated to perform spinal clearance; the significance of a positive MRI study in the setting of negative CT imaging is currently unclear because many false-positive findings are reported with MRI. As well, MRI is less sensitive than CT for injuries in the upper and posterior cervical spine. Shuster *et al.*⁵⁰ studied the role of MRI in assessing the spines of patients with persistent cervical pain and no motor deficits after trauma when the CT imaging was negative for injury. Ninety-three patients (3.4%) had a normal admission motor examination, a CT result negative for trauma, and persistent cervical spine pain; they underwent MRI examination. All MRI examinations were negative for clinically significant injury, and no patient subsequently experienced a neurologic deterioration. Hogan⁵¹ assessed the role of magnetic resonance imaging in 366 obtunded or unreliable patients who had normal CT imaging after trauma. Magnetic resonance images were negative for acute injury in 354 of 366 patients; the most common injury seen was a cervical cord contusion, identified in 7 patients. Magnetic resonance images were also negative for spinal ligament injuries in 362 of 366 patients; 4 patients had ligament injuries, but in all cases, the injury was limited to the ligaments of a single column. CT had negative predictive values of 98.9% for ligament injury and 100% predictive value for unstable cervical injury; MRI identified a small number of patients with ligament injuries not diagnosed with CT, but none of these were deemed to be unstable injuries.

In summary, in a patient at high risk for cervical injury, who cannot be evaluated clinically, a three-view cervical series supplemented by high-resolution CT scanning with sagittal reconstruction will reduce the likelihood of an occult fracture to less than 1%. After a technically adequate imaging series has been reviewed and cleared by a radiologist, it is prudent to remove cervical immo-

[†] Eastern Association for the Surgery of Trauma: Determination of cervical spine stability in trauma patients. Winston-Salem, North Carolina, EAST, 2000. Available at: www.east.org/tpg/chap3u.pdf. Accessed October 27, 2005.

bilization. If there is evidence of a neurologic deficit referable to the cervical spine despite the finding of normal cervical radiography and CT imaging, MRI should be considered.

Spinal Ligament Injuries and Spinal Cord Injury without Radiographic Abnormality

Spinal ligament injuries are of particular concern because of the high incidence of resultant spinal instability, the potential for cord injury, and the hemodynamic instability common at presentation in this subpopulation. In Demetriades³⁷ review of CSI patients admitted during 5 yr to a major trauma center, 31 patients (10.6%) had a ligament injury (subluxation without fracture), and 11 patients (3.8%) had an isolated spinal cord injury without fracture or subluxation (spinal cord injury without radiographic abnormality [SCIWORA]). Of the 31 patients with ligament injury, one third required tracheal intubation before clinical evaluation of the spine was completed. Of the 11 patients with spinal cord injury without radiographic abnormality, 27.3% required intubation before spinal evaluation occurred. The diagnosis of cord injury was made on admission in only 5 patients (45.5%) with spinal cord injury without radiographic abnormality. In 3 patients, the neurologic examination on admission was normal, and neurologic deficits appeared a few hours later. In the remaining 3 patients (2 intubated, 1 intoxicated), the diagnosis was missed initially. Patients who required urgent airway intervention were less likely to have had a complete neurologic evaluation and were more likely to have neurologic injury than those who did not require urgent interventions. Chiu *et al.*⁵² also investigated the incidence of cervical spinal ligament injury in 14,577 blunt trauma victims. Six hundred fourteen patients (4.2%) had CSI, and 87 (14% of CSI) had dislocation without evidence of fracture. There were 2,605 (18%) patients who could not be assessed for symptoms, and 143 (5.5%) of these unreliable patients had a CSI; 129 (90%) had a fracture, and 14 had no fracture.

Trauma patients with greater severity of injury are more likely to have had a CSI; clinical evaluation is more difficult in these patients, typically because of depressed consciousness. Patients with ligament injury of the cervical spine without fractures frequently require urgent intubation, and not uncommonly, clinical evaluation is either not possible or not complete at the time that intervention is required; delay in the diagnosis of injury is common in these patients.

Failure to Diagnose Cervical Spine Injury at Initial Assessment: Factors and Consequences

Patients with decreased mental status from trauma, alcohol, or drugs and patients with other painful or distracting injuries have an unreliable history and physical examination for CSI; patients with these char-

acteristics have spinal injuries that are also more likely to be missed on initial presentation. The commonest reasons for missed diagnosis are failure to obtain radiographs, poor quality of the imaging study, or misinterpretation of the radiographs.^{9,10} Inadequate radiographic studies are more likely in patients with hemodynamic compromise on admission or in those patients urgently requiring intervention for operative treatment of associated injuries. Unfortunately, missed injuries are often unstable, and secondary neurologic lesions occur in 10–29% of patients whose injuries are not diagnosed at initial evaluation.^{9,10} Failure to immobilize the spine in patients whose injuries are missed at the initial assessment is considered to be a leading cause of secondary injury.

Poonnoose *et al.*⁵³ conducted a detailed review of the experience of a specialty spinal cord injury unit to determine both the incidence of missed injury and the clinical mismanagement that occurred in the setting of missed injury. The medical records of 569 patients with neurologic deficits secondary to traumatic spinal cord injury were reviewed. In 52 instances (9.1%), the diagnosis was initially missed, and 26 of these patients (50%) had evidence of neurologic deterioration after admission to care. The median time to recognition of the injury was 4 days. Therapeutic interventions were performed in 34 patients that were deemed inappropriate to their condition before the diagnosis was made. In 19 patients, there were significant neurologic findings present on initial assessment, and in 7, the initial neurologic deficit was minimal. Nine patients eventually developed paralysis, and 6 died with the deaths attributed to the delay in diagnosis. Again, the major cause for delayed diagnosis was related to radiographic assessments: In 18 cases, the initial images were of poor quality; in 11 patients, the area of concern was not adequately visualized; in 10 cases, an obvious fracture was missed; in 11 cases, facet joint malalignment was not recognized; and in 10 cases, prevertebral hematoma went undetected. It was common for the clinicians to consider the spine cleared when the radiographs “failed” to reveal injury and to attribute neurologic findings to either preexistent conditions (*e.g.*, ankylosing spondylitis) or peripheral traumatic injuries. As well, 7 patients with evidence of neurologic deficits were initially labeled as “hysterical” and not managed as at-risk.

It is unfortunately the case that patients with CSI are frequently not correctly diagnosed at the time of initial presentation.^{9,10,53,54} This may occur in a small percentage of CSI patients because the injury is a ligamentous one and the screening imaging seems on initial review to be negative.^{37,54} However, it more commonly occurs because there is a low index of suspicion for injury despite high-risk mechanisms, inadequate radiographic studies are deemed acceptable, and neurologic signs or symptoms are either attributed to other causes or ig-

nored entirely. Delayed diagnosis is associated with a very high incidence of secondary injury, and the magnitude of that injury is often considerable.^{9,10,53,54}

Secondary Neurologic Injury after Cervical Spine Injury

Secondary injury may be precipitated in CSI victims when management is suboptimal, and in particular when the injured spine is not immobilized. However, there is also evidence that neurologic deterioration occurs after acute injury despite appropriate management paradigms; the reported incidence of neurologic deterioration in this setting ranges from 2 to 10%.⁵⁵ Frankel⁵⁶ reported the occurrence of an ascending myelopathy 2–18 days after spinal cord injury despite appropriate clinical management. Only patients with ascension of injury level of at least four levels were included in this analysis; despite the high threshold for inclusion, this magnitude of secondary injury occurred in 1% of 808 patients admitted to the center. Frankel attributed the deterioration to either vascular catastrophes (arterial insufficiency or venous thrombosis) or inflammation; this report predated MRI, so no imaging is available in these patients to support the clinical conjecture. Marshall *et al.*⁵⁵ reported a prospective study assessing neurologic deterioration in cord-injured patients conducted in five US trauma centers. Deterioration occurred in 4.9% of patients and was consistent across the five centers. Although the deterioration was often associated with a specific intervention (surgery in 4 patients, traction application in 3, halo vest application in 2, Stryker frame rotation in 2, and rotobed rotation in 1), there was no evidence that these procedures were performed poorly or that they could have been performed in an altered fashion to prevent the deterioration. There were 375 such interventions recorded among the 283 patients. The authors concluded that deterioration is an inevitable consequence of providing care to cord-injured patients and will occur in some patients despite acceptable care practices.

Farmer *et al.*⁵⁷ reported the experience of a US regional spinal cord center regarding neurologic deterioration after cervical cord injury. Deterioration was evident in 1.84% of 1,031 patients assessed. The average time from injury to deterioration was 3.95 days, and deteriorations were associated with early surgery (< 5 days after injury), sepsis, ankylosing spondylitis, and tracheal intubation. Tracheal intubation was associated with two minor and two major deteriorations, but no further details were offered regarding this cohort; it is possible that the intubation was necessitated by the neurologic deterioration and not the cause of it. In the patients who experienced deterioration and survived, 92% of patients eventually had improvement in their neurologic status. Harrop *et al.*⁵⁸ analyzed the cases of

12 of 186 patients (6%) with acute traumatic cord injuries who demonstrated neurologic ascension within 30 days after injury. Three subgroups were defined: an early deterioration group who worsened within 24 h, a delayed deterioration group (1–7 days), and a late (beyond 7 days) deterioration group. Two patients in the late group had vertebral artery injury; vertebral artery injury is common after midcervical injury, and its clinical significance is uncertain.^{59,60}

Yablon *et al.*⁶¹ described 14 cases of ascending myelopathy (involving 1–4 levels) that occurred in the first 4 weeks after injury. These cases were attributed to spinal cord edema; MRI studies demonstrated evidence of this as well as diffuse intrathecal hemorrhage. Belanger *et al.*⁶² identified a similar occurrence of ascending myelopathy, which they labeled as subacute post-traumatic ascending myelopathy, occurring within the first 2 weeks after injury. This syndrome occurred in three patients who experienced neurologic deterioration with a secondary injury ascending six or more levels (6, 9, and 17 levels) from the initial level after an uneventful early course. No etiologic factors could be identified. In all three patients, T₂ weighted MRI studies revealed a high signal intensity located centrally within the cord and extending rostrally from the site of injury. T₂-weighted images are sensitive to the presence of edema and effectively distinguish pathologic from normal tissue; the high signal intensity identified indicates injury and edema.

The above reports suggest that there is a progressive postinjury course in some patients leading to a secondary neurologic injury and ascension of injury level, sometimes to a striking degree. In some instances, this deterioration has been associated with clinical interventions, including immobilization, traction, surgery, intubation, and sepsis. In other instances, no clear factors are associated, and in particular, both extrinsic cord compression and vascular interruptions have been excluded. This syndrome, when witnessed early in the course after injury, has usually been attributed to vascular perturbations or cord edema and inflammation; MRI studies have been consistent with this attribution. More recent work has also suggested a role for apoptosis in the causation and progression of ascending myelopathy.⁶³ A diagnosis of ascending myelopathy must be considered when a secondary injury has occurred; there is natural temptation to attribute the deterioration to temporally related clinical interventions but, in fact, these interventions are rarely associated with neurologic sequelae. Progressive neurologic injury after CSI may be inevitable in some patients because of pathophysiologic processes initiated at the time of the application of the injuring forces and may occur despite the provision of appropriate management paradigms and interventions.

Clinical Care of the Spine-injured Patient

Spinal Immobilization in Trauma Patients: The Overview

During the past 30 yr, the neurologic status of spinal cord-injured patients arriving in emergency departments has dramatically improved, and the odds of dying during the first year after injury have been significantly reduced.^{64,65} The improvement in the neurologic status of patients has been attributed to improved initial care and retrieval systems, recognition of the importance of instituting prehospital spinal immobilization, maintaining immobilization until clearance is obtained or definitive therapy is applied, and hospital practices designed to prevent secondary injury. The routine use of spine immobilization for all trauma patients, particularly those with a low likelihood of spinal injury, has been challenged on the basis that it is unlikely that all patients rescued from the scene of an accident or site of traumatic injury require spine immobilization.⁶⁶ A Cochrane systematic review also concluded that the impact of immobilization on mortality, neurologic injury, and spinal stability was uncertain and that direct evidence linking immobilization to improved outcomes was lacking.⁶⁷ The Cochrane review further concluded that the potential for immobilization to actually increase morbidity or mortality could not be excluded based on a review of the literature. However, the current consensus among experts remains that all patients with the potential for a CSI after trauma should be treated with spinal column immobilization until injury has been excluded or definitive management for CSI has been initiated.⁶⁴

The benefits, consequences, and sequelae of spinal immobilization in at-risk patients have been recently analyzed, and the reader is referred to these reviews for more detailed discussions.^{64,68,69} The chief concern during the initial management of patients with potential CSI is that neurologic function may be further compromised by pathologic motion of the injured vertebrae. Management of the potentially traumatized spine emphasizes three principles: (1) restoration and maintenance of spinal alignment, (2) protection of the cord with preservation of intact pathways, and (3) establishment of spinal stability. To achieve these principles, immobilization of the cervical spine before radiographic assessment and clearance is the accepted standard of care. The rationale behind early immobilization is the prevention of neurologic injury in the patient with an unstable spine. Institution of a clinical care paradigm that features immobilization as a core element has resulted in improved neurologic outcomes in spine-injured patients during the past three decades.^{64,65} Failure to immobilize in the context of missed or delayed diagnosis is also associated with an increased incidence of neurologic injury.^{9,10,53} Lack of immobilization has been cited as a cause of neurologic deterioration among acutely injured trauma

patients being transported to medical facilities for definitive care.⁷⁰

A number of complications to prolonged immobilization have been identified.^{64,68,69} Cutaneous ulcerations (pressure sores) are common, and the incidence increases when immobilization is prolonged beyond 48–72 h. Airway management, central venous access and line care, provision of oral care, enteral nutrition, and physiotherapy regimes are all made more difficult when immobilization must be maintained. The need for multiple staff to allow for safe positioning and transfer of immobilized patients makes barrier nursing more difficult and may result in higher rates of cross-contamination and infection in high-dependency units.

The application of cervical collars has also been associated with increased intracranial pressure (ICP) in both injured patients and healthy volunteers. Davies⁷¹ prospectively analyzed ICP in a series of injured patients treated with a rigid collar. The ICP increased a mean of 4.5 mmHg when the collar was firmly in place. Kolb⁷² also examined changes in ICP after the application of a rigid Philadelphia collar in 20 adult patients. ICP averaged 17.68 cm H₂O initially and increased to an average of 20.15 cm H₂O after collar placement. Although the difference in ICP of 2.47 mm H₂O was statistically significant, it remains uncertain that it has clinical relevance. Nonetheless, this modest increase in pressure may be magnified in patients who already have increased ICP and poor intracranial compliance. The potential for complications should not discourage the use of immobilization where indicated. Rather, because many of the complications are time dependent, they should encourage attempts to promptly assess the patient for cervical injury to expedite the discontinuance of immobilization in those patients whose spines can be cleared.

Techniques and Devices for Preadmission Spinal Immobilization

The position in which the injured spine should be placed and held immobile, the “neutral position,” is poorly defined. De Lorenzo *et al.*,⁷³ in an MRI study of 19 adults, found that 2 cm of occiput elevation produced a favorable increase in spinal canal/spinal cord ratio at the C5 and C6 levels, a region of frequent unstable cervical spine injuries. Podolsky *et al.*⁷⁴ evaluated the efficacy of cervical spine immobilization techniques. Hard foam and hard plastic collars were better at limiting cervical spine motion than soft foam collars, although the use of collars alone did not effectively restrict spinal motion. The use of sandbag-tape immobilization was more effective at reducing spinal movement than any of the other individual methods tested. Adding a Philadelphia collar to the sandbag-tape construct reduced neck extension but had no effect on any other motion of the cervical spine. These authors found that sandbags and tape combined with a rigid cervical collar was the most effective con-

struct of those evaluated to limit cervical spine motion, restricting movement to approximately 5% of the normal range. The sandbag-tape-backboard-collar and variations thereof have become the most commonly used extrication and transport assembly in prehospital trauma care to provide spinal immobilization.

Bednar⁷⁵ assessed the efficacy of soft, semirigid, and hard collars to immobilize the neck in a destabilized elderly cadaver model. Bednar's experiment involved creation of unstable motion segments at the C3-C4, C4-C5, or C5-C6 levels; isolated posterior column, combined column, and then anterior column injuries were sequentially assessed. Soft, semirigid, and rigid collars were used in an attempt to restrict neck movements, and then the spines were subjected to unrestrained gravitational forces with flexion, lateral side-bending, and extension. The collars were not effective in reducing spinal movement; in fact, there was evidence for increased spinal movement. Bednar hypothesized that the increased movement resulted from the levering of the mobile head and proximal cadaver neck over the collar edge. The model described allowed for the application of forces that would rarely be applied or permitted in clinical settings but did emphasize the very limited role that collars would play in limiting spinal movement if the spine were subjected to very hostile forces.

Goutcher and Lochhead⁷⁶ measured maximal mouth opening (interincisor distance) in 52 volunteers, before and after the application of a semirigid cervical collar. Three collars were assessed: the Stifneck (Laerdal Medical Corp., Wappinger's Falls, NY), the Miami J (Jerome Medical, Moorestown, NJ) and the Philadelphia (Philadelphia Cervical Collar Co., Thorofare, NJ). Application of a collar significantly reduced interincisor distance from a mean of 41 ± 7 mm in the control state to 26 ± 8 mm with the Stifneck, 29 ± 9 mm with the Miami J, and 29 ± 9 mm with the Philadelphia. There was a wide variation between subjects, and a significant proportion had an interincisor distance reduced to less than 20 mm after application of the collar (Stifneck, 25%; Miami J, 21%; Philadelphia, 21%). Goutcher and Lochhead concluded that the presence of a semirigid collar significantly reduced mouth opening and would likely often interfere with airway management; removal of the anterior portion of the collar before attempts at tracheal intubation was encouraged by these authors.

Manual In-line Immobilization

The goal of manual in-line immobilization (MILI) is to apply sufficient forces to the head and neck to limit the movement which might result during medical interventions, most notably, airway management. MILI is typically provided by an assistant positioned either at the head of the bed or, alternatively, at the side of the stretcher facing the head of the bed. The patient is positioned supine with the head and the neck in neutral

position. Assistants either grasp the mastoid processed with their fingertips and cradle the occiput in the palms of their hands (head-of-bed assistant) or cradle the mastoids and grasp the occiput (side-of-bed assistant). When MILI is in place, the anterior portion of the cervical collar can be removed to allow for greater mouth opening, facilitating airway interventions. During laryngoscopy, the assistant ideally applies forces that are equal in force and opposite in direction to those being generated by the laryngoscopist to keep the head and neck in the neutral position.

Avoiding traction forces during the application of MILI may be particularly important when there is a serious ligamentous injury resulting in gross spinal instability. Lennarson *et al.*⁷⁷ noted excess distraction at the site of a complete ligamentous injury when traction forces were applied for the purposes of spinal stabilization during direct laryngoscopy. Similarly, Kaufmann *et al.*⁷⁸ demonstrated that in-line traction applied for the purposes of radiographic evaluation resulted in spinal column lengthening and distraction at the site of injury in four patients with ligamentous disruptions. Bivins *et al.*⁷⁹ reported that traction applied during orotracheal intubation in four victims of blunt traumatic arrest with unstable spinal injuries resulted in both distraction and posterior subluxation at the fracture site. It is possible that the fracture site distraction that was observed resulted from application of traction forces not appropriately axially aligned.

Majernick *et al.*⁸⁰ demonstrated that MILI reduced total spinal movement during the process of laryngoscopy and tracheal intubation; movement was not reduced to a similar degree by collars. Similarly, Watts *et al.*⁸¹ measured a reduction of spinal movement with the application of MILI during tracheal intubation in patients with normal spines during general anesthesia. However, Lennarson *et al.*⁸² were unable to demonstrate that application of MILI resulted in any significant reduction in movement during intubation in a cadaver model with a posterior column injury. In a cadaver model with complete ligamentous instability, Lennarson *et al.*⁷⁷ reported that application of MILI minimized distraction and angulation at the injured level but had no effect on subluxation at the site of injury.

Manual in-line immobilization may be effective in reducing overall spinal movements recorded during airway maneuvers but may have lesser restraining effects at the actual point of injury. This may be because spinal movement is restricted by the weight of the torso at the caudal end and the MILI forces at the cephalad end but is unrestricted by any force at its cervical midpoint. It is possible that application of traction forces during MILI would also reduce midcervical movement in some patients, but traction forces may also result in distraction at the site of injury; the use of such forces during applica-

tion of in-line immobilization continues to be discouraged.

Impact of MILI on the View Obtained at Laryngoscopy

The application of MILI during airway maneuvers may result in decreases in overall spinal movement, but the evidence also suggests modest, if any, effect at individual motion segments.^{77,82} However, the use of MILI may have lesser impact on the view obtained during direct laryngoscopy than relying on other immobilization techniques, such as axial traction or a cervical collar, tape, and sandbags. Heath⁸³ examined the effect on laryngoscopy of two different immobilization techniques in 50 patients. A grade 3 or 4 laryngoscopic view (partial or no view of the glottic structures) was obtained in 64% of patients immobilized with a collar, tape, and sandbags compared with 22% of patients stabilized with MILI. The laryngeal view improved by one grade in 56% of patients and by two grades in 10% when MILI was substituted for the collar, tape, and sandbags. The main factor contributing to the increased difficulty of laryngoscopy when patients were wearing cervical collars was reduced mouth opening. Gerling *et al.*⁸⁴ reported the findings of an analogous study using a cadaver model with a C5-C6 destabilization and arrived at similar findings. MILI allowed less spinal movement than did cervical collar immobilization during laryngoscopy and intubation and was associated with improved laryngeal visualization.

Hastings and Wood⁸⁵ measured the degree of head extension required to expose the arytenoid cartilages and glottis and determined the impact of applied MILI. The subjects were 31 anesthetized patients (24 study, 7 control) with normal cervical spines and Mallampati 1 views on preoperative airway assessment. Two methods of immobilization were assessed. Either axial traction was applied, wherein the assistant pulled the head in a caudal to cephalad direction as strongly as he or she thought was necessary to immobilize the neck, or force was applied to the head in a downward direction to hold the head onto the table. Without stabilization, the best view of the glottis was achieved with 10°-15° of head extension. Head immobilization reduced extension angles of 4°-5° compared with no stabilization, and it was more effective than axial traction immobilization in limiting extension. In 4 of the 24 study patients (17%), 2 in each immobilization group, the laryngoscopic view deteriorated from grade I or II to grade III with the application of immobilizing forces. Therefore, the use of MILI reduced the amount of head extension that was necessary for laryngoscopy but resulted in a poorer view in a portion of the patients studied.

Although MILI seems to have the least impact of all immobilization techniques on airway management, it may make direct laryngoscopy more difficult in some patients than if no immobilizing forces are being applied.

Nolan and Wilson⁸⁶ assessed the impact of MILI with cricoid pressure on the view obtained at laryngoscopy in 157 normal patients and compared it with the view obtained in the same patients while in the sniffing position. With application of MILI and cricoid pressure, the view remained the same in 86 patients (54.8%), was worse by one grade in 56 (35.6%), and was worse by two grades in 15 (9.5%). A grade 3 view (partial glottic view) was obtained in 34 restrained patients (21.6%) compared with 2 (1.3%) in the sniffing position. Wood *et al.*⁸⁷ also studied the effect of cervical stabilization maneuvers on the view obtained at laryngoscopy in 78 uninjured, elective surgical patients and concluded that cervical immobilization commonly worsened laryngoscopic view. The effects of MILI on laryngeal view were in a similar direction to those reported by Hastings but occurred more commonly in Wood's study. Anterior laryngeal or cricoid pressure often improved the view of the larynx when the neck was immobilized. Concern has been expressed in the past regarding the use of anterior cervical pressure in patients at risk for CSI, but Donaldson *et al.*⁸⁸ reported that application of cricoid pressure did not result in movement in an injured upper cervical spine in a cadaver model.

Manual in-line immobilization may have lesser impact on airway interventions than do other forms of immobilization. The experience supports routinely removing at least the anterior portion of collars to facilitate airway interventions provided that cervical spinal immobilization is maintained by MILI. Removal of the anterior portion of the collar improves mouth opening and facilitates airway management; reapplication of the mechanical immobilization should occur promptly when airway interventions are complete. MILI may increase laryngoscopic grade in some patients; this may be countered with anterior laryngeal or cricoid pressure.

Spinal Movement during Airway Interventions

The early biomechanical analyses of spinal motion typically used static radiography to determine the relations between the vertebral elements of the cervical spine and to quantify spinal movements. Unfortunately, no standardized technique of measurement has been used in the works since published, which have evaluated spinal movement during airway interventions. Both static radiography and dynamic fluoroscopy have been used; study findings have been reported movement as absolute distances, relative distances (typically a percentage of vertebral body width), and degrees of motion and have further been categorized relative to individual motion segments or upper and lower cervical spinal divisions or summated across the entire cervical spine. There is also little guidance available as to the clinical importance of the movements recorded, especially as they relate to the injured spine. Those spinal movements that fall within physiologic ranges have usually been considered to be

nonthreatening to the cord; whether they are in fact and remain so in a spine with a canal lumen already compromised by an acute, a chronic, or an acute superimposed on chronic anatomical derangement is by no means certain. Unfortunately, as we analyze the published works, we typically find ourselves in the position of comparing the recorded results with physiologic norms and then drawing an empiric conclusion as to the potential risk of such movements.

The Effects of Basic Airway Maneuvers on the Injured Neck. Aprahamian⁸⁹ studied the effect of both airway maneuvers on a human cadaver, unstable spine model. The anterior and most of the posterior column were surgically disrupted; the interspinous and supraspinous ligaments were spared. Lateral cervical spine radiographs were taken during both basic and advanced airway maneuvers. Basic maneuvers included chin lift, jaw thrust, head tilt, and placement of both oral and esophageal airways. Advanced maneuvers included placement of the following: an esophageal obturator airway; an orotracheal tube placed with both a straight and a curved laryngoscopic blade; and a nasotracheal tube, blindly placed. Chin lift and jaw thrust resulted in expansion of the disc space more than 5 mm at the site of injury. When blind nasotracheal intubation was facilitated by anterior pressure to stabilize the airway, 5 mm of posterior subluxation occurred at the site of injury. The other advanced airway maneuvers produced 3–4 mm of disc space enlargement. The study was repeated after the application of both soft and semirigid cervical collars; collars did not effectively immobilize the neck for either basic or advanced airway maneuvers.

Hauswald⁹⁰ also determined the impact of basic airway maneuvers on cervical spine movement. Eight human traumatic arrest victims were studied within 40 min of death. All subjects were ventilated by mask, and their tracheas were intubated orally with a direct laryngoscope, over a lighted oral stylet and using a flexible laryngoscope, and nasally. Cinefluoroscopic measurement of maximum cervical displacement during each procedure was made with the subjects supine and immobilized by a hard collar, backboard, and tape. The mean maximum cervical spine displacement was found to be 2.93 mm for mask ventilation, 1.51 mm for oral intubation, 1.85 mm for guided oral intubation, and 1.20 mm for nasal intubation. Ventilation by mask caused more cervical spine displacement than the other procedures studied. It was concluded that mask ventilation moves the cervical spine more than any of the commonly used methods of tracheal intubation.

Airway maneuvers will result in some degree of neck movement, both in general and specifically at the sites of injury. The amounts of movement are small, typically well within physiologic ranges, and their impact on secondary neurologic injury has not been defined. However, as will be subsequently discussed, airway interven-

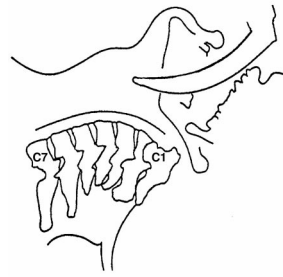


Fig. 6. Impact of direct laryngoscopy and tracheal intubation on cervical spine movement.^{91,92}

During blade insertion:
minimal displacement

With blade elevation:
superior rotation of Oc-C1
inferior rotation C2-C5

With tracheal intubation:
superior rotation of Oc-C1

tions are frequently performed on at-risk trauma patients, and there seems to be a very low incidence of secondary injury in these patients associated with airway clinical interventions.

Cervical Spinal Movement during Direct Laryngoscopy in Normal Patients. Sawin *et al.*⁹¹ determined the nature, extent, and distribution of segmental cervical motion produced by direct laryngoscopy and orotracheal intubation in normal human subjects. Ten patients underwent laryngoscopy while paralyzed and during general anesthesia. Minimal displacement of the skull base and cervical vertebral bodies was observed during laryngoscope blade insertion; elevation of the laryngoscope blade to achieve laryngeal visualization caused superior rotation of the occiput and C1 and mild inferior rotation of C3–C5. The largest magnitude motions were at the atlanto-occipital and atlantoaxial joints, but there was extension at each motion segment assessed. Tracheal intubation created slight additional superior rotation at the craniocervical junction but caused little alteration in the postures of C3–C5. Horton *et al.*⁹² conducted a similar experiment in volunteers during topical anesthesia only. Subjects in a supine, sniffing position underwent direct laryngoscopy, and at full glottic exposure, a lateral radiograph of the head and neck was performed. The radiographs indicated that extension at the craniocervical junction was near maximal and that there was progressively increasing extension from C4 to the base of the skull, but that the position of the lower cervical spine remained static during laryngoscopy. Both Sawin *et al.* and Horton *et al.* agreed that, during laryngoscopy, in both awake and unconscious subjects, most cervical motion occurs at the craniocervical junction; the subaxial cervical segments subjacent to and including C4 are minimally displaced (fig. 6).^{91,92}

Spinal Movement during Laryngoscopy in Injured Spine Models. Donaldson *et al.*⁸⁸ studied the motion that occurred during intubation in a cadaver model with an unstable C1–C2 segment. The following were measured in the intact specimen and then again after creation of the unstable segment: angulation, distraction, and the space available for the cord (SAC). With maximum flexion and extension, the SAC was narrowed

1.49 mm in the intact cervical spine but 6.06 mm in the unstable spine. Chin lift and jaw thrust reduced the SAC by 1 mm and 2.5 mm, respectively; oral intubation and nasal intubation created a similar (1.6 mm) reduction of SAC. Distraction at the unstable injured level was similar for chin lift, jaw thrust, and crash intubation (1–2 mm); distraction during gentle oral intubation and nasal intubation was less than 1 mm. Chin lift and jaw thrust created similar angulations (4° – 5°) to those of the oral intubation techniques, but nasal intubation caused less (2.5°). Cricoid pressure resulted in no significant movements when it was applied in either the stable or unstable model. Donaldson *et al.* concluded that (1) the SAC was narrowed to a greater degree by preintubation maneuvers than it was by intubation techniques, (2) nasal and oral intubation techniques resulted in similar amounts of SAC narrowing, and (3) application of cricoid pressure produced no significant movement at the craniocervical junction.

Stabilization during Airway Interventions in Cadaver Models of an Injured Spine. Lennarson *et al.*⁸² evaluated the impact of commonly used immobilization techniques in limiting spinal motion in an injured-spine model; the model involved the creation of a posterior ligamentous injury at the C5 level and compared the effects of MILI and Gardner-Wells traction. The predominant motion measured at all spinal levels during laryngoscopy and intubation in the intact spine was extension; this was consistent with the findings of Donaldson *et al.*,⁸⁸ Sawin *et al.*,⁹¹ and Horton *et al.*⁹² Subluxation in the anterior–posterior dimension remained less than 1 mm in both the intact and the partially destabilized spine; rotatory or angular movements were the only significant movement recorded. Application of Gardner-Wells traction limited rotatory motion at the craniocervical junction after destabilization; MILI did not have a similar effect.

Lennarson *et al.*⁷⁷ conducted a similar experiment assessing the efficacy of immobilization maneuvers in a model of complete C4–C5 segmental instability. Movement was measured at the injured level during the application of traction, during MILI, and without stabilization. Traction resulted in distraction at the site of injury when instability was complete; the magnitude of these movements was not reduced by MILI, although they remained within physiologic limits. Gerling *et al.*⁸⁴ also evaluated the effect of both MILI and cervical collar immobilization on spinal movement during direct laryngoscopy in an unstable C5–C6 cadaver model. Although there was less displacement (2 mm) measured with application of MILI compared with collars, the magnitude of movement was small overall and within physiologic ranges.

Brimacombe *et al.*⁹³ assessed spinal movement in a cadaver model with a posterior injury at C3, with MILI applied as various airway interventions (facemask venti-

lation, direct laryngoscopy and tracheal intubation, fiberoptic nasal intubation, laryngeal mask insertion, intubating laryngeal mask airway insertion followed by fiberoptic intubation, and insertion of a Combitube) were performed. Posterior displacement was less when intubation was performed nasally with a flexible scope (0.1 ± 0.7 mm) than for any other maneuver; most maneuvers caused 2–3 mm of displacement.

Influence of Laryngoscope Blade Type on Spinal Movement during Direct Laryngoscopy. Three authors have assessed the influence of the type of laryngoscope blade on the spinal movements generated during direct laryngoscopy. MacIntyre *et al.*⁹⁴ compared the Macintosh and McCoy blades in patients with normal spines during general anesthesia with cervical collars applied. There were no significant differences between the two blades with respect to the amount of spinal movement generated during intubation. Hastings *et al.*⁹⁵ compared head movement occurring during laryngoscopy in patients with normal spines using Macintosh and Miller laryngoscopes, and again, there were no differences in the amount of movement measured. Finally, Gerling *et al.*⁸⁴ compared spine movement in a cadaver model with a C5–C6 transection injury while performing laryngoscopy with Miller, Macintosh, and McCoy-type blades. There was no difference in the movements recorded with the different blades with regard to either anteroposterior displacement or angular rotation. Less axial distraction was measured with the Miller blade compared with the other two blade types; in absolute terms, the difference was 1.7 mm. Overall, there seems to be little difference in the spinal movement resulting from direct laryngoscopy relative to the type of blade used during laryngoscopy.

Cervical Spinal Movement with Indirect Rigid Fiberoptic Laryngoscopes. Watts *et al.*⁸¹ compared cervical spine extension and time to intubation with the Bullard (ACMI Corp., Southborough, MA) and Macintosh laryngoscopes during a simulated emergency with cervical spine precautions taken. Twenty-nine patients were placed on a rigid board, and anesthesia was induced. Laryngoscopy was performed on four occasions, twice each with the Bullard and Macintosh laryngoscopes, both with and without MILI applied (MILI was applied with cricoid pressure). Cervical spine extension (from the occiput to C5) was greatest with the Macintosh and was reduced both when the Macintosh was used with MILI and when the Bullard was used with or without stabilization. Times to intubation were similar for the Macintosh with MILI and for the Bullard without MILI. MILI applied during laryngoscopy with the Bullard resulted in further reduction in cervical spine extension but a prolonged the time to intubation, although it still was achieved in less than a minute. In a study design similar to that of Watts *et al.*, Hastings *et al.*⁹⁵ found that cervical spine extension from the occiput to C4 was

decreased when comparing the Bullard with both the Macintosh and the Miller laryngoscope blades.

The times to achieve intubation using the Bullard laryngoscope, in the study of Watts *et al.*,⁸¹ are similar to others reported in the literature. Twenty-two of 29 patients (76%) were intubated in less than 30s when using the Bullard under standard conditions.⁸¹ In a study using the dedicated intubating stylet, Cooper *et al.*⁹⁶ found 70% of patients were intubated in less than 30 s. There was also better exposure of the larynx during laryngoscopy with the Bullard than with the direct laryngoscope. Application of MILI resulted in deterioration in the grade view of the larynx when using the Macintosh in 19 of 29 patients (65%). In contrast, only 2 patients (7%) presented an inferior view of the larynx after application of MILI and cricoid pressure when using the Bullard laryngoscope.

Rudolph *et al.*⁹⁷ compared movement in the upper cervical spine in 20 patients scheduled to undergo elective surgery, when laryngoscopy was performed with the Bonfils intubation fiberscope (Karl Storz Endoscopy Ltd., Tuttlingen, Germany) and the Macintosh laryngoscope. With the patient's head in neutral position on the table and no pillow used, a baseline lateral radiograph was taken. The head was extended, laryngoscopy was performed using the Macintosh, a second radiograph was taken, and the head was returned to the neutral position. Laryngoscopy was then performed with the Bonfils fiberscope, and the trachea was intubated. With the Macintosh, views at laryngoscopy were class I in 8 patients, II in 5, and III in 7; all views obtained with the Bonfils fiberscope were class I. The time between insertion of the instrument and achievement of optimum view was similar for both instruments. Laryngoscopy with the Macintosh resulted in spinal movement that was greater in magnitude than that measured during Bonfils fiberscopy.

The Glidescope (Saturn Biomedical Systems, Burnaby, British Columbia, Canada) is a new video laryngoscope that incorporates a high resolution digital camera in the blade tip; the image is transmitted to a liquid crystal display monitor *via* a dedicated video cable. Agro *et al.*⁹⁸ compared the laryngeal view obtained initially with a Macintosh and then with the Glidescope in 15 normal patients presenting for general anesthesia who were wearing cervical collars. The laryngeal view was reduced by one Cormack grade in 14 of the 15 patients (93%) studied when the Glidescope was used compared with the Macintosh; the average time to intubation with the Glidescope was 38 s. Turkstra *et al.*⁹⁹ compared cervical spine movement, measured fluoroscopically, during intubation with a Macintosh, a light wand, and the Glidescope. In-line immobilization was achieved by taping the patients' heads into a Mayfield-type headrest; movement was measured at the Oc-C1, C1-C2, C2-C5, and C5-Th levels. The largest amount of motion measured was at

the Oc-C1 complex with all devices. Cervical spinal movement was reduced 57% overall (all segments combined) comparing the light wand with the Macintosh; reduced movement was apparent at each level. Spinal movement was reduced only at the C2-C5 segment when the Glidescope was compared with the Macintosh; $6.9^\circ \pm 5.2^\circ$ of flexion was measured during Macintosh laryngoscopy, and this was reduced by 50% using the Glidescope. Motion was not significantly altered at the three other segments studied. The time to intubation was longest with the Glidescope (27 ± 12 s) but similar with the light wand (14 ± 9 s) and the Macintosh (16 ± 7 s).

Cervical spine movements are generally less when rigid indirect laryngoscopes are used compared with the ML direct laryngoscope. Visualization of the glottis is also improved with the use of the rigid laryngoscopes, but the time to achieve the best view is somewhat longer; these times tend to be short, and the difference compared with the direct laryngoscope is likely to be of little clinical relevance.

Cervical Spinal Movement and Laryngeal Mask Airways. Kihara *et al.*¹⁰⁰ measured cervical movement produced by the intubating laryngeal mask airway during MILI in 20 anesthetized patients with cervical pathology undergoing cervical spine surgery. During the insertion of the intubating laryngeal mask airway, C5 and superior segmental levels were flexed by less than 2° . During intubation, C4 and superior segmental levels were flexed by 3° or less, and C3 and levels above were flexed by an average of 1° during removal. There was some posterior displacement at the C2-C5 levels during insertion and intubation but not during removal.

Keller *et al.*¹⁰¹ implanted microchip sensors into the pharyngeal surfaces of C2 and C3 in 20 cadavers to determine the pressures exerted against the cervical vertebrae by both the standard laryngeal mask airway and the intubating laryngeal mask airway during insertion and manipulation. The impact of these pressures on cervical spine movement was also determined. Keller *et al.* concluded that laryngeal mask devices exert high pressures against the upper cervical vertebrae during insertion, during inflation, and while *in situ*; these pressures could produce posterior displacement of the upper cervical C-spine. The clinical relevance of these findings as they relate to CSI has yet to be clarified.

Cervical Spinal Movement during Surgical Cricothyrotomy. Surgical cricothyrotomy was initially advocated as a preferred airway intervention in patients at risk for CSI compared with orotracheal intubation and now is deemed to be an appropriate alternative if oral or nasal routes cannot be used or are unsuccessful. Although long considered safe in the presence of a CSI, its application in this scenario has not been well studied with respect to either spinal movements or neurologic outcomes. Gerling *et al.*¹⁰² used a cadaver model to

quantify movement during cricothyrotomy. Standard open cricothyrotomy was performed in 13 cadavers with complete C5–C6 transection injuries, and cervical spine images were recorded fluoroscopically during the procedure. Peak axial distraction was measured at 4.5% of the C5 width, amounting to 1–2 mm of axial compression; peak antero-posterior displacement was measured at 6.3% of the C5 width, equivalent to 1–2 mm of displacement. Although these values were statistically significant, their clinical relevance has yet to be determined.

The Clinical Practice of Airway Management in Patients with Cervical Spine Injury

Surveys of Patterns of Clinical Practice Regarding Airway Management after Cervical Spine Injury.

Four authors have surveyed North American anesthesiologists as to their preferred methods of airway management in patients with cervical spine trauma or disease. Lord *et al.*¹⁰³ compared practice preferences among surgical members of the Eastern Association for the Surgery of Trauma with anesthesiologists in US anesthesiology training programs. In the elective situation (CSI but breathing spontaneously with stable vital signs), anesthesiologists stated that they were less likely to use nasotracheal intubation (53% *vs.* 69%), equally likely to use orotracheal intubation, and more likely to use the fiberoptic bronchoscope than were trauma surgeons. In the urgent scenario (patient with unstable vital signs), anesthesiologists tended to use both nasotracheal and orotracheal intubation in a manner similar to that of the surgeons but more frequently (16%) preferred the bronchoscope. In an emergency situation (apneic patient with unstable vital signs), both anesthesiologists and surgeons relied extensively on the direct laryngoscope (78% and 81%); anesthesiologists were more likely to use the bronchoscope (15%) than were surgeons but used a surgical airway less frequently than did the surgeons (7% *vs.* 19%).

Rosenblatt *et al.*¹⁰⁴ received 472 responses from 1,000 active members of the American Society of Anesthesiologists who were surveyed as to their preferences for management methods for the difficult airway in cooperative adult patients. With respect to patients with CSI, 78% of respondents expressed a preference for an awake intubation and the use of bronchoscope; the bulk of the remainder induced general anesthesia and used a direct laryngoscope. Rosenblatt *et al.* did not request information regarding the levels of experience attained with the devices preferred but did ascertain that they were available to the practitioners who stated that they would use them. Jenkins *et al.*¹⁰⁵ collected 833 responses from 1,702 members of the Canadian Anesthesiologists' Society surveyed regarding their management choices for the difficult airway in Canada. When faced with a patient with a cervical cord compression and neurologic deficit

presenting for discectomy, 67% expressed a preference for awake intubation, and most (63%) stated that they would use a bronchoscope. Thirty-one percent would induce general anesthesia before airway intervention, and slightly more would use a direct laryngoscope than preferred a lighted stylet in this setting. Jenkins *et al.* did not solicit information regarding the level of experience with the methods identified as being preferred by the survey respondents.

Ezri *et al.*¹⁰⁶ surveyed 452 American-trained American Society of Anesthesiologists members attending the 1999 Annual Meeting. When faced with a cooperative adult patient with cervical spine disease (rheumatoid arthritis or ankylosing spondylitis) presenting for elective surgery, awake fiberoptic intubation was preferred by most. Although 75% stated that they would use it in some of the scenarios outlined, only 59% of respondents reported skill in the use of the bronchoscope.

The surveys are consistent in revealing that many North American anesthesiologists express a preference for the use of a fiberoptic bronchoscope during airway management in patients with cervical spine disease or injury including in apneic trauma scenarios. This preference persists despite the fact that some who state this preference also acknowledge that they are not confident regarding their skill levels with the bronchoscope. Depending on the setting and the perceived urgency of the situation, direct laryngoscopy is still commonly used, and use of the lightwand is preferred by a significant minority of anesthesiologists, at least in Canada.

Airway Management of Cervical Spine–injured Patients: The Experience and Outcomes Reported.

Meschino *et al.*¹⁰⁷ reviewed their experience with 454 patients with critical cervical cord or spine injuries or both. One hundred sixty-five patients underwent awake tracheal intubation within 2 months of injury; 289 did not require intubation during the same period. The direct laryngoscope was used in 36 patients (22%), the fiberoptic bronchoscope was used in 76 (46%), and 51 patients (32%) underwent blind nasal intubation. Patients undergoing intubation were more severely impaired than those who did not require intubation. Despite this, there was no difference in the incidence of neurologic deterioration over time between the two groups, and tracheal intubation was not associated with neurologic deterioration in any patient. Holley and Jordan¹⁰⁸ conducted a retrospective analysis of traumatic, unstable cervical spine fractures requiring operative management to determine both the airway management techniques used and the incidence of neurologic complications. One hundred thirty-three patients with 140 fractures were reviewed. Ninety-four patients underwent nasal intubation in the operating room, and 29 were intubated with direct laryngoscopy and in-line stabilization. No neurologic complications were recognized in any patient.

Rhee *et al.*¹⁰⁹ analyzed their experience with 21 patients with cervical cord or spine injury who underwent tracheal intubation in the emergency room. Orotracheal intubation was used in 81% of CSI patients; neuromuscular blockers were used in 82% of these intubations. The authors concluded that no injury was recognized to be caused or exacerbated by airway maneuvers. However, one patient with a C7-T1 dislocation and a C7 cord transection was noted to have absent sensation below the nipples before intubation (T4 level) and motor and sensory examination results consistent with a C7 cord transection after intubation. Whether this disparity reflect an ascension in the level of injury from T4 to C7 or the difference in findings between an emergency room screening neurologic exam and a more precise examination performed later is not certain; the authors' conclusions seem to prefer the latter explanation. Scannell *et al.*¹¹⁰ reviewed their experience with 81 patients with CSI, including 58 with unstable fractures, who received emergency orotracheal intubations performed by experienced anesthesiologists. Neurologic assessment was documented before and after intubation, and in no instance was there a recognized deterioration of neurologic functions after tracheal intubation. Shatney *et al.*¹¹¹ reviewed their experience with 81 patients with 98 fractures who were neurologically intact on initial presentations. Orotracheal intubation was performed in 48 patients, and no neurologic deteriorations were recognized. In-line immobilization was used during the airway maneuvers, and agitated or combative patients were sedated, paralyzed, or both. Talucci *et al.*¹¹² reviewed their experience with 335 patients requiring urgent intubations. Seven patients with unstable CSI underwent orotracheal intubation after induction of anesthesia and paralysis; none experienced neurologic compromise as a result of airway management.

Suderman *et al.*¹¹³ reviewed the experience of 150 patients with traumatic CSI and well-preserved neurologic function presenting for operative stabilization. General anesthesia before intubation was induced in 83 patients, of whom 65 had their tracheas intubated with the direct laryngoscope; 22 patients were intubated while awake using the direct laryngoscope. The remainder had tracheal intubation performed with a variety of alternatives to the direct laryngoscope, most commonly the bronchoscope; the majority of those latter intubations were performed with the patient awake. Two patients experienced new neurologic deficits; one had a wire passed through the cervical cord accidentally during operative stabilization and was rendered quadriplegic, the second recovered from a new single level radiculopathy attributed to the operative decompression. Both of these patients had their tracheas intubated with a direct laryngoscope while anesthetized. McCrory¹¹⁴ performed a similar retrospective analysis of the records of 45 patients who presented for operative stabilization

of cervical injuries resulting from trauma. Tracheal intubation was performed after induction of general anesthesia with neuromuscular block in 40% of cases; in the remainder, intubation was performed with a bronchoscope while the patient was awake. One awake tracheal intubation was abandoned as a result of patient noncompliance; this patient's trachea was intubated after induction of general anesthesia. Weighted traction was used in all cases to immobilize the spine. No patient developed either a new neurologic finding or worsening of a pre-existent deficit.

Wright *et al.*¹¹⁵ reviewed the records of 987 blunt trauma patients; 60 of the patients had a cervical fracture, and 53 of these were deemed to be unstable. Twenty-six patients' tracheas were intubated orally, 25 were intubated nasally, and two were intubated by cricothyrotomy. One patient who underwent nasotracheal intubation experienced a neurologic deterioration. Lord *et al.*¹⁰³ reviewed the case records of 102 patients who had a CSI and were admitted to their center after trauma. Sixty-two patients required airway management. The most common method used was orotracheal intubation facilitated by direct laryngoscopy (43%), followed by bronchoscope-assisted intubation (27%), nasotracheal intubation (22%), and tracheostomy (2%); in 4%, the method could not be determined. No patient was recognized to have experienced a neurologic deterioration associated with airway management. Other authors have reported similar findings in smaller series of trauma patients with CSI.^{112,116}

These studies are limited by both their small sample size and their retrospective nature. However, they do reveal that neurologic deterioration in CSI patients is uncommon after airway management, even in high-risk patients undergoing urgent tracheal intubation. They are not sufficient to rule out the potential that airway management provided in isolation or as part of a more complex clinical intervention, even provided with the utmost care, may rarely result in neurologic injury. To do so would require a study of enormous proportions. As noted previously, progressive neurologic deterioration occurs in a minority of CSI patients. If this incidence was set at 2% and a study was designed to prove that an airway intervention did not double this baseline incidence, approximately 1,800 patients would need to be studied. No method of airway intervention has been evaluated with such a study, or anything close to it, and therefore, statements comparing the relative safety of different methods have tenuous evidentiary support.

The Use of the Direct Laryngoscope after Cervical Spine Injury: The Debate. As part of the early efforts aimed at reducing secondary injuries in spine-injured patients, a hypothesis was generated that the tracheas of patients with unstable cervical spines could not be safely managed by direct laryngoscopy and oral intubation.¹¹⁷ Oral intubation was deemed dangerous because it alleg-

edly caused excessive spinal movement, and this movement could lead to secondary injury. Such secondary injury could theoretically be avoided by the careful performance of nasotracheal intubation or cricothyrotomy. These techniques were advocated as the emergency airway maneuvers of choice in patients at risk for spinal injury. There were no data at that time to support this thesis, and the data collected since seem to suggest that secondary neurologic injury associated with any form of airway management is exceedingly rare. The early Advanced Trauma Life Support protocols for airway management were consistent in their support for the nasal intubation/cricothyrotomy strategy, implying a lack of support for the use of direct laryngoscopy in this clinical setting. Not all practitioners agreed that the use of direct laryngoscopy was contraindicated in patients at risk for cervical injury. There was evidence made available soon after publication of these protocols that some experienced trauma centers (including our own) were ignoring the Advanced Trauma Life Support recommendations and performing direct laryngoscopy in at-risk populations.^{107,113,118}

McLeod and Calder¹¹⁹ examined the association between the use of the direct laryngoscope in patients and subsequent spinal injury or pathology. They suggested that the following five case features would add credence to the diagnosis of a laryngoscopy-induced cord injury: (1) a short period of unconsciousness, (2) myelopathy present on recovery, (3) autonomic disturbances after laryngoscopy, (4) difficult laryngoscopy, and (5) craniocervical disease or gross instability below C3. These criteria were then used to evaluate the likelihood that laryngoscopy was the causative factor for neurologic deterioration in the reports. Although they do make intuitive sense, whether these criteria discriminate well in assigning cause to injury recognized after intubation is not established. Six reports dealing with 10 patients in which it was alleged that direct laryngoscopy contributed to a neurologic injury were reviewed.^{57,120-124} With the possible exception of one case, they concluded after review and analysis of the case reports, that the reports did not provide sufficient data to allow them to make the determination that the use of the direct laryngoscope was the cause of the neurologic injuries reported.

The first report analyzed was that of Farmer *et al.*,⁵⁷ who reviewed their institutional experience with cord-injured patients. They reported that four patients had neurologic deteriorations associated with tracheal intubation. Two deteriorations were classified as minor and two were classified as major, but no further details were provided regarding the cases or the intubations. The second report was that of Muckart *et al.*,¹²⁰ who reported two cases of neurologic deterioration after clinical interventions. The first patient was a 45-yr-old man involved in a motor vehicle accident who sustained

bilateral femoral fractures and a closed head injury. Despite the mechanism of injury, a period of unconsciousness, and the presence of neck pain, no imaging was performed, and his spine was not immobilized. He underwent anesthesia for operative repair of the femoral fractures and was quadriplegic on awakening; a C2 fracture-dislocation was subsequently diagnosed, and he recovered completely. The second patient was a 22-yr-old man with multiple gunshot wounds to the neck; he arrived in the hospital neurologically intact. Imaging of the neck revealed no apparent injury to the cervical spine to a level of C5; the radiograph showed only the upper five vertebrae. He underwent emergency surgery during general anesthesia without neck immobilization and was quadriplegic after. A CT scan demonstrated a burst fracture of C6 with a retropulsed fragment impinging on the canal. He was placed in traction, had operative fixation, and recovered completely. Although direct laryngoscopy and tracheal intubation were component parts of the care of both patients, they were not the sole interventions; the lack of immobilization and the potential for malpositioning cannot be excluded as significant risk factors in both cases. The complete recovery in both patients suggests that malpositioning may have been an etiologic factor inducing a transient, compressive neuropraxia-like injury.

The third report analyzed was that of Redl,¹²¹ who described the case of an 18-yr-old man with undiagnosed spondyloepiphyseal dysplasia congenita resulting in unrecognized craniocervical instability. He underwent general anesthesia and direct laryngoscopy with tracheal intubation for removal of retained knee hardware. The intraoperative and early postoperative course was uneventful, but he developed a spastic quadriplegia the day after surgery. A CT scan demonstrated a congenitally abnormal craniocervical junction with an os odontoidium (congenitally nonfused odontoid process) in the foramen magnum compressing the spinal cord. Although he made a full recovery, he awoke quadriplegic after a subsequent craniocervical stabilization procedure for which his trachea was intubated using a fiberoptic bronchoscope. The precise role of the laryngoscopy in the development of transient neurologic symptoms in a patient with a congenitally abnormal and unstable spine is uncertain; the development of symptoms on the day after laryngoscopy reduces the strength of a causative association. The fourth report reviewed is that of Yan and Diggan,¹²² who described the occurrence of a central cord syndrome in a 42-yr-old woman with acquired immune deficiency syndrome who underwent urgent laryngoscopy and intubation for respiratory failure. Before her admission, she was using a walker and wheelchair to ambulate. Following the recognition of upper extremity weakness after intubation and resuscitation, she underwent imaging and evaluation of her central and peripheral nervous system. There was no evidence of

spinal anomaly or instability; there was imaging evidence of marked and generalized cerebral atrophy and a spinal cord contusion and electrodiagnostic evidence of both central and peripheral neuropathy. The etiology of injury was attributed to hyperextension, but there was also evidence of advanced neurologic disease likely related to infection with human immunodeficiency virus. The fifth report was that by Yaszemski *et al.*,¹²³ who reported the case of a 59-yr-old woman with advanced rheumatoid arthritis. She underwent a right wrist fusion during general anesthesia, and her trachea was intubated with a bronchoscope while she was awake. Her trachea was extubated at the end of the procedure, and the early postoperative course was uneventful. She had a cardiac arrest 10 h postoperatively and was intubated with direct laryngoscopy, but could not be resuscitated. At autopsy, she was confirmed to have atlantoaxial instability (recognized preoperatively), and there was microscopic evidence of focal areas of ischemia and infarction in the upper cord and lower medulla oblongata. The authors attributed the damage and the cause of death to the resuscitation intubation, although she was already dead at the time of that intubation. Further, the pathologic finding of infarction suggests that the injury likely took place remotely from the time of death, perhaps during the surgery, and may well have been a positioning injury that was progressive.

The case that MacLeod and Calder cited as being most likely (four of five features present) a laryngoscopy-induced cord injury was that reported by Hastings and Kelley.¹²⁴ They reported of the case of a 65-yr-old man admitted to hospital after a motor vehicle accident. Despite reporting neck pain and exhibiting left arm weakness, CSI was not ruled out, nor was spinal immobilization enforced. His condition deteriorated some hours subsequently, and after repeated, failed attempts at direct laryngoscopy without spinal immobilization, he underwent cricothyrotomy; 3 h later, he was found to be paraplegic. A review of the original cervical spine radiograph demonstrated a widened disc space at C6–C7 suggesting disruption of the anterior longitudinal ligament. CT scans confirmed that finding as well as noting congenital spinal stenosis from C3 to C7, osteophyte fragments in the spinal canal at C6, a fracture of the C6–C7 facet joint, a C7 laminar fracture, and a C6 spinous fracture. The constellation of symptoms could not be attributed to a single cord lesion, and he was diagnosed as having both an *anterior cord syndrome* affecting the T11 and subjacent levels and a *central cord syndrome* at the cervical level. No MRI study was performed to detail the nature of the cord injuries, and it is possible that his neurologic deterioration was inevitable and perhaps the cause of his respiratory insufficiency. However, at no time from admission until the occurrence of his neurologic deterioration was his spine immobilized.

Two additional cases of intubation-associated neurologic injury not reviewed by MacLeod and Calder have been reported.^{125,126} Liang *et al.*¹²⁵ reported a case similar to that of Hastings and Kelley of a man involved in a motor vehicle accident with a suspected CSI who was left quadriplegic after airway management. Despite the evidence of a CSI (nature of injury not reported) and a neurologic deficit (limited movement in both upper extremities), repeated and failed attempts were made at both nasal (five attempts) and then oral intubation with a direct laryngoscopy (five attempts). The last three attempts at oral intubation were made after removal of the cervical collar, but MILI was not used. The trachea was eventually intubated *via* a surgical airway. There is no discussion of the care afforded after intubation with respect to the spine injury or any description of subsequent imaging studies performed. The next day, it was recognized that he was quadriplegic. Powell and Heath¹²⁶ reported the case of 59-yr-old man found collapsed and unconscious. Paramedics found him to be apneic, cyanosed, and unresponsive and attempted but failed to intubate his trachea. Tracheal intubation was performed in the emergency room, and then the spine was immobilized. A lateral cervical radiograph revealed an odontoid peg fracture, and the patient's condition was consistent with a complete cord injury at the C2 level. Although it was inferred that the cord injury may have been caused or aggravated by the airway management, it was acknowledged by the authors that the injury was probably sustained at the time of the accident.

A number of reports detailing a relation between airway management and the occurrence of secondary neurologic injury in CSI patients have been reviewed. These reports consist typically of observations made in a single patient or in a small series of patients admitted to a single institution. Although the deterioration has often been associated temporally with airway management, in most cases, it is impossible to determine with certainty the cause of the deterioration because confounding factors are typically present and acknowledged by the reporting authors. As well, it is possible in some instances that the association between airway management and a worsening neurologic state arises not because of cause and effect but because the airway intervention was made necessary by a progressively deteriorating clinical condition such as an ascending myelopathy. It may well be that the magnitude of the deterioration does not become apparent until after clinical interventions, at which time they, themselves, become suspect culprits. As unsatisfactory as it might be, determining the true nature of the association (causal or otherwise) between airway management and adverse neurologic outcomes in CSI patients is not possible at this time, given the current state of our knowledge.

The Use of the Flexible Fiberoptic Bronchoscope in Cervical Spine Injury. There is considerable enthusiasm, particularly among anesthesiologists, for the use of the fiberoptic bronchoscope in patients at risk for cervical spine disease. The advantages are its potential for use in awake patients, the minimal cervical movement required to achieve tracheal intubation, and the ability to perform postintubation neurologic assessments in cooperative and cognitively intact patients. However, there have been relatively few reports recognized in the literature regarding the use of the bronchoscope in the emergency management of the airway after trauma.¹²⁷ The overall success rate for intubation using the bronchoscope in the trauma setting has been cited at 83.3% (95% CI, 72–94.6%).¹²⁷ There is a report detailing the successful use of the bronchoscope to facilitate awake intubation in 327 consecutive patients presenting for elective cervical spine surgery; the bulk of the procedures were surgeries for cervical disc prolapse, and there were no patients with traumatic injuries included in the review.¹²⁸ Although the procedure was well tolerated by the majority of the patients, 38 (12%) developed low oxygen saturations; in this group, the mean oxygen saturation measured by pulse oximetry was $84 \pm 4\%$ (range, 72–89%). The potential for desaturation during bronchoscope-facilitated intubation seems to be as great or greater in CSI patients compromised by traumatic injury as in these elective surgical patients; the incidence and magnitude of hypoxemia in a series of CSI-trauma patients undergoing such management has not been reported.

There are no published data in the English literature that would indicate that the cited advantages of the fiberoptic bronchoscope translate into improved outcomes among CSI patients compared with other intubation techniques. As well, Ezri *et al.*¹⁰⁶ reported, after a survey of American anesthesiologists, that more than 40% of respondents acknowledged that they were not comfortable using a bronchoscope for airway management. McGuire and El-Beheiry¹²⁹ reported two cases of complete airway obstruction during elective awake bronchoscope-assisted intubation in patients with unstable cervical spine fractures; both patients were salvaged with emergency surgical airways. In patients with brain injury, a common concurrent injury to CSI, the use of the bronchoscope is associated with significant increases in ICP that are not prevented by the administration of morphine, midazolam, and nebulized lidocaine.¹³⁰

Comparing Rigid and Flexible Fiberoptic Endoscopes in At-risk Populations. Cohn and Zornow¹³¹ compared the fiberoptic bronchoscope and the Bullard laryngoscope with respect to rapidity of glottic visualization and intubation in patients requiring cervical immobility during tracheal intubation. Seventeen adult patients scheduled to undergo neurosurgical correction of a cervical spine problem were studied. Each patient was

considered at risk for neurologic injury during tracheal intubation based on a request for awake fiberoptic tracheal intubation by the neurosurgical team, or radicular symptoms initiated or exacerbated by neck extension. Most showed evidence of spinal canal impingement on a preoperative MRI. Patients were allocated randomly to one of two study groups for tracheal intubation with the Bullard ($n = 8$) or the fiberoptic bronchoscope ($n = 9$); before intubation, glottic visualization was performed using the alternative technique. All intubations were performed with the neck in a comfortable position for the patient and with any preexisting immobilization device (*e.g.*, collar, traction) in place. Glottic visualization was uniformly successful on the first attempt in both groups. Tracheal intubation was also uniformly successful, although one intubation in the bronchoscope group took 183 s because of difficulty passing the endotracheal tube through the glottis after an easy laryngoscopy. No new neurologic deficits were observed after tracheal intubation in either group.

Practice Options for Airway Management after Cervical Spine Injury. There is discordant opinion expressed in the literature regarding the optimal means of securing the airway in patients with CSI. Enthusiasm is expressed by some neuroanesthesia experts for the exclusive use of the fiberoptic bronchoscope to facilitate tracheal intubation in spine-injured patients.¹³² There are a number of theoretical factors that would support such a choice. The head and neck may be left in a neutral position, and little spinal movement is required to achieve laryngeal visualization and tracheal intubation. The patient's protective reflexes are largely left intact, and the potential for deleterious movements and positioning is perhaps reduced. A neurologic assessment can be made after intubation to ensure that there has been no change in the patient's status, although the accuracy of this evaluation may be diminished by sedation. Finally, the patient could be positioned awake to increase the likelihood that potentially injurious position could be avoided. These considerations support the use of the tracheal intubation facilitated by a fiberoptic bronchoscope and performed by an experienced care provider as a practice option in the management of the airway in spine-injured patients. Survey evidence also supports the conclusion that many anesthesiologists are of the opinion that it is the preferred option, especially in elective scenarios. This preference persists even among physicians who acknowledge limited skills with the device. However, there are no data to suggest that better neurologic outcomes are achieved with its use. In fact, the application of a technique by practitioners not expert in its use may carry risk. Failed awake intubation has been identified as a cause of morbidity and mortality in the latest analysis of difficult airway claims by the American Society of Anesthesiologists' Closed Claims Project.¹³³

The use of a direct laryngoscope after induction of

anesthesia is also deemed an acceptable practice option by the American College of Surgeons as outlined in the student manual of the Advanced Trauma Life Support Program for Doctors; by experts in trauma, anesthesiology, and neurosurgery; and by the Eastern Association for the Surgery of Trauma.^{3,107,109,119,127,134-143} The principle advantages of the direct laryngoscope are that anesthesiologists are very experienced in its use and that it is a highly effective tool; many anesthesiologists do not consider themselves similarly skilled with other practice options.¹⁰⁶ Direct laryngoscopy can also be performed more quickly than some, but not all, alternative techniques, and it does not require time to obtain and set up specialized equipment. However, it has the potential to cause greater spinal movement than indirect techniques. In addition, if laryngoscopy is performed after the induction of general anesthesia, the potential for difficult ventilation, a failed intubation, and a cannot-intubate, cannot-ventilate scenario cannot be excluded. Finally, if there is underlying severe, chronic cervical spinal pathology, difficult laryngoscopy should be anticipated because it is more likely to occur.³ This is particularly true if the upper cervical spine is severely impacted by the disease process.

The use of the direct laryngoscope is a practice option accepted by expert practitioners; its use is commonly encouraged in urgent or emergent situations. Other practice options, such as light wands, rigid fiberoptic laryngoscopes, and laryngeal mask airways, are also deemed appropriate. There is no published evidence that would indicate that one intubation option is superior to others with respect to outcomes in general and, in particular, with respect to neurologic outcomes. Any comparative study that could or would support a single practice option would have to be very large to be persuasive.

Summary of the Literature

There is an incidence of CSI approximating 2% among victims of blunt trauma, and this incidence is trebled if the patient presents unconscious or with a GCS score reduced to 8 or below. A finding of a focal neurologic deficit also significantly increases the likelihood of a cervical injury. The need to evaluate all at-risk patients with a complete and technically adequate imaging series seems to be accepted as the standard of care, although there is debate as to what constitutes the at-risk population and an acceptable imaging series. A three-view spine series (lateral, antero-posterior, and odontoid views) supplemented by computerized tomographic imaging through areas that are difficult to visualize or suspicious is effective in ruling out injury in both cooperative and noncooperative patients. MRI studies may be useful in patients with neurologic symptoms but nega-

tive radiography and CT imaging; they seem to add little to the evaluation of patients with persistent pain but a normal neurologic examination and negative imaging. As well, although MRI may identify CSI not captured by CT, these injuries are not usually unstable. Failure to diagnose the injury at time of presentation is associated with a worse neurologic outcome; it occurs most commonly as a result of either failure to appropriately image the spine or misinterpretation of appropriate imaging.

Immobilization of the spine in at-risk patients at the time of first system contact and maintenance of the immobilization until the spine is cleared is accepted by expert consensus as the standard of care. However, there is some debate about the need for immobilization in patients at low risk. Prolonged spinal immobilization is costly in terms of system resources and not without risk to the patient. Strategies that permit efficient and prudent spine clearance are available and their use is encouraged so as to reduce costs, conserve resources, and, most importantly, to prevent harm.

Secondary neurologic injury occurs after CSI and may be associated with clinical care interventions. There is now recognized a syndrome of progressive, ascending myelopathy that occurs in some patients and that is characterized by a widely distributed cord injury. It may occur after a period of relative clinical stability and in the absence of both mechanical instability and canal compromise at the spinal levels to which the injury has ascended. The use of MRI (especially T2-weighted studies) has been instrumental in documenting both the occurrence and the nature of this injury. It may also present at a time when clinical interventions are ongoing to treat the original traumatic injuries. Although there has been a past tendency to attribute many secondary injuries to clinical interventions, especially in a medical-legal context, critical examination of these cases, supplemented with MRI evaluations, may reveal that some, and perhaps most, are an inevitable consequence of the primary injury.

The routine use of some form of immobilization during airway maneuvers in at-risk patients is accepted as the standard of care. All airway maneuvers will result in some degree of neck movement, both in general and specifically at the sites of injury. The amounts of movement are small and may be restrained by in-line immobilization, but they are not eliminated. The available data and the accumulated clinical experience support a conclusion at the current time that these movements are unlikely to result in neurologic injury provided that reasonable care is taken during airway interventions. However, a study of sufficient size to validate this statement has not been performed.

The most appropriate technique for performing tracheal intubation in patients with cervical spine injury continues to be debated. There are no clinical outcome data that suggest better neurologic outcomes with any

particular technique, and it is acknowledged that a very large study would be required to furnish such data. Surveys indicate that the majority of American anesthesiologists would prefer to use a fiberoptic bronchoscope to intubate the trachea of at-risk patients and to do so with the patient awake. A significant proportion of those sharing this preference acknowledge limited skills with the bronchoscope. As well, failed awake intubation has been associated with morbidity and mortality in recent analyses of closed claims. Surprisingly, there are no reports of series of CSI patients treated in this fashion, and so it is not possible to comment on the outcomes of this strategy.

There are a large number of reports that confirm that rapid sequence induction of general anesthesia followed by direct laryngoscopy and tracheal intubation is widely performed in patients at risk for and with confirmed CSI; the resulting neurologic outcomes compare favorably to similar patient populations undergoing awake tracheal intubation and to patients who do not require airway intervention after traumatic injury. This technique does not seem to be associated with a higher incidence of secondary injury when compared with any other technique of intubation. Unfortunately, these reports are limited by small sample size and their retrospective nature. The current evidence and opinion expressed in the literature support the use of a range of practice options in the management of the airway in CSI patients.

References

- Jofe MH, White AA, Panjabi MM: Clinically relevant kinematics of the cervical spine. *The Cervical Spine*, 2nd edition. Edited by the Cervical Spine Research Society. Philadelphia, JB Lippincott, 1989, pp 57-69
- Nichol HC, Zuck D: Difficult laryngoscopy: The "anterior" larynx and the atlanto-occipital gap. *Br J Anaesth* 1983; 55:141-4
- Calder I, Calder J, Crocckard HA: Difficult direct laryngoscopy in patients with cervical spine disease. *Anaesthesia* 1995; 50:756-63
- Bouchard-Chabot A, Lioté F: Cervical spine involvement in rheumatoid arthritis: A review. *Jt Bone Spine* 2002; 69:141-54
- Cusick JF, Yoganandan N: Biomechanics of the cervical spine 4: Major injuries. *Clin Biomech* 2002; 17:1-20
- White AA III, Johnson RM, Panjabi MM, Southwick WO: Biomechanical analysis of clinical stability in the cervical spine. *Clin Orthop* 1975; 109:85-95
- Johnson RM, Wolf JW: Stability, *The Cervical Spine*. Edited by the Cervical Spine Research Society. Philadelphia, JB Lippincott, 1983, pp 35-53
- White AA III, Panjabi MM: Clinical Biomechanics of the Spine, 2nd edition. Philadelphia, JB Lippincott, 1990, pp 314-7
- Reid DC, Henderson R, Saboe L, Miller JDR: Etiology and clinical course of missed spine fractures. *J Trauma* 1987; 27:980-6
- Davis JW, Phreaner DL, Hoyt DB, MacKersie RC: The etiology of missed cervical spine injuries. *J Trauma* 1993; 34:342-6
- Goldberg W, Mueller C, Panacek E, Tigges S, Hoffman J, Mower WR: Distribution and pattern of blunt traumatic cervical spine injury. *Ann Emerg Med* 2001; 38:17-21
- Stiell IG, Wells GA, Vandemheen KL, Clement CM, Lesiuk H, De Maio VJ, Laupacis A, Schull M, McKnight RD, Verbeek R, Brison R, Cass D, Dreyer J, Eisenhauer MA, Greenberg GH, MacPhail I, Morrison L, Reardon M, Worthington J: The Canadian C-spine rule for radiography in alert and stable trauma patients. *JAMA* 2001; 286:1841-8
- Tator CH: Update on the pathophysiology and pathology of acute spinal cord injury. *Brain Pathol* 1995; 5:407-13
- Kwon BK, Tetzlaff W, Grauer JN, Beiner J, Vaccaro AR: Pathophysiology and pharmacologic treatment of acute spinal cord injury. *Spine J* 2004; 4:451-64
- Carlson GD, Gorden CD, Oliff HS, Pillai JJ, Lamanna JC: Sustained spinal cord compression: I. Time-dependent effect long-term pathophysiology. *J Bone Jt Surg* 2003; 85A:86-94
- Delamarter RB, Sherman J, Carr JB: Pathophysiology of spinal cord injury: Recovery after immediate and delayed decompression. *J Bone Jt Surg* 1995; 77A:1042-9
- Fehlings MG, Tator CH: An evidence-based review of decompressive surgery in acute spinal cord injury: Rational, indications, and timings based on experimental and clinical studies. *J Neurosurg (Spine 1)* 1999; 91:1-11
- LaRosa G, Conti A, Cardali S, Cacciola F, Tomasello F: Does early decompression improve neurological outcome of spinal cord injured patients? Appraisal of the literature using a meta-analytical approach. *Spinal Cord* 2004; 42:503-12
- Keene JS, Fischer SP, Vanderby R, Drummond DS, Turski PA: Significance of acute posttraumatic bony encroachment of the neural canal. *Spine* 1989; 14:799-802
- Panjabi M, White AA III: Biomechanics of nonacute cervical spinal cord trauma. *The Cervical Spine*, 2nd edition. Edited by the Cervical Spine Research Society Editorial Committee. Philadelphia, JB Lippincott, 1989, pp 91-6
- Panjabi MM, Yue JJ, Dvorak J, Goel V, Fairchild T, White AA: Cervical spine kinematics and clinical instability. *The Cervical Spine*, 4th edition. Edited by Clark CR. Philadelphia, Lippincott Williams & Wilkins, 2005, pp 55-78
- Paxinos O, Ghanayem AJ: Biomechanics of nonacute cervical spine trauma. *The Cervical Spine*, 4th edition. Edited by Clark CR. Philadelphia, Lippincott Williams & Wilkins, 2005, pp 102-9
- Henderson FC, Geddes JF, Vaccaro AR, Woodard E, Bery KJ, Benzel EC: Stretch-associated injury in cervical spondylolytic myelopathy: New concept and review. *Neurosurgery* 2005; 56:1101-13
- Ching RP, Watson NA, Carter JW, Tencer AF: The effect of post-injury spinal position on canal occlusion in a cervical spine burst fracture model. *Spine* 1997; 22:1710-5
- Graham CB III, Wippold FJ, Bae KT, Pilgram TK, Shaibani A, Kido DK: Comparison of CT myelography performed in the prone positions in the detection of cervical spinal stenosis. *Clin Radiol* 2001; 56:35-9
- Benner BG: Etiology, pathogenesis, and natural history of discogenic neck pain, radiculopathy, and myelopathy. *The Cervical Spine*, 3rd edition. Edited by the Cervical Spine Research Society Editorial Committee. Philadelphia, Lippincott-Raven, 1998, pp 735-40
- Lee TC, Yang LC, Chen HJ: Effect of patient position and hypotensive anesthesia on inferior vena caval pressure. *Spine* 1998; 23:941-7
- Dominguez J, Rivas JJ, Lobato RD, Diaz V, Larru E: Irreversible tetraplegia after tracheal resection. *Ann Thorac Surg* 1996; 62:278-80
- Deem S, Shapiro HM, Marshall LF: Quadriplegia in a patient with cervical spondylolysis after thoracolumbar surgery in the prone position. *ANESTHESIOLOGY* 1991; 75:527-8
- Miller RA, Crosby G, Sundaram P: Exacerbated spinal neurological deficit during sedation of a patient with cervical spondylolysis. *ANESTHESIOLOGY* 1987; 67:844-6
- Bejjani GK, Rizkallah RG, Tzortidis F, Mark AS: Cervical spinal cord injury during cerebral angiography with MRI confirmation: Case report. *Neuroradiology* 1998; 40:51-3
- Weglinski MR, Berge KH, Davis DH: New-onset neurological deficits after general anesthesia for MRI. *Mayo Clin Proc* 2002; 77:101-3
- Magnaes B: Clinical recording of pressure on the spinal cord and cauda equina: III. Pressure on the cervical spinal cord during endotracheal intubation in patients with cervical spondylolysis. *J Neurosurg* 1982; 57:64-6
- Crosby ET, Lui A: The adult cervical spine: Implications for airway management. *Can J Anaesth* 1990; 37:77-93
- Goldberg W, Mueller C, Panacek E, Tigges S, Hoffman JR, Mower WR: Distribution and patterns of blunt traumatic cervical spine injury. *Ann Emerg Med* 2001; 38:17-21
- Holly LT, Kelly DF, Counelis GJ, Blinman T, McArthur DL, Cryer HG: Cervical spine trauma associated with moderate and severe head injury: Incidence, risk factors, and injury characteristics. *J Neurosurg (Spine 3)* 2002; 96:285-291
- Demetriades D, Charalambides K, Chahwan S, Hanpeter S, Alo K, Velmahos G, Murray J, Asenio J: Nonskeletal cervical spine injuries: Epidemiology and diagnostic pitfalls. *J Trauma* 2000; 48:724-7
- Hackl W, Hausberger K, Sailer R, Ulmer H, Gassner R: Prevalence of cervical spine injuries in patients with facial trauma. *Oral Surg Oral Med Oral Pathol Oral Radiol Endod* 2001; 92:370-6
- Blackmore CC, Emerson SS, Mann FA, Koepsell TD: Cervical spine imaging in patients with trauma: Determination of fracture risk to optimize use. *Radiology* 1999; 211:759-65
- Sekhon LHS, Fehlings MG: Epidemiology, demographics and pathophysiology of acute spinal cord injury. *Spine* 2001; 26:S2-12
- Hoffman JR, Mower WR, Wolfson AB, Todd KH, Zucker MI: Validity of a set of clinical criteria to rule out injury to the cervical spine in patients with blunt trauma. *New Engl J Med* 2000; 343:94-9
- Mower WR, Hoffman JR, Pollack CV Jr, Zucker MI, Browne BJ, Wolfson AB, for the NEXUS Group: Use of plain radiography to screen for cervical spine injuries. *Ann Emerg Med* 2001; 38:1-7
- Hadley MN: Guidelines of the American Association of Neurologic Surgeons and the Congress of Neurologic Surgeons: Radiographic assessment of the cervical spine in asymptomatic trauma patients. *Neurosurgery* 2002; 50 (suppl): S30-5
- Stiell IG, Clement CM, McKnight RD, Brison R, Schull MJ, Rowe BH,

- Worthington JR, Eisenhauer MA, Cass D, Greenberg G, MacPhail I, Dreyer J, Lee JS, Bandiera G, Reardon M, Holroyd B, Lesiuk H, Wells GA: The Canadian C-Spine Rule *versus* the NEXUS Low-Risk Criteria in patients with trauma. *New Engl J Med* 2003; 349:2510-8
45. Lindsey RW, Gugala Z: Clearing the cervical spine in trauma patients. *The Cervical Spine*, 4th edition. Edited by Clark CR. Philadelphia, Lippincott Williams & Wilkins, 2005, pp 375-86
46. Grossman MD, Ravichandran G, McClelland M: National survey of the incidence of cervical spine injury and approach to cervical spine clearance in US trauma centers. *J Trauma* 1999; 47:684-90
47. Jones PS, Wadley J, Healy M: Clearing the cervical spine in unconscious adult trauma patients: A survey of practice in specialist centres in the UK. *Anaesthesia* 2004; 59:1095-9
48. Hadley MN: Guidelines of the American Association of Neurologic Surgeons and the Congress of Neurologic Surgeons: Radiographic spinal assessment in symptomatic trauma patients. *Neurosurgery* 2002; 50 (suppl):S36-43
49. Morris CGT, McCoy E: Clearing the cervical spine in unconscious poly-trauma victims, balancing risk and effective screening. *Anaesthesia* 2004; 59:464-82
50. Shuster R, Waxman K, Sanchez B, Becerra S, Chung R, Conner S, Jones T: Magnetic resonance imaging is not needed to clear cervical spines in blunt trauma patients with normal computed tomographic results and no motor deficits. *Arch Surg* 2005; 140:762-6
51. Hogan GJ, Mirvis SE, Shanmuganathan K, Scalea TM: Exclusion of unstable cervical spine injury in obtunded patients with blunt trauma: Is MR imaging needed when multi-detector row CT findings are normal? *Radiology* 2005; 237:106-13
52. Chiu WC, Haan JM, Cushing BM, Kramer ME, Scalea TM: Ligamentous injuries of the cervical spine in unreliable blunt trauma patients: Incidence, evaluation, and outcome. *J Trauma* 2001; 50:457-64
53. Poonnoose PM, Ravichandran G, McClelland M: Missed and mismanaged injuries of the spinal cord. *J Trauma* 2002; 53:314-20
54. Hendey GW, Wolfson AB, Mower WR, Hoffman JR, National Emergency X-radiography Study Group: Spinal cord injury without radiographic abnormality: Results of the National Emergency X-radiography Utilization Study in blunt cervical trauma. *J Trauma* 2002; 53:1-4
55. Marshall LF, Knowlton S, Garfin SR, Klauber MR, Eisenberg HM, Kopaniky D, Miner ME, Tabbador K, Clifton GL: Deterioration following spinal cord injury: A multicenter study. *J Neurosurg* 1987; 66:400-4
56. Frankel HL: Ascending cord lesion in the early stages following spinal injury. *Paraplegia* 1969; 7:111-8
57. Farmer J, Vaccaro A, Albert TJ, Malone S, Balderston RA, Cotler JM: Neurologic deterioration after cervical spinal cord injury. *J Spinal Disord* 1998; 11:192-6
58. Harrop JS, Sharan AD, Vaccaro AR, Przybylski GJ: The cause of neurologic deterioration after acute cervical spinal cord injury. *Spine* 2001; 26:340-6
59. Friedman D, Flanders A, Thomas C, Millar W: Vertebral artery injury after acute cervical spine trauma: Rate of occurrence as detected by MR angiography and assessment of clinical consequences. *Am J Neuroradiol* 1995; 16:443-7
60. Taneichi H, Suda K, Kajino T, Kaneda K: Traumatically induced vertebral artery occlusion associated with cervical spine injuries: Prospective study using magnetic resonance angiography. *Spine* 2005; 30:1955-62
61. Yablon IG, Ordia J, Mortara R, Reed J, Spatz E: Acute ascending myelopathy of the spine. *Spine* 1989; 14:1084-9
62. Belanger E, Picard C, Lacerte D, Lacerte D, Lavallee P, Levi ADO: Subacute posttraumatic ascending myelopathy after spinal cord injury: Report of three cases. *J Neurosurg* (Spine 2) 2000; 93:294-9
63. Al-Ghatany M, Al-Schraim M, Levi ADO, Midha R: Pathological features including apoptosis in subacute posttraumatic ascending myelopathy. *J Neurosurg*: Spine 2005; 1:619-23
64. Hadley M: Guidelines of the American Association of Neurologic Surgeons and the Congress of Neurologic Surgeons: Cervical spine immobilization before admission to hospital. *Neurosurgery* 2002; 50 (suppl):S7-17
65. DeVivo MJ, Krause JS, Lammertse DP: Recent trends in mortality and causes of death among persons with spinal cord injury. *Arch Phys Med Rehabil* 1999; 80:1411-9
66. Hauswald M, Braude D: Spinal immobilization in trauma patients: Is it really necessary? *Curr Opin Crit Care* 2002; 8:566-70
67. Kwan I, Bunn F, Roberts I, on behalf of the WHO Prehospital Trauma Care Steering Committee: Spinal immobilisation for trauma patients. *Cochrane Database Syst Rev* 2001; (2):CD002803
68. Morris CG, McCoy EP, Lavery GG: Spinal immobilisation for unconscious patients with multiple injuries. *BMJ* 2004; 329:495-9
69. Morris CGT, McCoy E: Cervical immobilization collars in ICU: Friend or foe? *Anaesthesia* 2003; 58:1051-5
70. Toscano J: Prevention of neurological deterioration before admission to a spinal cord injury unit. *Paraplegia* 1988; 26:143-50
71. Davies G, Dealin C, Wilson A: The effect of a rigid collar on intracranial pressure. *Injury* 1996; 27:647-9
72. Kolb JC, Summers RL, Galli RL: Cervical collar-induced changes in intracranial pressure. *Am J Emerg Med* 1999; 17:135-7
73. DeLorenzo RA, Olson JE, Boska M, Johnston R, Hamilton GC, Augustine J, Barton R: Optimal positioning for cervical immobilization. *Ann Emerg Med* 1996; 28:301-8
74. Podolsky S, Baraff LJ, Simon RR, Hoffman JR, Larmon B, Ablon W: Efficacy of cervical spine immobilization methods. *J Trauma* 1983; 23:461-5
75. Bednar DA: Efficacy of orthotic immobilization of the unstable subaxial cervical spine of the elderly patient: Investigation in a cadaver model. *Can J Surg* 2004; 47:251-6
76. Goutcher CM, Lochhead V: Reduction in mouth opening with semi-rigid cervical collars. *Br J Anaesth* 2005; 95:344-8
77. Lennarson PJ, Smith DW, Sawin PD, Todd MM, Sato Y, Traynelis VC: Cervical spinal motion during intubation: Efficacy of stabilization maneuvers in the setting of complete segmental instability. *J Neurosurg* (Spine 2) 2001; 94:265-70
78. Kaufman HH, Harris JH, Spencer JA, Kopansky SR: Danger of traction during radiography for cervical trauma (letter). *JAMA* 1982; 247:2369
79. Bivins HG, Ford S, Bezmalinovic Z, Price HM, Williams JL: The effect of axial traction during orotracheal intubation of the trauma victim with an unstable cervical spine. *Ann Emerg Med* 1988; 17:25-9
80. Majernick TG, Bienek R, Houston JB, Hughes HG: Cervical spine movement during orotracheal intubation. *Ann Emerg Med* 1986; 15:417-20
81. Watts ADJ, Gelb AW, Bach DB, Pelz DM: Comparison of Bullard and Macintosh laryngoscopes for endotracheal intubation of patients with a potential cervical spine injury. *ANESTHESIOLOGY* 1997; 87:1335-42
82. Lennarson PJ, Smith D, Todd MM, Carras D, Sawin PD, Brayton J, Sato Y, Traynelis VC: Segmental cervical spine motion during orotracheal intubation of the intact and injured spine with and without external stabilization. *J Neurosurg* (Spine 2) 2000; 92:201-6
83. Heath KJ: The effect on laryngoscopy of different cervical spine immobilization techniques. *Anaesthesia* 1994; 49:843-5
84. Gerling MC, Davis DP, Hamilton RS, Morris GF, Vilke GM, Garfin SR, Hayden SR: Effects of cervical spine immobilization technique and laryngoscope blade selection on an unstable cervical spine in a cadaver model of intubation. *Ann Emerg Med* 2000; 36:293-300
85. Hastings RH, Wood PR: Head extension and laryngeal view during laryngoscopy with cervical spine stabilization maneuvers. *ANESTHESIOLOGY* 1994; 80:825-31
86. Nolan JP, Wilson ME: Orotracheal intubation in patients with potential cervical spine injuries. *Anaesthesia* 1993; 48:630-3
87. Wood PR, Dresner M, Hayden Smith J, Kumar CM, Lawler PGP: Direct laryngoscopy and cervical spine stabilization. *Anaesthesia* 1994; 49:77-8
88. Donaldson WF III, Heil BV, Donaldson VP, Silvaggio VJ: The effect of airway maneuvers on the unstable C1-C2 segment: A cadaver study. *Spine* 1997; 22:1215-18
89. Aprahamian C, Thompson BM, Finger WA, Darin JC: Experimental cervical spine injury model: Evaluation of airway management and splinting techniques. *Ann Emerg Med* 1984; 13:584-7
90. Hauswald M, Sklar DP, Tandberg D, Garcia JF: Cervical spine movement during airway management: Cinefluoroscopic appraisal in human cadavers. *Am J Emerg Med* 1991; 9:535-8
91. Sawin PD, Todd MM, Traynelis VC, Farrell SB, Nader A, Sato Y, Clausen JD, Goel VK: Cervical spine motion with direct laryngoscopy and orotracheal intubation: An *in vivo* cinefluoroscopic study of subjects without cervical abnormality. *ANESTHESIOLOGY* 1996; 85:26-36
92. Horton WA, Fahy L, Charters P: Disposition of the cervical vertebrae, atlanto-axial joint, hyoid and mandible during x-ray laryngoscopy. *Br J Anaesth* 1989; 63:435-8
93. Brimacombe J, Keller C, Kunzel KH, Gaber O, Boehler M, Puhlinger F: Cervical spine motion during airway management: a cinefluoroscopic study of the posteriorly destabilized third cervical vertebrae in human cadavers. *Anesth Analg* 2000; 91:1274-8
94. MacIntyre PR, McLeod ADM, Hurley R, Peacock C: Cervical spine movements during laryngoscopy: Comparison of the Macintosh and McCoy laryngoscope blades. *Anaesthesia* 1999; 54:413-8
95. Hastings RH, Vigil AC, Hanna R, Yang BY, Sartoris DJ: Cervical spine movement during laryngoscopy with the Bullard, Macintosh and Miller laryngoscopes. *ANESTHESIOLOGY* 1995; 82:859-69
96. Cooper SD, Benumof JL, Ozaki GT: Evaluation of the Bullard laryngoscope using the new intubating stylet: Comparison with conventional laryngoscopy. *Anesth Analg* 1994; 79:965-70
97. Rudolph C, Schneider JP, Wallenborn J, Schaffranietz L: Movement of the upper cervical spine during laryngoscopy: A comparison of the Bonfils intubation fiberscope and the Macintosh laryngoscope. *Anaesthesia* 2005; 60:668-72
98. Agro F, Barzoi G, Montechia F: Tracheal intubation using a Macintosh laryngoscope or a Glidescope in 15 patients with cervical spine immobilization. *Br J Anaesth* 2003; 90:705-6
99. Turckstra TP, Craen RA, Pelz DM, Gelb AW: Cervical spine motion: A fluoroscopic comparison during intubation with lighted stylet, Glidescope, and Macintosh laryngoscope. *Anesth Analg* 2005; 101:910-5
100. Kihara S, Watanabe S, Brimacombe J, Taguchi N, Yaghuji Y, Yamaski Y: Segmental cervical spine movement with the intubating laryngeal mask during manual in-line stabilization in patients with cervical pathology undergoing cervical spine surgery. *Anesth Analg* 2000; 91:195-200
101. Keller C, Brimacombe J, Keller K: Pressures exerted against the cervical

- vertebrae by the standard and intubating laryngeal mask airways: A randomized, controlled, cross-over study in fresh cadavers. *Anesth Analg* 1999; 89:1296-300
102. Gerling MC, Davis DP, Hamilton RS, Morris GF, Vilke GM, Garfin SR, Hayden SR: Effect of surgical cricothyrotomy on the unstable cervical spine in a cadaver model of intubation. *J Emerg Med* 2001; 20:1-5
 103. Lord SA, Boswell WC, Williams JS, Odon JW, Boyd CR: Airway control in trauma patients with cervical spine fractures. *Prehosp Disas Med* 1994; 9:44-9
 104. Rosenblatt WH, Wagner PJ, Ovassapian A, Zain ZN: Practice patterns in managing the difficult airway by anesthesiologists in the United States. *Anesth Analg* 1998; 87:153-7
 105. Jenkins K, Wong DT, Correa R: Management choices for the difficult airway by anesthesiologists in Canada. *Can J Anesth* 2002; 49:850-6
 106. Ezri T, Szmuk P, Warters RD, Katz J, Hagberg CA: Difficult airway management practice patterns among anesthesiologists practicing in the United States: Have we made any progress? *J Clin Anesth* 2003; 15:418-22
 107. Meschino A, Devitt JH, Koch JP, Szalai JP, Schwartz ML: The safety of awake tracheal intubation in cervical spine injury. *Can J Anaesth* 1992; 39:114-7
 108. Holley J, Jordan R: Airway management in patients with unstable cervical spine fractures. *Ann Emerg Med* 1989; 10:1237-9
 109. Rhee KJ, Green W, Holcroft JW, Mangili JA: Oral intubation in the multiply injured patient: The risk of exacerbating spinal cord damage. *Ann Emerg Med* 1990; 19:511-4
 110. Scanel G, Waxman K, Tommaga G, Barker S, Anna C: Orotracheal intubations in trauma patients with cervical fractures. *Arch Surg* 1993; 128:903-6
 111. Shatney CH, Brunner RD, Nguyen TQ: The safety of oro-tracheal intubation in patients with unstable cervical spine fracture or high spinal cord injury. *Am J Surg* 1995; 170:676-80
 112. Talucci RC, Shaikh KA, Schwab CW: Rapid sequence induction with oral endotracheal intubation in the multiply injured patient. *Am Surg* 1988; 54:185-7
 113. Suderman VS, Crosby ET, Lui A: Elective oral tracheal intubation in cervical spine-injured adults. *Can J Anaesth* 1991; 38:785-9
 114. McCrory C, Blunnie WP, Moriarty DC: Elective tracheal intubation in cervical spine injuries. *Irish Med J* 1999; 90:234-5
 115. Wright SW, Robinson GG II, Wright MB: Cervical spine injuries in blunt trauma patients requiring emergent endotracheal intubation. *Am J Emerg Med* 1992; 10:104-9
 116. Norwood S, Myers MB, Butler TJ: The safety of emergency neuromuscular blockade and oro-tracheal intubation in the acutely injured trauma patient. *J Am Coll Surg* 1994; 179:646-52
 117. Walls RM.: Orotracheal intubation and potential cervical spine injury (letter). *Ann Emerg Med* 1987; 16:373
 118. Grande CM, Barton CR, Stene JK: Appropriate techniques for airway management of emergency patients with suspected spinal cord injury. *Anesth Analg* 1988; 67:714-5
 119. McLeod ADM, Calder I: Spinal cord injury and direct laryngoscopy: The legend lives on. *Br J Anaesth* 2000; 84:705-8
 120. Muckart DJ, Bhagwanjee S, van der Merwe R: Spinal cord injury as a result of endotracheal intubation in patients with undiagnosed cervical spine fractures. *ANESTHESIOLOGY* 1997; 87:418-20
 121. Redl G: Massive pyramidal tract signs after endotracheal intubation: A case report of spondyloepiphyseal dysplasia congenital. *ANESTHESIOLOGY* 1998; 89:1262-4
 122. Yan K, Diggan MF: A case of central cord syndrome caused by intubation: A case report. *J Spin Cord Med* 1997; 20:230-2
 123. Yaszemski MJ, Shepler TR: Sudden death from cord compression associated with atlanto-axial instability in rheumatoid arthritis. *Spine* 1990; 15:338-41
 124. Hastings RH, Kelley SD: Neurologic deterioration associated with airway management in a cervical spine-injured patient. *ANESTHESIOLOGY* 1993; 78:580-3
 125. Liang BA, Cheng MA, Tempelhoff R: Efforts at intubation: Cervical injury in an emergency circumstance? *J Clin Anesth* 1999; 11:349-52
 126. Powell RM, Heath KJ: Quadriplegia in a patient with an undiagnosed odontoid peg fracture: The importance of cervical spine immobilization in patients with head injuries. *J Roy Army Med Corps* 1996; 142:79-81
 127. Dunham CM, Barraco RD, Clark DE, Daley BJ, Davis FE III, Gibbs MA, Knuth T, Letarte PB, Luchetter FA, Omert L, Weirter LJ, Wiles CE III, EAST Practice Management Guidelines Work Group: Guidelines for emergency tracheal intubation immediately after traumatic injury. *J Trauma* 2003; 55:162-79
 128. Fuchs G, Schwarz G, Baumgartner A, Kaltenbock F, Voit-Augustin H, Planinz W: Fiberoptic intubation in 327 patients with lesions of the cervical spine. *J Neurosurg Anesth* 1999; 11:11-6
 129. McGuire G, El-Beheiry H: Complete upper airway obstruction during awake fiberoptic intubation in patients with unstable cervical spine fractures. *Can J Anesth* 1999; 46:176-8
 130. Kerwin AJ, Croce MA, Timmons SD, Maxwell RA, Malhotra AK, Fabian TC: Effects of fiberoptic bronchoscopy on intracranial pressure in patients with brain injury: A prospective clinical study. *J Trauma* 2000; 48:878-83
 131. Cohn AI, Zornow MH: Awake endotracheal intubation in patients with cervical spine disease: A comparison of the Bullard laryngoscope and the fiberoptic bronchoscope. *Anesth Analg* 1995; 81:1283-6
 132. Chestnut RM: Management of brain and spine injuries. *Crit Care Clin* 2004; 20:25-55
 133. Peterson GN, Domino KB, Caplan RA, Posner KL, Lee LA, Cheney FW: Management of the difficult airway: A closed claims analysis. *ANESTHESIOLOGY* 2005; 103:33-9
 134. Urdanetta F, Layon AJL: Respiratory complications in patients with traumatic cervical spine injuries: Case report and review of the literature. *J Clin Anesth* 2003; 15:398-405
 135. Richards CF, Mayberry JC: Initial management of the trauma patient. *Crit Care Clin* 2004; 20:1-11
 136. *Advanced Trauma Life Support for Physicians Student Manual*, 6th edition. Chicago, American College of Surgeons, 1997
 137. Ball PA: Critical care of spinal cord injury. *Spine* 2001; 26 (suppl):S27-S30
 138. Ford P, Nolan J: Cervical spine injury and airway management. *Curr Opin Anaesth* 2000; 15:193-201
 139. Ivy ME, Cohn SM: Addressing the myths of cervical spine injury management. *Am J Emerg Med* 1997; 15:591-5
 140. Abrams KJ, Grande CM: Airway management of the trauma patient with cervical spine injury. *Curr Opin Anaesth* 1994; 7:184-90
 141. Gajraj NM, Pennant JH, Giesecke AH: Cervical spine trauma and airway management. *Curr Opin Anaesth* 1993; 6:69-74
 142. Crosby ET: Tracheal intubation in the cervical spine-injured patient. *Can J Anesth* 1992; 39:105-9
 143. Hastings RH, Marks JD: Airway management for trauma patients with potential cervical spine injuries. *Anesth Analg* 1991; 73:471-82