

Are your **MRI contrast agents** cost-effective?

Learn more about generic **Gadolinium-Based Contrast Agents**.



FRESENIUS
KABI

caring for life

AJNR

Gd-DTPA Enhancement in MR Imaging of Central Pontine Myelinolysis

Kevin J. Koch and Richard R. Smith

AJNR Am J Neuroradiol 1989, 10 (5 suppl) S58

http://www.ajnr.org/content/10/5_suppl/S58.citation

This information is current as
of April 19, 2024.

Gd-DTPA Enhancement in MR Imaging of Central Pontine Myelinolysis

Central pontine myelinolysis is a well-recognized clinicopathologic demyelinating disorder with characteristic MR features [1–3]. We report a case that, in addition to the usual MR findings, also had peripheral gadolinium enhancement on T1-weighted MR images, a characteristic not previously reported in central pontine myelinolysis.

Case Report

A 37-year-old man with a history of alcohol abuse was admitted for evaluation of agitation, incoordination, and confusion. Initial screening laboratory examination revealed a serum sodium of 96 mEq/l, blood urea nitrogen of 4 mg/dl, and creatinine of 0.7 mg/dl. The patient's severe hyponatremia was corrected with IV fluids including 5% dextrose in normal saline. Serum sodium levels were normalized over 72-hr and remained normal throughout the rest of the hospitalization. CT of the head on admission showed moderate, diffuse cerebral atrophy.

MR imaging of the head without and with IV administration of gadopentetate dimeglumine (0.1 mmol/kg) showed characteristic abnormalities on both short and long TR images in the pons and both thalami consistent with the clinical diagnosis of central pontine and extrapontine myelinolysis (Figs. 1A–1C). With gadolinium, ring enhancement around the pontine abnormality was seen (Fig. 1D).

Discussion

Central pontine myelinolysis is a rare, but well-documented, demyelinating disorder originally described by Adams et al [4]. The process is seen in association with chronic alcoholism, states such as malnutrition and liver disease, and other conditions that predispose the patient to severe metabolic and/or serum electrolyte alterations. The importance of serum electrolyte abnormalities, in particular, severe hyponatremia, in the pathogenesis of central pontine myelinolysis has been postulated [5]. Clinically, diagnosis on the basis of physical examination can be made in only one-third of cases; patients have quadriplegia, pseudobulbar palsy, and pseudocoma. In the other two-thirds, the diagnosis may be obscured by the profound gravity of the primary aggravating disease [6].

MR is superior to CT in the visualization of central pontine myelinolysis. The findings on MR may be similar to those associated with other conditions that affect the pons, such as infarction, multiple sclerosis, tumor, and infection. The lack of surrounding edema should help exclude infection or neoplasm, as would the lack of a mass effect. The lack of associated white-matter lesions in the periventric-

ular area would make multiple sclerosis unlikely. An infarct may be more difficult to exclude, but the clinical history should help differentiate the two processes.

The ring enhancement seen in our case is similar to that described by Grossman et al. [7] in their discussion of gadolinium enhancement in MR imaging of multiple sclerosis plaques. Foci of acute demyelination showed either homogeneous or ring enhancement, which appeared related to a transient breakdown of the normal blood-brain barrier at the interface of the focus of acute demyelination and normal brain. Chronic lesions did not show gadolinium enhancement, although presumably asymptomatic acute lesions were seen. The marginal enhancement in central pontine myelinolysis also occurs at the interface of normal brain and the focus of acute demyelination. The transient breakdown of the blood-brain barrier may be secondary to the destructive myelinolysis as perivascular inflammation, similar to that seen with multiple sclerosis, does not tend to occur in central pontine myelinolysis [6]. Our case confirms that other acute demyelinating lesions can show gadolinium enhancement and may do so in patterns similar to those seen in multiple sclerosis.

Kevin J. Koch
Richard R. Smith
Indiana University Medical Center
University Hospital
Indianapolis, IN 46223

REFERENCES

1. Thompson AJ, Brown MM, Swash M, Thakkar C, Scholtz C. Autopsy validation of MRI in central pontine myelinolysis. *Neuroradiology* 1988;30:175–177
2. DeWitt LD, Bronmino FS, Kistler JP, et al. Central pontine myelinolysis: demonstration by nuclear magnetic resonance. *Neurology* 1984;34:570–576
3. Rippe DJ, Edwards MK, D'Amour PG, Holden RW, Roos KL. MR imaging of central pontine myelinolysis. *J Comput Assist Tomogr* 1987;11(4):724–726
4. Adams RD, Victor M, Mancall E. Central pontine myelinolysis: a hitherto undescribed disease occurring in alcoholic and malnourished patients. *Arch Neurol Psychiatry* 1959;81:154–172
5. Sterns RH, Riggs JE, Schochet SS. Osmotic demyelination syndrome following correction of hyponatremia. *N Engl J Med* 1986;314:1535–1542
6. Adams RD, Victor M, eds. *Principles of neurology*, 3rd ed. New York: McGraw-Hill, 1985:778–780
7. Grossman RI, Gonzalez-Scarano F, Atlas SW, Galetta S, Silberberg DH. Multiple sclerosis: gadolinium enhancement in MR imaging. *Radiology* 1986;161:721–725

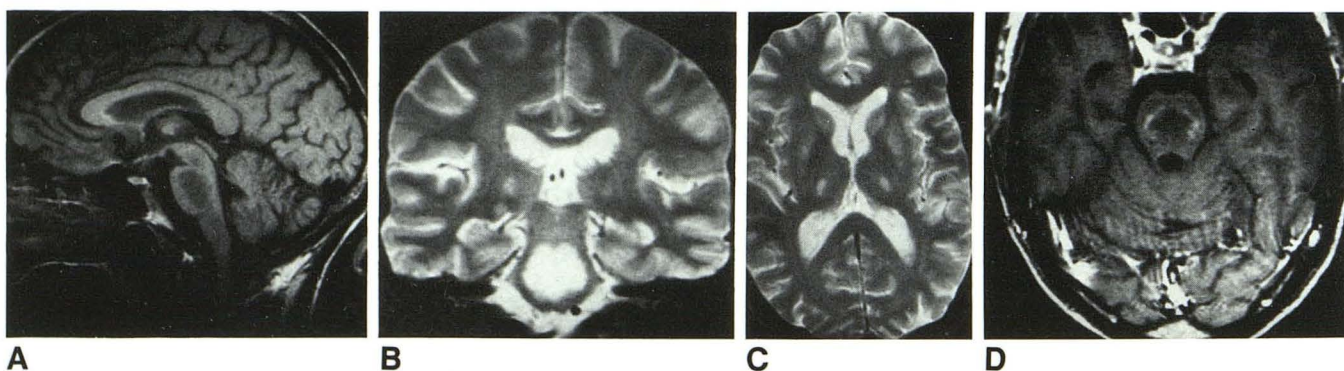


Fig. 1.—Central pontine myelinolysis.
A, Sagittal MR image (600/26) shows central well-demarcated low signal intensity in pons with peripheral rim of normal ventral pontine tissue and pontine tegmentum.
B and C, Coronal (B) and axial (C) T2-weighted MR images (2500/80) confirm central symmetric pathologic changes in pons (B) and show bilateral thalamic lesions (B and C). Symmetric areas of high signal intensity in thalamus bilaterally correspond to areas of extrapontine myelinolysis (C).
D, Axial T1-weighted gadolinium-enhanced MR image (600/26) shows ring enhancement clearly demarcating margin of demyelination in pons.