

Are your **MRI contrast agents** cost-effective?

Learn more about generic **Gadolinium-Based Contrast Agents**.



FRESENIUS
KABI

caring for life

AJNR

The relationship between frontal sinus drainage and osteomeatal complex disease: a CT study in 217 patients.

R Wallace, J E Salazar and S Cowles

AJNR Am J Neuroradiol 1990, 11 (1) 183-186

<http://www.ajnr.org/content/11/1/183>

This information is current as of May 8, 2024.

The Relationship Between Frontal Sinus Drainage and Osteomeatal Complex Disease: A CT Study in 217 Patients

Robert Wallace¹
Jorge E. Salazar
Stefan Cowles

Over a period of 2 years we reviewed the CT scans of 217 patients with recurrent sinusitis. Our findings revealed a number of cases of osteomeatal complex disease with no frontal sinus involvement. This result is difficult to reconcile with the concept of a common drainage in the middle meatus shared by the frontal and anterior ethmoid sinuses.

We conclude that the frontal sinus drains separately from the other paranasal sinuses in a large percentage of cases, and that the frontal sinus is frequently spared when there is ethmoid or maxillary sinusitis.

AJNR 11:183-186, January/February 1990

Drainage of the frontal sinuses has not been well delineated in the radiologic literature [1-3]; only one publication describes it briefly [4]. With the increasing use of fiberoptic endoscopic sinus surgery, coronal CT of the sinuses has become the ideal complement to this surgical procedure. Direct coronal CT provides excellent anatomic display of the osteomeatal unit or complex (OMC), which includes the middle meatus, infundibulum, hiatus semilunaris, frontal recess, anterior ethmoids, and maxillary sinus ostium [4-6].

In our practice, we have observed a high frequency of OMC disease with no frontal sinus involvement. OMC disease is inflammatory mucosal disease that primarily affects the anterior ethmoid cells, the ethmoid infundibulum, and the middle meatus, and secondarily affects the drainage pathways leading to the middle meatus [7].

In this investigation we reviewed all sinus CT examinations performed at our institution during a 2-year period for the purpose of describing the drainage of the frontal sinus in relation to the OMC. In addition, we correlated our findings with previously reported anatomic dissections [8, 9].

Materials and Methods

Over a 2-year period, from January 1987 through December 1988, we evaluated retrospectively 217 CT examinations of the sinuses in patients with sinus disease. The patients were studied at the Veterans Administration Medical Center in Memphis. All studies were done on a General Electric 8800 scanner using bone algorithm. Direct coronal images with 5-mm slice thickness and 3-mm overlap were obtained. Studies with motion or beam-hardening artifacts were not reviewed. The contralateral sinus was included in patients who had sinus surgery on one side. With each side considered separately, 434 OMCs were reviewed. Three hundred seventeen OMCs were excluded from the study because of surgery, pansinusitis, the absence of frontal sinuses, or normality.

Results

The remaining 117 OMCs were divided into the following three groups: (1) OMC disease without frontal sinus involvement, (2) OMC disease with frontal sinus

Received March 7, 1989; revision requested May 2, 1989; revision received June 12, 1989; accepted June 20, 1989.

¹ All authors: Department of Radiology, University of Tennessee, Memphis, Veterans Administration Medical Center, 865 Jefferson Ave., Memphis, TN, 38163. Address reprint requests to J. E. Salazar.

0195-6108/90/1101-0183
© American Society of Neuroradiology

involvement, or (3) frontal sinus disease without OMC disease.

There were 84 patients in group 1, 32 in group 2, and one in group 3. Seventeen patients with bilateral OMC disease had frontal sinus involvement on one side with no frontal sinus involvement on the contralateral side.

Discussion

Drainage of the frontal sinus is variable, as determined by embryological development. The lateral nasal wall develops from furrows that are separated by ridges; the furrows become the meatus and the ridges become the conchae. A deep anterior superior depression in the middle meatus is the frontal recess (Fig. 1), sometimes called the ethmoidal prechamber to the frontal sinus [7]. The frontal sinus may develop from the upward extension of the entire frontal recess into the frontal bone, from one of the pits of the frontal recess, from one of the cells of the ethmoid infundibulum, or, rarely, from the ethmoid bulla. When development originates from direct extension of the frontal recess or from a frontal recess pit, the frontal sinus drains separately from the ethmoid infundibulum, hiatus semilunaris, or ethmoid cells [8, 10]. If the frontal sinus originates from the direct extension of the

frontal recess (Fig. 2), drainage is via a frontal ostium. If, however, the frontal sinus develops from a pit in the frontal recess, drainage takes place through a nasofrontal duct, which also opens above the infundibulum (Fig. 3). In either event, the ostium of the frontal sinus or the nasofrontal duct opens directly into the middle meatus. On the other hand, if a frontal sinus originates from one of the cells of the ethmoid infundibulum, a nasofrontal duct exists, but drainage is into the ethmoid infundibulum (Fig. 4). Occasionally, a frontal sinus arises above the ethmoid bulla.

If inflammatory disease involves the opening of any of these sinuses and/or drainage pathways in the middle meatus, hiatus semilunaris, or ethmoid infundibulum, the result is retention of mucus, mucosal inflammation, and thickening in the involved sinus. Under appropriate circumstances, the sinus becomes infected and chronically diseased because of scarring at the sinus ostium. The anatomy of the sinuses determines the tendency to develop frontal sinus disease with the onset of ethmoid inflammation. Frontal sinuses that arise from the ethmoid bulla become diseased whenever the draining ethmoid air cell becomes diseased. Frontal sinuses draining into the ethmoid infundibulum or hiatus semilunaris are involved when there is mucosal inflammation at their drainage meatus (Fig. 5). Patients with completely separate frontal

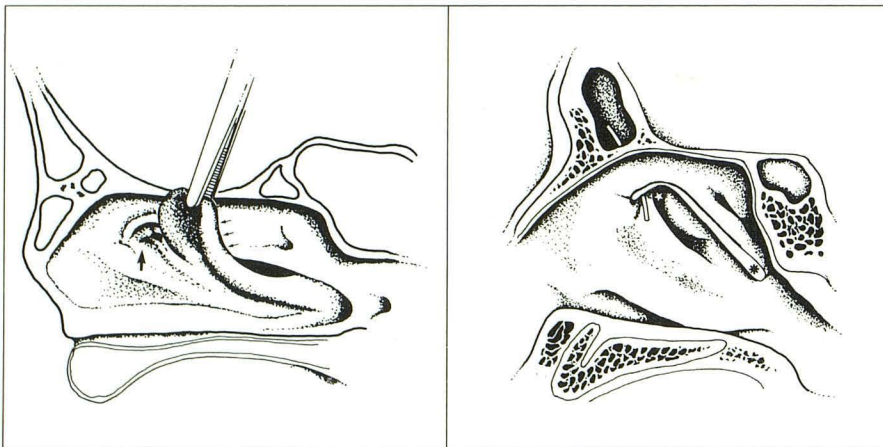


Fig. 1.—Lateral nasal wall. Retracted anterior attachment of middle turbinate (small arrows) enables visualization of frontal recess (large arrow). (Modified from [8].)

1 2

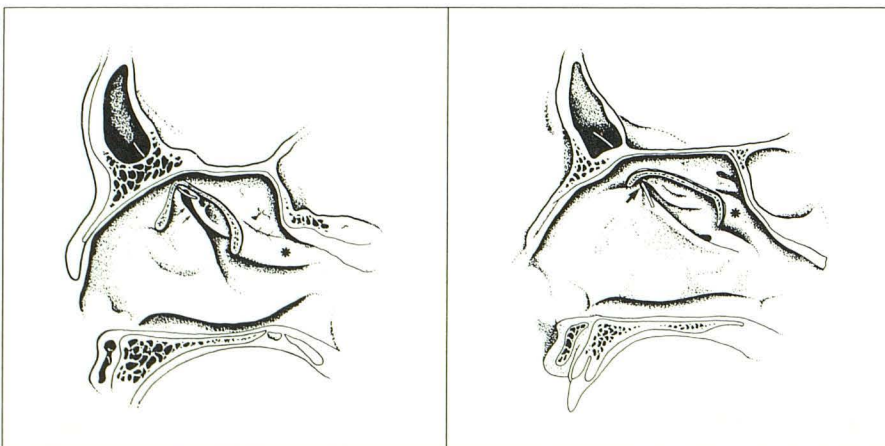


Fig. 2.—Frontal sinus opening in frontal recess via frontal ostium. Star = infundibulum; asterisk = middle turbinate. (Modified from [8].)

3 4

Fig. 3.—Suprafundibular opening of frontal sinus via nasofrontal duct. Arrows = infundibulum; asterisk = middle turbinate. (Modified from [8].)

Fig. 4.—Nasofrontal duct opens into infundibulum (arrow). Asterisk = middle turbinate. (Modified from [8].)

sinus drainage by way of the frontal recess sustain frontal sinus disease only when there is diffuse involvement of the entire meatus resulting in pansinusitis, or, rarely, when middle meatal involvement at the frontal recess causes frontal sinus disease but no ethmoid or maxillary sinus disease [7].

In studies of cadaver sinuses at the University of Chicago, Van Alyea [8] found that 55% of the specimens had drainage by the frontal recess that opened directly into the middle meatus by the frontal ostium. Thirty percent of specimens had a frontal recess pit that drained above the infundibulum but not into it, for a total of 85% that drained into a frontal recess pit or the frontal ostium. In 15% of specimens, the nasofrontal connection was infundibular. Approximately 1% had drainage above the ethmoid bulla.

In another study, Kasper [9] found that 60% of the sinuses he examined drained via a frontal recess, 34% drained above the cranial end of the infundibulum, 4% drained into the infundibulum, and 2% drained into the ethmoid bulla. A total of 94% of the sinuses in Kasper's study drained into a frontal recess pit or frontal ostium.

In our study, 72% of the cases had OMC involvement without frontal sinus disease (Fig. 6). There is a reasonable correlation between this finding (72%) and the findings of Van Alyea (85%) and Kasper (94%), which describe the anatomic

site of drainage of the frontal sinuses. We found 27% of our cases of OMC disease had frontal sinus involvement. This is slightly lower than the 39% reported by Zinreich et al. [4] but higher than the 16% and 6% that would be predicted by the sinus anatomy reported by Van Alyea and Kasper, respectively. The higher percentages found in our study and Zinreich's study are probably a result of the extension of mucosal disease into the frontal recess, thereby obstructing the frontal sinus drainage. The two anatomic studies, based as they were on cadaver specimens, could not take into account obstruction due to mucosal disease.

In correlating our CT studies of the sinuses with the anatomic studies of Van Alyea and Kasper, we found a close correspondence between our data and theirs, indicating that the anatomy of the frontal sinus drainage and its proximity to the pathologic process determines whether the frontal sinus will be involved. The frontal sinus is frequently spared when there is ethmoid or maxillary sinusitis. This has not been well documented in the radiologic literature.

ACKNOWLEDGMENTS

We thank Patty Felix and Geneva Reid for assistance in manuscript preparation.

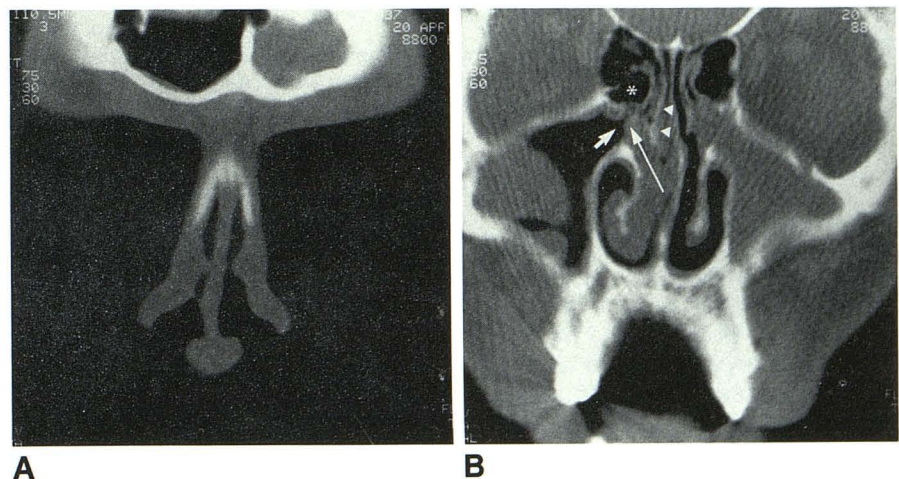


Fig. 5.—A and B, Bilateral osteomeatal complex disease and left frontal sinusitis. Notice the normal right frontal sinus despite total obliteration of ipsilateral nasal fossa and middle meatus. Bilateral maxillary sinusitis. Short arrow points to maxillary sinus ostium leading to infundibulum; long arrow = uncinete process; asterisk = bulla ethmoidalis; arrowheads = middle turbinate.

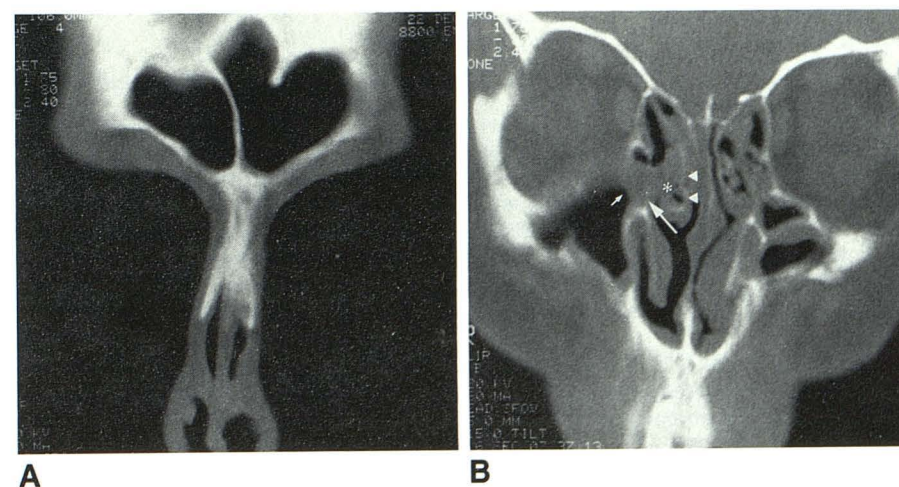


Fig. 6.—A and B, Normal frontal sinuses (A) and coronal CT scan at level of maxillary sinus ostia (B). Bilateral osteomeatal complex disease and bilateral maxillary sinusitis. Small arrow = occluded maxillary sinus ostium and infundibulum; long arrow = uncinete process; asterisk = expected location of middle meatus; arrowheads = middle turbinate.

REFERENCES

1. Dodd GD, Jing B. *Radiology of the nose, paranasal sinuses and nasopharynx*. Baltimore: Williams & Wilkins, 1977:60
2. Samuel E, Lloyd G. *Clinical radiology of the ear, nose and throat*. Philadelphia: Saunders, 1978:19-20
3. Harris L, Marano GD, McCorkle D. Nasofrontal duct: CT in frontal sinus trauma. *Radiology* 1987;165:195-198
4. Zinreich SJ, Kennedy DW, Rosenbaum AE, et al. Paranasal sinuses: CT imaging requirements for endoscopic surgery. *Radiology* 1987;163:769-775
5. Naumann HH. Pathologische Anatomie der chronischen Rhinitis und Sinusitis. In *Proceedings of the VIII International Congress of Otorhinolaryngology*, Series No. 113. Amsterdam: Excerpta Medica, 1965:80
6. Kennedy DW, Zinreich SJ, Rosenbaum AE, Johns ME. Functional endoscopic sinus surgery: theory and diagnostic evaluation. *Arch Otolaryngol* 1985;111:576-582
7. Stammberger H, Wolf G. Headaches and sinus diseases: the endoscopic approach. *Ann Otol Rhinol Laryngol* 1988;97:3-23
8. Van Alyea OE. *Nasal sinuses: an anatomic and clinical consideration*. Baltimore: Williams & Wilkins, 1951:79
9. Kasper KA. Nasofrontal connection. *Arch Otolaryngol* 1936;36:322-343
10. Ritter FN. *The paranasal sinuses: anatomy and surgical techniques*. St. Louis: Mosby, 1978:34-35