

Are your **MRI contrast agents** cost-effective?

Learn more about generic **Gadolinium-Based Contrast Agents**.



FRESENIUS
KABI

caring for life

AJNR

Treatment of dural sinus thrombosis by urokinase infusion.

T P Smith, R T Higashida, S L Barnwell, V V Halbach, C F Dowd, K W Fraser, G P Teitelbaum and G B Hieshima

AJNR Am J Neuroradiol 1994, 15 (5) 801-807

<http://www.ajnr.org/content/15/5/801>

This information is current as of May 5, 2024.

Treatment of Dural Sinus Thrombosis by Urokinase Infusion

Tony P. Smith, Randall T. Higashida, Stanley L. Barnwell, Van V. Halbach, Christopher F. Dowd, Kenneth W. Fraser, George P. Teitelbaum, and Grant B. Hieshima

PURPOSE: To gain a preliminary understanding of the role of thrombolytic therapy for the thrombosed dural sinus, we retrospectively reviewed our initial experience. **METHODS:** Seven patients, ages 25 to 71, who presented with symptomatic dural sinus thrombosis and who failed a trial of medical therapy were treated with direct infusion of urokinase into the thrombosed sinus. Patients received urokinase doses ranging from 20 000 to 150 000 U/h with a mean infusion time of 163 hours (range 88 to 244 hours). **RESULTS:** Patency of the affected dural sinus was achieved with antegrade flow in all patients. Six patients either improved neurologically over their prethrombolysis state or were healthy after thrombolysis; one of them required angioplasty. The other patient improved after surgical repair of a residual dural arteriovenous fistula. The only complications were an infected femoral access site which resolved after treatment with antibiotics and hematuria which cleared after discontinuation of anticoagulation. **CONCLUSIONS:** Thrombolysis of the thrombosed dural sinus shows promise as a safe and efficacious treatment. The results of this study should provide the impetus for further research.

Index terms: Dural sinuses; Thrombosis, dural sinus; Thrombolysis; Interventional neuroradiology

AJNR Am J Neuroradiol 15:801-807, May 1994

Dural sinus thrombosis is a well-defined entity but can often be clinically difficult to diagnosis (1). The prognosis for patients with dural sinus thrombosis has also been difficult to elucidate. Early series were based on autopsy findings; thrombosis was found in 0.1% of all deaths (2). With the advent of angiography, and more recently, computed tomography and magnetic resonance, much higher incidences have been reported, mostly in patients with very mild symptoms who often recover without residual deficit (3-6). However, dural sinus thrombosis can at times carry a high rate of morbidity and mortality, and the treatment may therefore require more urgent intervention than standard medical therapy. Early reports of treatment with thrombolytic agents have been mostly case reports with very

good results (7-12). Over the past 3 years, we have treated seven patients with dural sinus thrombosis using urokinase by direct infusion into the dural sinuses. We report our results in order to assess the safety and efficacy of direct infusion of a thrombolytic agent into the thrombosed dural sinus.

Patients and Methods

Patient characteristics are summarized in the Table. A total of seven patients, four women and three men, presented with clinical signs and symptoms suggesting increased intracranial pressure including headache, papilledema, and/or focal neurologic deficits. The decision to proceed with thrombolytic therapy was based on the clinical and angiographic findings. All patients had worsening of their symptoms despite medical treatment, including two patients with progressive lethargy. Symptom duration ranged from 1 week to 6 months before treatment with thrombolytics, and all patients received standard medical treatment including anticoagulation ranging from 1 day to 3 months during this interval. All patients' symptoms and physical findings were carefully evaluated by at least one of the neuroscience clinical services to determine the final need for aggressive therapy. Prior imaging studies including magnetic resonance and computed tomography were available for all patients and did not suggest acute hemorrhage. Initial angiography was performed via a transfemoral route

Received February 12, 1993; accepted for publication May 26.

From the Department of Radiology, University of California, San Francisco (T.P.S., R.T.H., V.V.H., C.F.D., K.W.F., G.P.T., G.B.H.); and Division of Neurosurgery, Oregon Health Sciences University, Portland (S.L.B.).

Address reprint requests to Tony P. Smith, MD, Department of Radiology, University of California, San Francisco, 505 Parnassus Ave, L352, San Francisco, CA 94143-0628.

AJNR 15:801-807, May 1994 0195-6108/94/1505-0801

© American Society of Neuroradiology

in all patients (Fig 1). Thrombosis of the dural sinuses ranged from marked filling defects within the contrast column to complete obstruction. All patients had thrombosis of the transverse sinus with occlusion or hypoplasia of the opposite transverse sinus. In addition, two patients had thrombosis of the superior sagittal sinus.

All seven patients were fully anticoagulated either before the procedure based on partial thromboplastin times (1.5 to 2 times control), or in the angiography suite based on activated clotting times (2 times control). After angiography, venous access was achieved from the femoral route in one patient and from the internal jugular route in 7 patients. One patient had both a femoral and a jugular route (Table, patient 1). A 3-F catheter (Tracker, Target Therapeutics, Fremont, Calif) was placed as far into the thrombus as possible and its location confirmed by contrast injection (Fig 1). However, guide wire and catheter placement through completely occluded sinuses was not purposefully attempted.

All seven patients received urokinase by a constant infusion method as previously described for the peripheral system, three of the seven receiving a loading dose (80 000, 100 000, and 250 000 U) over a 15-minute interval (13–15). One of these patients received the loading dose (250 000 U) in a pulse-spray manner using a catheter with

side holes in addition to an end hole (Target Therapeutics). The doses of urokinase are summarized in the Table. Three patients had their doses of urokinase increased during infusion to an eventual level of 150 000 U/h.

Venography via the infusion catheter was carried out every 12 to 24 hours, and the catheter was repositioned into an optimal location for maximal thrombolysis when necessary. In one patient mechanical disruption of thrombus in the transverse sinus was attempted with a 5-F occlusion balloon catheter (Arrow International, Reading, Pa) at 73 hours of urokinase infusion (Table, patient 7) (Fig 2). Overall, total infusion times ranged from 88 to 244 hours (average 163 hours). Patients were kept in either the neurologic intensive care unit or close observation area throughout infusion, where frequent vital signs and neurological assessment were possible. All patients were kept fully anticoagulated with intravenous heparin during infusion (partial thromboplastin times 1.5 to 2 times control). Because of hematuria, one patient had the heparin discontinued after 48 hours of urokinase infusion (Table, patient 7). Despite continued urokinase infusion, the hematuria rapidly cleared, and the patient had no untoward consequences from either the hematuria or lack of anticoagulation. Six patients were placed on warfarin for at least 6 months after thrombolytic therapy. The single case requir-

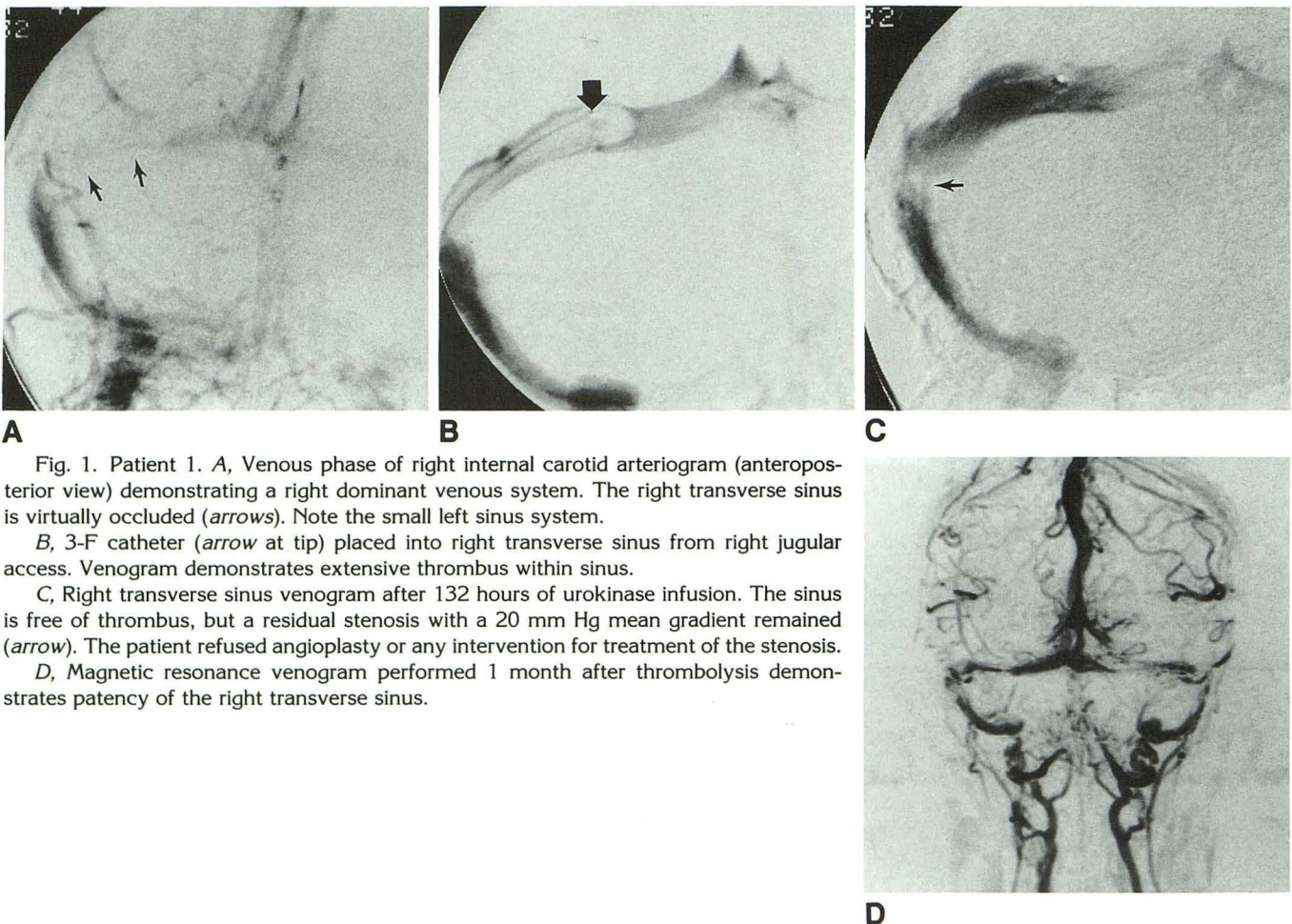


Fig. 1. Patient 1. A, Venous phase of right internal carotid arteriogram (anteroposterior view) demonstrating a right dominant venous system. The right transverse sinus is virtually occluded (arrows). Note the small left sinus system.

B, 3-F catheter (arrow at tip) placed into right transverse sinus from right jugular access. Venogram demonstrates extensive thrombus within sinus.

C, Right transverse sinus venogram after 132 hours of urokinase infusion. The sinus is free of thrombus, but a residual stenosis with a 20 mm Hg mean gradient remained (arrow). The patient refused angioplasty or any intervention for treatment of the stenosis.

D, Magnetic resonance venogram performed 1 month after thrombolysis demonstrates patency of the right transverse sinus.

Characteristics of patients with dural sinus thrombosis and results of urokinase infusion

Patient	Age (years)	Symptoms	Duration (weeks)	Site of Thrombosis	Urokinase Dose (1000 U)		Time for Lysis (hours)	Additional Treatment	Follow-Up (months)	Neurologic Condition after Lysis
					Bolus (15 min)	Infusion (per hour)				
1	52	Headache, papilledema	1	Superior sagittal sinus, right transverse sinus	...	20 to 80	244	None	37	Improved
2	71	Cranial nerves IX, X, XII	2	Left transverse sinus, sigmoid sinus, jugular bulb	100	40	88	Surgery for dural arteriovenous fistula	32	Improved
3	62	Lethargy, left hemiparesis	24	Left transverse sinus	...	60 to 150	147	None	29	Improved
4	40	Lethargy, right hemiparesis	1	Superior sagittal sinus, left transverse sinus	40	80	238	None	20	Healthy
5	32	Headache, papilledema	2	Right transverse sinus	...	80 to 150	165	None	11	Improved
6	25	Headache, papilledema	8	Left transverse sinus	...	80	144	Percutaneous angioplasty	11	Healthy
7	34	Headache, papilledema	6	Left transverse sinus	250	100 to 150	116	Clot maceration	8	Improved

Note.—Condition refers to neurologic status after thrombolysis compared with the patient's condition before thrombolysis.

ing surgical repair of a dural arteriovenous fistula was not anticoagulated long-term (Table, patient 2).

Patient follow-up was based on clinical condition and noninvasive imaging studies. All patients were followed by telephone interviews and clinical visits at intervals depending on the clinical situation.

Results

The results are summarized in the Table. Complete thrombolysis was defined as antegrade blood flow with no angiographic demonstration of residual thrombus. Complete thrombolysis occurred in all seven patients at an average of 163 hours. One patient was infused for 82 hours from the femoral venous access and an infection developed at the groin site (Table, patient 1). Thrombolysis was discontinued at that point, and the patient was left on anticoagulation for a 10-day course of antibiotics. Subsequently, based on the patient's clinical condition, thrombolysis was resumed for an additional 162 hours (total time to thrombolysis 244 hours). Four patients required no further therapy except anticoagulation; one of these had a residual stenosis that was not significant by pressure gradients (Table, patient 7) (Fig 2). Two patients had significant stenoses after infusion. The first patient received success-

ful percutaneous angioplasty of a left transverse sinus stenosis (Table, patient 6). The second patient refused further surgical or percutaneous treatment of a right transverse sinus stenosis (Table, patient 5) (Fig 1). The final patient required surgical correction of a dural arteriovenous fistula which was uncovered during thrombolysis and was probably the cause of the thrombosis (Table, patient 2).

Clinically, all patients were either healthy (neurologic exam and level of function equal to predural sinus thrombosis) or improved (neurologic exam and level of function better than in thrombosed state but not equal to predural sinus thrombosis). No patients were unimproved or of a worsened neurologic condition from thrombolysis. Of the 4 patients with papilledema, all had improved at ophthalmologic examination after thrombolysis, and three of the four continued to improve. All patients with focal neurologic deficits improved by physical examination. All patients reported complete or almost complete resolution of headaches. One patient initially had improvement in headache symptoms and papilledema, but after 12 months her symptoms and findings had not improved further. Follow-up studies revealed worsening white matter abnormality despite transverse sinus patency. Eventual biopsy

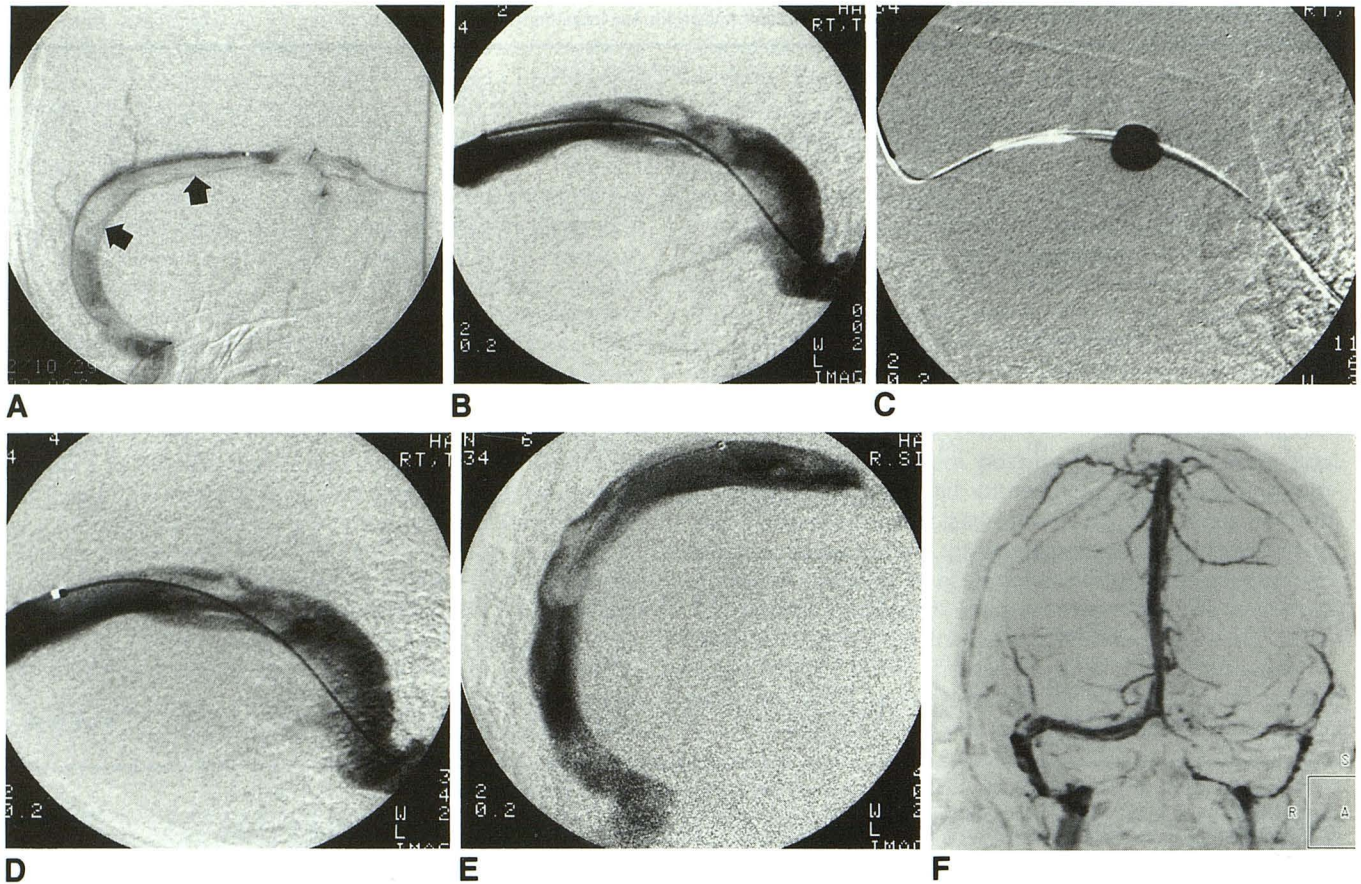


Fig. 2. Patient 7. A, Venogram (anteroposterior view) of the right transverse sinus showing extensive thrombus (*arrows*). Filling of some small cortical veins is also noted.

B, Venogram (lateral view) of right transverse sinus after approximately 73 hours of urokinase. Thrombus has decreased since commencing thrombolysis, but there has been no change over past 24 hours.

C, A 5-F angiographic balloon catheter was placed over a 0.021-inch guide wire, slowly inflated, and gently pulled back in an attempt to macerate the thrombus. Balloon is shown inflated with contrast.

D, Venogram of right transverse sinus after balloon inflation. There is very little change in appearance of the thrombus; however, mean pressure gradient across this area was only 4 mm Hg. This probably represented angioplasty effect on a residual stenosis rather than true clot maceration.

E, Final venogram after 116 hours of urokinase infusion showing some residual stenosis within the transverse sinus, but with marked improvement over prethrombolysis state. Flow within the sinus is excellent without filling of cortical veins.

F, Magnetic resonance venogram performed 1 month after thrombolysis. Right transverse sinus is patent with only some residual loss of signal at the site of prior thrombosis. Also note the small left transverse sinus system. The patient has had significant improvement in symptoms.

revealed astrocytoma for which she is currently undergoing treatment.

The site of thrombosis, cause of thrombosis, or degree of clinical symptoms did not correlate with the dose of urokinase, time to thrombolysis, or clinical success. The duration of dural sinus thrombosis averaged 6 weeks, but two patients had more chronic processes of 8 and 24 weeks. However, time to thrombolysis did not seem to vary with the length of symptoms (assumed length of time of thrombosis).

Only two complications occurred: a groin infection, which caused discontinuation of throm-

bolysis for 10 days, and hematuria, which caused discontinuation of anticoagulation during thrombolysis. The infection cleared completely after treatment with appropriate antibiotics. The hematuria cleared after discontinuation of the heparin and did not recur during long-term anticoagulation, which was begun after the completion of thrombolysis.

Discussion

The most common clinical features of dural sinus thrombosis are a reflection of intracranial hypertension and most commonly include head-

ache and papilledema (16). Other presenting symptoms may include seizures, focal neurologic deficits, and mental status changes ranging from mild to comatose (17). Unfortunately, there is often no clear clinical picture of thrombosis.

Medical and surgical treatments have been applied to dural sinus thrombosis. Medical treatment is probably the best initial therapy. Intracranial pressure can be lowered by controlling edema with the use of steroids. The mainstay of medical therapy at this point appears to be anticoagulation. Although some isolated reports have demonstrated poor results, most believe that heparinization should be the initial therapy depending on the patient's condition (18). All of the patients in our series were given a trial of anticoagulation before thrombolysis. Surgical treatment, although reported, has not been widely applied. Thrombectomy has been performed and has been advocated by some (19). Bypass has even been successfully performed (20). The elevated intracranial pressures have been controlled using drainage of cerebrospinal fluid and pharmacologically induced coma (21). Treatment with direct infusion of thrombolytic agents offers an option as the next step after medical treatment and before more aggressive surgical measures. However, specific criteria for patient selection are still very unclear, and there are certainly fears concerning the use of thrombolytics in the dural sinuses.

Specific patient selection criteria are difficult to determine because the reported outcomes in patients with dural sinus thrombosis have been varied. Older angiographic series state that mortality varied from 30% to 50% (22, 23). It appears to be true that extension into cerebral veins is a poor prognostic sign (24). However, in more recent series, 71% of the patients with cerebral venous thrombosis affecting the dural sinuses made a complete recovery (16). The same series noted, however, that there still existed a 10% mortality rate. The authors also concluded that although in general the clinical presentation seemed to influence the outcome, patients with focal neurologic signs were less apt to have a complete recovery. However, for a given patient the outcome was unpredictable. It seems logical and was our premise, therefore, to proceed with more aggressive treatment in patients with worsening clinical symptoms.

Early reports concerning the use of thrombolytics were not encouraging (18, 25). The main concern with anticoagulation and thrombolysis

has been the fear of hemorrhage (26). For that reason, most discussions concerning intracranial thrombolysis center around the choice of thrombolytic agent, its appropriate dosage, and methods to shorten the length of time to complete thrombolysis.

Urokinase was the drug of first choice in this study, mainly because of its success and our experience in the peripheral vascular system (13, 27). Therefore we were most comfortable with this agent. However, animal reports have stated the efficacy of tissue plasminogen activator, and human trials have been performed for arterial thrombosis in the vasculature of the central nervous system (28, 29).

Three different loading doses were given in the three patients who received loading doses of urokinase. These variations are certainly a reflection of the newness of the technique and our willingness to increase the loading doses on subsequent cases after more experience was gained. Likewise, for long-term infusion, our initial doses of urokinase were lower than those used later. The initial doses of 20 000 and 40 000 U/h, although successful, are certainly less than can be safely tolerated in most cases. It seems from this small series that doses of 100 000 to 150 000 U/h can be well tolerated for long-term infusion. There are also reports of successful intravenous administration of urokinase for dural sinus thrombosis, also obviously resulting in systemic doses for longer time intervals (10). However, as is known from peripheral data, hemorrhage may be difficult to correlate well with dosage (30). Doses should always be kept as low as possible to achieve a successful outcome safely. In theory, placement of the thrombolytic agent directly into the thrombus should promote faster thrombolysis with less systemic dosage. Therefore, the hope has been that this will decrease the chances of hemorrhagic complications. Certainly in this series no hemorrhagic complications were encountered, but the methods of study and the small number of patients do not allow statistical conclusions to be reached. However, until agents are available with better fibrin-binding specificity, this series does show empirically that long-term infusion of thrombolytics can be safely performed in selected cases of dural sinus thrombosis without bleeding complications.

The time required for thrombolysis was quite lengthy in this series (average 171 hours, range 88 to 244). This is certainly in part a reflection of lower urokinase doses as discussed above. How-

ever, the length of time of infusion also may reflect the extensive degree of thrombosis (in order to warrant thrombolysis) and the underlying causes. Two patients had significant stenoses after thrombolysis, necessitating additional intervention (which was refused by one); one patient had an underlying dural arteriovenous fistula. Recently, time to thrombolysis has reportedly been reduced by larger initial boluses which are often given in a pulse-spray technique via side-hole catheters (31). Based on reports of the peripheral arterial system and a report of the dural sinuses, we did initially give one patient a bolus of urokinase in this pulse-spray manner (12, 32). However, this did not result in any greater immediate results or shorter eventual time to thrombolysis. Other reports in the literature have noted shortened time to thrombolysis after clot maceration which, presumably serves to increase the available surface area to the thrombolytic agent (33, 34). We attempted this in one patient after 73 hours of thrombolysis, the last 24 hours having resulted in no substantial change by venography. Improvement (Fig 2) was demonstrated only radiographically by improvement in flow and by decreased pressure gradient. Further infusion of urokinase did not result in any significant change; this area in fact probably represented residual stenosis rather than residual thrombus, although this cannot be determined with absolute certainty. Although mechanical disruption of thrombus may have a role, it should be clear that care must be exercised whenever catheter manipulations are performed in the dural sinuses because perforation could be catastrophic. In addition, manipulations in the dural sinuses whether for clot maceration or angioplasty can be very painful, necessitating adequate sedation, which we did use. Certainly, further work needs to be done before the optimal combination of factors to achieve expedient thrombolysis is known.

In one patient, an infection developed at the femoral vein access site and cleared after appropriate antibiotic therapy. This patient was our first; after this case preferential access has changed to the internal jugular vein. This however was not based solely on the single complication. The jugular puncture allows the patient more mobility and catheter manipulation is often much easier when the site of access is closer to the eventual site of thrombolysis.

All patients in our series were easily monitored by neurologic exam. However, it must be noted that for any deterioration in neurologic status,

immediate computed tomographic scanning should be obtained, probably after immediately stopping urokinase until the diagnosis of hemorrhage can be eliminated. In addition, if patients cannot be reliably monitored by neurologic exam, computed tomographic scans at given intervals, probably before designated catheter checks, should be obtained.

The results of this study demonstrate that urokinase can be a safe and efficacious treatment for dural sinus thrombosis; we hope this study will provide an impetus for further research. As more data are collected, the criteria for treatment will become better defined. It should be clear however that dural sinus thrombosis alone is not an indication for thrombolytic therapy, particularly if the diagnosis was made by easily accessible, noninvasive imaging studies obtained because of minimal symptoms. Thrombolytic therapy should be a consideration when a patient fails to respond to more conservative medical treatment; therefore the indications for thrombolytic therapy over medical therapy should be based on the patient's deteriorating clinical condition in the absence of any evidence of recent intracranial hemorrhage. However, even hemorrhage may not be an absolute contraindication for local urokinase infusion based on an individualized approach, given a particular patient's clinical condition and anticipated prognosis with the alternative forms of therapy available (9).

References

1. McLean BN. Dural sinus thrombosis. *Br J Hosp Med* 1991;45:226-231
2. Ehlers H, Courville CB. Thrombosis of internal cerebral veins in infancy and childhood: review of the literature and report of five cases. *J Pediatr* 1936;8:600-623
3. Hulcelle PJ, Dooms GC, Mathurin P, Cornelis G. MRI assessment of unsuspected dural sinus thrombosis. *Neuroradiology* 1989;31:217-221
4. Virapongse C, Cazenave C, Quisling R, Sarwar M, Hunter S. The empty delta sign: frequency and significance in 76 cases of dural sinus thrombosis. *Radiology* 1987;162:779-785
5. Thron A, Wessel K, Linden D, Schroth G, Dichgans J. Superior sagittal sinus thrombosis: neuroradiological evaluation and clinical findings. *J Neurol* 1986;233:283-288
6. Tsuruda JS, Shimakawa A, Pelc NJ, Saloner D. Dural sinus occlusion: evaluation with phase-sensitive gradient-echo MR imaging. *AJNR Am J Neuroradiol* 1991;12:481-488
7. Persson L, Lilja A. Extensive dural sinus thrombosis treated by surgical removal and local streptokinase infusion. *Neurosurgery* 1990;26:117-121
8. Eskridge JM, Wessbecher FW. Thrombolysis for superior sagittal sinus thrombosis. *J Vasc Interv Radiol* 1991;2:89-94
9. Higashida RT, Helmer E, Halbach VV, Hieshima GB. Direct thrombolytic therapy for superior sagittal sinus thrombosis. *AJNR Am J Neuroradiol* 1989;10:S4-S6

10. Di Rocco C, Iannelli A, Leone G, Moschini M, Valori VM. Heparin-urokinase treatment in aseptic dural sinus thrombosis. *Arch Neurol* 1981;38:431-435
11. Barnwell SL, Higashida RT, Halbach VV, Dowd CF, Hieshima GB. Direct endovascular thrombolytic therapy for dural sinus thrombosis. *Neurosurgery* 1991;28:135-142
12. Tsai FY, Higashida RT, Matovich V, Alfieri K. Acute thrombosis of the intracranial dural sinus: direct thrombolytic treatment. *AJNR Am J Neuroradiol* 1992;13:1137-1141
13. Cragg AH, Smith TP, Corson JD, et al. Two urokinase regimens in native arterial and graft occlusions: initial results of a prospective, randomized clinical trial. *Radiology* 1991;178:681-686
14. McNamara, TO, Fischer JR. Thrombolysis of peripheral arterial and graft occlusions: improved results using high-dose urokinase. *AJR Am J Roentgenol* 1985;144:769-775
15. Sullivan KL, Gardiner GA, Shapiro MJ, Bonn J, Levin DC. Acceleration of thrombolysis with a high-dose transthorbus bolus technique. *Radiology* 1989;173:805-808
16. Bousser M-G, Chiras J, Bories J, Castaigne P. Cerebral venous thrombosis: a review of 38 cases. *Stroke* 1985;16:199-213
17. Angelov A. Intracranial venous thrombosis in relation to pregnancy and delivery. *Pathol Res Pract* 1989;185:843-847
18. Gettelfinger DM, Kokmen E. Superior sagittal sinus thrombosis. *Arch Neurol* 1977;34:2-6
19. Estanol B, Rodriguez A, Conte G, Aleman JM, Loyo M, Pizzuto J. Intracranial venous thrombosis in young women. *Stroke* 1979;10:680-684
20. Sindou M, Mercier P, Bokor J, Brunon J. Bilateral thrombosis of the transverse sinuses: microsurgical revascularization with venous bypass. *Surg Neurol* 1980;13:215-220
21. Hanley DF, Feldman E, Borel CO, Rosenbaum AE, Goldberg AL. Treatment of sagittal sinus thrombosis associated with cerebral hemorrhage and intracranial hypertension. *Stroke* 1988;19:903-909
22. Krayenbuhl HA. Cerebral venous and sinus thrombosis. *Clin Neurosurg* 1967;14:1-24
23. Weber G. Zerebrale venen und sinus thrombosen. *Schweiz Arch* 1958;82:320-344
24. Kalbag RM, Woolf AL. Radiology, prognosis, pathology, and treatment. In: *Cerebral venous thrombosis: with special reference to primary aseptic thrombosis*. London: Oxford University Press, 1967:237-250
25. Rousseaux P, Bernard MH, Scherpereel B, Guyot JF. Thrombose des sinus veineux intra-craniens (a propos de 22 cas). *Neurochirurgie* 1978;24:197-203
26. Schmidek HH, Auer LM, Kapp JP. The cerebral venous system. *Neurosurgery* 1985;17:663-678
27. Lammer J, Pilger E, Neumayer K, Schreyer H. Intraarterial fibrinolysis: Long-term results. *Radiology* 1986;161:159-163
28. Alexander LF, Yamamoto Y, Ayoubi S, Al-Mefty O, Smith RR. Efficacy of tissue plasminogen activator in the lysis of thrombosis of the cerebral venous sinus. *Neurosurgery* 1990;26:559-564
29. Chehraz BB, Seiber JA, Hein L, Brock J, Kissel P. Differential effect of recombinant tissue plasminogen activator-induced thrombolysis in the central nervous system and systemic arteries. *Neurosurgery* 1991;28:364-369
30. Marder VJ, Sherry S. Thrombolytic therapy: current status. *N Engl J Med* 1988;318:1585-1595
31. Bookstein JJ, Fellmeth B, Roberts A, Valji K, Davis G, Machado T. Pulse-spray pharmacomechanical thrombolysis: preliminary clinical results. *AJR Am J Roentgenol* 1989;122:1097-1100
32. Valji K, Roberts AC, Davis GB, Bookstein JJ. Pulsed-spray thrombolysis of arterial and bypass graft occlusions. *AJR Am J Roentgenol* 1991;156:617-621
33. Bookstein JJ, Saldinger E. Accelerated thrombolysis: in vitro evaluation of agents and methods of administration. *Invest Radiol* 1985;20:731-735
34. Davis GB, Dowd CF, Bookstein JJ, Maroney TP, Lang EV, Halasz N. Thrombosed dialysis grafts: efficacy of intrathrombotic deposition of concentrated urokinase, clot maceration, and angioplasty. *AJR Am J Roentgenol* 1987;149:177-181

Received February 9, 1993; accepted pending revision April 1993; revised August 9

From the Department of Radiology, Stanford University Medical Center, Stanford, Calif.

Address reprint requests to Michael P. Marks, MD, Department of Radiology, Stanford University Medical Center, Stanford, CA 94305-5088.

© 1994 American Society of Neuroradiology