

Are your **MRI contrast agents** cost-effective?

Learn more about generic **Gadolinium-Based Contrast Agents**.



FRESENIUS
KABI

caring for life

AJNR

A pain in the ear: the radiology of otalgia.

J L Weissman

AJNR Am J Neuroradiol 1997, 18 (9) 1641-1651

<http://www.ajnr.org/content/18/9/1641.citation>

This information is current as
of April 19, 2024.

A Pain in the Ear: The Radiology of Otolgia

Jane L. Weissman, *Departments of Radiology and Otolaryngology, University of Pittsburgh (Pa) Medical Center*

Otolgia is ear pain. Ear disease causes primary otalgia. Secondary (referred) otalgia is referred to the ear from disease in structures remote from the ear. Otolgia, especially referred otalgia, can be a diagnostic challenge.

The radiologic approach to a patient with otalgia relies on the physical examination. If the otoscopic findings are abnormal, the computed tomographic (CT) or magnetic resonance (MR) study focuses on the temporal bone. (The appropriate radiologic study depends on the disease.) The physical examination for ear pain includes the ear (auricle and temporal bone) and structures that are potential sources of referred pain. Imaging studies can show clinically occult temporal bone disease as well as sources of referred pain in the nasopharynx, retropharynx, paranasal sinuses and nasal cavity, temporomandibular joint (TMJ), parotid gland, oropharynx and oral cavity (including teeth), hypopharynx and larynx, thyroid gland, esophagus, and trachea. Tailoring a CT or MR study to evaluate primary or referred otalgia requires an understanding of the (admittedly complex) anatomy of ear pain.

Sensory Innervation

Briefly, sensation from the ear and adjacent structures travels along four cranial nerves (V, VII, IX, and X), the upper cervical plexus, and (possibly) cervical sympathetic fibers (1–5). These nerves mediate primary otalgia (Fig 1A and B).

Referred pain is the subjective experience of pain in a structure remote from the disease. Pain is referred along routes of shared innervation. In other words, referred pain (secondary otalgia) is referred to the ear from distant structures that receive sensory innervation from the same four cranial nerves as the ear itself: the upper and lower aerodigestive tracts, TMJs, teeth, salivary

glands, and thyroid gland (2, 4, 5) (Fig 1C). *Synalgia* and *telalgia* are rarely used synonyms for referred pain (6).

Pathways Mediating Primary Otolgia

The skin of the ear is an interface between branchial and postbranchial innervation. Therefore, sensory innervation of the external ear is mediated by both cutaneous and cranial nerves (5). However, innervation is variable, and the map of the sensory innervation of the ear remains imprecise (5).

Trigeminal Nerve.—The mandibular division of the trigeminal nerve (V3) gives off the auriculotemporal nerve (1, 2, 7), which runs with the superficial temporal artery and vein (7). The auriculotemporal nerve receives sensory input from the anterior portions of the outer ear: the anterior auricle (pinna), the tragus, the anterior and superior walls of the external auditory canal (EAC), and the lateral (EAC) surface of the tympanic membrane (TM) (1, 2, 4, 5, 7).

Facial Nerve.—The facial nerve is primarily a motor nerve. Its small sensory branches include the nervus intermedius of Wrisberg, the posterior auricular nerve, and the greater superficial petrosal nerve (GSPN). The nervus intermedius carries sensation from a small part of the medial EAC (8); its branches include the posterior auricular and greater superficial petrosal nerves. The posterior auricular branch carries sensation from the posterior wall of the EAC, the posterior TM, and the skin behind the pinna (1, 2, 5, 7). The GSPN mediates referred otalgia, and is discussed below.

Glossopharyngeal Nerve.—The tympanic branch of the glossopharyngeal nerve (Jacobson's nerve) carries sensation from the medial (middle ear) surface of the TM (7), the middle ear mucosa, and the upper eustachian tube (4). Jacobson's nerve anastomoses in the tympanic

Address reprint requests to Jane L. Weissman, MD, Department of Radiology, Room D-132 PUH, University of Pittsburgh Medical Center, 200 Lothrop St, Pittsburgh, PA 15213.

Index terms: Ear, diseases; Special reports

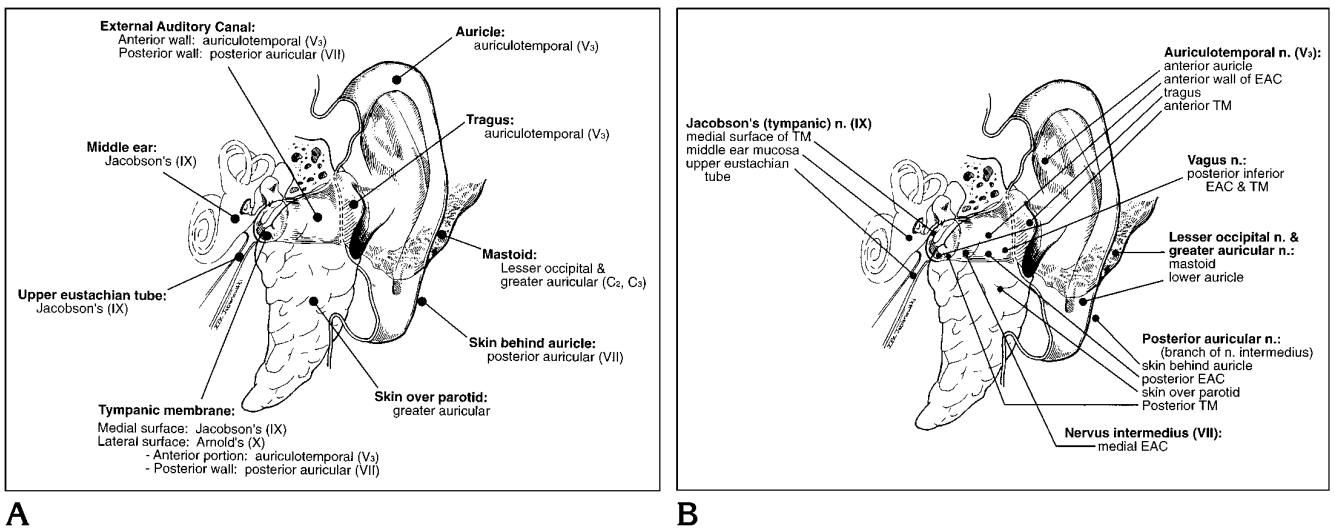
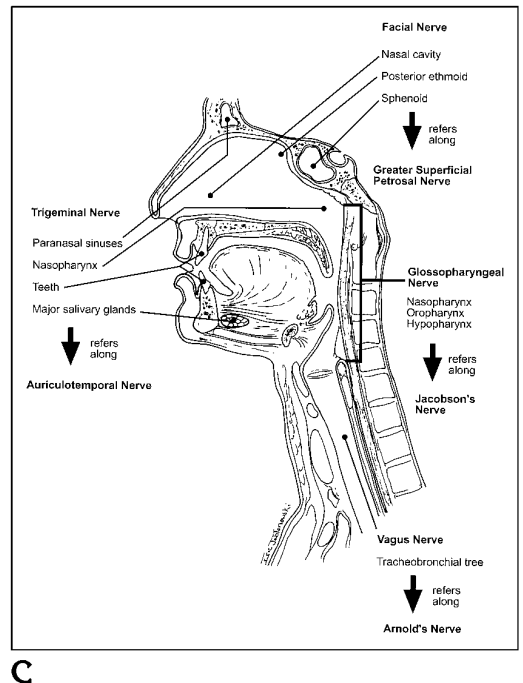


Fig 1. Sensory innervation of the ear and surrounding structures: primary and secondary otalgia.
 A, Primary otalgia: sensory innervation by location.
 B, Primary otalgia: sensory innervation by nerve.
 C, Secondary (referred) otalgia: the structures that refer pain to the ear, and the pathways of referred pain.

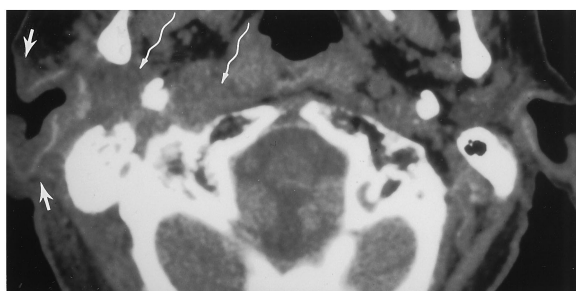


plexus of the middle ear. The tympanic plexus also contains sympathetic and parasympathetic fibers (5, 9).

Vagus Nerve.—Sensory input from the posterior-inferior ear travels along the auricular branch of the vagus nerve (Arnold's nerve). Arnold's nerve arises from the superior (jugular) ganglion of the vagus (5), and can receive fibers from the facial and glossopharyngeal nerves as well as the vagus (1, 5). Arnold's nerve receives input from the auricle and from the inferior and posterior portions of the EAC and TM (5).

Cervical Nerves.—The cervical plexus receives cutaneous innervation from the neck (1). C2 and C3 contribute to the greater auricular and lesser occipital nerves. The greater auricular nerve runs with the external jugular vein to supply the skin over the parotid gland (4), the lower (1, 9) and superior-medial pinna (5), and the mastoid (2, 5). The lesser occipital nerve innervates the skin over the mastoid (7) and behind the ear (1, 4).

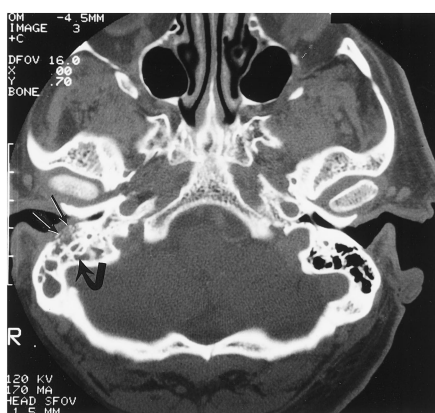
Sympathetic Nerves.—The sympathetic plexus accompanies the internal carotid artery



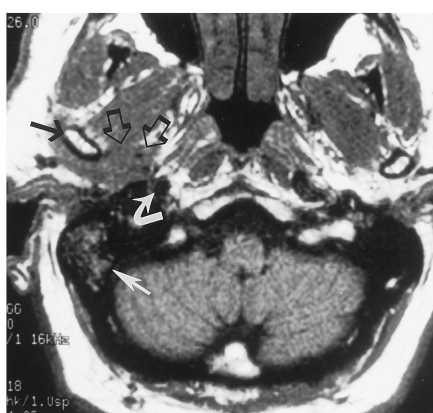
A

be edema or granulation tissue. There is also a sympathetic mastoid effusion (straight white arrow).

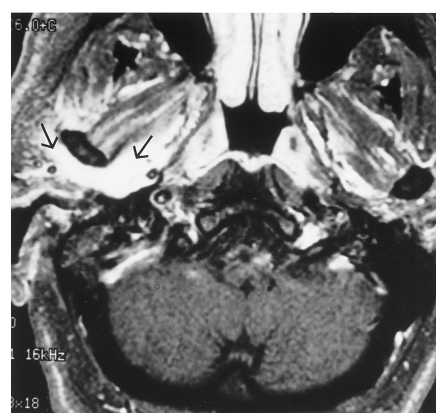D, Axial contrast-enhanced T1-weighted MR image (625/20/1) with fat suppression at a slightly higher level than C shows hyperintense signal from the soft tissue (arrows).



B



C



D

Fig 2. Malignant otitis externa.

A, Axial CT scan (soft-tissue algorithm) shows infiltration of the fat around the right internal carotid artery and internal jugular vein and in the stylohyoid tunnel (wavy arrows). Compare to the normal left side. The pinna is edematous (straight arrows). This image was obtained at a level below the EAC.

B, Axial CT image (bone algorithm) shows erosion of the mastoid cortex (arrows) along the posterior wall of the EAC. The mastoid air cells are opacified (curved arrow).

C, Axial T1-weighted MR image (625/20/1 [repetition time/echo time/excitations]) below the EAC shows infiltration of the fat beneath the skull base (open arrows), around the mandibular condyle (black arrow), and partially surrounding the internal carotid artery (curved arrow). This could

through the upper neck and skull base. Sympathetic fibers join Jacobson's nerve in the tympanic plexus of the middle ear (7). It is not clear whether and how these autonomic fibers transmit pain (9).

Pathways Mediating Referred Otalgia

Trigeminal Nerve.—Diseases of the mouth and face are the most frequent sources of referred otalgia, and the trigeminal nerve is the most frequent pathway for referred otalgia (2). The central pathway involved is most likely the spinal tract nucleus of the trigeminal nerve (3).

The maxillary and mandibular divisions of the trigeminal nerve receive sensory innervation from the nasopharynx, paranasal sinuses, upper and lower teeth, and three pairs of major salivary glands, most notably (for referred otalgia) the parotid gland (5, 9). The mandibular division supplies both motor and sensory innervation to the muscles of mastication and the tensor tympani and tensor veli palatini muscles (2). Pain from all of these structures is referred

to the ear along the auriculotemporal branch of the trigeminal nerve.

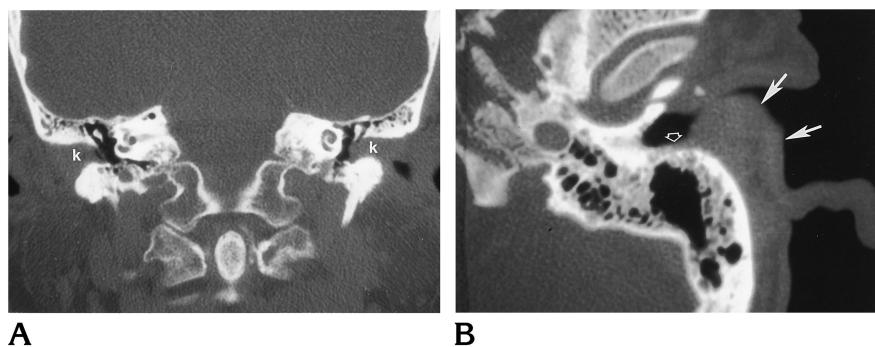
Facial Nerve.—The GSPN arises from the geniculate ganglion of the facial nerve. Sympathetic fibers that accompany the internal carotid artery join the GSPN to form the vidian nerve (the nerve of the pterygoid canal). The vidian nerve enters the pterygopalatine fossa, where it synapses in the sphenopalatine ganglion (5, 7). The vidian nerve innervates the mucosa of the nasal cavity, the posterior ethmoidal sinus, and the sphenoidal sinus (4), but the exact distribution of sensory innervation by the GSPN is not known (5). The nervus intermedius, which contributes fibers to the GSPN (1), is the presumed path along which pain from the nose and sinuses can be referred to the ear. (The nervus intermedius also carries sensation from the EAC and so is also a pathway of primary otalgia.)

Glossopharyngeal Nerve.—The glossopharyngeal nerve receives sensory input from the nasopharynx down to the hypopharynx (4, 7). Pain from the anterior eustachian tube, the soft

Fig 3. CT images (bone algorithms) of EAC masses.

A, Coronal image of a young patient with keratosis obturans shows soft tissue (*k*) filling both EACs. There is no erosion of the canal walls, but the right EAC appears to be expanded.

B, Axial image of a squamous cell carcinoma (*arrows*) that has eroded the posterior wall of the EAC (*open arrow*).



palate (4), the posterior third of the tongue or tongue base (1, 4, 7), the pharyngeal tonsils (7), and the lateral wall of the pharynx (1, 4, 7) is referred to the ear along the tympanic branch of the glossopharyngeal (Jacobson's) nerve (4).

Vagus Nerve.—The vagus nerve carries sensory innervation from the lower aerodigestive tract (1, 7). Sensation from the mucosa of the valleculae, piriform sinuses, and larynx travels along the internal branch of the superior laryngeal nerve (1, 10). The recurrent laryngeal nerve receives sensation from the cervical esophagus and trachea, besides supplying motor fibers to the intrinsic muscles of the larynx (1). The bronchial tree and lung refer pain along the bronchial branch of the vagus (3). Pain from structures innervated by the vagus is referred to the ear along the auricular branch of the vagus (Arnold's nerve) (4).

Sources of Primary Otalgia

Auricle, External Auditory Canal, and Tympanic Membrane

Diseases of the auricle (pinna), such as relapsing chondritis, frostbite, and burn (2, 11, 12), are apparent on clinical inspection and are not usually referred for radiologic studies. Auricle edema can be identified on studies obtained for other reasons (Fig 2A). Acute otitis externa ("swimmer's ear") and an EAC carbuncle or furuncle (folliculitis) are among the most frequent causes of earache (13). Foreign bodies, eczema, and fungal infections of the EAC also cause pain (2, 12). None of these routinely requires radiologic studies. Bullous myringitis is a viral infection of the tympanic membrane that

can cause excruciating ear pain, is unilateral or bilateral, and can be accompanied by a ("sympathetic") middle ear effusion (11). Bullous myringitis is diagnosed and treated clinically.

Malignant external otitis (MEO), or malignant external otitis, is a virulent, necrotizing infection, not (despite the name) a neoplasm (14, 15) (Fig 2). This potentially fatal pseudomonas osteomyelitis of the skull base occurs in patients immunosuppressed by tumor, drugs (chemotherapy, steroids), and diabetes mellitus (11). The clinical findings are severe ear pain that wakes the patient from sleep, ear discharge, and an elevated erythrocyte sedimentation rate (14). Both CT and MR studies delineate the extent of disease, including inflammation in the mastoid and middle ear, around the eustachian tube, and beneath the skull base (16) (Fig 2B–D). CT bone algorithms show EAC erosion (Fig 2B). These studies also document regression of inflammation after treatment (15, 16).

In keratosis obturans, desquamated keratin accumulates in the EAC, causing severe ear pain (14). The process is often bilateral and is usually encountered in young people who might also have bronchiectasis and sinusitis (14). CT scans can show concentric enlargement of the EAC (Fig 3A). An EAC cholesteatoma is usually unilateral, occurs in older patients, and causes dull pain unlike the severe pain of MEO (14). The localized EAC erosion of a cholesteatoma (Fig 3B) can appear identical to the erosion of a squamous cell carcinoma or another, even more rare, benign or malignant EAC neoplasm (15). Biopsy is necessary for diagnosis. CT studies define the extent of bone erosion; CT and MR studies delineate the soft tissue component.

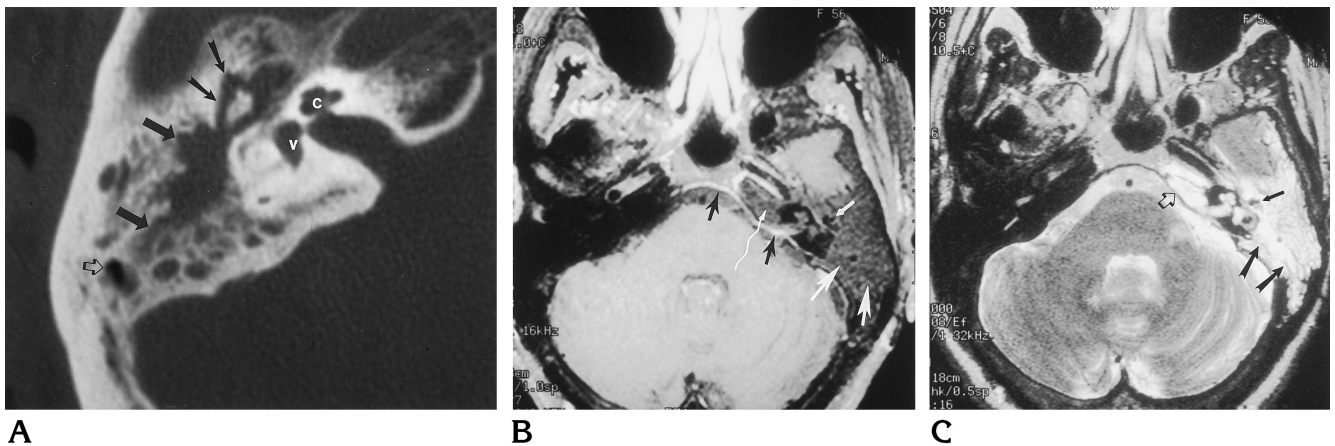


Fig 4. Mastoid and middle ear effusions on axial images.

A, CT image (bone algorithm) shows opacification of the middle ear (*thin arrows*), the mastoid antrum (*thick arrows*), and the peripheral mastoid air cells (*open arrow*). There is some residual aeration of one mastoid air cell. C indicates cochlea; V, vestibule.

B, T1-weighted contrast-enhanced MR image (525/27/2) shows stippled soft tissue throughout the left mastoid (*large white arrows*). This is fluid in the mastoid air cells. The petrous apex air cells also contain fluid (*wavy arrow*). Fluid in the middle ear silhouettes the signal void of the ossicles (*small arrow*). The meningeal enhancement in the posterior fossa and internal auditory canal (*black arrows*) reflects prior surgery. The effusion fluid does not enhance.

C, T2-weighted MR image (4000/108 effective/1) shows the hyperintense effusion fluid throughout mastoid air cells (*large arrows*) and petrous apex air cells (*open arrow*) and silhouetting the ossicles in the middle ear (*small arrow*).

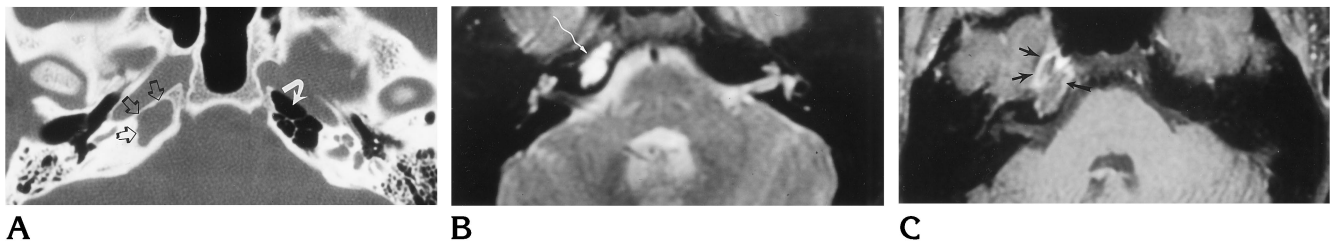


Fig 5. Petrous apex mucocele on axial images.

A, CT scan (bone algorithm) shows a solitary, opacified petrous apex air cell (*open arrows*) on the right side. The pneumatized left petrous apex contains many small, clear air cells (*curved arrow*). It is not possible to determine whether the findings on the right represent a single, expanded air cell or many smaller air cells that became confluent because the septations were destroyed.

B, T2-weighted MR image (4000/80/2) shows the high signal of the obstructed air cell on the right (*arrow*). The signal void in the left petrous apex could be pneumatized air cells or cortical bone.

C, T1-weighted contrast-enhanced MR image (625/25/1) shows that the mucosa lining the air cell enhances intensely (*arrows*) and the mucocele contents are slightly hyperintense to cerebrospinal fluid.

Middle Ear and Mastoid

Acute otitis media and acute mastoiditis are frequent causes of otalgia (12). These are recognized and treated clinically. Chronic otitis media and chronic mastoid disease are usually not painful (12), and can be identified as incidental findings on studies done for other reasons (Fig 4). Usually, pain in the setting of chronic otitis media is a clue to a complication such as petrous apicitis, dural venous sinus thrombosis, and temporal lobe or cerebellar abscess (2, 12). In children with "eustachian tube dysfunction," chronic serous otitis media, which is painful even in the absence of superimposed acute infection, develops (13).

Disease in a petrous apex air cell is a rare cause of pain. An obstructed, expanded air cell is a mucocele (Fig 5A–C); this can be hemorrhagic (cholesterol cyst) or can become infected. A cholesteatoma can also expand the petrous apex.

Gradenigo syndrome, or painful ophthalmoplegia (13, 17), is abducens dysfunction, pain in the distribution of the trigeminal nerve, and suppurative otitis media (17). The middle ear infection spreads through air cells or nonpneumatized (diploic) bone to the petrous apex, and from there to the gasserian ganglion in Meckel's cave and the abducens nerve in Dorello's canal (17). Imaging studies play an important role in

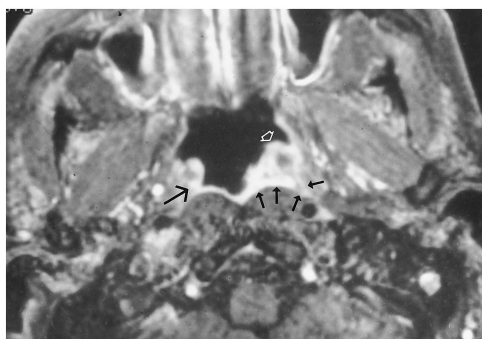
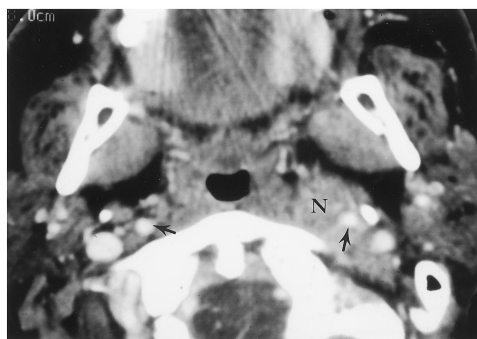
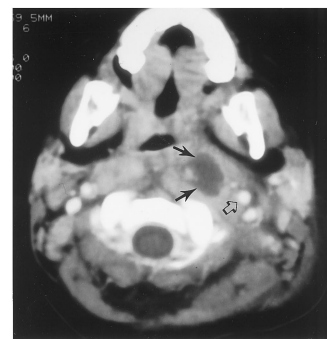


Fig 6. Nasopharyngeal squamous cell carcinoma. Axial T1-weighted contrast-enhanced MR image (500/25/1) with fat suppression shows a small tumor infiltrating around the left torus tubarius (*open arrow*) and extending into the fossa of Rosenmuller (*small arrows*). There is normal enhancing mucosa in the right fossa (*large arrow*).



A



B

Fig 7. Retropharyngeal adenopathy on axial contrast-enhanced CT images.

A, There is an enlarged, heterogeneous retropharyngeal lymph node (*N*). This was metastatic squamous cell carcinoma. Retropharyngeal nodes (nodes of Rouviere) are medial to the internal carotid artery (*arrows*).

B, This necrotic retropharyngeal mass (*solid arrows*) medial to the internal carotid artery (*open arrow*) was a retropharyngeal abscess.

diagnosis and subsequent treatment of these patients.

Tumors of the middle ear are rare, and rarely cause otalgia. Fungal infection after mastoidectomy can cause pain and discharge from the mastoidectomy bowl (13).

Sources of Referred Otalgia

Nasopharynx and Retropharynx

The clinical manifestations of nasopharyngeal carcinoma depend on the location and extent of the primary tumor (18) (Fig 6). Otalgia is not a frequent presentation (13). More often, patients report hearing loss because the tumor, especially one in the fossa of Rosenmuller, obstructs eustachian tube drainage, causing a serous otitis media and a conductive hearing loss (14).

Disease of the retropharyngeal lymph nodes (nodes of Rouviere) presents with deep eye pain and occipital pain, but can cause otalgia. Such pain might be the first clue to metastatic tumor in these nodes (Fig 7A). Suppurative adenitis of a retropharyngeal node (a retropharyngeal abscess) causes fever, dyspnea, and dysphagia (Fig 7B). Clinically, the abscess is a fluctuant mass that creates a bulge under intact mucosa of the posterior pharyngeal wall (19).

Paranasal Sinuses and Nasal Cavity

Disease in the sinuses and nasal cavity causes otalgia referred along the GSPN (4) to

the geniculate ganglion (5). Both acute (viral and bacterial) sinusitis and chronic sinusitis can cause pain (4). A deviated nasal septum that touches or compresses a nasal turbinate is also believed to cause pain (8, 20) (Fig 8). Neoplasms are usually not painful unless they obstruct a sinus or invade adjacent structures (13).

Oropharynx and Oral Cavity

The oropharynx is the most frequent site of primary carcinoma of the upper aerodigestive tract (21). The oropharyngeal tumors that present with otalgia include squamous cell carcinoma of the base of the tongue (Fig 9) and of the palatine tonsil (22) (Fig 10A). Tumors of the base of the tongue are more rare than tumors of the oral tongue and have a worse prognosis, both because they are histologically high-grade tumors and because they tend to remain clinically silent until large and bulky (22).

The palatine (faucial) tonsils are lymphoid tissue covered by squamous epithelium. Each tonsil fills the tonsillar fossa between the anterior tonsillar pillar or arch (palatoglossus muscle) and the posterior tonsillar pillar or arch (palatopharyngeus muscle) (1). The two muscles and the interposed tonsil might not be identifiable as distinct structures on imaging studies; the term *tonsillar pillar* refers to the soft tissues flanking the airway at the level of the oral cavity and oropharynx (Fig 10).

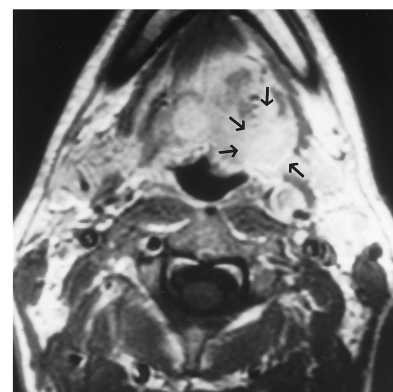
Nonneoplastic tonsil disease can present with

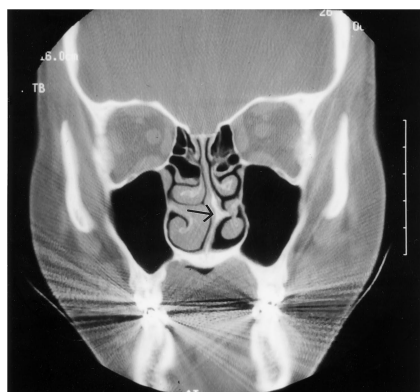
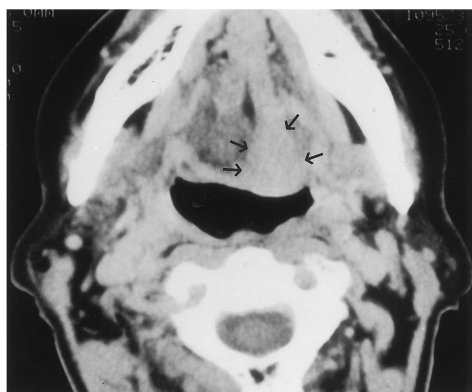
Fig 8. Coronal CT image (bone algorithm) shows a nasal septal spur (*arrow*) that touches the mucosa of the left inferior turbinate.

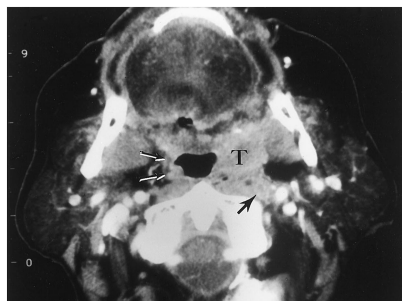

A

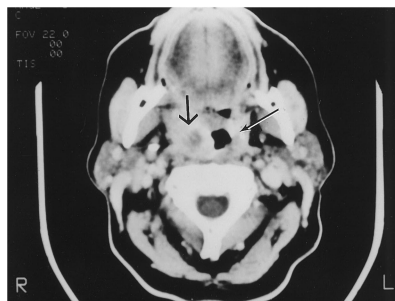


B

Fig 9. Squamous cell carcinoma of the base of tongue.
 A, Axial enhanced CT image shows the carcinoma (*arrows*) infiltrating the normal fat planes of the left base of the tongue.
 B, Axial contrast-enhanced T1-weighted MR image (650/25/1) with fat suppression shows the enhancing tumor infiltrating the left base of the tongue (*arrows*).



A



B

Fig 10. Disease in the pharyngeal tonsils on axial CT images.
 A, A heterogeneously enhancing squamous cell carcinoma (*T*) replaces the left tonsil and infiltrates into surrounding soft tissues. There is a small, necrotic retropharyngeal lymph node on the left (*arrow*). The normal right tonsillar pillar (*highlighted arrows*) is not very conspicuous in this older adult.
 B, A low-density mass with a thick, enhancing rim (*black arrow*) widens the right tonsillar pillar in a young patient with a peritonsillar abscess. In this case, the clinical information is especially important, because carcinoma and abscess can have a similar appearance. The individual components of the normal left tonsillar pillar (*highlighted arrow*) (the palatoglossus and palatopharyngeus muscles and the tonsil) cannot be identified as distinct structures.

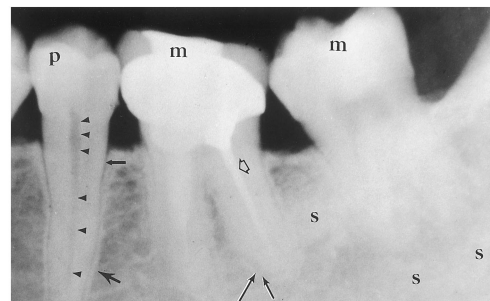


Fig 11. Periapical (dental) radiograph of the mandibular premolar (*p*) and two molars (*m*). The premolar has a normal lucent pulp chamber (*arrowheads*), lucent periodontal ligament (*small solid arrow*), and dense lamina dura (*larger arrow*). There is periapical sclerosis (*S*) around the roots of the molars and widening of the periodontal ligament (*highlighted arrows*). The root canal of the second molar is obliterated. The metallic material in the pulp canals of the first molar is from a root canal procedure (*open arrow*). These findings can also be seen on CT scans.

a sore throat and ear pain (2, 19). Acute tonsillitis is diagnosed by physical examination and cultures, not imaging. A quinsy tonsil (peritonsillar abscess) is a complication of untreated or inadequately treated tonsillitis (Fig 10B). Severe ear pain is one hallmark of a peritonsillar abscess. Pus usually collects between the tonsil and the anterior pillar (19). CT scans confirm the presence of an abscess that is amenable to surgical drainage.

Dental infections are a frequent cause (some say the most frequent cause) of referred otalgia

(2, 20, 23). Pain from molars, especially mandibular molars, radiates to the ear (3, 7).

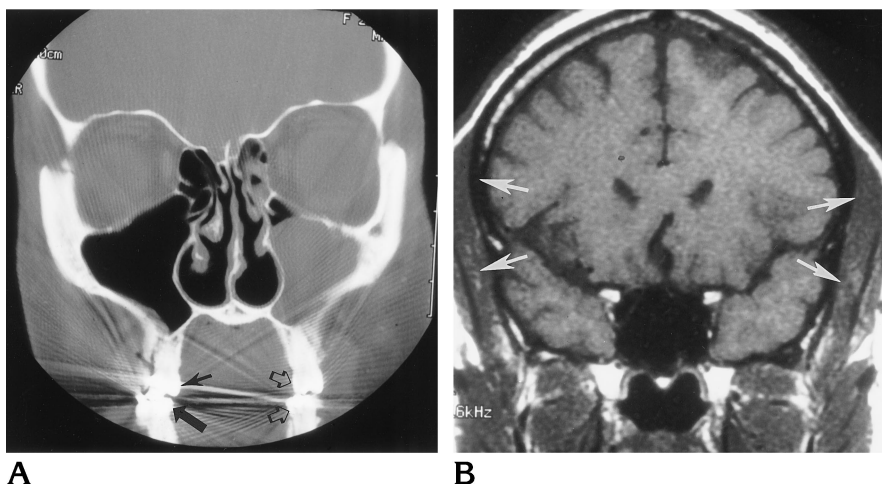
Blood vessels and nerves within the crown and root of a tooth are called the *dental pulp*. The pulp cavity or chamber is visible on plain films and CT scans as a lucency within the tooth (1) (Fig 11). Caries (cavities) can cause abscess and necrosis of the pulp. Patients can have difficulty locating the pain of pulpitis accurately (13).

Periapical dental radiographs of an acute dental abscess might be normal (3), or they can

Fig 12. Malocclusion and related disease.

A, Coronal CT image shows malocclusion on the patient's right side. On the normal left side, the lingual (medial) cusp of the maxillary tooth is lateral to the cusp of the mandibular tooth (*open arrows*). In comparison, on the right, the lingual (medial) cusp of the maxillary tooth (*small solid arrow*) is medial to the lingual cusp of the mandibular tooth (*large solid arrow*). This is called a *full crossbite*. There is an incidental retention cyst in the left maxillary sinus.

B, Coronal T1-weighted MR image (600/25/1) shows hypertrophy of the temporalis muscles (*arrows*), which can be seen in patients with bruxism (clenching of the teeth).



show widening of the periodontal membrane at the root apex (24). Periapical lucency (loss of bone around the apex of a root) is evidence that bacteria have spread beyond the tooth into the surrounding bone (3, 24). This lucency is visible on CT scans as well as dental radiographs (Fig 11). An acute periapical abscess can subside into chronic abscess (3, 24), which can be painless (3), or a dental granuloma (24); either one can cause periapical lucency (Fig 11). Chronic periapical infection can also create sclerosis ("condensing osteitis") (24) in the surrounding bone (Fig 11).

Malocclusion (Fig 12A), impacted teeth, and erupting teeth are other important sources of otalgia. These are best assessed clinically, but can be identified on imaging studies. Molars and premolars have cusps, or tubercles, that help grind food (5). In normal occlusion, the lingual (medial) cusp of a maxillary tooth is lateral to the corresponding cusp of the mandibular tooth (Fig 12A). Abnormalities of the teeth, jaws, and TMJ can contribute to malocclusion. Malocclusion also contributes to TMJ dysfunction and pain. Bruxism, or teeth clenching, causes referred otalgia, possibly from spasm of the medial or lateral pterygoid muscles (3) (Fig 12B). Unlike many other sources of otalgia, the otalgia of bruxism is often bilateral (3).

TMJ

The TMJ is a frequent, and frequently overlooked, cause of ear pain (13) (Fig 13A). Joint pain comes from the capsule, collateral ligaments, and retrodiskal bilaminar fold (7), be-

cause the disk and articular surfaces are not innervated (7). Exposure of bone or overgrowth of synovium can cause TMJ pain (7), because synovium and subcortical bone are innervated. Internal derangement is a malpositioned articular disk (meniscus); most often the disk is anterior to the articular surface of the condyle (3) (Fig 13B). Malocclusion and bruxism (clenching) contribute to TMJ disease and pain, probably through associated muscle spasm.

Parotid Gland

Before development of the mumps vaccine, mumps virus was the most frequent cause of parotitis (25). Viral (mumps) and bacterial parotitis both cause referred otalgia (7). A CT scan can help the clinician exclude an obstruction as the cause of inflammation and infection. Calculi are radiopaque on CT studies. Mucus plugs and strictures are not themselves visible on CT scans, but the dilated duct and inflamed gland are (Fig 14). A parotid neoplasm is another potential cause of referred otalgia (7).

Hypopharynx and Larynx

Referred otalgia can be the presenting symptom of carcinoma of the hypopharynx. Sore throat and dysphagia usually accompany the otalgia (6, 19). Piriform sinus tumors are an important source of referred otalgia (Fig. 15). Both rheumatoid arthritis and ankylosing spondylitis can involve the cricoarytenoid joint and cause otalgia (13). Chondritis of laryngeal cartilage can also present as ear pain (2) (Fig 16).

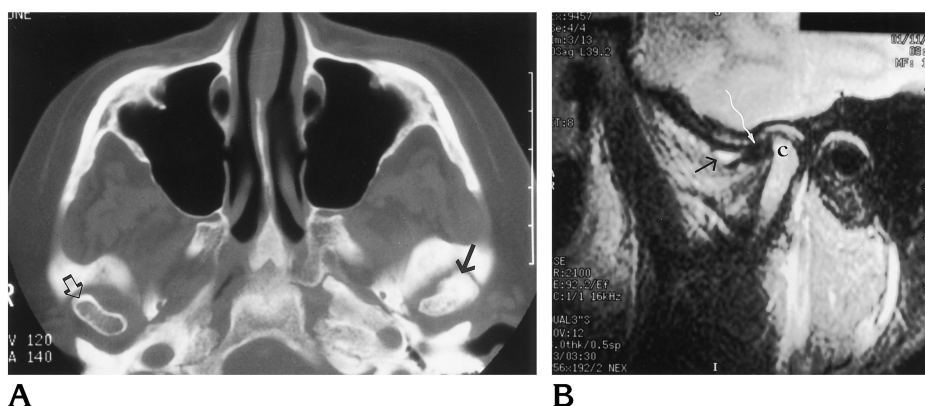


Fig 13. TMJ disease.

A, Axial CT image (bone algorithm) shows sclerosis, irregularity, and subchondral lucencies of the left mandibular condyle and narrowing of the left TMJ (solid arrow). The right condyle and joint space are normal (open arrow).

B, Direct sagittal T2-weighted MR image (2100/92.2 effective/2) shows the hypointense disk (white arrow) anterior to the mandibular condyle (C). Normally, the disk covers the articular surface of the condyle; this is an anterior displacement. There is also a small joint effusion (black arrow).

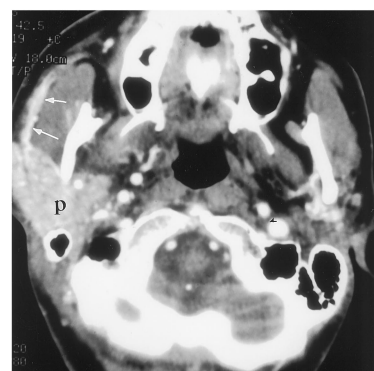


Fig 14. Acute viral parotitis. Axial contrast-enhanced CT image shows enlargement and intense enhancement of the right parotid gland (p) and accessory lobe (arrows). No obstructing calculus is present, and Stensen's duct and the intraglandular ducts are not dilated.

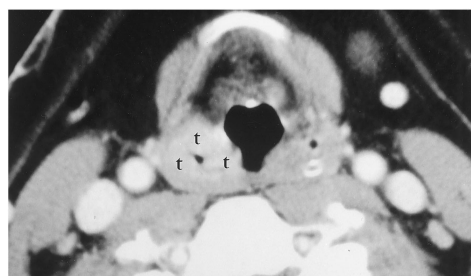

Fig 15. Squamous cell carcinoma of the piriform sinus. Axial enhanced CT image shows tumor (t) thickening the walls of the right piriform sinus.

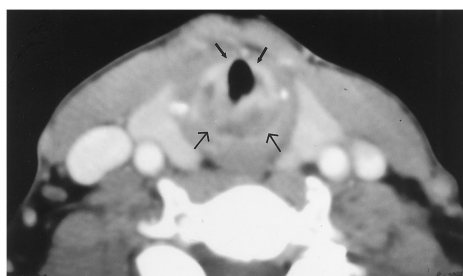


Fig 16. Radiation chondritis. Axial enhanced CT image of a patient who had received radiation therapy for a squamous cell carcinoma of the hypopharynx shows the posterior portion of the cricoid cartilage to be thicker and of lower density (large arrows) than the more normal anterior portion (small arrows).

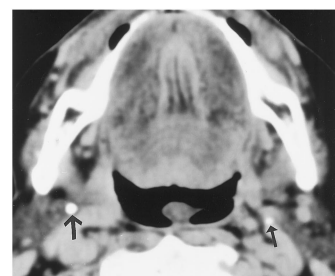


Fig 17. Eagle syndrome. Axial CT image (soft tissue algorithm) shows an enlarged and densely calcified right styloid process (large arrow). The left stylohyoid ligament is normal (small arrow). The patient's symptoms resolved after surgical removal of the right styloid process.

Carotidynia and Eagle Syndrome

Carotidynia is a disputed entity (26) that causes unilateral pain around the carotid bulb. The cause of carotidynia is unknown, although inflammation (vasculitis) might play a role (8). The pain radiates to the ipsilateral ear (4). An elongated styloid process or calcified stylohyoid ligament is one proposed cause of carotidynia (12).

In Eagle syndrome, an elongated styloid process or calcified stylohyoid ligament is implicated as a cause of throat and ear pain (5, 11, 23). An elongated, deviated styloid can impinge on the external or internal carotid artery to cause carotidynia, or irritate the tonsillar fossa

or a scar in the fossa after tonsillectomy (5). CT scans (axial images and three-dimensional reconstructions) and orthopantomograms show the styloid process well (Fig 17).

Thyroid Gland, Esophagus, and Trachea

Thyroid inflammation, including early and subacute thyroiditis, can cause pain that is referred to the angle of the mandible and the ear (2, 20, 23). The entire gland or one lobe can be involved. Gastroesophageal reflux is a rare cause of otalgia (2, 27, 28). Rarely, esophageal carcinoma presents with otalgia (12). A foreign body is another esophageal source of otalgia (2).

Tracheal chondritis, like laryngeal chondritis, can cause referred otalgia. Lung cancer (29, 30) and a thoracic aortic aneurysm (7) have also reportedly presented as otalgia, possibly referring pain to the ear from the bronchial branches of the vagus nerve.

Neuralgias

Primary neuralgia of the trigeminal, facial, glossopharyngeal, and vagus nerves can cause a variety of ear pains (8, 31). Some authors consider these neuralgias primary otalgia; others have classified them as referred otalgia (2, 8, 31). CT and MR studies play an important role in the evaluation of patients with cranial nerve neuralgias. A tumor arising from or adjacent to the nerve can be the cause of pain that is clinically indistinguishable from idiopathic neuralgia (9).

Trigeminal neuralgia (*tic douloureux*) most often causes agonizing, unilateral facial pain. Occasionally there is ear pain as well (2, 23).

All of the sensory branches of the facial nerve have been implicated in otalgia. Sluder (sphenopalatine) neuralgia is pain of the eyes and nose, with radiation to the ear (7, 23). The GSPN is most likely the pathway along which this pain radiates to the ear. It is crucial to exclude benign and malignant sinus disease before making the diagnosis of (idiopathic) sphenopalatine neuralgia (7). Chorda tympani neuralgia has been described in patients with otalgia; sectioning chorda tympani alleviated their pain (9). There is one report of nervus intermedius neuralgia (9). Genuiculate neuralgia can be idiopathic or herpetic (7). Herpetic genuiculate neuralgia (the Ramsay Hunt syndrome) is herpes of the external auditory canal and auricle, and facial nerve palsy. The facial nerve enhances intensely (32) (Fig 18). The patients may also have sensorineural hearing loss, tinnitus, vertigo, and ear pain. Herpetic neuralgia can affect any cranial or spinal nerve (2), with pain lasting long after the vesicles heal (postherpetic neuralgia). Thus, otalgia can persist after the eruption and other findings of Ramsay Hunt syndrome have resolved.

Glossopharyngeal neuralgia causes paroxysmal pain in the ear, tonsil, tongue base, and pharynx, often elicited by swallowing (2, 9, 23, 33). Some authors consider isolated ear pain alone as "partial" glossopharyngeal neuralgia, or Jacobson neuralgia (8). Glossopharyngeal

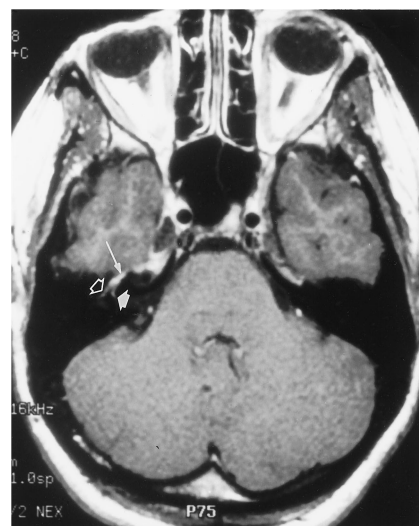


Fig 18. Ramsay Hunt syndrome (herpetic neuralgia). Axial contrast-enhanced T1-weighted MR image (625/25/2) shows intense enhancement of the labyrinthine (*thick solid arrow*) and tympanic (*open arrow*) portions of the right facial nerve and of the GSPN (*long arrow*).

neuralgia is usually idiopathic, but it can be caused by intracranial and extracranial neoplasms and vascular malformations (33) that might first be detected on imaging studies. Vagal (superior laryngeal) neuralgia is a rare cause of ear pain, more often causing pain in the larynx and hypopharynx (2).

Myofascial Pain Syndromes and Pain of Spinal Nerve Origin

For patients with myofascial pain syndrome, pressure on a trigger point recreates their pain (7). Myofascial trigger points known to cause otalgia are found in the masseter, trapezius, sternocleidomastoid, and medial and lateral pterygoid muscles (3, 7). Whiplash and other injuries to these muscles can also cause referred otalgia (3). Herpetic neuralgia of the cervical spinal roots causes a nonlocalized ear pain that is difficult to diagnose before the herpetic vesicles appear (13). Musculoskeletal diseases of the neck such as cervical facet arthropathy, intervertebral disk disease, and whiplash can also cause pain that radiates to the ear (13, 20, 34).

Conclusion

The patient with otalgia presents a diagnostic challenge to the clinician and the radiologist. Normal otoscopic findings can conceal primary temporal bone disease such as petrous apicitis

that is readily apparent on a CT or MR study. Normal findings can also be a clue to pain referred to the ear from remote disease. The radiologist may be the first to identify the remote source of ear pain. In the radiographic evaluation of patients with otalgia, it is important to cast the imaging net wide, to include sources of referred pain.

Acknowledgments

I am grateful to Eric Jablonowski for his patience and talent in developing the illustrations; to Sabrina L. Jennings for her superb secretarial support and her constant good nature in the face of alterations and revisions; and to Barry Hirsch, MD, for suggestions, references, ideas, and feedback during the preparation of this article.

References

- Hollinshead WH. *Textbook of Anatomy*. Hagerstown, Md: Harper & Row; 1974
- McDonald JS. Otolgia. In: Jackler RK, ed. *Textbook of Neurotology*. St Louis, Mo: Mosby-Year Book Inc; 1994:167-177
- Kreisberg MK, Turner J. Dental causes of referred otalgia. *Ear Nose Throat J* 1987;66:30-48
- Levine HL. Otorhinolaryngologic causes of headache. *Med Clin N Am* 1991;75:677-692
- Hollinshead WH. *Anatomy for Surgeons, Vol 1: The Head and Neck*. New York, NY: Harper & Row; 1968
- Stedman's Medical Dictionary. 26th ed. Baltimore, Md: Williams & Wilkins; 1995
- Wazen JJ. Referred otalgia. *Otolaryngol Clin North Am* 1989;22:1205-1215
- Rareshide EH, Amedee RG. Referred otalgia. *J La State Med Soc* 1990;142:7-10
- Cook JA, Irving RM. Role of tympanic neurectomy in otalgia. *J Laryngol Otol* 1990;194:114-117
- Thawley SE, O'Leary M. Malignant neoplasms of the oropharynx. In: Cummings CW, Fredrickson JM, Krause CH, Harker LA, Schuller DE, eds. *Otolaryngology-Head and Neck Surgery*. 2nd ed. St Louis, Mo: Mosby-Year Book Inc; 1993:1306-1354
- Jahn AF, Hawke M. Infections of the external ear. In: Cummings CW, Fredrickson JM, Krause CJ, Harker LA, Schuller DE, eds. *Otolaryngology-Head and Neck Surgery*. 2nd ed. St Louis, Mo: Mosby-Year Book Inc; 1993:2787-2794
- Paparella MM. Otolgia. In: Paparella MM, Shumrick DA, eds. *Otolaryngology*. 2nd ed. Philadelphia, Pa: WB Saunders; 1980:1354-1357
- Birt D. Headaches and head pains associated with diseases of the ear, nose, and throat. *Med Clin North Am* 1978;62:523-531
- Weissman JL. State of the art: hearing loss. *Radiology* 1996;199:593-611
- Grandis JR, Curtin HD, Yu VL. Necrotizing (malignant) external otitis: prospective comparison of CT and MR imaging in diagnosis and followup. *Radiology* 1995;196:499-504
- Rubin J, Curtin HD, Yu VL, Kamerer DB. Malignant external otitis: utility of CT in diagnosis and followup. *Radiology* 1990;174:391-394
- Chole RA, Donald PJ. Petrous apicitis: clinical considerations. *Ann Otol Rhinol Laryngol* 1983;92:544-551
- Neel HB. Benign and malignant neoplasms of the nasopharynx. In: Cummings CW, Fredrickson JM, Harker LA, Krause CJ, Schuller DE, eds. *Otolaryngology-Head and Neck Surgery*. 2nd ed. St Louis, Mo: Mosby-Year Book; 1993:1355-1371
- Zalzal GH, Cotton RT. Pharyngitis and adenotonsillar disease. In: Cummings CW, Fredrickson JM, Harker LA, Krause CJ, Schuller DE, eds. *Otolaryngology-Head and Neck Surgery*. 2nd ed. St Louis, Mo: Mosby-Year Book; 1993:1180-1198
- Harvey H. Diagnosing referred otalgia: the ten Ts. *J Craniomandib Prac* 1992;10:333-334
- Sinard RJ, Netterville JL, Garrett CG, Ossoff RH. Cancer of the larynx. In: Myers EN, Suen JY, eds. *Cancer of the Head and Neck*. 3rd ed. Philadelphia, Pa: WB Saunders Co, 1996:381-422
- Civantos FJ, Goodwin WJ. Cancer of the oropharynx. In: Myers EN, Suen JY, eds. *Cancer of the Head and Neck*. 3rd ed. Philadelphia, Pa: WB Saunders Co; 1996:361-380
- Yanagisawa K, Kveton JF. Referred otalgia. *Am J Otolaryngol* 1992;13:323-327
- Stafne EC, Gibilisco JA. *Oral Roentgenographic Diagnosis*. 4th ed. Philadelphia, Pa: WB Saunders Co; 1975
- Rabinov K, Weber AL. *Radiology of the Salivary Glands*. Boston, Mass: GK Hall Medical Publishers; 1985
- Biousse V, Bousser M-G. The myth of carotidynia. *Neurology* 1994;44:993-995
- Gibson WS, Cochran W. Otolgia in infants and children: a manifestation of gastroesophageal reflux. *Int J Ped Otorhinolaryngol* 1994;28:213-218
- Blau JN. Ear pain referred by the vagus. *Br Med J* 1989;299:1569-1570
- Bongers KM, Willigers HMM, Koehler PH. Referred facial pain from lung carcinoma. *Neurology* 1992;42:1841-1842
- Bindoff LA, Heseltine D. Unilateral facial pain in patients with lung cancer: a referred pain via the vagus? *Lancet* 1988;9:812-815
- Rupa V, Saunders RL, Weider DJ. Geniculate neuralgia: the surgical management of primary otalgia. *J Neurosurg* 1991;75:505-511
- Anderson RE, Laskoff JM. Ramsay Hunt syndrome mimicking intracanalicular acoustic neuroma on contrast-enhanced MR. *AJNR Am J Neuroradiol* 1990;11:409
- Chalmers AC, Olson JL. Glossopharyngeal neuralgia with syncope and cervical mass. *Otolaryngol Head Neck Surg* 1989;100:252-255
- Edmeads J. Headaches and head pains associated with diseases of the cervical spine. *Med Clin North Am* 1978;62:533-544