

Are your **MRI contrast agents** cost-effective?

Learn more about generic **Gadolinium-Based Contrast Agents**.



**FRESENIUS  
KABI**

caring for life

**AJNR**

**CT findings in chondroradionecrosis of the larynx.**

R Hermans, F A Pameijer, A A Mancuso, J T Parsons and W M Mendenhall

*AJNR Am J Neuroradiol* 1998, 19 (4) 711-718

<http://www.ajnr.org/content/19/4/711>

This information is current as of April 19, 2024.

## CT Findings in Chondroradionecrosis of the Larynx

Robert Hermans, Frank A. Pameijer, Anthony A. Mancuso, James T. Parsons, and William M. Mendenhall

**PURPOSE:** Our goal was to describe the CT findings before and after radiation therapy in a series of patients with laryngeal chondroradionecrosis.

**METHODS:** The CT studies obtained before and after radiation therapy in nine patients with the diagnosis of laryngeal chondroradionecrosis were reviewed retrospectively.

**RESULTS:** CT scans revealed abnormalities in all patients. A variable degree of laryngeal soft-tissue swelling was seen in eight of the patients. In four patients, cartilaginous abnormalities were visible initially, and appeared in three of four other patients who had further follow-up CT studies. Six patients had involvement of the thyroid cartilage; collapse of the thyroid cartilage was seen in two cases and gas bubbles were visible adjacent to the thyroid cartilage in three cases. Four patients with involvement of the thyroid cartilage eventually underwent total laryngectomy, and one died suddenly in severe respiratory distress. In all three patients with arytenoidal involvement, anterior dislocation of this cartilage was seen; in two of these patients, the adjacent part of the cricoid cartilage showed some sclerosis. Two patients with arytenoidal necrosis (both with cricoidal sclerosis) kept a functional larynx. In one case, cricoidal sclerosis was seen in association with lysis of the thyroid cartilage.

**CONCLUSION:** The CT appearance of laryngeal chondroradionecrosis is nonspecific, but the diagnosis can be strongly suggested in cases of sloughing of the arytenoid cartilage, fragmentation and collapse of the thyroid cartilage, and/or in the presence of gas bubbles around the cartilage.

Definitive radiation therapy (RT) for laryngeal cancer may cure the cancer but lead to severe edema or necrosis of the larynx, eventually requiring its removal because of pain or threat to airway patency (1, 2). In a number of cases, such conservative measures as administration of antibiotics and steroids or hyperbaric oxygenation can control these complications and leave the patient with a functional larynx (3-5).

Differentiating local recurrence of laryngeal cancer after RT from a significant treatment complication, such as severe edema possibly due to cartilage necrosis, is a difficult clinical problem. Since most necroses and many recurrences occur within 1 year after RT, the time of onset is not helpful in distin-

guishing between the two (6). Tumor recurrence is many times more common than chondroradionecrosis. The rate of primary recurrence with definitive RT is about 10% to 20% in T1/T2 lesions and 40% to 50% in T3/T4 lesions. Persisting edema and radionecrosis of the larynx are uncommon treatment complications, with a prevalence of about 1% (6). Approximately 50% of patients with severe edema after RT for laryngeal cancer will have local recurrence (2, 6).

The predictive value of a negative biopsy result is relatively low in patients treated by definitive RT (7, 8); the presence of tumor may only be confirmed on histologic examination of the entire larynx. Computed tomography (CT) can have a role in the evaluation of patients showing signs of laryngeal edema and/or necrosis after RT. When CT findings reveal only expected postradiotherapeutic laryngeal tissue changes, tumor recurrence is highly unlikely. On the other hand, if CT scans show asymmetric laryngeal tissues in a symptomatic patient, these findings may be used to target the biopsy into the most suspect area radiologically to increase the specificity of biopsy findings.

Because deep biopsies can aggravate existing necroses (9), it is useful to have more information about the CT findings in larynges containing chondroradio-

---

Received July 10, 1997; accepted after revision October 6.

R. Hermans received a study grant from the Royal Belgian Radiological Society; F. Pameijer received a fellowship grant from the Dutch Cancer Society.

From the Departments of Radiology (R.H., F.A.P., A.A.M.) and Radiation Oncology (J.T.P., W.M.M.), University of Florida College of Medicine, Gainesville.

Address reprint requests to Robert Hermans, MD, Department of Radiology, University Hospitals Leuven, Herestraat 49, B-3000, Leuven, Belgium.

necrosis without the presence of tumor recurrence. Noninvasive identification of such cases may facilitate treatment choices and improve the likelihood that the patient can keep a functional larynx.

### Methods

Pretherapeutic and posttherapeutic CT studies in nine male patients, all treated by definitive RT for laryngeal squamous cell carcinoma and all with a posttreatment diagnosis of laryngeal chondroradionecrosis, were analyzed retrospectively. The diagnosis of chondroradionecrosis (and absence of tumor recurrence) was confirmed pathologically after total laryngectomy ( $n = 5$ ) or made by a combination of clinical signs and symptoms, radiologic findings, and follow-up examinations ( $n = 3$ ). One patient with CT findings highly suggestive of chondroradionecrosis died suddenly in respiratory distress; his death was attributed to laryngeal necrosis.

Age of the patients, staging and location of the tumor, and the radiation treatment parameters are summarized in Table 1. The clinical staging was done according to the 1988 recommendations of the American Joint Committee on Cancer (10). All patients were treated at the University of Florida between December 1981 and April 1995; all but one were treated with definitive hyperfractionated twice-daily continuous-course RT. The treatment techniques have been described previously (11–13). One patient was treated by conventional once-daily continuous-course RT. In the patient with stage N3a cancer, RT was followed by a planned radical neck dissection.

All patients were followed-up clinically for at least 2 years after completion of RT. No patient was lost to follow-up. The charts of the patients were reviewed for possible risk factors for laryngeal necrosis (such as diabetes mellitus, arterial hypertension, arteriosclerosis) (5), for clinical signs and symptoms related to this complication of RT, and for local outcome.

All pretreatment ( $n = 9$ ) and posttreatment ( $n = 26$ ) CT studies were performed during intravenous contrast injection; 3-mm-thick contiguous sections were obtained with the plane of section parallel to the true vocal cords (field of view, 12–18 cm; matrix,  $512 \times 512$ ) (14). Before 1986, some studies were done with 5-mm-thick sections.

All CT studies were reviewed retrospectively by two of the authors. Consensus was reached between the two reviewers for each CT study. On the pretreatment CT studies, the

relation of the tumor to the laryngeal cartilages and the presence of laryngeal cartilage involvement were specifically assessed. The criteria used for establishing abnormality of the laryngeal cartilage were asymmetric sclerosis (thickening of the cortical margin and/or increased medullary density, assessed by comparing one arytenoid to the other or one side of the cricoid or thyroid cartilage to the other side), lysis (destruction of ossified cartilage), and focal or diffuse soft-tissue changes visible on both sides of the cartilage. In seven patients, a tumor volume estimation was available, calculated by the summation-of-areas technique, as described previously (15). On the pretreatment CT examination, each tumor was assigned a high- or low-risk profile for local failure after RT on the basis of previously determined specific CT parameters. T3 glottic tumors were considered to be at high risk if the tumor volume was  $3.5 \text{ cm}^3$  or more, or when there was associated sclerosis of more than one laryngeal cartilage (arytenoid and adjacent part of cricoid cartilage) (16, 17). A high-risk profile was attributed to a supraglottic tumor if the tumor volume was  $6 \text{ cm}^3$  or more (15). The T2 glottic tumor was not classified, as a previous study did not reveal specific CT-based risk factors for this type of tumor (18).

On the posttreatment studies, the occurrence of new or progressive cartilaginous changes as compared with pretreatment CT findings was noted, as well as any soft-tissue changes beyond those expected after RT (ie, complete resolution of the tumor at the primary site and symmetric laryngeal tissue) (19); subtle CT findings, such as asymmetry of the laryngeal fat planes without focal mass lesion, were considered indeterminate in the absence of clinical signs and/or symptoms.

In two patients, the pretreatment ( $n = 2$ ) and follow-up ( $n = 7$ ) studies were not available for review. In these cases, the reports of one of the investigators were reviewed for tumor extension and cartilaginous involvement.

### Results

Table 1 shows the pretreatment CT-determined tumor volume and risk profile for all nine patients, as well as the presence of tumoral involvement of laryngeal cartilages (according to the above-defined criteria). Table 2 summarizes the CT findings after therapy.

**TABLE 1: Patients' age, tumor location and stage, CT-determined tumor volume, laryngeal cartilage status, risk profile, and radiation therapy parameters**

Case	Age, y	Tumor Location	Tumor Stage	Volume, mL	Arytenoid Cartilage	Cricoid Cartilage	Thyroid Cartilage	Risk Profile	Treatment Duration, d	Dose, Gy	No. of Fractions
1	34	Gl	T3NL <sub>0</sub>	3.0	Tumor against L; sclerosis	Tumor against L; sclerosis	Tumor against L; normal	High	42	74, 4	60
2	51	Gl	T3N1	7.9	Tumor against R; sclerosis	Tumor against R; normal	Tumor against R; lysis	High	43	76, 8	64
3	61	Gl	T3N0	7.5	Tumor against R; sclerosis	Tumor against R; sclerosis	Tumor close; normal	High	42	74	60
4	51	Sg	T2N3a	5.4	Normal	Normal	Normal	Low	47	74, 4	60
5	42	Sg	T3N2b	...	Normal	Normal	Normal	High	45	76, 8	64
6	41	Sg	T3N1	15.0	Tumor against L; sclerosis	Normal	Tumor over upper margin notch	High	45	76, 8	64
7	69	Sg	T2NL <sub>0</sub>	10.8	Tumor against L; normal	Normal	Normal	High	42	74, 4	60
8	55	Sg	T3N0	7.4	Normal	Normal	Tumor over upper margin and probably growing through	High	43	76, 8	64
9	62	Gl	T2N0	...	Normal	Normal	Probable invasion at anterior commissure	...	47	67, 5	30

Sg indicates supraglottis; gl, glottis.

TABLE 2: Findings on posttreatment CT studies and local outcome

Case	CT Findings after Radiation therapy				Outcome
	First Study	Second Study	Third Study	Fourth Study	
1	2 mo: expected changes	13 mo: increased soft-tissue thickening	21 mo: irregular L thyroid with fluid and gas	...	Sudden death in respiratory distress at 30 mo
2	3 mo: progressive lysis of thyroid + sclerosis of cricoid; ulcerated soft-tissue thickening	8 mo: thyroid collapse + progressive soft-tissue thickening	...	...	TL at 10 mo
3	6 mo: persistent-soft tissue thickening over R arytenoid and subglottic spaces	10 mo: gross soft-tissue thickening with gas surrounding thyroid	...	...	TL at 12 mo
4	4 mo: expected changes	7 mo: some soft-tissue thickening of R vocal cord	12 mo: anterior dislocation of R arytenoid + sclerosis of cricoid; surrounding soft-tissue thickening	16 mo: fragmentation of R arytenoid	NED at 8 y 4 mo
5	4 mo: slightly asymmetric supraglottic spaces	6 mo: unchanged	24 mo: anterior dislocation of L irregular arytenoid + slight sclerosis of cricoid; no soft-tissue mass	27 mo: disappearance of L arytenoid	NED at 3 y 10 mo
6	1 mo: soft-tissue thickening false cords and against thyroid notch	1.5 mo: largely unchanged	3 mo: thickening of L false cord and around thyroid notch	4 mo: soft-tissue thickening; denudation of anterior L false cord	TL at 5 mo
7	6 mo: expected changes	14 mo: severe edema with compromise of airway	15 mo: severe edema with anterior dislocation of L arytenoid	22 mo: marked anterosuperior displacement of L arytenoid, no soft-tissue mass	TL at 24 mo
8	3.5 mo: diffuse soft-tissue thickening; gas against thyroid notch; some thyroid collapse	...	...	...	TL at 4 mo
9	35 mo: diffuse soft-tissue swelling; fragmentation of thyroid and fluid around thyroid	75 mo: sloughing of dead cartilage; defects in cartilage; soft-tissue swelling resolved	...	...	DID at 7 y

TL indicates total laryngectomy; NED, no evidence of disease; and DID, died of intercurrent disease. Time after end of radiation therapy is given.

None of the patients had diabetes mellitus or arterial hypertension. One patient had arteriosclerosis, complicated by a myocardial infarction 3 years before radiation treatment; another patient had severe calcified arteriosclerosis on the pretreatment CT study of the neck. Two patients had several upper respiratory infections during their posttherapeutic follow-up. Two patients continued smoking after RT. Two patients had laryngeal trauma: one (case 6) was hit in the throat by a rod 6 weeks after RT, but at this time his laryngeal condition was already worsening; the other (case 5) had an emergency intubation after an accidental stab wound 18 months after RT; his laryngeal condition started worsening 6 months later.

The mean time between completion of RT and the first evidence of suspicious or progressive soft-tissue or cartilaginous changes on a posttreatment CT study was 12 months (mean, 10 months; SD 3.7; range, 1 to 35 months). In eight cases, symptoms were present

more or less at the same time: five patients had some degree of dyspnea, five patients reported neck and/or ear pain, three had some degree of dysphagia, and one had a sudden onset of anterior neck swelling. In six of these eight patients, indirect laryngoscopy revealed varying degrees of laryngeal edema; additionally, two of the six (cases 3 and 8) had a unilateral yellow plaque or yellow debris over the cord region. Exposed cartilage was not seen in any of these patients. In the remaining two patients, no particular abnormalities were noted initially at indirect laryngoscopy; one of the patients (case 2) remained tracheotomized after the completion of RT and was asymptomatic at the time of the first suspicious follow-up CT study.

The first abnormal posttreatment CT study showed alterations in the thyroid cartilage combined with soft-tissue changes in three cases. In two patients, the thyroid cartilage abnormalities were lytic, and, in one



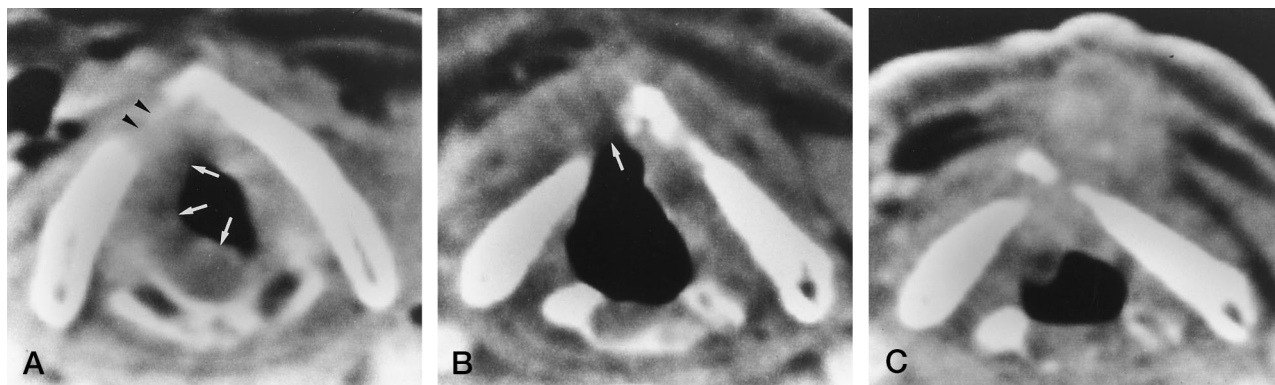


FIG 1. A, Pretreatment CT scan of a patient with a stage T3N1 glottic carcinoma shows thickening of the right true vocal cord, extending into the subglottic region (arrows). The focal defect in the right thyroid lamina (arrowheads) is suggestive of cartilage invasion.

B, CT scan 3 months after completion of RT shows ulceration of the laryngeal soft tissues overlying the cartilage defect, with some progression of lysis (arrow). Some sclerosis of the right cricoid cartilage is apparent, with thickening of the overlying extralaryngeal soft tissue.

C, CT scan 8 months after RT shows progressive lysis of the thyroid cartilage, which has collapsed. More endolaryngeal and prelaryngeal soft-tissue thickening is apparent. A total laryngectomy 2 months later revealed pyogenic granulomata and necrosis of ossifying cartilage.

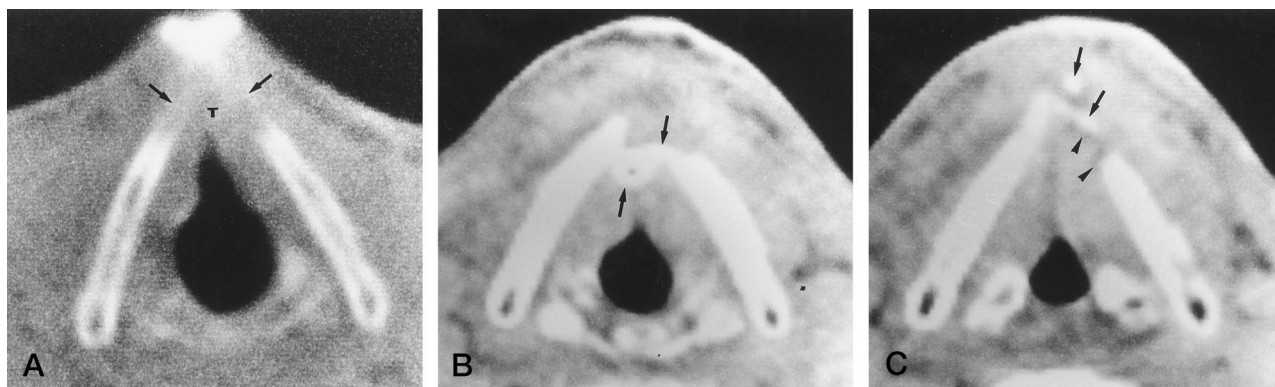


FIG 2. A, Pretreatment CT scan of a patient with a T2 glottic carcinoma shows tumor (T) most likely invading the cartilage at the anterior commissure (arrows).

B and C, CT scans 35 months after RT show diffuse soft-tissue thickening, fragmentation of the anterior portion of the thyroid cartilage (arrows), and a fluid area around the paramedian portion of the thyroid cartilage (arrowheads). D and E, CT scans obtained 6 years 3 months after RT show sloughing of the fragments of dead cartilage (arrow), leaving defects in the cartilage. Some soft-tissue thickening remains at the level of the anterior commissure (arrowhead). Healed chondronecrosis is limited to the area of tumor invasion.

case, they were associated with some cricoid sclerosis (Figs 1 and 2). In the third case, diffuse laryngeal soft-tissue thickening was seen, associated with gas bubbles against the thyroidal notch and some thyroid cartilage collapse (Fig 3); this last patient underwent total laryngectomy soon after the CT study because of progressive difficulty in breathing and swallowing, which did not respond to medical treatment. In all three cases there was evidence of tumoral involvement of the thyroid cartilage on the pretreatment CT studies. Of the two patients who had further fol-

low-up CT studies, one showed progressive soft-tissue thickening and thyroid cartilage collapse 5 months later (Fig 1); total laryngectomy was performed on the basis of the clinical and CT findings after biopsy specimens were negative for tumor. In the second patient, a control CT study 3 years 4 months later showed a defect in the thyroid cartilage and largely resolved soft-tissue swelling (Fig 2); this patient was asymptomatic at that time and died of intercurrent disease 7 years after completing RT.

Alterations on the first abnormal CT study after

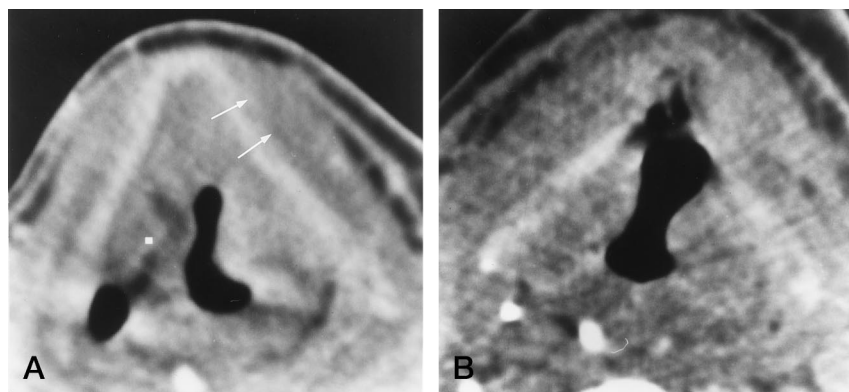


FIG 3. A, Pretreatment CT scan of a patient with a T3 supraglottic carcinoma at the level of the false cords shows tumor massively growing in the preepiglottic space, reaching against thyroid cartilage with subtle thickening of the left prelaryngeal strap muscles (arrows). There is subtle evidence of cartilage invasion.

B, CT scan obtained 3.5 months after RT shows persistent asymmetric thickening of the supraglottic soft tissues, with ulceration into the preepiglottic space and gas bubbles against the thyroid cartilage. Total laryngectomy revealed necrosis; no tumor was found.

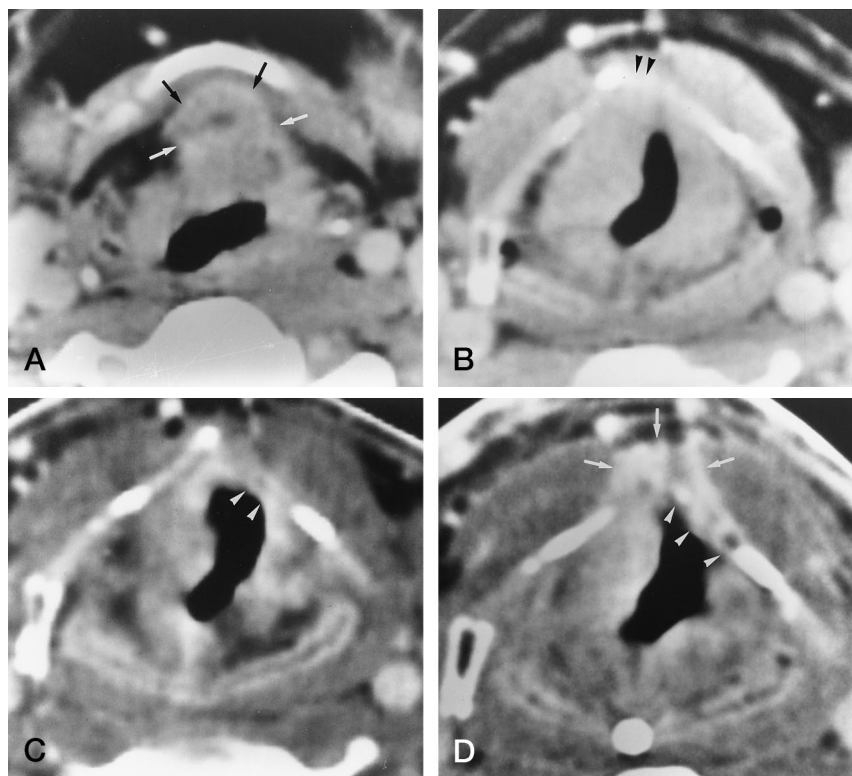


FIG 4. A and B, Pretreatment CT scan in a patient with a T3N1 supraglottic carcinoma (B) was obtained 5 mm below A. Tumor is seen growing into the preepiglottic space (arrows) and over the upper margin of the thyroid cartilage notch (arrowheads).

C, Posttreatment CT scan, 1 month after RT, shows thickening of the false cords, with tissue loss at the anterior side of the left false cord (arrowheads), reaching close to the thyroid cartilage.

D, CT scan obtained 3 months after RT shows progression of the soft-tissue thickening around notch of thyroid cartilage (arrows); the thyroid cartilage appears denuded at the anterior side of the left false cord (arrowheads). Total laryngectomy was performed 3 months later because of pain and aspiration; pathologic examination revealed severe soft-tissue inflammation and chondritis.

treatment were limited to the soft tissues in five cases. In three of these, a mass lesion with a maximum diameter of more than 1 cm was present (Fig 4), associated in one case with gas bubbles surrounding the thyroid cartilage at the location where the tumor approached the cartilage on the pretreatment CT study; this last patient underwent total laryngectomy soon after the CT study for progressive breathing difficulties. In the two other cases, a more subtle tissue asymmetry and diffuse edema, respectively, were present, but the findings were progressive as compared with a previous follow-up CT study.

Four patients in this subgroup had further follow-up CT studies; in three, associated alterations of the cartilage developed. Anterior dislocation of an arytenoid cartilage was visible in two patients 1 month and 5 months, respectively, after the first abnormal

posttreatment CT study. In one of them, the dislocation was associated with ipsilateral cricoid sclerosis; both patients needed a tracheostomy, definitive in one patient, and eventually leading to total laryngectomy to improve the patient's comfort, and temporary in the other patient. The latter patient is without evidence of disease 8 years 4 months after RT. In the third patient, an irregular and deformed thyroid surrounded by fluid and gas bubbles was seen 5 months after the first abnormal posttreatment CT study; at the same time an abscess developed on the anterior side of the neck, which ruptured spontaneously. Direct laryngoscopy revealed no abnormalities in this patient, who died in sudden respiratory distress 9 months after the last follow-up CT study. One patient had progressive soft-tissue thickening surrounding the thyroid cartilage associated with endolaryngeal focal tissue loss but no visible cartilage alterations 1.5



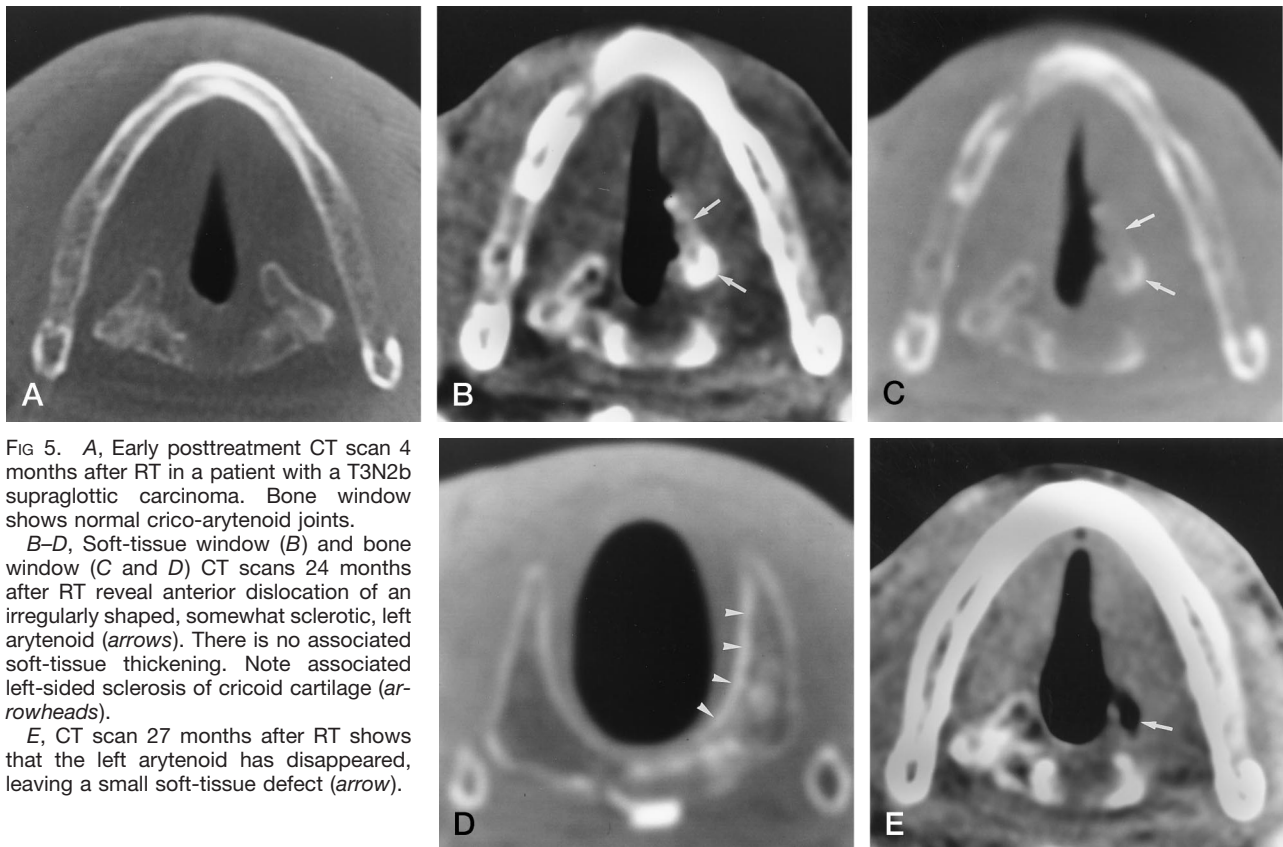


FIG 5. A, Early posttreatment CT scan 4 months after RT in a patient with a T3N2b supraglottic carcinoma. Bone window shows normal crico-arytenoid joints.

B-D, Soft-tissue window (B) and bone window (C and D) CT scans 24 months after RT reveal anterior dislocation of an irregularly shaped, somewhat sclerotic, left arytenoid (arrows). There is no associated soft-tissue thickening. Note associated left-sided sclerosis of cricoid cartilage (arrowheads).

E, CT scan 27 months after RT shows that the left arytenoid has disappeared, leaving a small soft-tissue defect (arrow).

months after the first abnormal posttreatment CT study (Fig 4). Despite treatment with hyperbaric oxygen, total laryngectomy was performed because of pain and aspiration.

In one case, no soft-tissue abnormalities were present on the first abnormal posttreatment CT study, but a unilateral anterior dislocation of an irregular and slightly sclerotic arytenoid was noted, associated with slight ipsilateral cricoid sclerotic 24 months after RT (Fig 5); these findings were not present on two prior posttreatment follow-up CT studies, obtained 4 and 8 months, respectively, after RT. This patient underwent an emergency intubation 18 months after RT, and began experiencing pain about 5 months later. A follow-up CT study 27 months after RT revealed that the dislocated arytenoid cartilage had disappeared; the patient reported having coughed up a small clot. There was no evidence of disease at the latest follow-up study 3 years 10 months after RT.

### Discussion

Acute changes occur in the laryngeal tissues during and immediately after RT; clinically, they are most apparent in the mucosa (2). Edema can occur acutely, but usually does not persist beyond 6 months after treatment. Persisting severe edema and radionecrosis of the larynx are largely due to impaired vascular and lymphatic flow, caused by endothelial damage and fibrosis (20). Cartilage has no blood vessels and no

lymphatics, making it resistant to the effects of radiation. Cartilaginous changes usually occur when the perichondrium is breached by trauma or tumor, exposing the underlying irradiated cartilage to microorganisms in the airway (1); this may lead to infectious perichondritis, which may result in necrosis and laryngeal collapse.

The laryngeal cartilages show progressive ossification in adults, developing a blood supply, and this may play a role in the pathogenesis of laryngeal cartilage necrosis. According to Marx (21), osteoradionecrosis is a problem of tissue homeostasis and wound healing, not of infection: irradiation produces a hypoxic, hypocellular, and hypovascular tissue, which is unable to maintain its normal tissue turnover. Traumatic events or infections create a demand for tissue repair, which is beyond the capabilities of the irradiated bone, and this accelerates its breakdown.

All the patients in this study in whom thyroid cartilage necrosis developed had a tumor touching or causing an abnormality within this cartilage, suggesting a connection between the two events. All but one of these patients also had large-volume tumors before RT; the use of large irradiation portals in such patients increases the risk of treatment complications. Minimal alterations in the cartilage, usually seen in smaller tumors, are not associated with poor local outcome (17).

The three patients in whom arytenoid and/or cricoid necrosis developed did not have cartilaginous changes on the pretreatment CT study, although in

one of them the tumor reached the tip of an arytenoid. This cartilage is known to ossify more completely than thyroid cartilage, and the pathogenesis of necrosis may have been different, more like bone necrosis, as discussed above. The arytenoidal sloughing in one of these patients occurred a few months after endotracheal intubation, and this traumatic event may have accelerated the breakdown of the crico-arytenoidal structures.

The anterior dislocation of an arytenoid seen in three patients could have been due to crico-arytenoidal joint effusion, subsequent to inflammation or infection. Septic arthritis of the crico-arytenoidal joint after irradiation for laryngeal cancer has been described previously (1).

The soft-tissue changes surrounding necrotic cartilage may be pronounced and may be the only visible abnormality, making differentiation from recurrent tumor difficult. Furthermore, both conditions can occur simultaneously. In some cases, CT findings allow better differentiation of tumor recurrence from chondronecrosis than afforded by clinical examination alone. Recent studies on posttherapeutic surveillance of laryngeal and hypopharyngeal cancer (F. A. Pameijer et al, unpublished data) (22) have shown that progressive cartilaginous alterations on posttreatment CT studies are predictive of poor local outcome, either from tumor recurrence or chondroradionecrosis. In these studies, gas bubbles were not observed in the vicinity of cartilage or cartilage collapse in patients with local failure due to tumor recurrence. Such findings should be regarded as suggestive of chondroradionecrosis.

Although in most of our cases the CT studies were performed because of a worsening clinical condition, CT can show progressive tissue changes after RT, including chondroradionecrosis, earlier than clinical examination alone (Pameijer et al, unpublished data). Laryngeal chondroradionecrosis, if not recognized, may be a life-threatening condition. One of the patients in this series died suddenly in respiratory distress of what was attributed to laryngeal collapse consequent to chondroradionecrosis. Although the follow-up CT studies in this patient were strongly suggestive of this diagnosis, clinical examination, including direct laryngoscopy, was noncontributory.

Recent studies have shown that even in advanced cases of chondroradionecrosis a functional larynx can be retained after intensive treatment with hyperbaric oxygenation (3, 4). A major problem in these cases is to exclude the coexistence of local tumor recurrence. Ongoing studies suggest that radionuclide imaging can detect local recurrences with a higher accuracy than attained with purely anatomically based methods, such as CT and MR imaging (23, 24) (Gapany M et al, *Thallium-201 SPECT imaging of head and neck tumors*. Presented at the 4th International Conference on Head and Neck Cancer, Toronto, Ontario, July 28–Aug 1, 1996). Whether imaging with fludeoxyglucose F 18 (FDG) or thallium can differ-

entiate tumor recurrence from chondroradionecrosis remains to be proved.

## Conclusion

The CT appearance of laryngeal chondroradionecrosis is often nonspecific. The soft-tissue changes and cartilaginous alterations observed in some of these patients can also be seen in cases of local tumor recurrence. Progressive crico-arytenoidal sclerosis with surrounding soft-tissue swelling, anterior dislocation, and possibly eventual sloughing of the arytenoid may be signs of chondroradionecrosis. Patients with a large pretherapeutic tumor mass and/or a tumor abutting or involving the thyroid cartilage seem to be at higher risk for chondroradionecrosis; gas bubbles around the thyroid cartilage and fragmentation and collapse of the thyroid cartilage are highly suggestive of laryngeal chondroradionecrosis.

## References

- Keene M, Harwood AR, Bryce DP, van Nostrand AWP. **Histopathological study of radionecrosis in laryngeal carcinoma.** *Laryngoscope* 1982;92:173–180
- O'Brien P. **Tumour recurrence or treatment sequelae following radiotherapy for larynx cancer.** *J Surg Oncol* 1996;63:130–135
- Ferguson BJ, Hudson WR, Farmer JC. **Hyperbaric oxygen therapy for laryngeal necrosis.** *Ann Otol Rhinol Laryngol* 1987;96:1–6
- Feldmeier JJ, Heimbach RD, Davolt DA, Brakora MJ. **Hyperbaric oxygen as an adjunctive treatment for severe laryngeal necrosis: a report of nine consecutive cases.** *Undersea Hyperbaric Med* 1993;20:329–335
- Rowley H, Walsch M, McShane D, Fraser I, O'Dwyer TP. **Chondroradionecrosis of the larynx: still a diagnostic dilemma.** *J Laryngol Otol* 1995;109:218–220
- Parsons JT. **The effect of radiation on normal tissues of the head and neck.** In: Million RR, Cassisi NJ, eds. *Management of Head and Neck Cancer: A Multidisciplinary Approach*. Philadelphia, Pa: Lippincott; 1994:245–289
- Viani L, Stell PM, Dalby JE. **Recurrence after radiotherapy for glottic carcinoma.** *Cancer* 1991;67:577–584
- Keane TJ, Cummings BJ, O'Sullivan B, et al. **A randomized trial of radiation therapy compared to split course radiation therapy combined with mitomycin C and 5 fluorouracil as initial treatment for advanced laryngeal and hypopharyngeal squamous carcinoma.** *Int J Radiat Oncol Biol Phys* 1993;25:613–618
- Ward PH, Calcaterra TC, Kagan AR. **The enigma of post-radiation edema and recurrent or residual carcinoma of the larynx.** *Laryngoscope* 1975;85:522–529
- American Joint Committee on Cancer. **Manual for Staging of Cancer.** 3rd ed. Philadelphia, Pa: Lippincott; 1988:39–44
- Parsons JT, Mendenhall WM, Cassisi NJ, Isaacs JH Jr, Million RR. **Hyperfractionation for head and neck cancer.** *Int J Radiat Oncol Biol Phys* 1988;14:649–658
- Mendenhall WM, Parsons JT, Stringer SP, Cassisi NJ, Million RR. **Stage T3 squamous cell carcinoma of the glottic larynx: a comparison of laryngectomy and irradiation.** *Int J Radiat Oncol Biol Phys* 1992;23:725–732
- Mendenhall WM, Parsons JT, Mancuso AA, Stringer SP, Cassisi NJ. **Radiotherapy for squamous cell carcinoma of the supraglottic larynx: an alternative to surgery.** *Head Neck* 1996;18:24–35
- Mancuso AA. **Imaging in patients with head and neck cancer.** In: Million RR, Cassisi NJ, eds. *Management of Head and Neck Cancer: A Multidisciplinary Approach*. Philadelphia, Pa: Lippincott; 1994:43–59
- Freeman DE, Mancuso AA, Parsons JT, Mendenhall WM, Million RR. **Irradiation alone for supraglottic larynx carcinoma: can CT findings predict treatment results?** *Int J Radiat Oncol Biol Phys* 1990;19:485–490
- Lee WR, Mancuso AA, Saleh EM, Mendenhall WM, Parsons JT, Million RR. **Can pretreatment computed tomographic findings predict local control in T3 squamous cell carcinoma of the glottic**



- larynx treated with radiotherapy alone?** *Int J Radiat Oncol Biol Phys* 1993;25:683-687
17. Pameijer FA, Mancuso AA, Mendenhall WM, Parsons JT, Kubilis PS. **Can pretreatment computed tomography predict local control in T3 squamous cell carcinoma of the glottic larynx treated with definitive radiotherapy?** *Int J Radiat Oncol Biol Phys* 1997;37:1011-1021
  18. Mukherji SK, Mancuso AA, Mendenhall W, Kotzur IL, Kubilis P. **Can pretreatment CT predict local control of T2 glottic carcinomas treated with radiation therapy alone?** *AJNR Am J Neuroradiol* 1995;16:655-662
  19. Mukherji SK, Mancuso AA, Kotzur IM, et al. **Radiologic appearance of the irradiated larynx: I, expected changes.** *Radiology* 1994;193:141-148
  20. Alexander FW. **Micropathology of radiation reaction in the larynx.** *Ann Otol Rhinol Laryngol* 1963;72:831-841
  21. Marx RE. **Osteoradionecrosis: a new concept of its pathophysiology.** *J Oral Maxillofac Surg* 1983;41:283-288
  22. Mukherji SK, Mancuso AA, Kotzur IM, et al. **Radiologic appearance of the irradiated larynx: II, primary site response.** *Radiology* 1994;193:149-154
  23. Lapela M, Grénman R, Kurki T, et al. **Head and neck cancer: detection of recurrence with PET and 2-[F-18]fluoro-2-deoxy-D-glucose.** *Radiology* 1995;197:205-211
  24. McGuiert WF, Greven KM, Keyes JW, et al. **Positron emission tomography in the evaluation of laryngeal carcinoma.** *Ann Otol Rhinol Laryngol* 1995;104:274-278