

Are your **MRI contrast agents** cost-effective?

Learn more about generic **Gadolinium-Based Contrast Agents**.



FRESENIUS
KABI

caring for life

AJNR

Parenchymal CT correlates of senile dementia (Alzheimer disease): loss of gray-white matter discriminability.

A E George, M J de Leon, S H Ferris and I I Kricheff

AJNR Am J Neuroradiol 1981, 2 (3) 205-211

<http://www.ajnr.org/content/2/3/205>

This information is current as
of April 27, 2024.

Parenchymal CT Correlates of Senile Dementia (Alzheimer Disease): Loss of Gray-White Matter Discriminability

Ajax Elis George¹
 Mony J. de Leon²
 Steven H. Ferris²
 Irvin I. Kricheff¹

Neuropathologic studies have defined gross anatomic (structural) as well as histologic (parenchymal) changes of senile dementia (Alzheimer disease). This investigation suggests that loss of gray-white matter discriminability by computed tomography (CT) is related to cognitive impairment in this disease. Discriminability is defined as the relative ease of visual differentiation between gray and white tissues. Twenty-six elderly patients with dementia were subjected to extensive psychometric evaluation, a medical and neurologic examination, and CT scanning. Gray and white matter changes were assessed by subjectively evaluating three brain levels, the basal ganglia, the centrum semiovale, and the high convexity, on a five point scale. Quantitated gray and white matter scores were also obtained by sampling CT attenuation values. In addition, CT structural changes were evaluated by previously reported methods. There were significant correlations ($P < 0.05$) between the subjectively assessed loss of gray-white matter discriminability at all brain levels and the measures of cognitive decline. At the high convexity level 91% of cognitive measures correlated with loss of gray-white discriminability. In the same patient group no gray-white discriminability correlation with age was demonstrated suggesting that gray-white discriminability does not simply change with age.

The most common dementing disorder of the elderly, accounting for about 50% of cases, closely resembles Alzheimer presenile dementia pathologically [1], and, therefore, has been termed senile dementia of the Alzheimer type. Neuropathologic changes of senile dementia have been defined both at the gross anatomic (structural) [2, 3] and histologic (parenchymal) levels [4, 5]. Pathologic studies by Tomlinson et al. [2, 3] of nondemented and demented elderly brains demonstrated increased incidence of ventricular and sulcal enlargement in the dementia group. The hallmarks of Alzheimer disease at the parenchymal level, senile plaques, neurofibrillary tangles, and granulovacuolar degeneration, are found more often in the cortex of senile dementia brains than in normal brains [2, 3]. A correlation has also been shown between both plaque counts and neurofibrillary tangles and the severity of senile dementia [5, 6]. In addition, plaque counts have been found to correlate with cortical atrophy, especially temporal lobe atrophy, but not ventricular dilatation [3]. The advent of computed tomography (CT) has not only permitted noninvasive visual examination of structural changes of the brain, but, for the first time, allowed in vivo inspection of brain parenchyma.

In our previous studies of structural changes in senile dementia [7-9], significant correlations were found between ventricular enlargement and cognitive decline as had been demonstrated previously by others [10]. In addition, a correlation was established for the first time between sulcal prominence and the degree of cognitive decline. The relation was consistently stronger for ventricular rather than sulcal enlargement. Of the linear measures, the width of the third ventricle was the strongest correlate of cognitive decline [7-9].

This investigation examines the parenchymal CT correlates of the histologic

Received June 11, 1980; accepted after revision January 12, 1981.

Presented in part at the annual meeting of the American Society of Neuroradiology, Los Angeles, March 1980.

This work was supported in part by U.S. Public Health Service grant MH 29590.

¹Department of Radiology, New York University Medical Center, 550 First Ave., New York, NY 10016. Address reprint requests to A. E. George.

²Department of Psychiatry, New York University Medical Center, New York, NY 10016.

AJNR 2:205-213, May/June 1981
 0195-6108/81/0203-0205 \$00.00
 © American Roentgen Ray Society

changes of senile dementia. Impressed by a seemingly wide variation in the ease of differentiating gray from white tissue in older age groups, we undertook a study to test whether a correlation exists between the degree of gray-white matter discriminability and cognitive impairment in senile dementia. Our evaluation of structural changes is also summarized, but will be reported in detail separately.

Subjects and Methods

We studied 26 outpatients, ages 60–84 years, with similar biographic and medical characteristics and gradual onset and progressive course of dementia. All had medical and neurologic evaluation, psychometric testing, and CT scanning. The medical-neurologic evaluation included a history and physical, complete blood and urine analysis, electrocardiogram, and detailed neurologic examination. Patients with historic, clinical, or subsequent CT evidence of infarction or other significant neuropathology were excluded from the study. The presumptive diagnosis in all cases was senile dementia of Alzheimer type.

Psychometric Evaluation

Cognitive function was evaluated with a battery of psychometric tests: eight memory measures, one psychomotor performance measure, and two global mental status indicators. The memory measures were: Guild paragraph recall, immediate and delayed; Guild verbal paired associates, immediate and delayed; Guild designs, nonverbal paired associates using abstract designs and numbers; and digit span forward and digit span backward. The Wechsler Adult Intelligence Scale (WAIS) for vocabulary was used to estimate remote memory. Psychomotor performance was assessed using the Digit Symbol Substitution Test (DSST). The global measures were the Mental Status Questionnaire (MSQ) and the Global Deterioration Scale (GDS). This psychometric battery is described in detail in a previous publication [9].

CT

Studies were performed on a Philips 200 translation rotation scanner in routine fashion. The contrast resolution of this scanner, which uses the Hounsfield (H) scale, is sufficient to permit routine visualization of gray and white matter tissues. Slices were scanned between the base and vertex of the skull parallel to the supraorbital-meatal line without contrast enhancement. The scan factors were: slice thickness, 12 mm; table increment, 12 mm; scan time, 60 sec; 150 kV; 30 mA; and 256 × 256 matrix. Scans were imaged on 20.3 × 25.4 cm x-ray film hard copy at a window setting of 100 H centered at 40 H. All scans were studied by the following methods:

Evaluation of parenchymal changes. Gray-white matter discriminability, defined as the visual contrast between gray and white matter tissues, was evaluated subjectively by one of us (A. E. G.) on one occasion, without knowledge of clinical grading using a five point rating scale: 1 = poor; 2 = poor to fair; 3 = fair; 4 = fair to good, and 5 = good.

Three brain levels, the basal ganglia, the centrum semiovale, and the high convexity, were rated from the hard copy. For evaluation of the basal ganglia, a representative slice was selected that clearly defined the internal capsule, the third ventricle, and the sylvian fissures (figs. 1A, 2A, and 3A). For the centrum semiovale level, a CT slice was selected that best demonstrated gray and white matter above the level of the ventricular system, but below the level of the

vertex gyri (figs. 1B, 2B, and 3B). For the high convexity level, a CT slice was selected demonstrating vertex sulci and gyri (figs. 1C, 2C, and 3C).

Initially, we attempted to categorize gray-white discriminability on a three point scale as either poor, fair, or good. If white matter and especially its interdigitations within the cortex were clearly discernible, and, consequently, if there was a clear density difference visually between gray and white matter structures, gray-white discriminability was rated as good (fig. 2). In cases in which white matter could not be visually differentiated from surrounding cortical gray, that is, if white matter was "isodense" with gray, gray-white discriminability was rated as poor (fig. 1).

Cases demonstrating some, but not good, differentiation of gray from white structures were rated as fair (fig. 3). It soon became apparent that this initial rating scale was inadequate. Therefore, it was expanded to a five point scale by adding the categories *poor to fair* and *fair to good*.

We subsequently attempted to quantify gray-white discriminability by obtaining several sample attenuation values for both gray and white matter at the high convexity and centrum semiovale levels. Three separate four pixel sample values were obtained for both gray and white matter utilizing a lite pen. (A point identified by the lite pen is composed of four pixels.) Gray matter samples were taken from the medial cortex only, to avoid the beam hardening artifact of lateral gray matter. Average values for white matter were then subtracted from the average values for gray. Furthermore, a second set of measures was derived for each patient by subtracting average ventricular cerebrospinal fluid density from each value obtained for both gray and white. Three lite pen point samples of cerebrospinal fluid were obtained from a cut demonstrating the frontal horns. The intent of subtracting gray and white scores from a standard density reference (cerebrospinal fluid) was, in part, to correct for possible calibration drift in the CT numbers. Unfortunately, in patients not demonstrating significant ventricular enlargement the reliability of cerebrospinal fluid sampling is adversely influenced by partial volume effect especially with CT slices of 12 mm thickness. Therefore, thinner slices and plastic phantom reference densities are being used in subsequent studies.

Evaluation of structural changes. The scans were also assessed for ventricular and sulcal enlargement by subjective and objective methods described in our previous reports [7–9]. Ventricular and cortical changes were separately evaluated. *Subjective assessment* required two observers to rank order the scans into a continuum of increasing atrophic enlargement. The measures derived from this procedure were the average ventricular dilatation rank and the average sulcal prominence rank. *Objective measures* included the quantification of several linear anatomic variables including the maximal area of the lateral ventricles. These measurements were extracted from floppy disc by computer software using a lite pen as well as by direct application to the hard copy of a transparent metric ruler.

The linear measures included A, the maximal diameter of the frontal horns (bifrontal diameter) of the lateral ventricles as shown on any cut at or below the foramen of Monro; A', the maximal width of the brain at A measured from inner to inner table; B, the bicaudate diameter; B', the maximal brain width at B; C, the maximal width of the third ventricle; D, the third ventricle to sylvian fissure distance; E, the width of both lateral ventricles at the mid body level above the foramen of Monro; E', the maximal brain width at E; F, the maximal diagonal width of the left frontal horn; G, the maximal diagonal width of the right frontal horn; H, the maximal horizontal width of the left sylvian fissure; I, the maximal horizontal width of the right sylvian fissure; J, the sum of the width of the three largest sulci; and K, the maximal area of the lateral ventricles as shown on any one cut.

Fig. 1.—*Poor* gray-white discriminability: Alzheimer disease patient with severe cognitive impairment. **A**, Basal ganglia level. Virtual disappearance of internal capsule, especially anterior limb, which is isodense with adjacent basal ganglia. Frontal white also tends to blend with frontal cortex. **B**, Centrum semiovale level. Cortical gray both medially and laterally is essentially isodense with central white. **C**, High convexity level. White matter blends with gray.

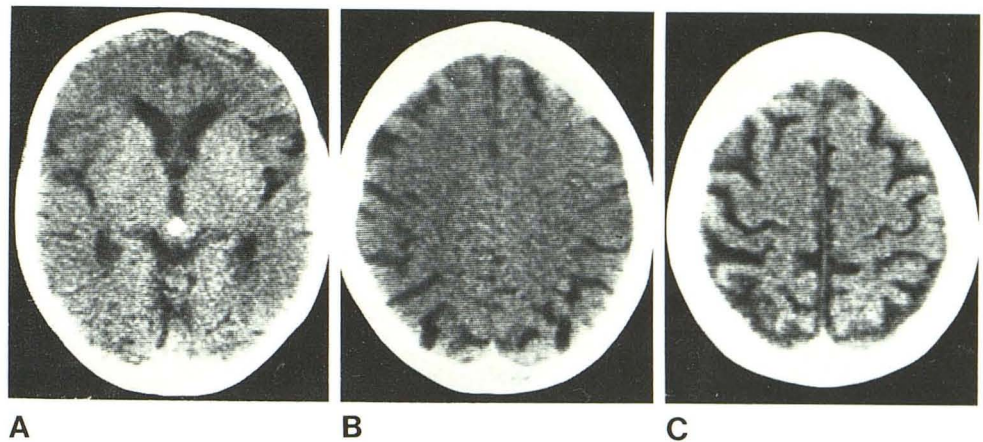


Fig. 2.—*Good* gray-white discriminability: Alzheimer disease patient with minimal impairment. **A**, Basal ganglia level. Both limbs of internal capsule are clearly discernible from adjacent basal ganglia. Frontal white matter is also visually separate from cortical gray. **B**, Centrum semiovale level. Central white matter well defined and of lesser attenuation value than cortical gray. (Lateral ventricles are partly visualized.) **C**, High convexity level. Excellent definition of white matter and its interdigitations. Sulci are not enlarged.

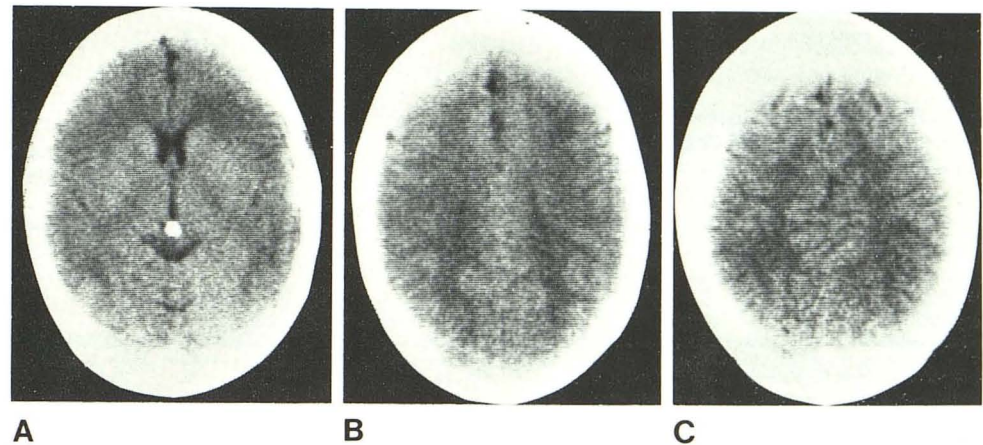
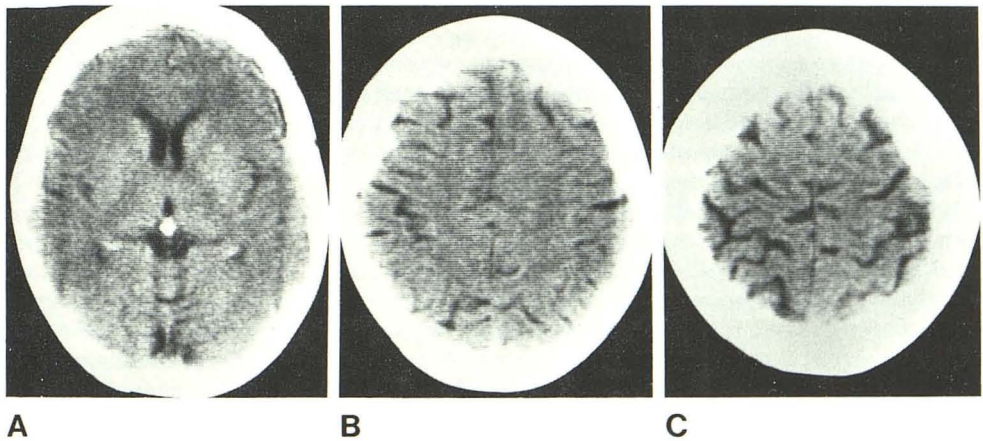


Fig. 3.—Alzheimer disease patient, moderately impaired. **A**, Basal ganglia level. Good gray-white discriminability. **B**, Centrum semiovale level. Fair discriminability. White matter partly visualized. **C**, High convexity level. Fair discriminability.



Results

Parenchymal Study

Subjective assessment of gray-white discriminability. There were significant correlations ($P < 0.05$) between the loss of gray-white matter discriminability for each of the three brain levels and scores on all but one of the cognitive measures (table 1). Of the total number of cognitive mea-

ures, 10 (91%) of 11 were significantly correlated ($P < 0.05$ or greater) with loss of gray-white discriminability at the high convexity level (table 1).

No gray-white matter discriminability correlation with age was demonstrated in this group. Thus, the more elderly in the patient group were not necessarily the most impaired. Although this suggests that gray-white variance is better explained by disease than by age, nevertheless, the lack of correlation may reflect the limited age range of this popu-

TABLE 1: Pearson Correlation Coefficients between Parenchymal Changes (Subjective Evaluation) and Cognitive Measures

Cognitive Measure	Loss of Gray-White Discriminability		
	Basal Ganglia	Centrum Semiovale	High Convexity
Paragraph 1	NS	NS	NS
Paragraph 2	0.38*	0.38*	0.42*
Paired associates 1	-0.46†	NS	0.47†
Paired associates 2	NS	NS	0.39*
Designs	NS	NS	0.43*
WAIS vocabulary	NS	NS	0.40*
Digits forward	NS	NS	0.36*
Digits backward	NS	NS	0.36*
DSST	0.44*	NS	0.40*
MSQ	-0.60†	-0.52†	-0.67†
GDS	-0.41*	-0.36*	-0.49†

Note.—WAIS = Wechsler Adult Intelligence Scale; DSST = Digit Symbol Substitution Test; MSQ = Mental Status Questionnaire; GDS = Global Deterioration Scale; NS = nonsignificant correlation.
 * $p < 0.05$.
 † $p < 0.01$.

TABLE 2: Correlations between CT Gray and White Attenuation Values* and Cognitive Measures

Brain Level	Significant Correlations (%) ($p < 0.05$)			
	Right Hemisphere		Left Hemisphere	
	Gray	White	Gray	White
High convexity	0	0	6	6
Centrum	14	14	38	22

Note.—In each structure, three measurements were made to correlate with the 11 cognitive measures; 33 individual correlations were made in each structure.
 * Cerebrospinal fluid corrected.

lation group. Evaluation of a wider range of normal controls would be desirable.

Quantitative assessment of gray-white discriminability. Certain potentially intriguing correlations were obtained between the cognitive and ventricular measures and the quantitated measures of gray-white discriminability. These results will be described in detail in a separate report.

Briefly, the cerebrospinal fluid-corrected gray and white matter density measures for both hemispheres were correlated with ventricular measurements both at the high convexity and centrum semiovale levels ($P < 0.05$). The correlations between these variables were all positive, suggesting that increases in brain attenuation values for both gray and white matter are covariant with increasing ventricular dilatation. In addition, the separate gray and white cerebrospinal fluid-corrected values suggested a pattern of left hemisphere but not right hemisphere gray and white matter attenuation value correlations with the cognitive measures (table 2). Of the total correlations, 38% were significant ($P < 0.05$) for left hemisphere gray matter at the centrum semiovale level whereas 14% were significant from the right hemisphere for gray as well as white. The assessment of the gray-white difference scores at the same two brain levels, that is, centrum and high convexity, produced the following result: 43% of the correlations between left hemisphere centrum semiovale gray-white difference scores and the cognitive measures were significant ($P < 0.05$).

TABLE 3: Pearson Correlation Coefficients between Subjective Gray and White Matter Discriminability and Objective Linear Measures of Structural Atrophy

Measurement	Basal Ganglia	Centrum Semiovale	High Convexity
Ventricular:			
A, Bifrontal diameter	-0.52†	-0.42*	NS
B, Bicaudate diameter	-0.41*	-0.43*	-0.43*
C, Third ventricle	-0.70†	-0.52†	-0.37*
D, Third to sylvian	NS	NS	NS
E, Width at bodies	-0.50†	-0.46*	-0.59†
F, Left diagonal width	-0.36*	-0.44*	-0.47*
G, Right diagonal width	-0.39*	-0.48*	-0.56†
K, Area	-0.40*		-0.45*
Cortical:			
J, Sum of sulci	-0.41*	-0.41*	-0.55†
H, Left sylvian	NS	NS	NS
I, Right sylvian	NS	NS	NS

Note.—NS = nonsignificant correlation.
 * $p < 0.05$.
 † $p < 0.01$.

TABLE 4: Pearson Correlation Coefficients between Subjective Gray-White Matter Discriminability and Subjective Cerebral Structural Atrophy

Ranking	Basal Ganglia	Centrum Semiovale	High Convexity
Ventricular	-0.58†	-0.53†	-0.58†
Cortical	-0.35*	-0.49†	NS

Note.—NS = nonsignificant correlation.
 * $p < 0.05$.
 † $p < 0.01$.

Structural Study

Both the ventricular and cortical ranking were consistently correlated ($P < 0.05$) with the cognitive measures of dementia. Ventricular ranking correlated with six of 11 of the cognitive measures and cortical ranking with three of 11. Of the overall number of correlations between linear ventricular measurements and cognitive measures, 48 of 77 were significant ($P < 0.05$); of the total correlations between cortical measurements and psychometrics, only one of 33 was significant ($P < 0.05$). Thus, subjective and objective ventricular assessments were significantly better predictors of cognitive impairment than the corresponding cortical evaluations. This is consistent with our previous observations [7-9].

Several linear measurements correlated consistently with gray-white discriminability at all three brain levels (table 3) ($P < 0.05$). These included the bicaudate diameter (B) and the left and right diameters of the anterior horns of the lateral ventricles (F and G). The best correlation between brain parenchyma and brain structure was found between loss of gray-white discriminability at the basal ganglia level and the width of the third ventricle ($r = -0.70$, $p < 0.01$) (table 3).

In addition, correlations were found between gray and white matter rating scores and both ventricular and cortical

ranking (table 4). It is of some interest that gray-white scores at the high convexity level correlated with ventricular ranking (table 4), but did not correlate significantly with cortical ranking (see Discussion).

Discussion

In this study we have attempted to define parenchymal CT changes of senile dementia. An examination of the contrast resolution capabilities of the scanner used for this study (Philips 200) may, therefore, be in order. Contrast resolution of the Philips 200 is sufficient to permit routine visualization of gray and white matter tissues. This assertion was verified in a review of scans of 50 consecutive ambulatory outpatients 20–65 years old, who were referred for a variety of clinical conditions other than dementia and interpreted to be normal. Good to excellent visualization of gray and white tissues was noted in all cases with distinct definition of the internal capsule and central cerebral as well as cerebellar white matter.

To our knowledge, this is the first radiologic study to report CT gray and white matter changes in brains of senile dementia patients and to demonstrate correlations between these changes and cognitive decline. The high correlation of gray-white discriminability loss at the high convexity level and cognitive impairment was stronger overall than the correlations with evaluations of cerebral atrophy. The magnitude of the correlations between parenchymal changes and cognitive measures (table 1) was of about the same strength as the correlations obtained for ventricular assessments, but superior to the cortical assessments. As in our previous reports [7–9], ventricular enlargement correlated more strongly with cognitive decline than did cortical atrophy. The close association of ventricular enlargement (tables 3 and 4) and gray-white discriminability suggests a possible relation between ventricular and parenchymal changes.

It is of further interest that the third ventricle was important in assessing the status of these cognitively impaired patients. In our previous reports on the ranking procedure [7–9], the width of the third ventricle was the best measurement correlate of clinical dementia; in our present study, the width of the third ventricle was the best linear measurement correlated with gray-white discriminability loss. Third ventricle width appears to be a useful criterion in the radiologic diagnosis of dementia.

The question arises of whether cerebral atrophy influences the subjective assessment of gray-white discriminability. Specifically, does the presence of cortical atrophy influence the gray-white assessment at the high convexity and centrum semiovale levels and does ventricular enlargement influence gray-white assessments at the basal ganglia level? The poor correlation between high convexity gray-white discriminability loss and the subjective evaluation of cortical atrophy (table 4) suggests that the subjectively assessed cortical atrophy did not significantly influence the rating of gray-white discriminability. However, subjectively rated, gray-white discriminability did correlate at all three brain levels ($P < 0.01$) with subjectively assessed ventricular

enlargement (table 4). This suggests that a cause and effect relation may indeed exist between parenchymal changes and ventricular enlargement. Alternatively, the presence of ventricular enlargement may have influenced the subjective assessments of gray-white discriminability.

Our initial effort to objectively quantify gray-white discriminability by obtaining CT number samples and thereby removing the potential subjective influence of coexisting cerebral atrophy produced some positive but inconsistent results. We postulated that this may have reflected in part an instability in scanner calibration. Therefore, in subsequent studies we are using a newer generation scanner with proven CT number stability and fine thickness slice capability.

Certain intriguing and potentially important correlations did arise between cognitive measures, and the objectively quantitated gray and white matter scores. First, increasing dementia was associated with increasing attenuation values of both gray and white matter; second, cognitive impairments may be related to left rather than right hemisphere attenuation changes. The significance of these findings is unclear and the preliminary nature of these results is stressed. The first finding is at variance with a previously reported study of CT numbers in dementia [11]. In that study, Naeser and coworkers reported that the CT numbers both of "healthy tissue" white matter samples (minimum of 150 pixels) as well as whole hemisphere samples in 21 senile and presenile dementia patients were significantly lower than in seven normal controls. The senile group consisted of seven dementia patients and one normal control. "Healthy tissue" samples were obtained from the cut immediately below the vertex. The probable contribution of gray matter, dilated sulci, and partial volume averaging of nonvisualized dilated sulci to the CT values obtained by this study must be considered before the results can be adequately interpreted. At this point, we believe that the issue of attenuation value changes in senile dementia is as yet unsettled.

The neuropathologic basis responsible for the loss of gray-white matter discriminability is still unknown; a review of the specific histologic changes that have been reported in senile dementia of Alzheimer type may offer clues to the underlying pathology. Furthermore, we assume that the CT attenuation value of brain parenchyma is a function of several tissue variables including vascularity, cellularity, and the characteristics of the extracellular space.

Large numbers of senile plaques and neurofibrillary tangles are found in Alzheimer disease. Plaques consist primarily of a core of amyloid surrounded by argentophilic fibers and granules [12]. Neurofibrillary tangles are composed of bundles of argentophilic fibers in the configuration of paired helical filaments. One can induce neurofibrillary tangles (not identical to human tangles) by treating certain animal species with intrathecal aluminum salts [13]. Interestingly, Crapper et al. [14] found a high concentration of aluminum in nervous tissue of patients with Alzheimer disease, although Wisniewski et al. [15] believe this to be an age-related phenomenon [16]. It is unknown whether plaques, tangles, or the concentration of aluminum salts

affect CT attenuation values.

On the issue of cellularity and its possible effect on CT attenuation values, studies by Brody [17] of cell counts demonstrated a significant loss of human cortical neurons as a function of age. The greatest loss was in the superior temporal gyrus. Terry et al. [18], in agreement with Tomlinson and Henderson [19], showed essentially identical cell counts when comparing more than 20 cases of senile dementia with the same number of age-matched controls. Therefore, cellular variability should equally influence CT attenuation values in both senile dementia and normal aging.

Corsellis [20] reported a changing ratio between cortical gray and white matter as a function of age, noting a shrinkage of white matter relative to gray matter during ages 40–90 years. This shrinkage is of unknown cause, but may result from a lessening of extracellular space or retrograde degeneration.

Finally, on the issue of the relative contribution of the vascular compartment to gray-white matter CT attenuation values, it is generally accepted that cerebrovascular disease changes are present in only 10%–15% of senile dementia patients [21]. However, studies of regional cerebral blood flow in senile dementia have shown a reduction of cerebral blood flow in proportion to the cognitive deficit with the frontal, temporal, and postcentral regions demonstrating the greatest reduction in flow [22]. Further investigations are required to determine whether any of the above factors are related to the underlying process responsible for the changes in gray-white discriminability demonstrated by CT.

In summary, a correlation has been demonstrated between loss of gray-white matter discriminability and cognitive impairment. Patients with the most severe cognitive impairments demonstrated virtual isodensity of gray and white tissues. Loss of discriminability at the high convexity level correlated with 10 (91%) of 11 cognitive measures. No correlation was demonstrated between discriminability loss and age within the pathologic group.

Loss of gray-white discriminability also correlated with several subjective as well as objective estimates of ventricular and cortical atrophy, especially the width of the third ventricle. Previous studies have consistently shown stronger correlations between ventricular enlargement rather than cortical atrophy and cognitive impairment; in our study gray-white discriminability loss was correlated more consistently at the cortical level with measures of cognitive impairment.

Increasing dementia was associated with increasing attenuation values for both gray and white matter and with increasing ventricular size; cognitive impairment may be more closely related to left rather than right hemisphere attenuation changes. The close correlation between gray-white changes and ventricular enlargement suggests that a relation may exist between parenchymal and ventricular changes.

As a consequence of these encouraging results, we are currently replicating and extending this study using a newer generation scanner to include quantitative aspects of gray-white discriminability in a larger patient population including an age-matched normal control group.

ACKNOWLEDGMENTS

We thank Barbara Lombardo and Maya Reiser for assistance in data collection and manuscript preparation.

REFERENCES

1. Alzheimer A. Ubereine eigenartige Erkrankung der Hirnrinde. *Zentralbl. New Psychol* **1907**;30:177–179
2. Tomlinson BE, Blessed G, Roth M. Observations on the brains of non-demented old people. *J Neurol Sci* **1968**;7:331–356
3. Tomlinson BE, Blessed G, Roth M. Observations on the brains of demented old people. *J Neurol Sci* **1970**;11:205–242
4. Corsellis JAN. *Mental illness and the aging brain*. London: Oxford, **1962**
5. Blessed G, Roth M, Tomlinson BE. The association between quantitative measures of dementia and of senile change in the cerebral grey matter of elderly subjects. *Br J Psychiatry* **1968**;114:797–811
6. Farmer PM, Peck A, Terry RD. Correlations among numbers of neuritic plaques, neurofibrillary tangles, and the severity of senile dementia. Presented at the annual meeting of the American Association of Neuropathology, San Francisco, June **1976**
7. de Leon MJ, Ferris SH, George AE, et al. A new method for the CT evaluation of brain atrophy in senile dementia. *IRCS J Med Sci* **1979**;7:404
8. de Leon MJ, Ferris SH, Blau I, et al. Correlations between CT changes and behavioral deficits in senile dementia. *Lancet* **1979**;2:859–860
9. de Leon MJ, Ferris SH, George AE, Reisberg B, Kricheff II, Gershon S. Computed tomography of brain-behavior relationships in senile dementia of the Alzheimer's type. *Neurobiol Aging* **1980**;1:69–79
10. Roberts MA, Caird FI, Grossart KW, Steven JL. Computerized tomography in the diagnosis of cerebral atrophy. *J Neurol Neurosurg Psychiatry* **1976**;39:909–915
11. Naeser MA, Gebhardt C, Levine HL. Decreased computerized tomography numbers in patients with presenile dementia. *Arch Neurol* **1980**;37:401–409
12. Terry RD. Senile dementia. *Fed Proc* **1978**;37:2837–2840
13. Terry RD, Pena C. Experimental production of neurofibrillary degeneration. 2. Electron microscopy, phosphatase histochemistry and electron probe analysis. *J Neuropathol Exp Neurol* **1965**;24:200–210
14. Crapper DR, Krishan SS, Dalton AJ. Brain aluminum distribution in Alzheimer's disease and experimental neurofibrillary degeneration. *Science* **1973**;180:511–513
15. Wisniewski H, Terry RD, Hirano A. Neurofibrillary pathology. *J Neuropathol Exp Neurol* **1970**;29:163–176
16. McDermott JR, Smith AI, Iqbal K, Wisniewski M. Aluminum and Alzheimer's disease. *Lancet* **1977**;2:710–711
17. Brody H. Organization of the cerebral cortex. III. A study of aging in the human cerebral cortex. *J Comp Neurol* **1955**;102:511–556
18. Terry RD, Fitzgerald C, Peck A, Millner J, Farmer P. Cortical cell counts in senile dementia. Presented at the annual meeting of the American Association of Neuropathology, Chicago, June **1977**
19. Tomlinson BE, Henderson G. Some quantitative cerebral findings in normal and demented old people. In: Terry RD, Gershon S, eds. *Neurobiology of aging*, vol 3. New York: Raven, **1976**: 183–204
20. Corsellis JAN. Some observations on the Purkinje cell population and on brain volume in human aging. In: Terry RD,

Gershon S, eds. *Neurobiology of aging*, vol 3. New York: Raven, 1976:205-209

21. Obrist WD. Cerebral circulatory changes in normal aging and dementia. In: Hoffmeister F, Miller C, eds. *Brain function in old age*. Berlin: Springer, 1979:278-287
22. Ingvar DH, Lassen NA. Activity distribution in the cerebral cortex in organic dementia as revealed by measurement of regional cerebral blood flow. In: Hoffmeister F, Miller C, eds. *Brain function in old age*. Berlin: Springer, 1979:268-277

Invited Commentary: Senile Dementia

The authors have obviously done a great deal of excellent and creative work in examining subjective analysis of gray-white matter discriminability and its correlation with severity of senile dementia. This aspect of the paper is well done, well documented, and presented in such a manner that the reader could replicate the study or begin to use it clinically on an already known demented population. However, the results are preliminary because there are no age-matched normal controls. Further the following comments on particular details seem appropriate.

1. Arimitsu et al. [1] found less difference between the CT values for gray and white matter in patients under 15 years of age than in older patients, which they suggested might be due to a higher attenuation value for white matter in their younger subjects. Since they also found that the calvarium was thinner in these young subjects they could not eliminate the possibility that the difference was due to radiographic spectral changes. George et al. may want to comment on this potential explanation for their observations.

2. The objective linear measurements of ventricular size and sulcal width (10 of them) are not fully presented, either in raw data form, summarized form, or in correlational form with cognitive measures. This limits the usefulness of this information. In addition, it would be useful to know if the ventricular/brain ratios at the frontal horns would have been altered, if bone windows had been used in measuring brain width [2].

3. The methodology used in obtaining the CT number information, "three four-pixel samples" at the centrum semiovale and high convexity levels in white and cortical gray matter is inadequately described. It is unclear if equal samples were taken in the left and right hemispheres, and if they were at exactly the same location and slice level in all subjects. We have observed changes in CT numbers of 2-8 H in white matter on the same centrum semiovale slice, depending on where the sample (150 pixels) was taken—frontal area, middle area, or parietal area (all away from bone).

4. Further, the authors examined gray and white CT values only at the centrum semiovale and high convexity slices. Previous research has shown that increased CT numbers are routinely observed near the apex [3]. One reason they found a correlation between increasing gray and white CT values at the centrum semiovale in high convexity slices and increasing ventricular size may be that these larger ventricles extended higher and forced the ob-

servers to examine even higher slices (closer to apex) than would normally be done in patients having normal-sized ventricles.

5. In aphasia stroke patients where semiautomated computer programs were used to analyze the infarct and ventricle size [4], a wide range in hemisphere size was observed—6,000 pixels (or less) to 11,000 pixels per slice, depending on the slice level [5]. It would be useful to know the mean size (standard deviation and range) of the slices examined at: (1) centrum semiovale and (2) high convexity. The high convexity slice in figure 2C appears to be much larger, for example, than the high convexity slice shown in figures 1C and 3C. The Naeser, Gebhardt, and Levine study with dementia cases found it necessary to control for slice size at the centrum semiovale level and CT numbers were examined *only* on slices of 6,900-9,000 pixels [6]. Lower white matter CT numbers (less than 40 H in 150 pixel samples) were observed in the dementia cases as compared to age-matched nondementia cases. The difference in dementia/nondementia cases was not observed at high convexity (5,000 pixels or less) or below the centrum semiovale level (greater than 10,000 pixels). Hence, it would be important to know the slice size range used in this study to obtain the gray and white matter CT number samples at both the centrum semiovale and high convexity levels.

6. The important issue of the relation between CT numbers in gray and white matter and aging and/or dementia needs to be studied further. Naeser et al. [6] observed *decreased* CT numbers in white matter and mixed gray and white matter at the centrum semiovale slice level in 21 presenile and senile dementia cases versus seven age-matched nondementia cases. Zatz et al. [7] recently examined 123 normal aging subjects, ages 23-88 years, with semiautomated computer programs and observed that with increasing age, there was a *decrease* in CT values in white matter in the slice just above the ventricles. The present fluid volume and cranial size had no effect on this observation. These two studies [6, 7] in both dementia cases and normal aging reported a *decrease* in CT numbers at the supraventricular level in white matter. Each used semiautomated computer programs to analyze the CT information [4] and each study examined tissue samples which were at least 150 pixels in size. These appear to contradict the observation of *increased* CT values in gray and white matter in more severely demented cases in the present study. It is possible such differences were observed in part because of differences in the number of pixels per sample studied—that is, 4 pixel samples in the present study, and 150 pixel samples in the other two studies [6, 7].

Szoke et al. [8] recently observed that compact myelin isolates from *aged* rat brain showed a large increase in the ratio of unsaturated/saturated long chain glycolipid fatty acids compared to isolates from mature or older animals. If this instability in myelin were also observed in aged human or dementia brains, it is possible the change would be observed in white matter CT values (although the direction of change is not known at this time). Penn et al. [9] already observed a 20% *increase* in brain tissue CT numbers in