

Are your **MRI contrast agents** cost-effective?

Learn more about generic **Gadolinium-Based Contrast Agents**.



FRESENIUS
KABI

caring for life

AJNR

CT in diagnosis of acoustic neuromas.

E H Wu, Y S Tang, Y T Zhang and R J Bai

AJNR Am J Neuroradiol 1986, 7 (4) 645-650

<http://www.ajnr.org/content/7/4/645>

This information is current as
of April 27, 2024.

CT in Diagnosis of Acoustic Neuromas

En-hui Wu¹
 Yu-san Tang
 Yun-ting Zhang
 Ren-ju Bai

A detailed analysis of the CT findings in 75 cases of acoustic neuroma is presented. The method of examination included plain and enhanced CT, metrizamide CT cisternography (M-CTC), and gas CT cisternography (gas-CTC). The common CT appearances of acoustic neuromas were as follows: 93.6% appeared as isodense or hypodense on precontrast scan; homogeneous enhancement was observed in 53.8% on postcontrast scan; the tumor center, mostly located at the level of the internal acoustic canal, was spherical in shape with an acute angle between the lateral tumor border and petrous bone; and there was widening of the internal acoustic canal or destruction of petrous bone. However, the presence of an acoustic neuroma could not be excluded if widening of the internal acoustic canal was absent. It was not certain whether contrast filling of the internal acoustic canal occurred at M-CTC in the four cases so examined. One case of intracanalicular neuroma was diagnosed by gas-CTC, which is the most sensitive and reliable technique for detecting and excluding small tumors. The significance of various CT appearances, early diagnosis, and differential diagnosis of acoustic neuroma from other cerebellopontine-angle tumors, particularly meningioma, are discussed.

The radiologic approaches for diagnosis of acoustic neuroma have included plain X-ray films, tomography, pneumoencephalography, ventriculography, Pantopaque cisternography, and vertebral angiography; all of these have some diagnostic limitations. However, CT has proven to be a safe and reliable method of diagnosing acoustic neuroma [1-5]. To improve our capability for diagnosis and differential diagnosis of acoustic neuroma, we thoroughly studied the CT findings in 75 patients with acoustic neuroma.

Subjects and Methods

Forty men and 35 women aged 16 to 64 years, with a mean age of 39.8 years, were studied. Seventy-one patients had unilateral tumors that were surgically and histologically proved. Four patients had bilateral tumors, which were associated with neurofibromatosis. Seventy-eight tumors were actually analyzed, with the exception of an intracanalicular neuroma, which was diagnosed by gas-CTC.

Twenty-six other cerebellopontine-angle extra-axial tumors were also studied, including 12 meningiomas, 11 epidermoid cysts, two trigeminal neuromas, and one chordoma.

Plain and enhanced CT were performed in all patients using a second-generation CT (Shimadzu SCT-100N) scanner with a 256 × 256 matrix, with a 0° or 20° craniocaudal angle between the scanning plane and the orbitomeatal line. We used a collimator of 10 mm in precontrast scans and of 5 mm in postcontrast scans, respectively.

Gas-CTC was performed in 24 patients suspected of having acoustic neuromas. In one case, an intracanalicular neuroma was seen, while the remaining 23 patients were found to be normal. The examining method has been reported elsewhere [6].

M-CTC was done in five cases, with a diagnosis in one case of acoustic neuroma and normal findings in the other four. Six to 8 ml of metrizamide (190 mg I/ml) was introduced into the subarachnoid space by lumbar puncture. The patient was placed supine, tilted into a 30° head-down position for 10 min, and subsequently moved to the CT unit. Consecutive 5-mm slices were obtained through the posterior fossa.

Received April 4, 1985; accepted after revision October 22, 1985.

¹ All authors: Tianjin Clinico-Radiological Research and Training Centre (First Teaching Hospital, Tianjin Medical College), 123 Anshan Rd., Tianjin, The People's Republic of China. Address reprint requests to E. H. Wu.

AJNR 7:645-650, July/August 1986

0195-6108/86/0704-0645

© American Society of Neuroradiology

Results

CT features of our 78 acoustic neuromas are summarized in Table 1.

The sizes of 78 tumors ranged between 1.0 cm and 6.0 cm, with a mean diameter of 3.9 cm. On the precontrast scan, 55.1% of acoustic neuromas were of normal brain density, 38.5% were hypodense, and 6.4% were slightly hyperdense.

TABLE 1: Analysis of CT Appearances of 78 Acoustic Neuromas

CT Appearance	No. of Cases	(%)
Precontrast attenuation		
Isodense	43	(55.1)
Hypodense	30	(38.5)
Hyperdense	5	(6.4)
Postcontrast pattern		
Homogeneous	42	(53.8)
Nonhomogeneous	20	(25.7)
Ring-shaped	14	(17.9)
No enhancement	2	(2.6)
Shape		
Round	60	(76.9)
Oval or semilunar	18	(23.1)
Peritumoral edema	26	(33.3)
Tumor calcification	1	(1.3)
Supratentorial extension	2	(2.6)
Tumor center at level of internal auditory canal	62	(79.5)
Tumor/petrous bone angle		
Acute angle	62	(79.5)
Obtuse angle	16	(20.5)
Widening of internal auditory canal	56	(71.8)
Fourth ventricle*		
Compressed and displaced	40	(56.3)
Invisible	29	(40.9)
Normal	2	(2.8)
Hydrocephalus*	55	(77.5)
Widening of ipsilateral cisterns*	32	(45.1)

* 71 cases of unilateral tumors are included here.

On the postcontrast scan, 97.4% of tumors exhibited contrast enhancement, and mean attenuation values increased 35.1 H. Only two hypodense tumors (2.6%) showed no enhancement; 53.8% of tumors showed homogeneous enhancement; 25.6% showed nonhomogeneous enhancement; and 17.9% of tumors appeared as ring-shaped enhancement. The pattern of enhancement was inherently related to precontrast attenuation values. Thus, the tumors with ring-shaped enhancement were mainly hypodense, which constituted 92.9% of all tumors of ring-shaped enhancement; and the tumors of homogeneous enhancement were mainly isodense, which constituted 90.5% of the cases. On precontrast scan, 74.4% of acoustic neuromas appeared as poorly defined masses. However, 82.1% of tumors manifested sharp margins on postcontrast scan. Most tumors (76.9%) were round. Mild or moderate peritumoral edema was present in 33.3% of tumors, and 79.5% of tumors had a narrow attachment to the petrous bone. In these, the angle formed between the antero- and posterolateral tumor border and the petrous bone was acute, which yielded the "acute-angle sign." The tumor center of 79.5% of tumors was located at the level of the internal acoustic canal. Supratentorial extension occurred in two cases, with one erroneously diagnosed as a meningioma. One case of tumor calcification with an attenuation value of 106 H (Fig. 1) was found. In two cases, tumor hemorrhage was seen as a lesion, with hyperdense fluid and a ring-shaped enhancement around the tumor (Fig. 2).

In 56 tumors (71.8%), CT showed a funnel-shaped enlargement of the internal acoustic canal and six of these were associated with the destruction of the petrous bone. Among 59 tumors examined by plain film, 47 had an abnormality of the internal acoustic canal, while CT showed enlarged canals in 43 of these. No significant discrepancy existed between plain films and CT ($p > 0.05$).

Widening of ipsilateral cisterns was seen in 32 (45.1%) of the 71 cases of unilateral tumors, including widening of one or more cisterns among the cerebellopontine-angle cistern,

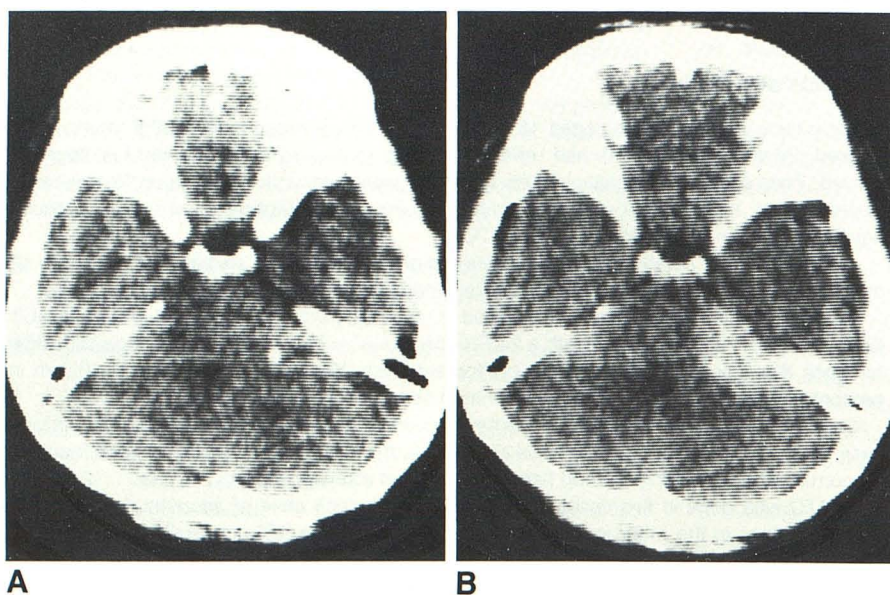


Fig. 1.—Calcification in acoustic neuroma. **A**, Precontrast scan. A small, round calcification shown within isodense tumor with attenuation value of 106 H. **B**, Postcontrast scan. Tumor shows homogeneous enhancement with single calcification.

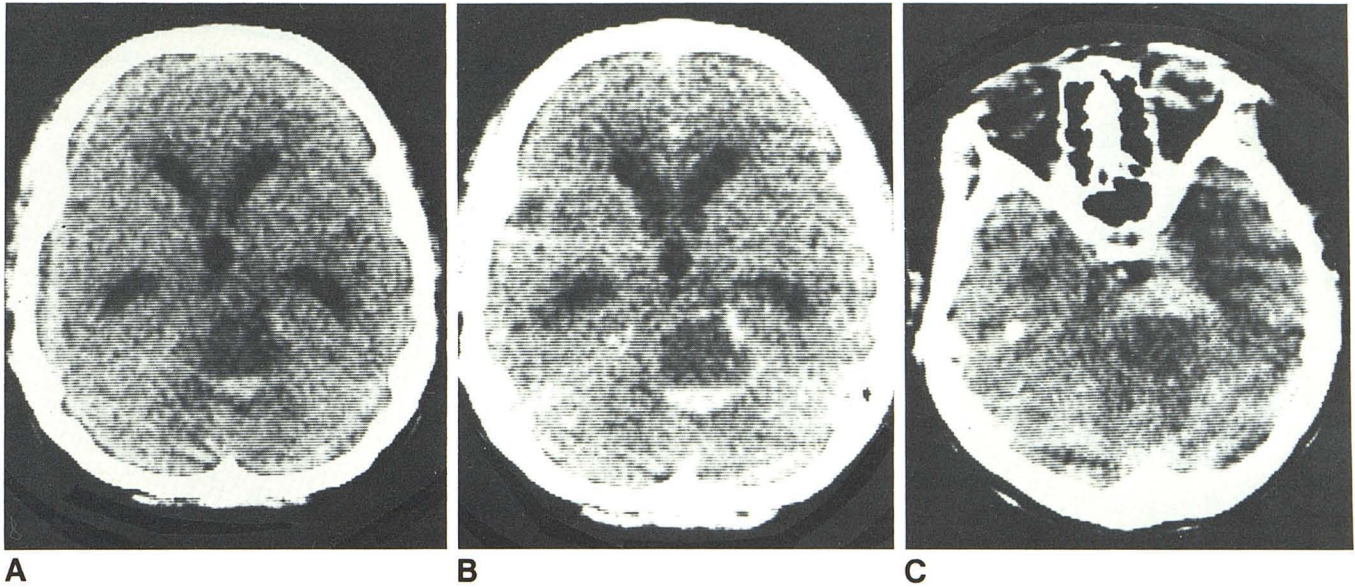


Fig. 2.—Hemorrhagic acoustic neuroma. **A**, Precontrast scan. Hypodense cystic tumor with hyperdense fluid. **B**, Postcontrast scan in supine position. Ring-shaped enhancement appears around tumor, with hyperdense fluid. **C**,

Postcontrast scan in prone position. Hyperdense fluid is in front of tumor, indicating that blood is mobile within cystic tumor with positional change.

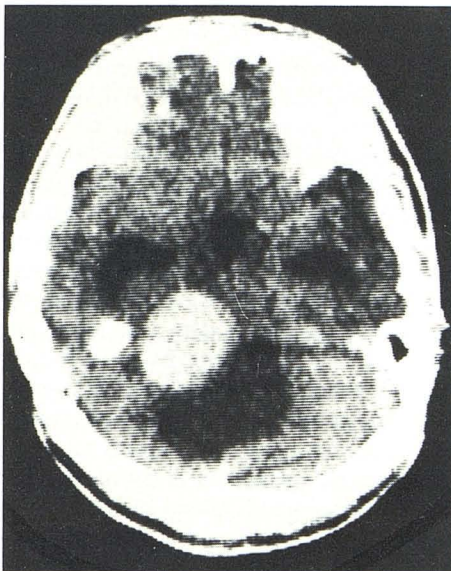


Fig. 3.—Acoustic neuroma associated with arachnoid cyst. Postcontrast scan. Hypodense cyst with well-defined borders and same density as cerebrospinal fluid is seen behind homogeneously enhanced acoustic neuroma.

the ambient cistern and the pontine cistern. The fourth ventricle was compressed and displaced in 56.3% of cases and normal in two cases. The posterior part of the third ventricle was compressed or laterally displaced in eight cases. Mild or moderate supratentorial hydrocephalus was seen in 77.5% of cases. Four cases of acoustic neuromas were associated with arachnoid cysts around the tumors (Fig. 3).

With the exception of one tumor located solely within the internal acoustic canal, seven tumors in four cases of bilateral acoustic neuromas appeared to be isodense and to have homogeneous enhancement, with widening of the internal acoustic canal. One case was associated with a suprasellar meningioma and three cases had multiple intracranial calcifications, in particular, massive calcifications of the choroid plexus (Fig. 4).

M-CTC showed filling of both cerebellopontine-angle cisterns with metrizamide in four normal patients, but it was not certain whether filling of the internal acoustic canals took place. M-CTC was not as certain as gas-CTC in demonstrating the neurovascular bundle within the cerebellopontine-angle cistern. One tumor, 3 cm in diameter, caused obliteration of the cerebellopontine-angle cistern and lateral displacement of the fourth ventricle.

Discussion

Significance of Various CT Appearances of Acoustic Neuroma

Widening of cisterns around a tumor is an important criterion for diagnosis of extra-axial tumors; it indicates that the brain is compressed by the tumor from the extra-axis. The presence of this sign can exclude a tumor within the cerebellar hemisphere and brainstem [7, 8]. The sign was present in 45.1% of our cases and appeared mainly as a widening of the ipsilateral half of the pontine cistern and the beginning of the ipsilateral ambient cistern. However, the cerebellopontine-angle cistern was usually not seen because of tumor occupation.

Enlargement of the internal acoustic canal is an important

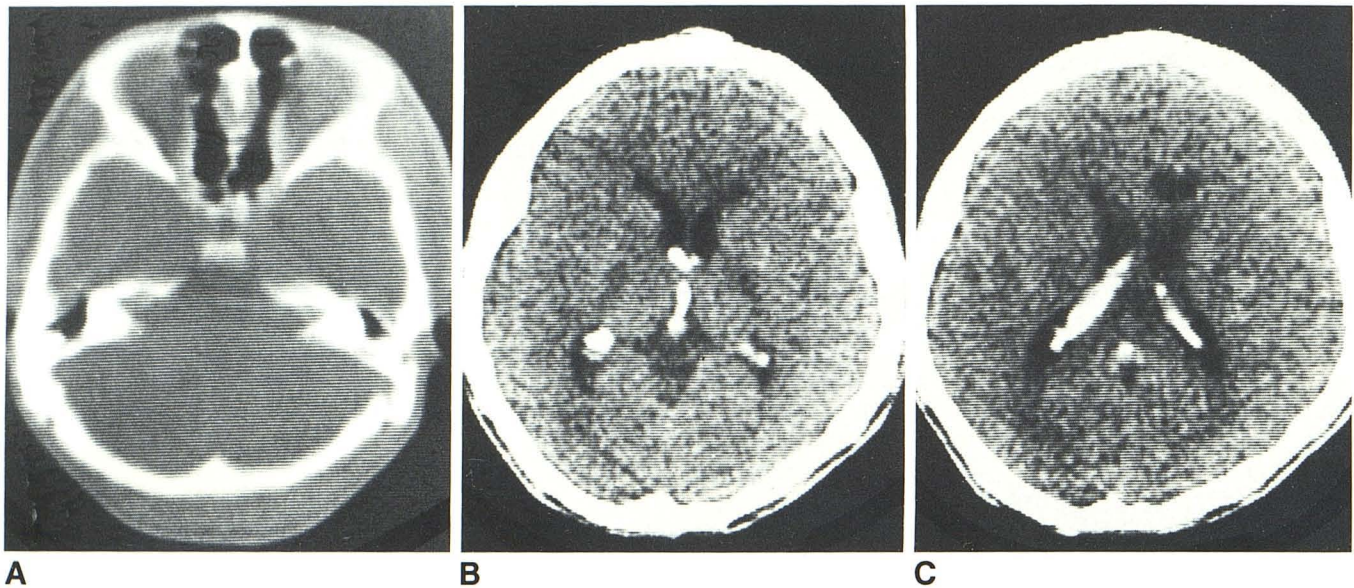


Fig. 4.—Bilateral acoustic neuromas. **A**, Window level setting at +700 H. Funnel-shaped enlargement of both internal auditory canals. **B** and **C**, Massive

calcifications of choroid plexus in third ventricle, region of foramina of Monro, atria, and bodies of lateral ventricles.

criterion in the diagnosis of acoustic neuroma. It was found in 71.8% with CT, which was lower than the number found with plain films. This difference was due to lower spatial resolution of the CT equipment. However, some acoustic neuromas grow mainly within the cerebellopontine angle or originate directly from the cisternal segment of the eighth nerve and have less effect on the internal acoustic canal. Therefore, the possibility of acoustic neuroma cannot be excluded, if the internal acoustic canal is intact (particularly with lower-resolution equipment).

More than half of the acoustic neuromas appeared as normal brain density on the precontrast scan, and most of them (97.4%) exhibited contrast enhancement. Therefore, routine enhanced CT is mandatory. Of the tumors in our group, 53.8% showed homogeneous enhancement, which is lower than the 73% and 87% reported in the literature [9, 10]; and 46.2% showed nonhomogeneous enhancement (including mixed or ring-shaped) or no enhancement, which was characteristic of tumor necrosis or cystic degeneration. It is generally believed that calcification is rare in acoustic neuroma; only one case has been reported in the CT literature [4] and only one case was found in our series.

On precontrast scan, most acoustic neuromas appeared as poorly defined masses. This was because most tumors were isodense and had little or no peritumoral edema. Because acoustic neuromas are extra-axial and have a complete integument, most of them have sharp margins on postcontrast scans. This sign is significant in demonstrating that the tumors are extra-axial. Most acoustic neuromas originate from the intracanalicular portion of the vestibular nerve sheath. Therefore, the tumors are almost in contact with the petrous bone, and the tumor centers are almost always located at the level of the internal acoustic canal. Most acoustic neuromas are round in shape so that an acute angle is

formed between the tumors and petrous bone. In our series, 5.1% of acoustic neuromas were associated with arachnoid cysts around the tumors (Fig. 3). This was a result of the cerebellopontine-angle cistern being occupied by tumor obstructing the cerebrospinal fluid circulation, which caused a secondary arachnoid cyst.

It has been reported that bilateral acoustic neuromas comprise 2%–5% of all acoustic neuromas, and these are usually associated with neurofibromatosis [11, 12]. Bilateral acoustic neuromas are considered a manifestation of neurofibromatosis even if skin lesions are absent [12]. This is a dominant inherited disorder with positive family history, characterized by rapid tumor growth and large size, and an association with other intracranial tumors. The four patients with bilateral acoustic neuromas in our series ranged in age from 15 to 34 years old with a mean age of 22.5 years, and were clinically and histologically proved to have neurofibromatosis. One case had an associated suprasellar meningioma, and it was notable that three cases had massive calcifications of the choroid plexus (Figs. 4B and 4C).

Differential Diagnosis Between Acoustic Neuroma and the Other Cerebellopontine-Angle Tumors

Meningioma and acoustic neuroma may each appear as a homogeneously enhanced mass in the cerebellopontine angle; it may be difficult to differentiate one from the other. (1) Precontrast density: In our series, 75% of meningiomas were hyperdense, while 93.6% of acoustic neuromas were isodense or hypodense. Hypodense meningioma in the cerebellopontine angle has not been seen in our series or reported in the literature [7]. Therefore, a hypodense tumor in the cerebellopontine angle is unlikely to be a meningioma. (2) Shape: 76.9% of acoustic neuromas were round. In contrast,

a round shape was present in only 16.7% of our cases of meningiomas; 83.4% of meningiomas were oval or semilunar in shape. Therefore, a round shape is characteristic of acoustic neuroma and a semilunar shape is typical of cerebellopontine-angle meningioma. (3) Angle between tumor and petrous bone: 79.5% of acoustic neuromas appeared with the "acute-angle sign." However such a sign was present in only 25% of meningiomas. The configuration of the angle depends primarily on the site of origin and the mode of growth of the tumor. Acoustic neuromas originate from the intracanalicular portion of the vestibular nerve sheath. As soon as they grow into the cerebellopontine angle they assume a spherical shape and form the "acute-angle sign." Meningiomas originate from the arachnoid villi cells of the venous sinus on the posterior surface of the petrous bone and have a broad attachment to the bone surface. When tumors grow further, their lateral borders are firmly attached to bone. Besides, the meningioma pannus, which tends to spread out along the dura, has a broad attachment to the petrous bone, resulting in a semilunar shape and forming the "obtuse-angle sign." (4) Widening of the internal acoustic canal: Widening of the internal acoustic canal was present in 71.8% of our cases of acoustic neuromas. In contrast, only one in 12 cases of meningioma had widening of the internal acoustic canal and was associated with destruction of the petrous bone. (5) Calcification: Tumor calcification occurred in 25% of our cases of meningiomas, but was only seen in one case (1.3%) of acoustic neuroma (Fig. 1), which showed statistical significance. Therefore, a calcified tumor in the cerebellopontine angle strongly suggests the diagnosis of meningioma. (6) Site and mode of growth: Between the two groups of tumors there existed significant discrepancies in three aspects; namely, the relation between the tumor center and the opening of the internal acoustic canal, tumor extending to occipital bone, and supratentorial extension of the tumor. A tumor with a center located at the level of the internal acoustic canal tends to be acoustic neuroma, while a tumor with supratentorial extension and/or extension to the occipital bone tends to be a meningioma. These discrepancies are related to the site of origin of the tumor. Meningiomas may originate from various sites on the posterior surface of the petrous bone and are therefore variable in position. (7) Pattern of contrast enhancement: Nonhomogeneous enhancement occurred in 46.2% of our cases of acoustic neuroma and in only 8.3% of meningiomas, a significant discrepancy. The occurrence of nonhomogeneous enhancement thus suggests the possibility of acoustic neuroma. (8) Delayed scans: A controlled study of delayed scans was done in five cases of acoustic neuromas and two cases of cerebellopontine-angle meningiomas in our series; that is, scans in the same plane were performed at 0-5, 20, 40, 60, 90, 120, and 180 min after intravenous contrast and attenuation values of the tumors were measured at each interval. Figure 5 shows the two tumors have different rates of clearance of contrast enhancement: rapid for meningiomas, because of the rich blood supply and rapid absorption of contrast medium into the vascular compartment, and relatively slow for acoustic neuromas. However, the number of cases observed by us is too small to afford a final conclusion.

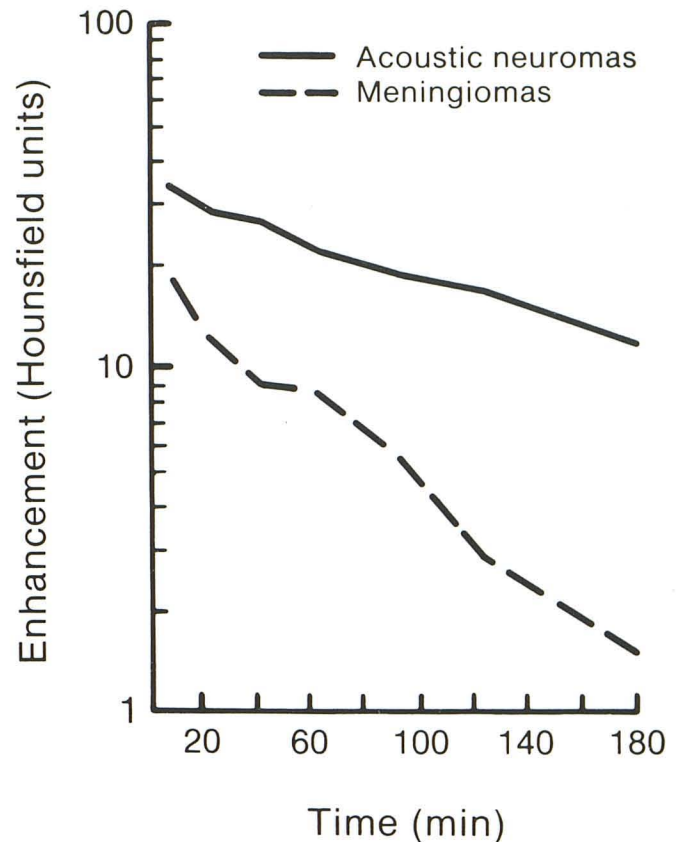


Fig. 5.—Rates of clearance of contrast enhancement in delayed scans of acoustic neuromas and cerebellopontine-angle meningiomas.

(9) Tumor size: The diameter of the 12 meningiomas in our series ranged from 4.0 cm to 6.0 cm, with a mean of 4.9, which was obviously larger than the size of acoustic neuromas with statistical significance. Möller et al. [13] reported that tumor size might serve as one of the criteria in differential diagnosis and noted that acoustic neuromas rarely exceeded 35 cm³ while meningiomas were probably seldom less than 13 cm³. However, in our series, 69.2% of acoustic neuromas were 4.0 cm or more in diameter. Therefore, it is not reliable to make a differential diagnosis according to tumor size. (10) Peritumor edema and supratentorial hydrocephalus: Our data showed there was no differential diagnostic value regarding these two signs.

According to the above differential criteria, we reviewed seven of the 78 acoustic neuromas (9.0%) that had been mistaken for meningiomas prior to surgery, and found that five of them conformed with the appearance of acoustic neuroma. The causes of the erroneous diagnosis were that homogeneous enhancement, slight hyperdensity, and lack of enlargement of the internal acoustic canal were overemphasized; and that the "acute-angle sign," the location of tumor center at the level of the internal acoustic canal, and the size of the internal acoustic canal were ignored. However, two tumors appearing semilunar in shape and without enlargement of the internal acoustic canal, one of which showed

supratentorial extension, were quite difficult to differentiate from meningioma. In this group of seven, four tumors were atypical in appearance, and qualitative diagnosis could not be made prior to surgery.

Epidermoid cysts generally show a well-defined, unenhanced, hypodense mass without widening of the internal acoustic canal, and are easily differentiated from acoustic neuromas. However, two tumors of hypodensity in our series showed no enhancement, and were misdiagnosed as epidermoid cysts prior to surgery. Review of the preoperative CT of the two patients showed the lesions were of nonhomogeneous density. One was associated with enlargement of the internal acoustic canal, which suggested the possibility of acoustic neuroma. In another, the lesion was semilunar in shape, was widely attached to the posterior surface of the petrous bone with no enlargement of the internal acoustic canal, and was difficult to differentiate from epidermoid cyst.

Trigeminal neuromas, unlike acoustic neuromas, have the tumor center at the petrous apex anterior to the level of the internal acoustic canal, involve the middle and posterior fossae, and have a dumbbell configuration. Moreover, there is compression and shortening of the petrous apex, destruction of the parasellar bone, and no enlargement of the internal acoustic canal.

Chordomas frequently contain spotty calcifications, are associated with extensive destruction of the dorsum sellae and clivus as well as the petrous apex, and may have suprasellar extension.

Early CT Diagnosis of Acoustic Neuroma

It has been reported that acoustic neuromas less than 1.5 cm in diameter were often difficult to detect by the second-generation CT [8, 14]. Only one of our 78 acoustic neuromas was 1.0 cm in diameter. On the precontrast scans, only 49.4% of the acoustic neuromas were directly demonstrated, and 24.1% appeared as hydrocephalus alone, or normal. So our experiences are: (1) For patients with clinical suspicion of an acoustic neuroma, enhanced CT should be performed even if the precontrast scans are normal. (2) Thin, overlapping slices, with slow scan speed should be performed after infusion of contrast medium. (3) Attention should be given to the size of the internal acoustic canal. (4) If possible, high-resolution CT should be used to increase small-tumor detectability.

M-CTC is an effective method for diagnosing small cerebellopontine-angle tumor [15]. However, our study suggests that with M-CTC it is difficult to diagnose an intracanalicular neuroma or small tumor protruding slightly into the cerebel-

lopontine angle.

There are many approaches for radiologic diagnosis of acoustic neuroma. This study suggests that plain films or geometrical tomography should be the first choice if high-resolution CT is not available, then plain and enhanced CT. If both give negative results, gas-CTC should be performed when an acoustic neuroma is strongly suspected.

REFERENCES

1. Davis KR, Parker SW, New PFJ. Cerebellopontine angle masses. In: Wolpert SM, ed. *Multiple imaging procedures*. Vol. 2, *Central nervous system*. New York: Grune & Stratton 1979:83-93
2. Schubiger O, Valavanis A, Menges H. Computed tomography for small acoustic neuromas. *Neuroradiology* 1978;15:287-290
3. Kendall B, Symon L. Investigation of patients presenting with cerebellopontine angle syndromes. *Neuroradiology* 1977;13:65-81
4. Robbins B, Marshall WH Jr. Computed tomography of acoustic neurinoma. *Radiology* 1978;128:367-370
5. New PFJ, Scott WR, Schnur JA, Davis KR, Taveras JM, Hochberg FH. Computed tomography with the EMI scanner in the diagnosis of primary and metastatic intracranial neoplasms. *Radiology* 1975;114:75-87
6. Wu En-hui, Tang Yu-san, Bai Ren-ju, Zhang Yun-ting. Gas-CT cisternography and canalography for the diagnosis of small acoustic neuroma. *Chin Med J* 1984;64:772-773
7. Valavanis A, Schubiger O, Hayek J, Pouliadis G. CT of meningiomas on the posterior surface of the petrous bone. *Neuroradiology* 1981;22:111-121
8. Naidich TP, Lin JP, Leeds NE, et al. Computed tomography in the diagnosis of extra-axial posterior fossa masses. *Radiology* 1976;120:333-339
9. Colnet H, Malgat R, Guibert-Tranier F, Piton J, Caillé JM. Acoustic neurinomas: clinical and radiological correlations. *J Neuro-radiol* 1983;10:301-314
10. Davis KR, Parker SW, New PFJ, et al. Computed tomography of acoustic neuroma. *Radiology* 1977;124:81-86
11. Nager GT. Acoustic neurinomas: pathology and differential diagnosis. *Arch Otolaryngol* 1969;89:252-279
12. Kasantikul V, Netsky MG, Glasscock III ME, Hays JW. Acoustic neurilemoma: clinicoanatomical study of 103 patients. *J Neurosurg* 1980;52:28-35
13. Möller A, Hatam A, Olivecrona H. The differential diagnosis of pontine angle meningioma and acoustic neuroma with computed tomography. *Neuroradiology* 1978;17:21-23
14. Valavanis A, Dabir K, Hamdi R, Oguz M, Wellauer J. The current state of the radiological diagnosis of acoustic neuroma. *Neuroradiology* 1982;23:7-13
15. Rosenbaum AE, Drayer BP, Dubois PJ, Black O. Visualization of small extracanalicular neurilemmomas by metrizamide cisternographic enhancement. *Arch Otolaryngol* 1978;104:239-243