

Are your **MRI contrast agents** cost-effective?

Learn more about generic **Gadolinium-Based Contrast Agents**.



FRESENIUS  
KABI

caring for life

# AJNR

## **MR imaging of syringohydromyelia and Chiari malformations in myelomeningocele patients with scoliosis.**

L Samuelsson, K Bergström, K A Thuomas, A Hemmingsson and R Wallensten

This information is current as of April 27, 2024.

*AJNR Am J Neuroradiol* 1987, 8 (3) 539-546  
<http://www.ajnr.org/content/8/3/539>

# MR Imaging of Syringohydromyelia and Chiari Malformations in Myelomeningocele Patients with Scoliosis

L. Samuelsson<sup>1</sup>  
 K. Bergström<sup>2</sup>  
 K-Å. Thuomas<sup>2</sup>  
 A. Hemmingsson<sup>2</sup>  
 R. Wallensten<sup>1</sup>

The brain and spinal cord were examined with MR imaging in 30 myelomeningocele patients 3–32 years old to study the prevalence of syringohydromyelia and Chiari malformations and to correlate these conditions with developmental scoliosis and spontaneously arrested hydrocephalus. Twelve patients had neurologic deficits above the level of the myelomeningocele and 10 had spontaneously arrested hydrocephalus. MR visualized syringohydromyelia in four patients with widened or focally bulging spinal cords and in eight patients with atrophic spinal cords. All patients had Chiari malformations, 28 of type II and two of type I. Syringohydromyelia was not correlated with type of scoliosis, result of ventriculoperitoneal shunting procedures, radiologic level of the myelomeningocele, or extent of the Chiari malformation. The two patients with the most rapid progression of thoracic scoliosis had the most extensive syringohydromyelia and radiologically low lumbar levels. Neurologic deterioration due to syringohydromyelia and Chiari malformations is probably more common in myelomeningocele than has been recognized previously and may cause developmental scoliosis, loss of ambulation, impaired extremity function, and progressive cranial nerve paralysis.

Scoliosis is a common cause of functional decline in patients with myelomeningocele [1–4] and is present in 50–70% of patients depending on neurologic level and age [1, 5–7]. During the last 10 years there has been an increasing awareness that progressive scoliosis in these patients may be caused by factors other than congenital vertebral anomalies or inadequate neuromuscular control from the back lesion [8–11]. Some children with myelomeningocele and scoliosis have increasing neurologic deficiencies characterized by weakness in the extremities, spasticity, and sensory disturbances at levels above the myelomeningocele [8–13]. The aim of our study was to use MR to evaluate the prevalence of syringohydromyelia and Chiari malformations with myelomeningocele and to correlate these conditions with developmental scoliosis, spontaneously arrested hydrocephalus, and neurologic deterioration.

## Subjects and Methods

Approval for this study was obtained from the Regional Research Ethics Committee of Karolinska Hospital, Stockholm. Informed consent was obtained before the MR examination from each patient or from the parents or guardians of each child.

The brain and spinal cord were examined in 30 patients, 15 males and 15 females 3–32 years old (mean, 17 years). All had had previous surgery for myelomeningoceles. The patients were selected from among 160 retrospectively investigated patients representing the total population of myelomeningocele patients treated at the Karolinska Hospital in Stockholm and Örebro Medical Centre Hospital. Referral for MR was on the basis of developmental scoliosis and/or signs and symptoms suggestive of lesions in the brainstem or spinal cord at levels above the myelomeningocele and/or spontaneously arrested hydrocephalus.

The spinal cords were also examined in seven normal children 10–15 years old to obtain criteria for normal morphology of the cord. In addition, the brains of 10 normal volunteers 9–40 years old were examined.

Received May 20, 1986; accepted after revision September 22, 1986.

Presented at the Symposium Neuroradiologicum, Stockholm, June 1986.

This work was supported by grants from Sven Jerring Fonden, Norrbacka Eugenia-Stiftelsen, and The Swedish Medical Research Council (project no. 6676).

<sup>1</sup> Department of Orthopaedic Surgery, Karolinska Hospital, S-104 01 Stockholm, Sweden. Address reprint requests to L. Samuelsson.

<sup>2</sup> Department of Diagnostic Radiology, Uppsala University, Akademiska Sjukhuset, S-751 85 Uppsala, Sweden.

*AJNR* 8:539–546, May/June 1987

0195–6108/87/0803–0539

© American Society of Neuroradiology

MR was performed with a 1.0-T superconducting magnet (Magnetom, Siemens) operating at 0.35 T in the first 15 patients and at 0.5 T in the next 15 when examining the skull and cervical region with the head coil. Surface-coil scans were obtained in 29 of 30 patients and in all volunteers; the thoracic spinal cord was examined at 0.5 T in all of these cases. One patient was scanned with the body coil. Multislice sagittal, axial, and in a few patients coronal or angulated scans were obtained using a spin-echo technique with a 300-msec repetition time and a 35- or 70-msec echo time. For contiguous imaging of the brainstem, the slice thickness was 10 mm with gaps of 10 mm, and the examination was repeated with a spatial offset of 10 or 6 mm. To ensure detection of syringohydromyelia, especially in patients with severe scoliosis and/or small cords, the slice thickness was 5 mm with gaps of 1 mm. In all patients the gaps were filled by repeating the examination, giving a 2-mm overlap on sagittal images. The average examination time was 120 min (range, 45–180 min).

The anteroposterior diameter of the spinal cord was measured at the C5 and T5 levels on both sagittal and axial images and was related to measurements from MR images of volunteers and to normal spinal cord size measurements reported by Nordqvist [14]. The scoliotic curve was measured by the method of Cobb [15] on frontal images obtained in the sitting position.

The functional neurologic level was defined as the lowest level on the best side at which the patient was able to perform an antigravity (grade 3) movement through the available range of joint motion [3, 16]. The radiologic level was defined as the highest vertebra with signs of posterior element defects.

## Results

### Scoliosis

Twenty-eight patients had developmental scoliosis, one had scoliosis associated with congenital vertebral anomalies, and a 4-year-old boy had no scoliosis at all. Twelve patients had compensatory curves in addition to primary curves. Eighteen curves were thoracic (mean, 50°, range, 10–99°), 12 were thoracolumbar (mean, 28°, range, 7–107°), and 13 were lumbar (mean, 31°, range, 7–95°).

### Normal Anatomy

There was close agreement between sagittal MR measurements of spinal cord size at C5 (mean, 8.6 mm, range, 8.3–9 mm) and T5 (mean, 7.1 mm, range, 7–7.5 mm) and measurements obtained by Nordqvist [14] from autopsies and myelograms.

### Syringohydromyelia

The spinal cord was clearly seen in all 30 patients. It was widened or focally bulging in four patients, of normal size in one, and diminished in 25. Mean sagittal diameter of the atrophic cords at C5 was 6.2 mm (range, 3–7 mm) and at T5 5.3 mm (range, 2–7 mm). In three patients with myelomeningoceles restricted to the sacral region, the central canal was seen in the conus medullaris, as it was in the youngest volunteer. Twelve patients had syringohydromyelia, yielding a prevalence of 40%; the findings in these patients are summarized in Table 1.

In two patients (cases 1 and 2) with enlarged spinal cords, the cystic area reached from C2 and C5, respectively, to the conus medullaris (Fig. 1). In one patient (case 4), two small cysts in enlarged areas of the thoracic spinal cord were sharply demarcated from the otherwise atrophic cord (Fig. 2). The fourth patient (case 3), the only one with congenital scoliosis, had a cyst with widened spinal cord from C4 to the middorsal region. In all these patients the rostral extension of the cavities was tapered and in no case located more proximal than the second cervical vertebral body. Communication of the cavities with the fourth ventricle could not be seen in any patient. In the two patients with cavities limited to parts of the spinal cord, the caudal extent was tapered, and in one of them the cyst continued in the distally atrophic cord.

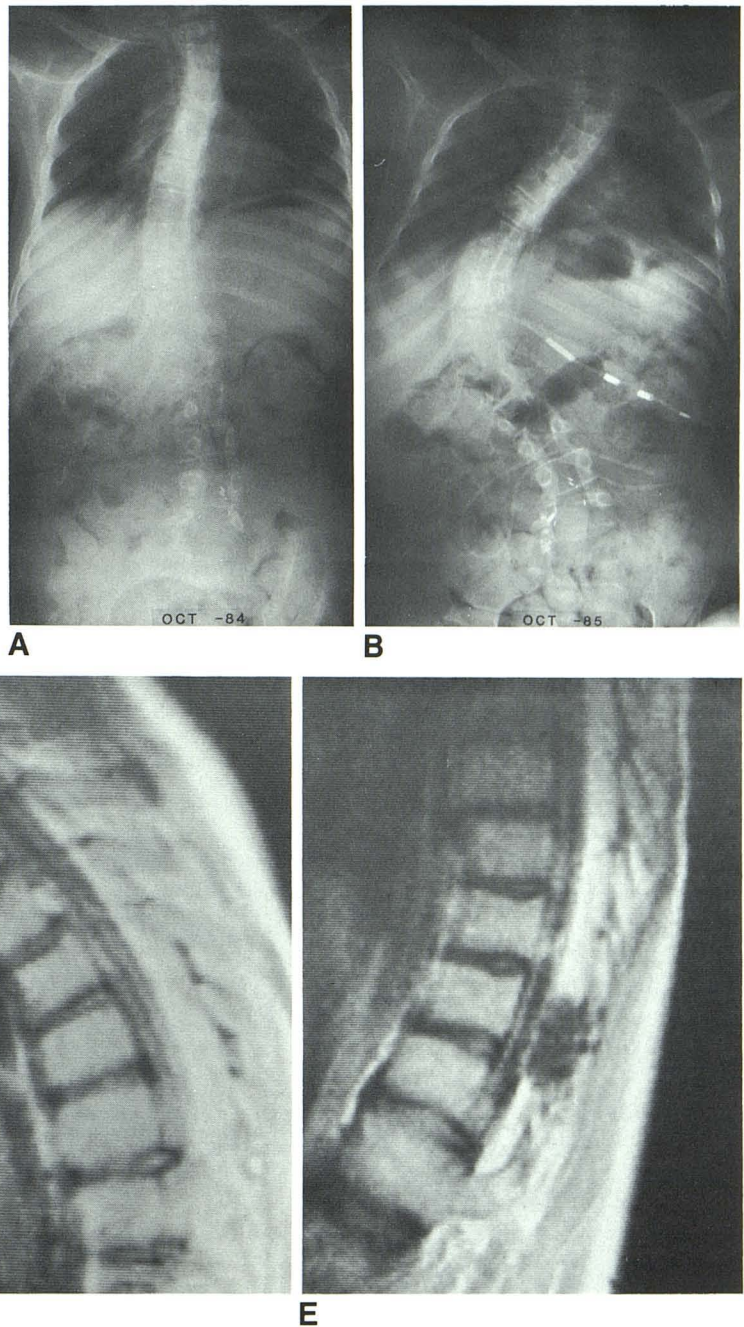
Five patients with atrophic spinal cords had narrow central cavities reaching from the upper thoracic region distally at

TABLE 1: Clinical and Radiologic Findings in Patients with Syringohydromyelia and Myelomeningocele

Case No.	Age	Gender	Level		HC	Shunt	Neurologic Signs Above Myelomeningocele				Spinal Cord Size	Location of Syringohydromyelia	Chiari Type
			Radiol	Neurol			Sensory Loss	Arm Weakness	Cranial Nerve Deficit	Scoliosis (degree)			
1	13	M	L4	T	—	+	+	+	—	T Dev (R 83)	W	C2–L5	I
2	11	F	L4	L3	—	+	+	+	+	T Dev (L 55)	W	C5–L5	II
3	17	M	T12	T	+	+	+	+	—	T Con (R 40)	W	C4–T8	II
4	32	F	L5	L5	SA	—	+	—	—	T Dev (R 16) TL (L 24)	W/A	T1–T2 T6–T8	II
5	16	M	L2	L2	—	+	—	+	—	TL Dev (R 17)	A	T5–T6	II
6	10	F	L4	L3	+	+	—	—	—	TL Dev (L 63)	A	T3–T10	II
7	25	F	L1	T	SA	—	—	—	—	T Dev (L 99)	A	T1–T12	II
8	23	F	L4	L4	SA	—	—	—	—	T Dev (R 84) TL (L 107)	A	T4–T12	II
9	13	F	S	S	+	Ext	—	—	—	TL Dev (R 11)	A	T1–L1	II
10	13	F	T12	T	—	+	—	—	—	T Dev (L 28) TL (R 52)	A	C5–T3	II
11	11	M	L4	L4	—	+	—	—	—	L Dev (R 10)	A	C2–C5	II
12	16	M	L5	L5	SA	—	—	—	—	TL Dev (R 13)	A	T11–L2	II

Note.—Radiologic level (radiol) is defined as the highest vertebral arch defect; neurologic level (neurol) is the functional neurologic level [16]; HC = hydrocephalus; T = thoracic; TL = thoracolumbar; S = sacral; W = widened; A = atrophic; R = right; L = left; Dev = developmental; Con = congenital; SA = spontaneously arrested; Ext = extirpated ventriculoperitoneal shunt.

Fig. 1.—Case 1: 13-year-old boy with developmental scoliosis and syringohydromyelia. Progression of scoliosis over 1 year (A and B) and extensive cavity (arrows) in spinal cord (C–E). B shows syrinx to peritoneal shunt.



least to the lower thoracic region (Fig. 3), while three patients had similar, less extensive cavities (Table 1).

#### Chiari Malformations

The prevalence of Chiari malformations was 100%. Two patients had type I and 28 had type II (Fig. 4) malformations. The fourth ventricle, cervicomedullary junction, and cerebellar ectopia were clearly seen on sagittal images. Although cortical bone gives no signal, the degree of subarachnoid space

narrowing at the foramen magnum was possible to assess due to obliteration of the cisterna cerebellomedullaris and the indentation made on the ectopic cerebellar tissue by the posterior rim of the foramen magnum.

The extent of the Chiari II malformation varied from the upper margin of C1 to the lower margin of C4. In all patients with this malformation, the brainstem and the cervicomedullary junction were more or less deformed. The "kinking" of the medulla was well seen in most patients but sometimes obscured by the lack of separation between the ectopic

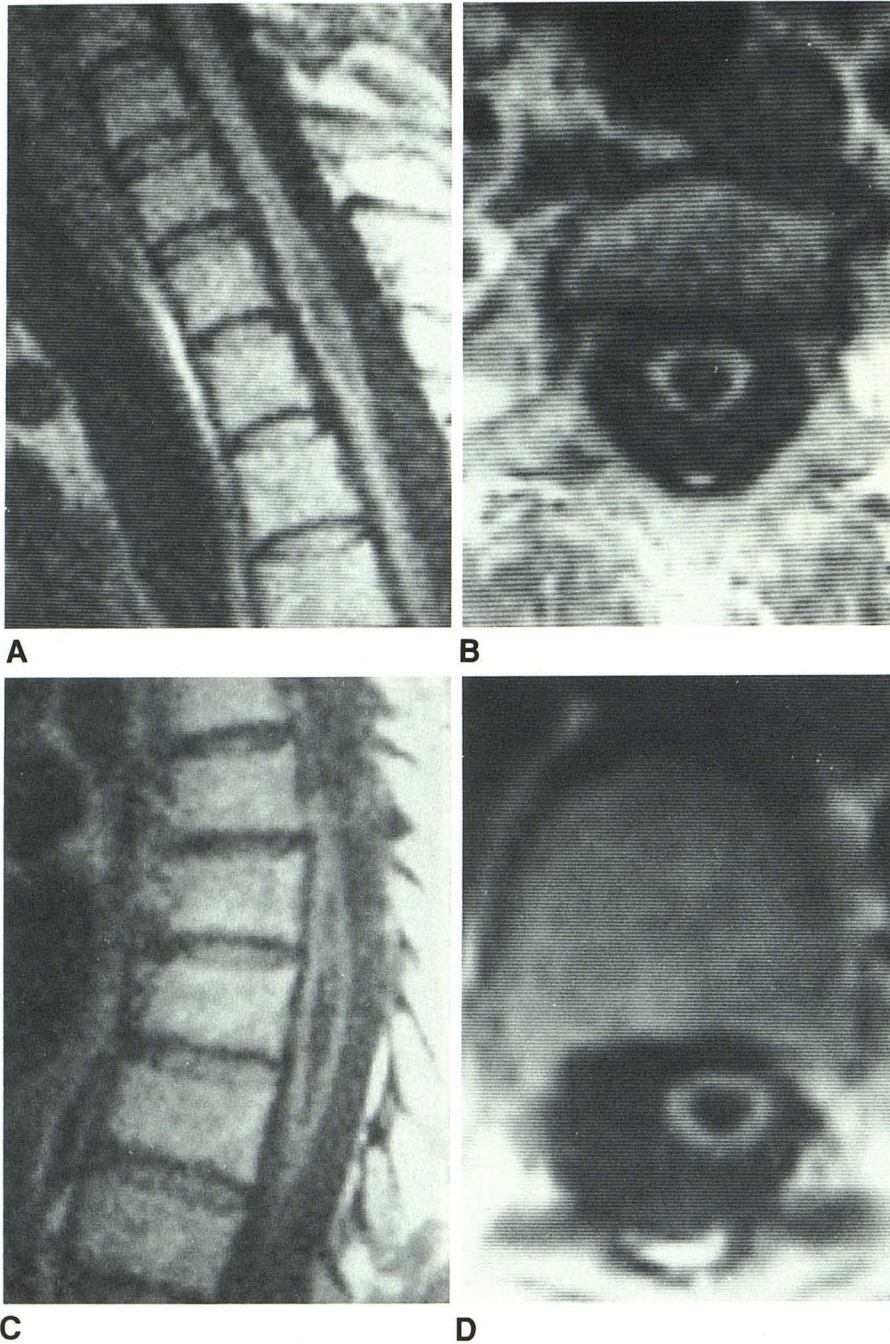


Fig. 2.—Case 4: 32-year-old woman with syringohydromyelia. Focally bulging thoracic spinal cord at T1-T2 on sagittal (A) and axial (B) views and at T6-T8 (C and D) due to cavities at two levels.

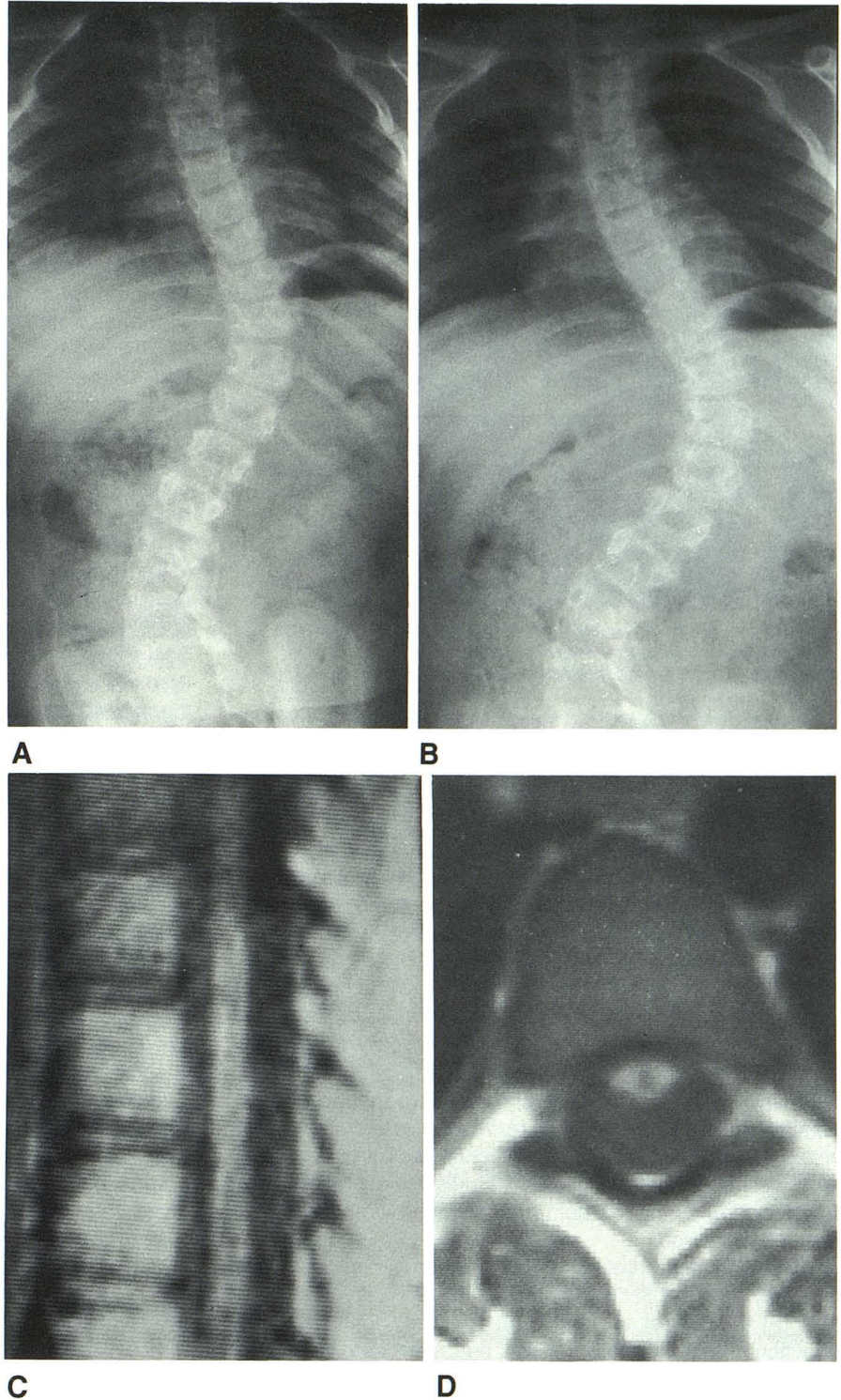
cerebellar tissue and the spinal cord. In two children 3 and 4 years old, there was a marked indentation on the posterior part of the brainstem and ectopic cerebellar tissue by the posterior arch of the atlas.

#### *Hydrocephalus*

Seventeen patients had clinically functioning ventriculoperitoneal shunts; of these, seven had hydrocephalus and 10 had normal or small ventricles. Seven of these 17 patients

had syringohydromyelia, in two cases in combination with hydrocephalus. One patient with a nonfunctional shunt had severe hydrocephalus, and two patients whose shunts were removed had moderate hydrocephalus. In nine of 10 patients with spontaneously arrested hydrocephalus there was a moderate to marked dilatation of the lateral ventricles and severe compression of the fourth ventricles; all nine had Chiari II malformation. The tenth patient had Chiari I malformation and moderate hydrocephalus. Syringohydromyelia was present in five of these 13 patients who had never been shunted or had extirpated or nonfunctional shunts.

Fig. 3.—Case 6: 10-year-old girl with developmental scoliosis and syringohydromyelia. Progression of scoliosis over 8 months (A and B) and central narrow syrinx in atrophic thoracic spinal cord on sagittal (C) and axial (D) views.



### Discussion

MR of the spinal cord requires proper techniques [17-23]. In patients with scoliosis this is done by examinations in multiple planes and angulated scans. Detection of small pathologic lesions requires thin and contiguous or overlapping

slices. Despite pronounced scoliosis and spinal cord atrophy it was possible to assess our patients for syringohydromyelia, but the examination was time-consuming with our current software and surface-coil technique.

In our study MR revealed syringohydromyelia in four patients with widened or bulging spinal cords and in eight

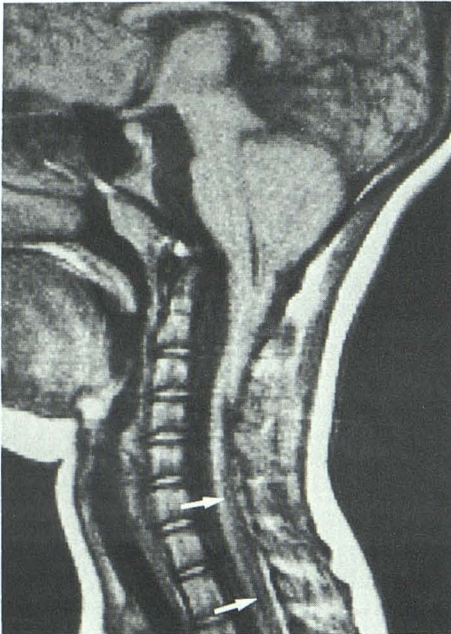


Fig. 4.—Case 10: 13-year-old girl with Chiari II malformation and limited syrinx (arrows) in lower cervical and upper thoracic spinal cord.

patients with atrophic spinal cords. The radiologic level of the myelomeningocele did not seem to affect the presence of cysts. This is in accordance with Hall et al. [9], who described a group of myelomeningocele children with syringohydromyelia, neurologic deficiencies, developmental scoliosis, and spontaneously arrested hydrocephalus. In some of their patients ventriculoperitoneal shunting resulted in both clinical and radiologic improvement.

We could not find any correlation between hydrocephalus and syringohydromyelia. Cavities were present in about the same proportion both in patients with clinically functioning shunts and no hydrocephalus and in those who had never been shunted who had moderate to severe hydrocephalus. This agrees with Park et al. [11], who reported 17 children with myelomeningocele, developmental scoliosis, and progressive neurologic deterioration studied with metrizamide CT myelography, all of whom had hydromyelia and/or brainstem compression.

The discrepancy between the number of syringohydromyelic cysts in our patients and the numbers reported by Hall et al. [9] and Park et al. [11] is probably partly due to different selection criteria, as their patients had more extensive neurologic deficiencies and functional losses. This is despite reports that syringohydromyelia is detected by metrizamide CT myelography in only about 80% of cases [17, 24, 25]. No reports discuss the critical size a cavity needs to be in order to be detected by this method [26, 27], and Park et al. [11] did not comment on this.

The prevalence of syringohydromyelia associated with myelomeningocele is unknown [28]. Based on necropsy studies of children under 3 years old it is reported to be 20–80% [29–

32], while Chiari malformations invariably are more common [29–36]. However, it is impossible to estimate the prevalence of syringohydromyelia, because, as in the studies of Hall et al. [9] and Park et al. [11], the subjects were selected from an unknown population. We found syringohydromyelia in 12 of 30 patients from a population of 160 myelomeningocele patients, yielding a prevalence of 40%, compared with the 0% prevalence before we used MR.

The relation between syringohydromyelia and developmental scoliosis in myelodysplastic patients is also unclear. It has been demonstrated that CSF flow into the spinal cord serves as a mechanism for compensation of hydrocephalus [9, 37], and Hall et al. [9] suggested that syringohydromyelia may be one cause of developmental scoliosis in patients without ventriculoperitoneal shunts. There is an established relation between scoliosis and syringohydromyelia in patients without myelomeningocele [38–44]. Scoliosis is probably caused by cavities in the spinal cord affecting lower motor neuron cells in the gray matter of the anterior horns, which innervate the muscles of the trunk [38, 43].

The two patients with the most rapid progression of thoracic scoliosis had low lumbar radiologic levels, widened spinal cords, and the most extensive syringohydromyelia. Scoliotic curves in this location and of this magnitude are normally absent in children of the same age with corresponding low lumbar levels. In one of these patients a syrinx to peritoneal shunt inserted to decompress the cavity failed to prevent progression of scoliosis (Fig. 1), probably due to spinal cord damage by the extensive cyst. This agrees with Hall et al. [9], who explained progression of scoliosis after ventriculoperitoneal shunting procedures in some of their patients by the possibility that the cyst had become independent of the ventricles when a critical size had been reached. A third patient with syringohydromyelia in an atrophic spinal cord also showed rapid progression of scoliosis (Fig. 3). These findings indicate that syringohydromyelia may contribute to the development of scoliosis in myelomeningocele, as was suggested by Hall et al. [9]. Park et al. [11] found that decompression of the hindbrain in combination with the obex plugging procedure led to resolution of spasticity and increase in motor strength, but they did not comment on the effect of their treatment on scoliosis.

In all four patients with widening or bulging of the spinal cord due to syringohydromyelia there was good clinical correlation between the extent of the cavities and the neurologic deficits. They were all characterized by sensory losses, and three of them exhibited upper extremity weakness and atrophy in muscles above the myelomeningocele. This contrasts with the eight patients with syringohydromyelia in atrophic spinal cords. Only one of them had neurologic deficiencies, which were characterized by spastic paresis of the upper extremities, probably caused by brainstem compression in the foramen magnum. The fact that acquired neurologic deficits were found mainly in patients with large cavities in widened cords suggests that syringohydromyelia in myelomeningocele patients may be caused by a slow widening of the central canal, perhaps due to compensation of hydrocephalus.

The Chiari malformations were mainly of type II [29–31, 35, 36, 45] and were invariably present, compared with a 46% prevalence before MR was used. In three patients severe compression and indentation of the brainstem by the posterior rim of the foramen magnum and the posterior arch of the atlas caused spastic paresis of the extremities. Another two patients developed multiple cranial nerve deficiencies due to brainstem compression or deformation. All five patients had the Chiari II malformation. However, a recent investigation [46] with MR imaging of the Chiari I malformation without myelomeningocele [47, 48] indicates that Chiari I changes are similar to those of Chiari II, but to a lesser degree. There is other evidence that the Chiari II deformity is only a severe form of the type I variety [35, 49]. The suggestion that development of cysts in the spinal cord is correlated to the degree of caudal movement of the brainstem and the cerebellar tissue [36] could not be confirmed, perhaps due to atrophy of the cerebellar spur in older patients.

All our patients had Chiari malformations, and many of them also had eye-movement disorders caused by brainstem lesions discovered clinically and by neurophysiologic investigations. It has been suggested that scoliosis might develop as a consequence of disturbance of the central mechanism of the postural reflexes in the brainstem [50, 51]. Because of the back lesion, all our patients had poor postural reflexes from levels below the myelomeningocele. The combination of disturbed feedback and Chiari malformations with deformation and compression of the brainstem may also contribute to scoliosis in myelomeningocele patients besides syringomyelia.

In conclusion, our experience with MR imaging of the brain and spinal cord in myelomeningocele indicates that syringomyelia and Chiari malformations probably are more common than has been recognized. These conditions may cause developmental scoliosis, loss of ambulation, impaired extremity function, and cranial nerve paralysis. MR allows a noninvasive analysis of these lesions, even in patients with severe scoliosis. Myelomeningocele patients with rapidly progressing scoliosis, or with high scoliosis in association with low neurologic or radiologic levels, should be examined with MR of the brainstem and spinal cord to search for these lesions, as should patients with acquired neurologic deficits above the myelomeningocele.

## REFERENCES

- Raycroft JF, Curtis BH. Spinal curvature in myelomeningocele. Natural history and etiology. In: *The American Academy of Orthopedic Surgeons symposium on myelomeningocele*. St Louis: Mosby, 1972:186–201
- Hoffer M, Feiwell E, Perry R, Perry J, Bonnett C. Functional ambulation in patients with myelomeningocele. *J Bone Joint Surg [Am]* 1973;55:137–148
- Asher M, Olson J. Factors affecting the ambulatory status of patients with spina bifida cystica. *J Bone Joint Surg [Am]* 1983;165:350–356
- Stillwell A, Menelaus MB. Walking ability in mature patients with spina bifida. *J Pediatr Orthop* 1983;3:184–190
- Bunch WH, Cass AS, Bensman AS, Long DM. Orthopedic approaches. In: *Modern management of myelomeningocele*. St. Louis, Green, 1972:121–180
- Shurtleff DB, Goiney R, Gordon LH, Livermore N. Myelodysplasia: the natural history of kyphosis and scoliosis. A preliminary report. *Dev Med Child Neurol [Suppl]* 1976;18[37]:126–133
- Piggott H. The natural history of scoliosis in myelodysplasia. *J Bone Joint Surg [Br]* 1980;62:54–58
- Batnitzky S, Hall PV, Lindseth RE, Wellman HN. Meningomyelocele and syringohydromyelia. Some radiological aspects. *Radiology* 1976;120:351–357
- Hall PV, Lindseth RE, Turner ML, Campbell RL, Mealy J Jr. Alterations in cerebrospinal fluid dynamics in syringomyelia, hydromyelia and myelomeningocele. *Neurobiol Cerebrospinal Fluid* 1983;2:895–911
- Sherk PS, Pasquariello PS, Charnley E, Schut L. Central nervous system lesions and developmental scoliosis in myelomeningocele. *Z Kinderchir* 1983;38[suppl 2]:87–89
- Park TS, Cail WS, Maggio WM, Mitchell DC. Progressive spasticity and scoliosis in children with myelomeningocele. Radiological investigation and surgical treatment. *J Neurosurg* 1986;62:367–375
- Wickramasinghe SF, Eckstein HB, Nixon HH. Posterior fossa decompression in shunt-treated hydrocephalic children. *Dev Med Child Neurol [Suppl]* 1968;10[15]:11–13
- Hoffman HJ, Hendrick EB, Humphreys RP. Manifestations and management of Arnold-Chiari malformation in patients with myelomeningocele. *Childs Brain* 1975;1:255–259
- Nordqvist L. The sagittal diameter of the spinal cord and subarachnoid space in different age groups. A roentgenographic post-mortem study. *Acta Radiol [Suppl]* (Stockh) 1964;227:38–58
- Cobb JR. Outline for the study of scoliosis. In: *Instructional course lectures*, vol 5. *The American Academy of Orthopedic Surgeons*. Ann Arbor: Edwards, 1948:261–275
- Lindseth RE. Treatment of the lower extremity in children paralyzed by myelomeningocele (birth to 18 months). In: *Instructional course lectures*, vol 25. *The American Academy of Orthopedic Surgeons*. St. Louis, Mosby, 1976:76–82
- Yeates A, Brant-Zawadzki M, Norman D, Kaufman L, Crooks LE, Newton TH. Nuclear magnetic resonance imaging of syringomyelia. *AJNR* 1983;4:234–237
- Johnson MA, Pennock JM, Bydder GM, et al. Clinical NMR imaging of the brain in children: normal and neurologic disease. *AJNR* 1983;4:1013–1026, *AJR* 1983;141:1005–1018
- Bradley WG Jr. Magnetic resonance imaging of the central nervous system. *Neurol Res* 1984;6:91–106
- Pojunas K, Williams AL, Daniels DL, Houghton VM. Syringomyelia and hydromyelia: magnetic resonance evaluation. *Radiology* 1984;153:679–683
- Lee BCP, Deck MDF, Kneeland JB, Cahill PT. MR imaging of the cranio-cervical junction. *AJNR* 1985;6:209–213
- Lee BCP, Zimmerman RD, Manning JJ, Deck MDF. MR imaging of syringomyelia and hydromyelia. *AJNR* 1985;6:221–228, *AJR* 1985;144:1149–1156
- Han JS, Benson JE, Kaufman B, et al. MR imaging of pediatric cerebral abnormalities. *J Comput Assist Tomogr* 1985;9(1):103–114
- Aubin ML, Vignaud J, Jardin C, Bar D. Computed tomography in 75 clinical cases of syringomyelia. *AJNR* 1981;2:199–204
- Quencer RM, Morse BMM, Green BA, Eismont FJ, Brost P. Intraoperative spinal sonography: adjunct to metrizamide CT in the assessment and surgical decompression of posttraumatic spinal cord cyst. *AJNR* 1984;5:71–79, *AJR* 1984;142:593–601
- Pettersson H, Harwood-Nash DCF. *CT and myelography of the spine and cord. Techniques, anatomy and pathology in children*. Berlin: Springer-Verlag, 1982
- Stanley P, Senac MO Jr, Segall HD, Park TS. Syringohydromyelia following meningomyelocele surgery—role of metrizamide myelography and computed tomography. *Pediatr Radiol* 1984;14:278–283
- Menelaus M. The spine. In: *The orthopaedic management of spina bifida cystica*. Edinburgh: Churchill Livingstone, 1980:152–187
- Cameron AH. The Arnold-Chiari malformation and other neuroanatomical malformations associated with spina bifida. *J Pathol* 1957;73:195–211
- Daniel PM, Strich SJ. Some observations on the congenital deformity of the central nervous system known as the Arnold-Chiari malformation. *J Neuropathol Exp Neurol* 1958;17:255–266
- Peach B. Arnold-Chiari malformation. Anatomic features of 20 cases. *Arch Neurol* 1965;12:613–621
- Emery JL. The back lesions, lipomas and dermoids. In: *The American*



- Academy of Orthopedic Surgeons symposium on myelomeningocele*. St Louis: Mosby, 1972:41-49
33. Andersson H, Carlsson CA, Rosengren K. A radiological study of the central canal in myelomeningocele. *Dev Med Child Neurol [Suppl]* 1967;9[13]:96-102
  34. MacKenzie NG, Emery JL. Deformities of the cervical cord in children with neurospinal dysraphism. *Dev Med Child Neurol [Suppl]* 1971;13 [25]:58-67
  35. Chiari H. Über Veränderungen des Kleinhirns infolge von Hydrocephalie des Grosshirns. *Dtsch Med Wochenschr* 1891;17:1172-1175
  36. Emery JL, MacKenzie N. Medullo-cervical dislocation deformity (Chiari II deformity) related to neurospinal dysraphism (meningomyelocele). *Brain* 1973;96:155-162
  37. Winston K, Hall J, Johnsson D, Micheli L. Acute elevation of intracranial pressure following transection of non-functional spinal cord. *Clin Orthop* 1977;128:41-44
  38. Huebert HT, MacKinnon WB. Syringomyelia and scoliosis. *J Bone Joint Surg [Br]* 1969;51:338-343
  39. Williams B. Current concepts of syringomyelia. *Br J Hosp Med* 1970;3:331-341
  40. Ballantine HT Jr, Ojemann RG, Drew JH. Syringohydromyelia. *Prog Neurol Surg* 1971;4:227-245
  41. Foster JB. Hydromyelia. In: Vinken PJ, Bruyn GW, Myrianthopoulos NC, eds. *Handbook of clinical neurology*, vol 32. Amsterdam: Elsevier/North-Holland Biomedical, 1978:231-237
  42. Schliep G. Syringomyelia and syringobulbia. In: Vinken PJ, Bruyn GW, Myrianthopoulos NC, eds. *Handbook of clinical neurology*, vol 32. Amsterdam: Elsevier/North-Holland Biomedical, 1978:255-327
  43. Williams B. Orthopaedic features in the presentation of syringomyelia. *J Bone Joint Surg [Br]* 1979;61:314-323
  44. Baker AS, Dove J. Progressive scoliosis as the first presenting sign of syringomyelia. Report of a case. *J Bone Joint Surg [Br]* 1983;65:472-473
  45. Naidich TP, McLone DG, Fulling KH. The Chiari II malformation: Part IV. The hindbrain deformity. *Neuroradiology* 1983;25:179-197
  46. Spinos E, Laster DW, Moody DM, Ball MR, Witcofski RL, Kelly DL Jr. MR evaluation of Chiari I malformations at 0.15 T. *AJNR* 1985;6:203-208, *AJR* 1985;144:1143-1148
  47. Paul KS, Lye RH, Strang FA, Dutton J. Arnold-Chiari malformation. *J Neurosurg* 1983;58:183-187
  48. Levy WJ, Mason L, Hahn JF. Chiari malformation presenting in adults: a surgical experience in 127 cases. *J Neurosurg* 1983;12(4):377-390
  49. Variend S, Emery JL. Cervical dislocation of the cerebellum in children with meningomyelocele. *Teratology* 1976;13:281-290
  50. Sahlstrand T, Petruson B, Örtengren R. Vestibulospinal reflex activity in patients with adolescent idiopathic scoliosis. *Acta Orthop Scand* 1979;50:272-281
  51. Yamada H, Ikata T, Yamamoto H, Nakagana Y, Tanaka H, Tezuka A. Equilibrium function in scoliosis and active corrective plaster jacket for the treatment. *Tokushima J Exp Med* 1969;16:1-7