

Are your **MRI contrast agents** cost-effective?

Learn more about generic **Gadolinium-Based Contrast Agents**.



FRESENIUS
KABI

caring for life

AJNR

**MR imaging vs CT in subacute sclerosing
panencephalitis.**

K Tsuchiya, T Yamauchi, S Furui, Y Suda and E Takenaka

AJNR Am J Neuroradiol 1988, 9 (5) 943-946

<http://www.ajnr.org/content/9/5/943>

This information is current as
of April 27, 2024.

MR Imaging vs CT in Subacute Sclerosing Panencephalitis

Kazuhiro Tsuchiya¹
Teiyu Yamauchi
Shigeru Furui
Yoshio Suda
Eiichi Takenaka

The MR findings in three patients with subacute sclerosing panencephalitis were reviewed and compared with CT findings in the same patients. Long-T2 lesions were demonstrated in each case, although their distribution varied with the clinical stage of the disease. MR, especially T2-weighted imaging, appears to be of great utility in the assessment of subacute sclerosing panencephalitis.

Subacute sclerosing panencephalitis (SSPE) is a slowly progressive and fatal encephalitis that is believed to be caused by measles virus. There have been many reports on CT features of SSPE [1-7], but little has been written about its MR findings [8]. We describe MR findings in three patients in different clinical stages of SSPE and compare these with the CT findings.

Materials and Methods

MR and CT images were reviewed in three patients with SSPE diagnosed from clinical findings, immunologic examinations, and electroencephalograms. The patients were diagnosed as being in stages II, III, and IV, respectively, according to the four clinical stages described by Jabbour et al. [9].

MR studies were performed with a prototype superconducting imager operating at 1.5 T.* Scans were obtained in axial planes using T1-weighted, 500/41 or 43 (TR/TE), and T2-weighted, 1800/80 or 100 (TR/TE), spin-echo sequences.

Results

Case 1 (Stage II)

A 12-year-old girl had an unexplained fall, loss of consciousness, and tonic-clonic convulsions 3 months before the first CT and MR studies. She was admitted to our hospital 1 month after the onset, when her measles antibody titers in the serum and CSF were elevated and her EEG showed characteristic periodic SSPE complexes. CT scans and T1-weighted MR images demonstrated no definite abnormalities (Figs. 1A-1C). On T2-weighted MR images, markedly increased intensity was noted bilaterally in the white matter of the cerebral hemispheres and cerebellum (Figs. 1D-1G). Follow-up CT scans and T2-weighted MR images were obtained 6 months later, when the patient's neurologic status had deteriorated slightly but was still diagnosed as being in stage II. Lesions of increased intensity (barely detected on CT) were found in the putamen bilaterally, and the distribution of increased intensity in the cerebral hemispheres was reduced (Figs. 1H-1K).

Received September 11, 1987; accepted after revision December 1, 1987.

Presented at the annual meeting of the American Society of Neuroradiology, New York, May 1987.

¹ All authors: Department of Radiology, National Defense Medical College, 3-2, Namiki, Tokorozawa, Saitama, 359, Japan. Address reprint requests to K. Tsuchiya.

AJNR 9:943-946, September/October 1988

0195-6108/88/0905-0943

© American Society of Neuroradiology

* Mitsubishi Electric, Tokyo, Japan.

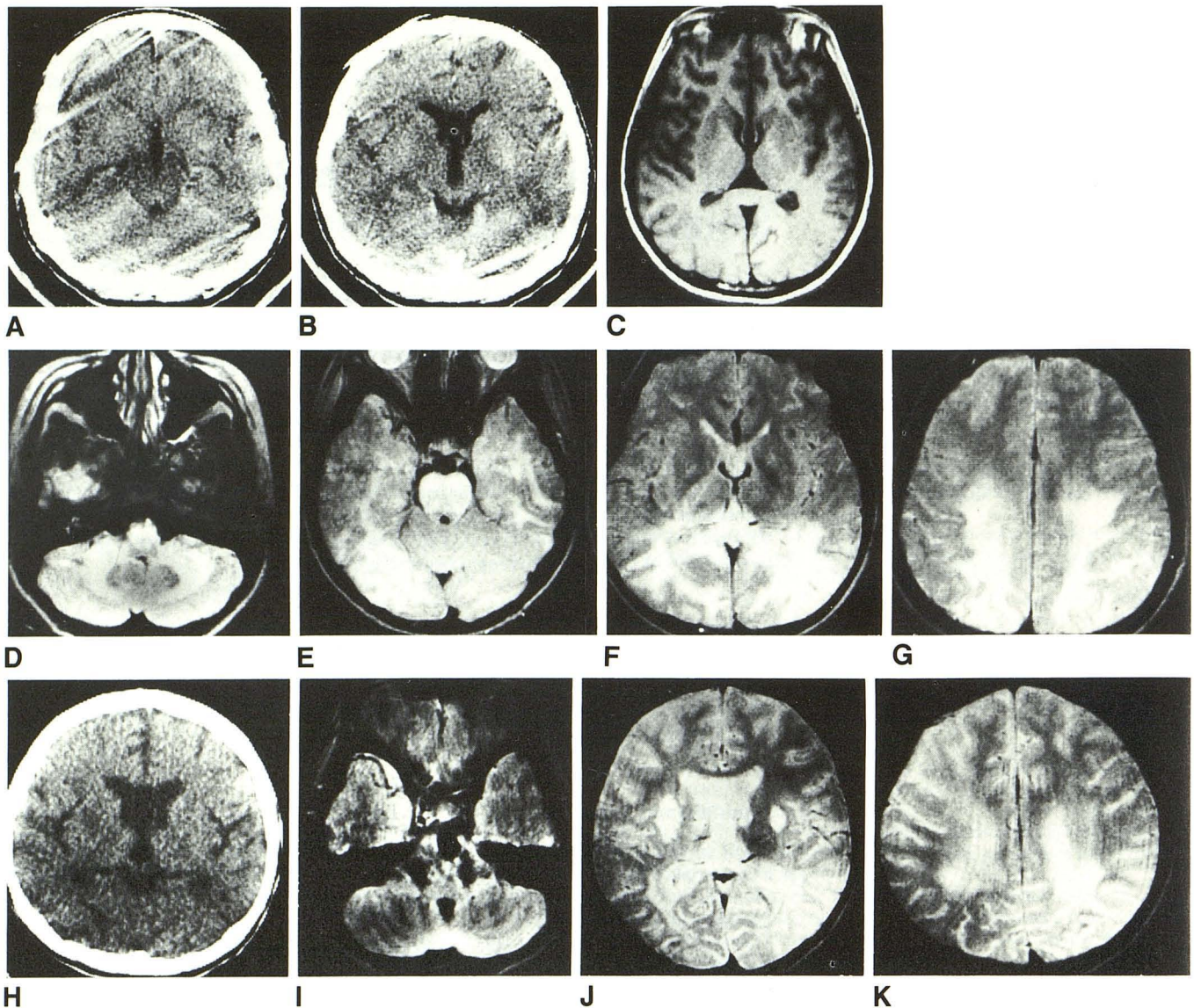


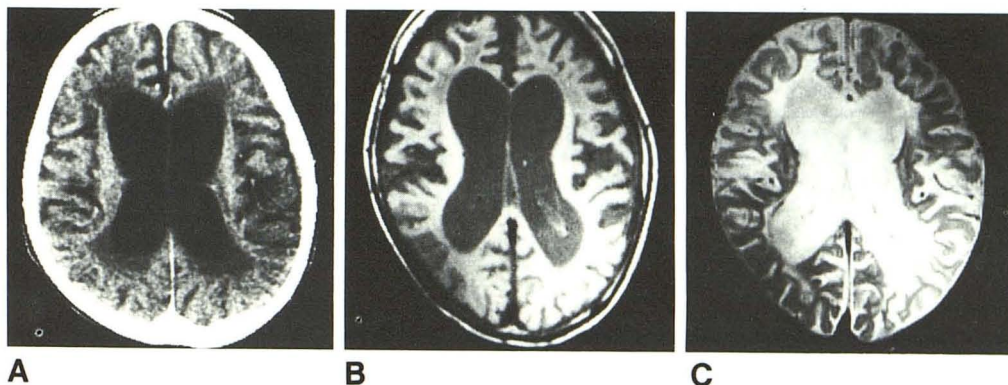
Fig. 1.—Case 1: 12-year-old girl with stage-II subacute sclerosing panencephalitis (3 months duration).
 A and B, Contrast-enhanced CT scans show no definite abnormalities.
 C, T1-weighted MR image (SE 500/41) reveals no abnormal intensity.
 D–G, T2-weighted MR images (SE 1800/100) demonstrate increased intensity in white matter of cerebellum; in anterior pons; and in white matter of temporal, occipital, and parietal lobes bilaterally.
 H, Follow-up CT scan obtained 6 months after A–G, when patient was still in stage II. Low-density lesion is noted in right putamen.
 I–K, Follow-up T2-weighted MR images (SE 1800/100) obtained at the same time as H show lesions of increased intensity in putamen bilaterally. The distribution of increased intensity in cerebral hemispheres has been reduced and the increased intensity in cerebellum has disappeared.

Case 2 (Stage III)

An 8-year-old boy developed progressive mental retardation 2½ years before CT and MR studies, when the diagnosis of SSPE was established on the findings of EEG and immunologic examinations. At the time of CT and MR studies, he

showed opisthotonus, opsoclonus, rigospastic tetraplegia, and severe mental retardation. His CT revealed low-density lesions in the periventricular white matter, which showed slightly decreased intensity on T1-weighted MR images and markedly increased intensity on T2-weighted MR images (Fig. 2). Atrophy of the cerebral hemispheres was also noted.

Fig. 2.—Case 2: 8-year-old boy with stage-III subacute sclerosing panencephalitis (30 months duration). Contrast-enhanced CT (A) shows brain atrophy and slight low density in periventricular white matter, which is not shown on T1-weighted MR image (SE 500/41) (B). On T2-weighted MR image (SE 1800/100) (C), markedly increased intensity is demonstrated in periventricular white matter in frontal region and, to a lesser degree, in occipital region.



Case 3 (Stage IV)

A 16-year-old boy with the longest clinical course (5 years and 10 months) in our series had been in stage-IV SSPE for 3½ years. His symptoms included akinetic mutism, and his CT scans and MR images were quite similar to those of case 2.

Discussion

SSPE is a rare encephalitis that primarily affects children between the ages of 5 and 12 years of age. It is believed to be a slow virus infection caused by measles virus. In most cases, patients with SSPE have had clinical measles before the age of 3 years.

The disease typically starts with mental or behavioral abnormalities (stage I) and then progresses to include motor signs such as myoclonic jerks, convulsions, tremors, and so forth (stage II). These are followed by coma and opisthotonus (stage III) and then by mutism, occasional myoclonus, and loss of cerebral cortical function (stage IV). The course in classical form takes from 1 to 3 years. In our case 3, the disease had been present for over 5½ years.

Pathologically, both gray and white matter are involved in SSPE. In the gray matter, gliosis and perivascular infiltration of lymphocytes are found. Demyelination of variable degrees and gliosis are seen in the white matter. Eosinophilic inclusion bodies are often found in oligodendrocytes and neural cells in the cortex. Pathologic changes are also found in the caudate nucleus, putamen, globus pallidus, pons, and thalamus.

The diagnosis of SSPE is established by clinical manifestations, presence of abnormal complexes on EEG, and laboratory findings including high levels of CSF gamma globulin and elevated titers of measles antibodies in the CSF and serum. Radiologic evaluation of patients with SSPE has elicited many reports on CT features of SSPE [1–7]. Pedersen and Wulff [6] described brain swelling demonstrated on CT in the early stage of SSPE, and cortical atrophy has been reported in relatively advanced cases [3, 4]. In addition, low-

density lesions have been reported in the white matter and basal ganglia [1, 3, 5]. These were attributed to necrosis, demyelination, and gliosis by Onoda et al. [1], and to gliosis and atrophy by Duda et al. [3]. Schoeman et al. [5] stated that lymphocytic infiltration, demyelination, and gliosis were observed in biopsied specimens obtained from lesions that showed low density on CT.

Takemoto et al. [8] reported the MR findings in four cases of stage-II SSPE. Each of their cases revealed lesions showing decreased intensity on T1-weighted images and increased intensity on T2-weighted images. They emphasized the superior sensitivity of MR imaging to CT in demonstrating lesions in the white matter and basal ganglia. We could also detect lesions in the white matter as areas of increased intensity on T2-weighted images. On CT, they were either undetected or obscure. Lesions in the putamen and cerebellum, which were previously described in Takemoto et al. [8], have not been reported in the literature on CT of SSPE. In addition, there has been no description of abnormalities in the brainstem demonstrated either by CT or MR imaging (case 1). We agree with Takemoto et al. [8] that abnormal signals on MR probably reflect demyelination and gliosis. However, the disappearance of high signal in the second study of case 1 may suggest that the high signal represents, at least in the early stage, reversible changes such as inflammation.

As stated, the diagnosis of SSPE is based on clinical manifestations, EEG, and laboratory findings. Findings on CT and MR imaging cannot be considered specific. However, because MR, especially T2-weighted imaging, appears to have greater sensitivity than CT, it can be of use in the clinical assessment of SSPE.

REFERENCES

1. Onoda M, Takahashi A, Shiozawa Z, Sobue I. A clinical evaluation of computed tomography in subacute sclerosing panencephalitis. *Neurol Med Chir (Tokyo)* 1978;8:84–87
2. Murata R, Hayashi M, Sugita K, Yoshida R, Fujii K. CT scan of subacute sclerosing panencephalitis. *J Pediatr Prac* 1979;42:605–610
3. Duda EE, Huttenlocker PR, Patronas NJ. CT of subacute sclerosing

- panencephalitis. *AJNR* **1980**;1:35-38
4. Manabe Y, Ono Y, Okuno T, Ueda T. Serial CT scans in subacute sclerosing panencephalitis. *J Comput Tomogr* **1981**;5:25-30
 5. Schoeman JF, Bezing K-LV, Hewlett RH. Correlative clinical, neuroradiological and pathological findings in subacute sclerosing panencephalitis. A report of 5 cases. *S Afr Med J* **1982**;62:447-450
 6. Pedersen H, Wulff CH. Computed tomographic findings of early subacute sclerosing panencephalitis. *Neuroradiology* **1982**;23:31-32
 7. Krawiecki NS, Dyken PR, Gammal TE, DuRant RH, Swift A. Computed tomography of the brain in subacute sclerosing panencephalitis. *Ann Neurol* **1984**;15:489-493
 8. Takemoto K, Koizumi Y, Kogame S, et al. Magnetic resonance imaging of subacute sclerosing panencephalitis. *Jpn J Clin Radiol* **1986**;31:999-1004
 9. Jabbour JT, Garcia JH, Lemmi H, Ragland J, Duenas DA, Sever JL. Subacute sclerosing panencephalitis. A multidisciplinary study of eight cases. *JAMA* **1969**;207:2248-2254