

Are your MRI contrast agents cost-effective?
Learn more about generic Gadolinium-Based Contrast Agents.



AJNR

**Flexion Teardrop Fracture of the Cervical Spine:
Radiographic Characteristics**

Kwang S. Kim, Harry H. Chen, Eric J. Russell and Lee F. Rogers

AJNR Am J Neuroradiol 1988, 9 (6) 1221-1228

<http://www.ajnr.org/content/9/6/1221>

This information is current as
of April 24, 2024.

Flexion Teardrop Fracture of the Cervical Spine: Radiographic Characteristics

Kwang S. Kim¹
 Harry H. Chen
 Eric J. Russell
 Lee F. Rogers

Teardrop fracture of the cervical spine is a confusing and loosely used term, often referring to any fracture with a triangular fragment in the involved body. The flexion teardrop fracture is a specific entity that should not be confused with other types of injury with a teardrop fragment. In a radiographic analysis of 45 patients with flexion teardrop fracture, the most characteristic feature was posterior displacement of the upper column of the divided cervical spine, observed in 78% of the cases. Other radiographic characteristics included backward displacement of the posterior fragment of the involved body, widening of the interlaminar and interspinous spaces, widening of the facet joint with backward displacement of the inferior facet, and kyphotic deformity of the cervical spine at the level of injury. The injury was frequently associated with sagittal-body and lamina fractures and occurred predominantly at the C5 level.

The flexion teardrop fracture (FTDF) is a common injury of the cervical spine that often has a devastating outcome [1–3]. Its name is derived from the characteristic triangle-shaped fragment that fractures from the anteroinferior corner of the vertebral body, and that resembles a drop of water dripping from the vertebral body. The posterior fragment of the divided body is displaced backward into the spinal canal. The lesion is also characterized by complete disruption of both the anterior and posterior ligamentous structures, resulting in marked instability at the site of injury [4].

The characteristic neurologic injury accompanying the FTDF is the anterior cord syndrome. This syndrome consists of quadriplegia with loss of pain, temperature, and touch sensations, and preservation of the posterior column senses of position, motion, and vibration [1, 4].

Neurologic consequences are usually severe with the FTDF; however, in some cases there are incomplete deficits or even intact neurologic status [2, 5]. Radiographic diagnosis of this unstable injury is, therefore, therapeutically important. Unfortunately, diagnostic confusion exists between the FTDF and other fractures with a teardrop fragment. While the radiographic features of FTDF have been described by many authors since the initial description by Schneider and Kahn in 1956 [4], there has been no comprehensive radiographic description of this entity in the literature. We present a complete radiographic analysis of 45 patients with FTDF and discuss the characteristic and differential features of FTDF as compared with other fractures with a teardrop fragment.

Subjects and Materials

We reviewed the records of 45 patients with flexion teardrop fractures who were admitted to the Midwest Spinal Cord Injury Unit of the Northwestern Memorial Hospital between May 1982 and June 1987. The cases were selected on the basis of availability of lateral radiographs, polytomograms, and medical records. Most of the cases were referred from outlying community hospitals, and the initial lateral radiograph was available for review in 20 cases. Serial lateral radiographs and anteroposterior and lateral views of polytomograms,

This article appears in the November/December 1988 issue of *AJNR* and the February 1989 issue of *AJR*.

Received December 2, 1987; accepted after revision March 8, 1988.

¹ All authors: Department of Diagnostic Radiology, Northwestern Memorial Hospital and Northwestern University Medical School, Olson Pavillion, 710 N. Fairbanks Court, Chicago, IL 60611. Address reprint requests to K. S. Kim.

AJNR 9:1221–1228, November/December 1988
 0195–6108/88/0906–1221

© American Society of Neuroradiology

obtained after traction tongs were applied, were available in all cases. The purpose of polytomography as a requirement for selection of the cases was to analyze all components of the injury that might not have been revealed on the plain cervical films. The diagnosis of FTDF was based on the characteristic appearance of the involved body and on evidence of disruption of the anterior and posterior ligamentous structures as described by Schneider and Kahn [4] and others [1, 5, 6]. In five cases, CT was available for review. Sagittal images were reformatted from the 3-mm axial slices.

FTDF was the result of diving accidents in 18 cases (40%), motor vehicle accidents in 13 cases (29%), falls in 12 cases (27%), and other types of injury in two cases (4%). The neurologic status after injury was complete quadriplegia in 25 cases (56%), incomplete quadriplegia in 14 cases (31%), and intact in six cases (13%).

Results

The Vertebral Body

In the lateral view, the involved vertebral body was divided into two fragments: the smaller anterior triangular fragment and the larger posterior fragment. The anterior aspect of the anterior fragment was generally aligned with that of the ver-

tebral body below, although in some cases it was displaced and rotated anteriorly beyond the anterior vertebral body line. In all cases, the posterior inferior aspect of the posterior fragment was displaced backward in relation to the superior aspect of the vertebral body below (Figs. 1–6). The displacement varied from 1 mm to the total body width, and was reduced by varying degrees after application of traction tongs (Figs. 3B, 5A, 5B). However, the posterior displacement was evident on at least one of the serial lateral radiographs or on the polytomogram during application of traction tongs. The superior aspect of the posterior fragment, on the other hand, was in normal alignment with the inferior aspect of the vertebral body above in all but four cases (91%). In these four cases, the backward displacement of the superior aspect was much less than that of the inferior aspect. The fractured vertebral body showed an anterior wedging deformity in 39 (87%) of 45 cases.

Signs of Ligamentous Disruption

In addition to fragmentation of the vertebral body with backward displacement of the posterior fragment, another

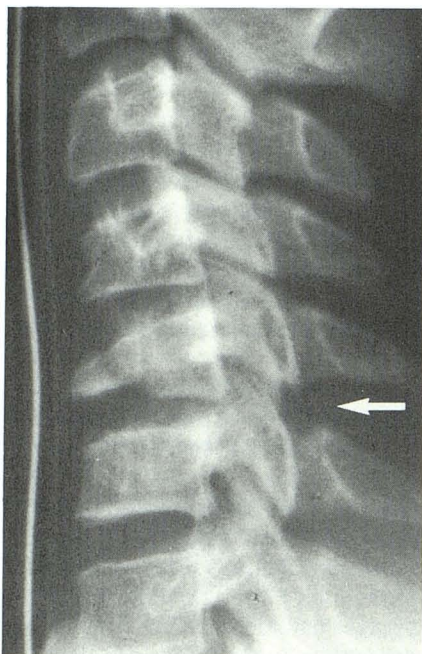


Fig. 1.—14-year-old with incomplete quadriplegia at C6 as a result of diving accident. Lateral radiograph, obtained after traction tongs are applied, shows flexion teardrop fracture at C5 with a mild degree of kyphotic angulation. Posterior fragment is slightly displaced backward in inferior aspect; disk space between posterior fragment and vertebral body below is narrowed; interlaminar and interspinous spaces are widened at C5–C6 (arrow); C5–C6 facet joint is widened; and fractured C5 body shows anterior wedging deformity. There is also compression deformity in anteroinferior aspect of C4 body.

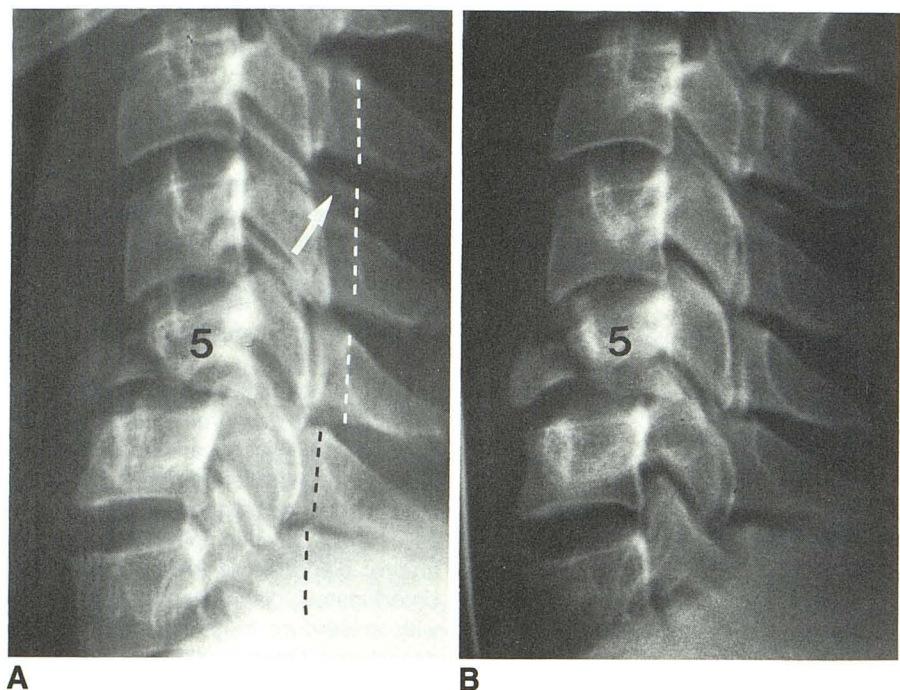


Fig. 2.—28-year-old man with incomplete quadriplegia at C6 as a result of falling accident. A, Lateral radiograph, obtained before traction tongs are applied, shows flexion teardrop fracture at C5 with backward displacement of posterior fragment in inferior aspect. Interlaminar and interspinous spaces are not widened; spinolaminar line of upper column (white dashed line) is displaced backward in relation to that of lower column (black dashed line); there is a moderate degree of kyphotic deformity at level of injury; and disk space between posterior fragment and vertebral body below is narrowed while the disk space between anterior fragment and vertebral body below is normal. There are sagittal fractures in C5 and C6 bodies, and multiple laminar fractures at C4, C5, and C6 (not shown except for C4 laminar fracture, which is indicated by arrow). There is also prevertebral soft-tissue swelling. B, Lateral radiograph, obtained after traction tongs have been applied, shows that kyphotic angulation and posterior displacement of spinolaminar line of upper column are improved. However, backward displacement of posterior fragment of fractured body and a slight degree of posterior displacement of spinolaminar line of upper column are still appreciated.

Fig. 3.—29-year-old man with complete quadriplegia at C5 as a result of motor vehicle accident.

A, Lateral radiograph, obtained before traction tongs are applied, shows flexion teardrop fracture at C5 with a marked degree of backward displacement of posterior fragment of fractured body. Inferior facet of C5 (arrow) is displaced backward in relation to superior facet of C6. Interlaminar and interspinous spaces are widened at C5–C6; spinolaminar line of upper column is displaced posteriorly in relation to that of lower column; and disk space between posterior fragment and vertebral body is lost while disk space between anterior fragment and vertebral body below is normal. The anterior fragment is aligned with lower column, and there is widening of prevertebral soft-tissue space.

B, Lateral polytomogram, obtained after traction tongs have been applied, shows that backward displacement of posterior fragment of fractured body and posterior offset of spinolaminar line of upper column are improved but still persist.

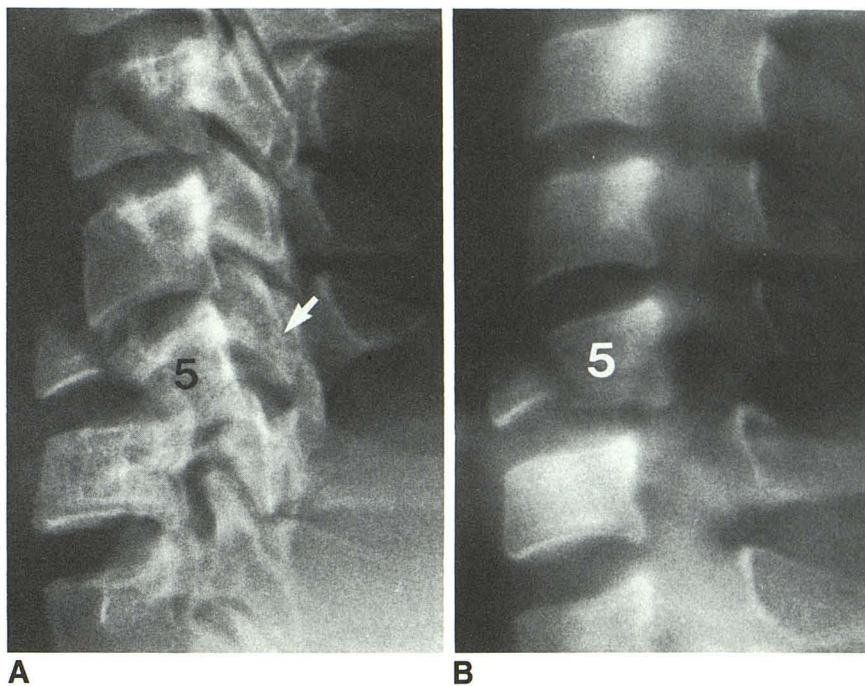
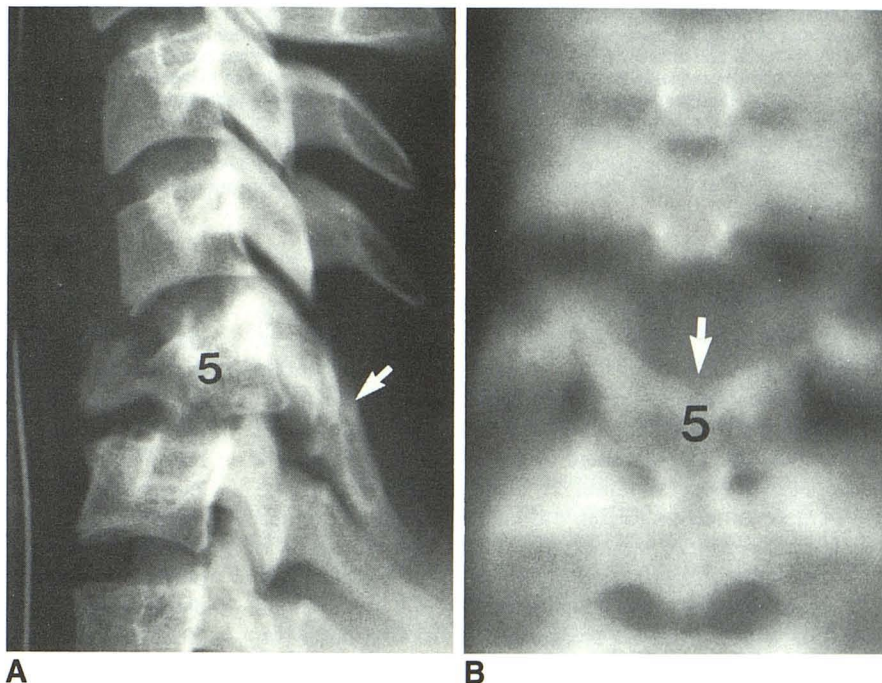


Fig. 4.—19-year-old man with complete quadriplegia at C5 as a result of motor vehicle accident.

Lateral radiograph (A) and anteroposterior polytomogram (B), obtained after traction tongs have been applied, show flexion teardrop fracture at C5 with kyphotic angulation and backward displacement of posterior fragment. C5 laminae are fractured and displaced downward (arrow) with paradoxical narrowing of C5–C6 interlaminar and interspinous spaces. Interlaminar and interspinous spaces are widened at C4–C5.



essential characteristic of FTF was evidence of complete disruption of the anterior and posterior ligamentous structures.

The disk space. While the disk space between the anterior fragment and the vertebral body below was usually maintained, the disk space between the posterior fragment and the vertebral body below was narrowed in all 20 cases (100%) for which the initial radiographs were available (Figs. 2A, 3A, 6). The disk space remained narrowed, changed to normal,

or widened after application of traction tongs, depending on the weight applied (Figs. 2B, 3B, 5A, 5B).

The facet joint. The facet joint between the level of injury and the one below was widened in all cases (100%). There was a varying degree of posterior displacement of the inferior facet in relation to the superior facet below in 29 (64%) of 45 cases (Figs. 2, 3A, 4A, 5A, 6). On polytomograms, widening of the facet joint space was observed in two or more adjacent levels on one or both sides in 39 (87%) of 45 cases.

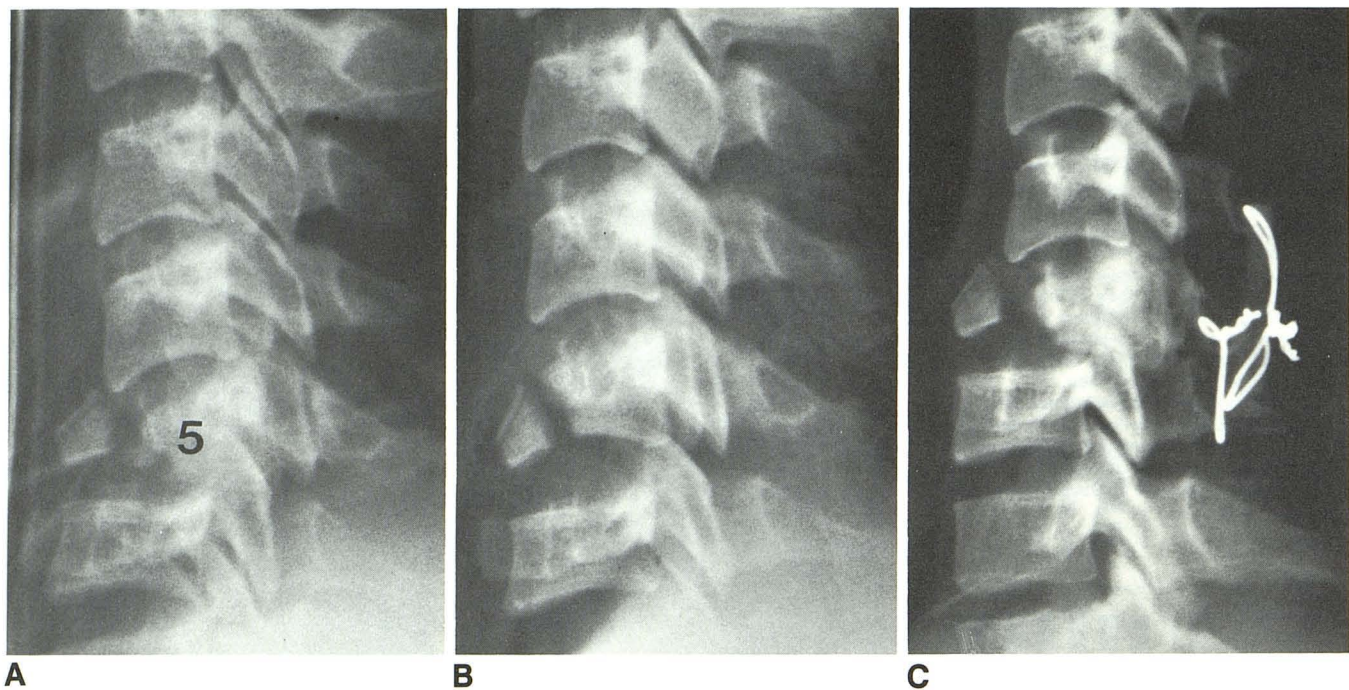


Fig. 5.—20-year-old man with complete quadriplegia at C6 as a result of motor vehicle accident.

A, Lateral radiograph, obtained after traction tongs have been applied, shows flexion teardrop fracture at C5 with kyphotic angulation and backward displacement of posterior fragment. There is a substantial degree of posterior displacement of inferior facet of C5 in relation to superior facet of C6. The C4–C5 interlaminar and interspinous spaces are widened due to C5 bilaminar fracture and disruption of C4–C5 ligamentous structures. The spinolaminar line of upper column above C5 level is slightly displaced backward in relation to that of lower column.

B, With further increase in traction weight, alignment is improved with reduction of both the kyphotic angulation and the backward displacement of posterior fragment. The spinolaminar line is now almost anatomical. Distraction force causes widening of disk space, facet joint, and interlaminar and interspinous spaces at C5–C6. C4–C5 interlaminar and interspinous spaces remain widened.

C, After a posterior fusion, posterior displacement of upper column is evident. C5 lamina is displaced downward with narrowing of interlaminar and interspinous spaces at C5–C6. Interlaminar and interspinous spaces above are widened. The disk space between posterior fragment and vertebral body below is narrowed.

The interlaminar and interspinous spaces. Of the 20 cases in which the initial lateral radiographs were available, eight (40%) showed widening of the interlaminar and interspinous spaces between the level of injury and the one below (Figs. 3A, 6). In five (25%) of the cases, the spaces were narrowed due to downward displacement of the fractured laminae; the spaces above were widened in these five cases. In the remaining seven cases (35%), the interlaminar and interspinous spaces were not widened (Fig. 2A). Of the 25 cases in which the initial lateral radiographs were not available, six (24%) showed widening of the interlaminar and interspinous spaces between the levels of inquiry and the one below on one of the serial lateral radiographs obtained after cervical traction (Fig. 1). In seven (28%) of the cases, the spaces were narrowed due to downward displacement of the fractured laminae; the spaces above were widened in these seven cases (Figs. 4, 5). In 12 (48%) of the cases, the interlaminar and interspinous spaces were not widened.

Kyphotic deformity of the cervical spine at the level of injury. A varying degree of kyphotic deformity of the cervical spine was present at the level of injury in 18 (90%) of 20 cases on the initial lateral radiographs (Figs. 2A, 3A, 6) and 13 (52%) of 25 cases on one of the serial lateral radiographs obtained after traction tongs were applied (Figs. 1, 4A, 5A).

Posterior displacement of the upper column. The cervical spine was divided into the upper and lower columns at the level of injury, following complete disruption of the anterior and posterior ligamentous structures. By observing the alignment of the spinolaminar line, posterior displacement of the upper column in relation to the lower one was seen at the level of injury in 16 (80%) of 20 cases before application of traction tongs (Figs. 2A, 3A). In the remaining 25 cases, evaluation was made with the serial lateral radiographs and polytomograms after traction tongs were applied. Posterior displacement of the upper column was still evident in 19 (76%) of these 25 cases (Figs. 4A, 5A). In some cases with a marked degree of kyphotic angulation at the level of injury, the upper column was inclined forward in such a way that it appeared deceptively displaced forward. However, the upper column immediately above the level of injury was invariably displaced backward (Fig. 6). When the kyphotic angulation was reduced after traction tongs were applied, backward displacement of the entire upper column often became evident.

Distraction. In 12 (27%) of 45 cases there was widening of the disk, facet, and interlaminar and interspinous spaces on one of the serial lateral radiographs obtained after traction tongs were applied (Fig. 5B).

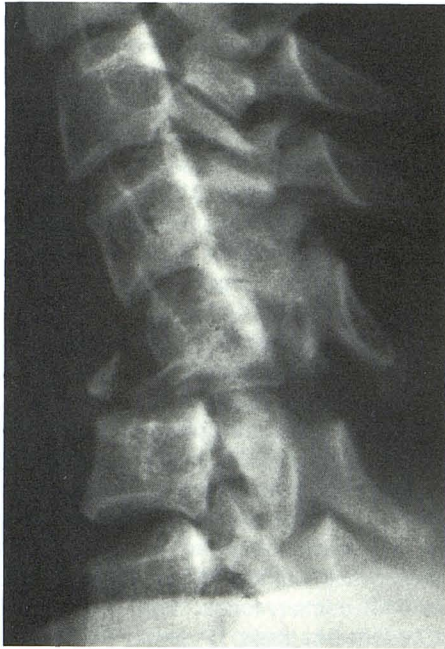

Fig. 6.—26-year-old woman with complete quadriplegia at C5 as a result of motor vehicle accident. Lateral radiograph, obtained before traction tongs are applied, shows flexion teardrop fracture at C5 with a marked degree of kyphotic angulation at level of injury. Upper column is inclined forward in such a way that it appears deceptively displaced forward. However, both the posterior fragment of the fractured body and the inferior facet of C5 are markedly displaced backward. Interlaminar and interspinous spaces are widened at C4-C5 and at C5-C6. The small anterior fragment is aligned with lower column.

Sagittal Body and Laminal Fractures

These fractures were evaluated with polytomography. A sagittal fracture was noted in 39 (87%) of 45 cases. Of these 39 cases, the sagittal fracture was present at the level of injury in all but one. In 13 (33%) of these 39 cases, the sagittal fractures were present at two or more adjacent levels. A laminal fracture, unilateral or bilaminar, was present in 38 (84%) of 45 cases. Of these 38 cases, the laminal fracture was noted at the level of injury in all but one. The laminal fracture was present at two or more adjacent levels in 12 (32%) of 38 cases. The laminal fracture was usually associated with the sagittal fractures in the body. The associated laminal fracture was present in 52 (96%) of 54 vertebrae with sagittal fractures.

Level of Injury

In two (4%) of 45 cases, the FTDFs were noted at two levels, the C4 and the C5 in one case, and the C5 and the C6 in the other. Of the remaining 43 cases, the lesion was at the C5 level in 31 cases (72%), the C6 level in eight cases (19%), and the C4 level in four cases (9%).

Associated Prevertebral Soft-Tissue Swelling

This was evident in 27 (60%) of 45 cases (Figs. 2A, 3A), questionable in 10 (22%) of the cases, and not present in eight (18%) of the cases.

Associated Spine Fracture Distant from the Level of Injury

In three (7%) of 45 cases, there were fractures of the spine distant from the FTDF: Jefferson fracture of C1 in two cases, and a burst fracture of L1 in one case.

CT Features

Axial CT scans with sagittal reformation were obtained in five cases. CT appeared superior to polytomography in detecting the sagittal-body and posterior-element fractures. These fractures were more clearly defined on the axial CT scans, although none were missed on the polytomograms. However, the reformatted sagittal images from the 3-mm axial slices were inferior to the lateral polytomograms and even to the lateral plain cervical films.

Relationship Between the Radiographic Features and Neurologic Status

In five (83%) of six cases with normal neurologic status, there were no sagittal-body or laminal fractures. A sagittal-body fracture was present in all but one of the remaining 39 cases with complete or incomplete neurologic deficits. The posterior displacement of the posterior fragment of the body and the upper column was mild in the cases with normal neurologic status compared with those with complete or incomplete neurologic deficits. There was no differentiating radiographic feature between the group with complete quadriplegia and the one with incomplete neurologic deficits.

Discussion

Teardrop fracture of the cervical spine is a confusing term [2, 7] that is often loosely used to describe any fracture with a triangular fragment of the body without indicating the mechanism of injury. The FTDF is a specific entity that should not be confused with other types of fractures with a teardrop fragment [1, 4-6].

The FTDF results from a combination of forceful flexion and axial compression of the cervical spine (Fig. 7A) that occurs when the neck is flexed and the head strikes a solid object, as in diving into shallow water, hitting the dashboard in a motor vehicle accident, or falling [1, 3, 5-7].

The anteroinferior margin of the involved vertebral body is fractured by a shear stress with compressive loading and the major portion of the body is displaced backward into the spinal canal. The intervertebral disk between the major fragment and the vertebral body below is disrupted. The reciprocal distractive force that occurs in the posterior column of the spine results in disruption of the posterior ligamentous structures [1]. Thus, the cervical spine is divided into an upper and a lower column at the level of injury. The line of disruption separates the anterior and posterior fragment of the body, the disk space between the posterior fragment and the body below, the facet joint, and the interspinous space (Figs. 7B-7D).

Radiographic evaluation of the FTDF is best made with initial lateral radiographs obtained before applying a traction device. However, these radiographs are often of limited quality because of the difficulty in positioning the seriously injured patient. In 25 (56%) of 45 cases, initial lateral radiographs were not available when the patient was referred to our institution. Our study demonstrated that the radiographic characteristics of FTDF could still be appreciated on serial lateral films and on polytomograms in most cases, despite the altered deformity of the cervical spine after traction tongs were applied.

In lateral radiographs, the characteristic feature is the displaced posterior fragment of the involved body, although the injury derives its name from the appearance of the anterior fragment. While the anterior fragment is aligned with the lower column, the posterior fragment is displaced backward as a unit with the upper column relative to the vertebral body below (Figs. 1–7). This feature, when observed at the C5 or adjacent level, strongly implies the diagnosis of FTDF. If such a displacement is found, the next step is the search for signs of disruption of the anterior and posterior ligamentous structures. The disk space narrowing between the posterior fragment and the vertebral body below indicates disruption of the disk. The offset of the anterior and the posterior vertebral body lines at the level of injury is suggestive of disruption of the anterior and posterior longitudinal ligaments. The widening of the facet joint, interlaminar space, and interspinous space represents disruption of the facet joint capsule, ligamentum

flavum, and the interspinous ligament, respectively (Figs. 7B–7D).

The facet joint capsules are thin and lax, contributing little to the strength of the spine [8]. The widening of this joint space is frequently observed in other types of injury, including simple compression and burst fractures. Facet joint space widening alone is not indicative of complete disruption of the posterior ligamentous structures. However, the presence of a substantial degree of posterior displacement of the inferior facet may be indicative of complete disruption (Figs. 3A, 4A, 5A, 5C, 6).

Widening of the interlaminar and interspinous spaces has been stressed by previous authors in establishing the diagnosis of FTDF [1, 6]. However, the interlaminar and interspinous spaces between the level of injury and the one below were widened in only eight (40%) of 20 cases without traction tongs (Figs. 3A, 6) and in six (24%) of 25 cases with traction tongs (Fig. 1). The spaces were paradoxically narrowed due to downward displacement of the fractured laminae in five (25%) of 20 cases without traction tongs and in seven (28%) of 25 cases with traction tongs (Figs. 4, 5A). The spaces above were widened in these 12 cases. The widening of the interlaminar and interspinous spaces is indicative of disruption of the posterior ligamentous structures but not necessarily specific to FTDF: a distractive hyperflexion injury, which includes a flexion sprain injury, with unilateral or bilateral facet locking [3], may produce widening of the interlaminar and interspinous spaces.

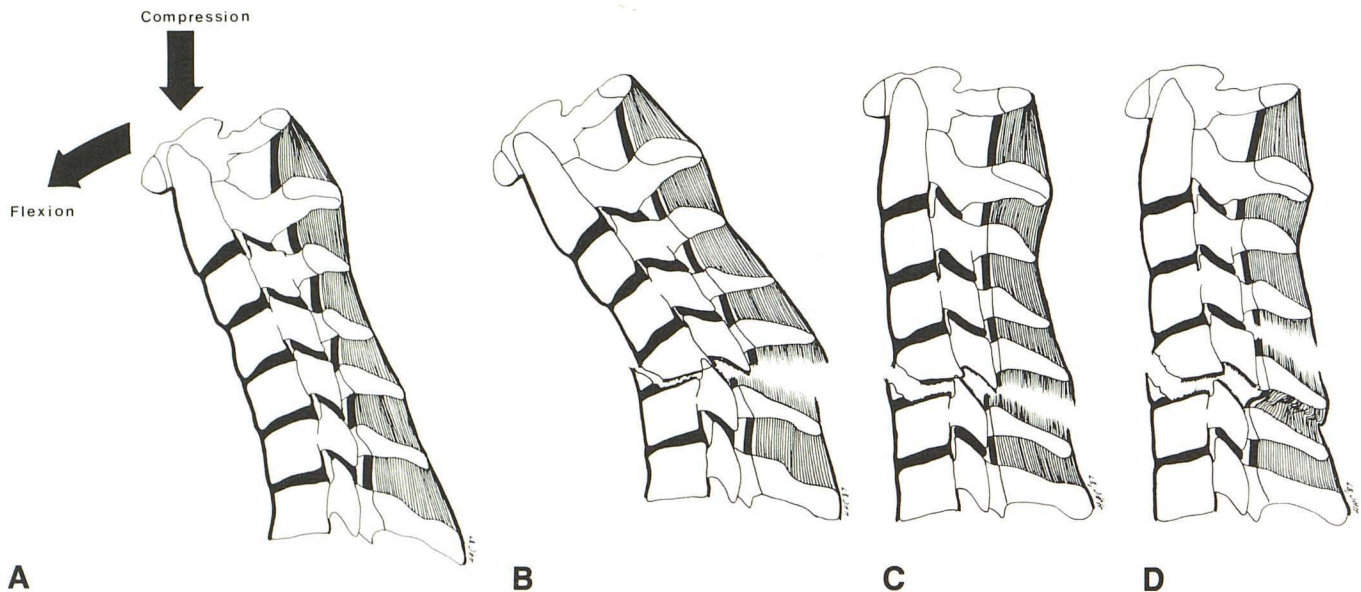


Fig. 7.—A and B, Diagrams show mechanism of flexion teardrop fracture (A) and resultant deformity (B).
 C, Drawing shows altered deformity after traction tongs have been applied. Alignment is improved with reduction of both the kyphotic angulation and the posterior displacement of upper column. However, some degree of posterior displacement of posterior fragment of fractured body and posterior offset of spinolaminar line of upper column often persists. Distraction force may cause widening of disk space, facet joint, and interlaminar and interspinous spaces between the level of injury and the one below.
 D, Variation of C. In some cases of bilaminar fracture at the level of injury, the interlaminar and interspinous spaces between the level of injury and the one below are paradoxically narrowed due to downward displacement of fractured laminae. Interlaminar and interspinous spaces above are widened with torn ligamentum flavum and interspinous ligament.

However, we believe that posterior displacement of the upper column at the level of injury is a specific feature of FTDF, observed in 35 (78%) of the 45 cases. This was demonstrated by a posterior step-off of the spinolaminar line at the level of injury (Figs. 2, 3, 4A), or at one level above in some patients with a bilaminar fracture (Figs. 5A, 5C). Posterior step-off of the anterior and posterior vertebral body lines provided additional evidence of posterior displacement of the upper column.

In 12 (27%) of the 45 cases, a distraction force following application of the traction tongs produced widening of the disk space, facet joint, and interlaminar and interspinous spaces at the level of injury (Fig. 5B). This allowed us to more easily define the line that divided the cervical spine into the unstable upper and lower columns.

A sagittal fracture in the involved body was present in 39 (87%) of the 45 cases. A laminar fracture was usually associated with the sagittal-body fracture. This high incidence of sagittal-body and laminar fractures associated with FTDF reflects the severity of the axial load compression [9].

The level of injury was predominantly at the C5 level, observed in 33 (73%) of the 45 cases and at the C4 and the C6 levels in the remaining cases. The FTDF was not encountered at the C3 or C7 levels in our series, nor has it been

reported at these levels, to the best of our knowledge, in the literature. This observation may be of some diagnostic value.

CT appeared to be of limited value in evaluating FTDF. CT was superior to polytomography in detecting the sagittal-body fracture, laminar fracture, and spinal stenosis [10]. However, the radiographic characteristics of FTDF were observed in the lateral view of the cervical spine. The comparable sagittal image was reformatted from the 3-mm axial slices and this was inferior to the lateral view of the polytomograms and even to the lateral plain cervical films.

An attempt was made to correlate the radiographic features and neurologic status of the patients. In five (83%) of the six cases with intact neurologic status, no sagittal-body or laminar fracture was present. This was compared with the presence of these fractures in 38 (97%) of 39 cases with complete or incomplete neurologic deficits. The posterior displacement of the posterior fragment of the body and the upper column was mild in the group with normal neurologic status as compared with the group with quadriplegia. Although the number of cases is too small to draw a meaningful implication, the absence of the sagittal-body and laminar fractures and a mild degree of posterior displacement of the posterior body fragment and the upper column simply reflect a mild degree of hyperflexion and compression force applied to the cervical

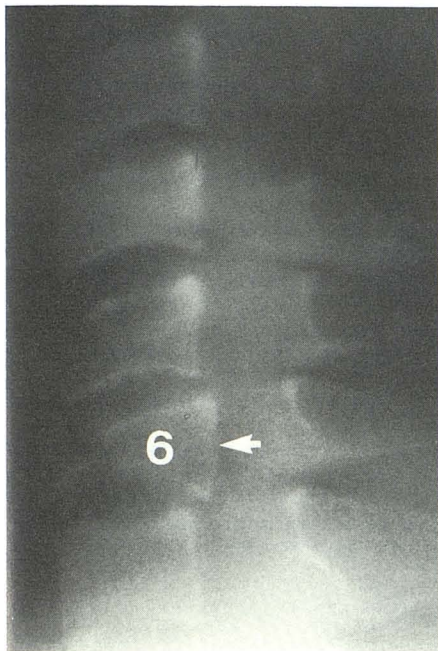
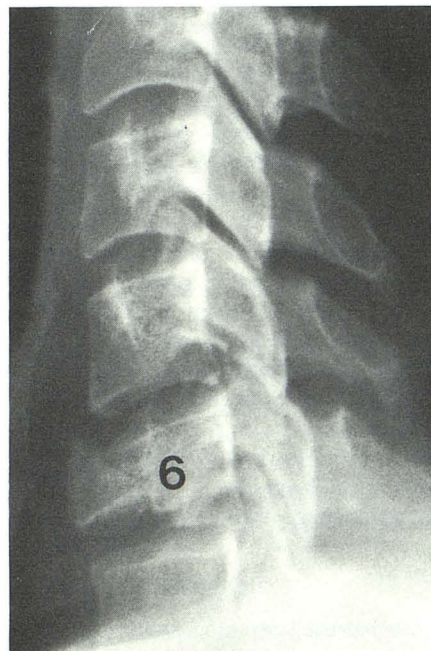
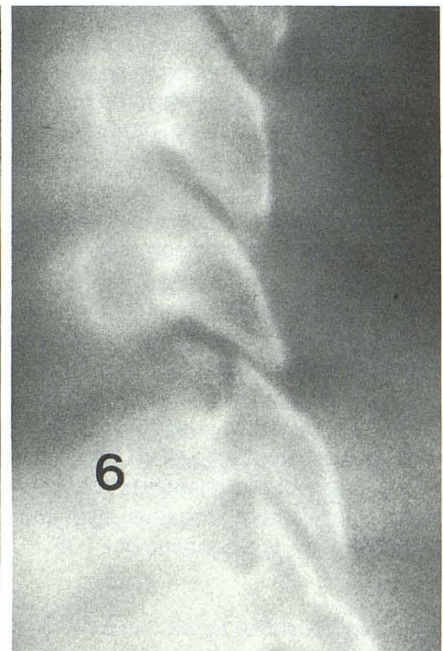


Fig. 8.—Lateral polytomogram shows burst fracture at C6 level with a teardrop fragment. Posterior fragment (arrow) is displaced backward in superior aspect as well as in inferior aspect. This is different from a flexion teardrop fracture, in which backward displacement of posterior fragment takes place in inferior aspect. Spinolaminar line is intact and there is no widening of interlaminar or interspinous space.



A



B

Fig. 9.—A, Lateral radiograph shows distraction flexion injury with a teardrop fracture in C6 body. Posterior fragment is slightly displaced backward. The appearance of the fractured body is not dissimilar to that of a flexion teardrop fracture; however, the upper column is displaced forward at C5-C6 level.

B, Lateral polytomogram shows forward displacement of C5 facet on the C6 facet, which is fractured.

spine. There was no statistically significant differentiating feature between the group with complete neurologic deficits and the one with incomplete deficits.

Diagnostic confusion may occur between the FTDF and the other types of injury with a teardrop fragment in the involved body. A burst fracture produces fractures of the involved body with a smaller anterior and a larger posterior fragment that is retropulsed into the spinal canal. The posterior fragment is displaced posteriorly in the superior aspect as well as in the inferior aspect (Fig. 8). This is in contradistinction to the FTDF, in which the posterior displacement of the posterior fragment takes place in the inferior aspect and not in the superior aspect. In the burst fracture, the posterior ligamentous structures are essentially intact [1, 6, 11] and there is no widening of the interlaminar or interspinous space nor disruption of the spinolaminar line, although the facet joint space may be widened.

An extension injury may produce an avulsion fragment from the anteroinferior corner of the body, simulating a teardrop fragment of the FTDF. The involved body may be displaced posteriorly on the body below; however, the similarity should end here. The posterior ligamentous structures are intact and there is no kyphotic deformity of the cervical spine in the extension injury.

A distractive flexion injury may produce fractures of the body similar to those of the FTDF when the axial compression load is sufficiently forceful [2]. The sagittal-body and the laminar fractures may be present. The distractive force produces disruption of the posterior ligamentous structures with widening of the interspinous space, and kyphotic deformity of the cervical spine may also be present. These features are in common with those of FTDF; however, the cervical spine above the level of injury is displaced forward and often associated with unilateral or bilateral facet locking (Fig. 9). In contrast, the upper column is displaced backward in FTDF.

In conclusion, the radiographic characteristics of FTDF are as follows:

1. In the lateral radiographs, the involved vertebral body is divided into a smaller anterior fragment and a larger posterior fragment, which are displaced backward in the inferior aspect. The disk space between the posterior fragment and the vertebral body below is narrowed.

2. The upper column of the divided cervical spine is displaced backward in relation to the lower one at the level of injury. This feature, together with the appearance of the vertebral body, is diagnostic of FTDF.

3. If posterior displacement of the upper column is not present, widening of the interlaminar and interspinous spaces is supportive of the diagnosis of FTDF, provided there is no forward subluxation or dislocation of the cervical spine above the level of injury.

4. Widening of the facet joint space alone is not indicative of complete disruption of the posterior ligamentous structures. However, a substantial degree of posterior displacement of the inferior facet in relation to the superior facet below at the level of injury is suggestive of FTDF.

5. Sagittal-body and laminar fractures are frequently associated with FTDF at levels that are the same as or adjacent to the level of injury. The bilaterally fractured laminae at the level of injury were displaced inferiorly, in some cases, with paradoxical narrowing of the interlaminar and interspinous spaces between the level of injury and the one below. The interlaminar and interspinous spaces between the level of injury and the one above were widened in these cases.

6. FTDF occurred predominantly at the C5 level and less frequently at the C4 and the C6 levels, but it was never encountered at the C3 or the C7 level.

REFERENCES

1. Harris JH, Edeiken-Monroe B. *The radiology of acute cervical spine trauma*, 2nd ed. Baltimore: Williams & Wilkins, 1987
2. Lee C, Kim KS, Rogers LF. Triangular cervical body fragments: diagnostic significance. *AJR* 1982;138:1123-1132
3. Allen BL, Ferguson RL, Lehmann TR, O'Brian RP. A mechanistic classification of closed, indirect fractures and dislocations of the lower cervical spine. *Spine* 1982;7(1):1-27
4. Schneider RC, Kahn EA. Chronic neurological trauma to the spine and spinal cord. Part I. The significance of the acute flexion or "teardrop" fracture dislocation of the cervical spine. *J Bone Joint Surg (Am)* 1956;38:985-997
5. Gehweiler JA, Osborne RL, Becker RF. *The radiology of vertebral trauma*. Philadelphia: Saunders, 1980
6. Scher AT. "Teardrop" fractures of the cervical spine: radiologic features. *S Afr Med J* 1982;61:355-356
7. White AA, Panjabi MM. *Clinical biomechanics of the spine*. Philadelphia: Lippincott, 1978
8. Halliday DR, Sullivan CR, Hollinshead WH, Bahn RC. Torn cervical ligaments: necropsy examination of normal cervical region. *J Trauma* 1964;4:219-232
9. Lee C, Kim KS, Rogers LF. Sagittal fractures of the cervical vertebral body. *AJR* 1982;139:55-60
10. Acheson MB, Livingston RR, Richardson ML, Stimac GK. High resolution CT scanning in evaluation of cervical spine fractures: comparison with plain film examination. *AJR* 1987;148:1179-1185
11. Holdworth F. Fractures, dislocations and fracture dislocation of the spine. *J Bone Joint Surg (Am)* 1970;52(A):1534-1551