

# Fried Tooth and Nail Syndrome with Possible Mutation - A Rare Entity

Ashwin Devasya<sup>1</sup>, Mythri Sarpangala<sup>2</sup>, Ajeya Kumara<sup>3</sup>, Rakshith S Shetty<sup>4</sup>

<sup>1</sup>Department of Pedodontics and Preventive Dentistry, Kannur Dental College, Anjarakandy, Kannur, Kerala State, India, <sup>2</sup>Department of Periodontology, Kannur Dental College, Anjarakandy, Kannur, Kerala State, India, <sup>3</sup>Department of Periodontology, Century International College of Dental Sciences, Poinachy, Kasaragod, Kerala state, India, <sup>4</sup>Senior Endodontic Consultant, Kannur, Kerala State, India

## Corresponding author:

Ashwin Devasya, Department of Pedodontics and Preventive Dentistry, Kannur Dental College, Anjarakandy, Kannur, Kerala State, India,  
Tel: +91- 8129132950;  
E-mail: ashwindkumbla@gmail.com

## Abstract

**Background:** Tooth and Nail Syndrome (TNS) is a rare genetic disorder and one of the common types of Ectodermal Dysplasias (ED). Fried and Witkop Syndromes are two subtypes with similar clinical and radiological features with a difference in the inheritance pattern. Just state the genetic difference. The condition is particularly of interest to dentists because of the challenges in prosthetic rehabilitation. **Case report:** This article reports a case of an 8-year-old girl whose parents came with a chief complaint of unerupted permanent teeth. Clinical examination showed the features of a possible syndrome with some missing teeth, thin scalp hairs and eyebrows, everted lips, dysplasia of nails and palmoplantar hyperkeratosis. Orthopantomograph showed missing mandibular primary central and lateral incisors and absence of permanent tooth buds. Based on the clinical findings and autosomal recessive inheritance pattern, the girl was diagnosed of Fried Tooth and Nail syndrome. **Conclusion:** The present case is a rare occurrence of Fried Tooth and Nail syndrome. Case also presents with palmoplantar hyperkeratosis, which is unusual, suggesting a possibility of mutation of gene responsible for the condition.

**Keywords:** Ectodermal dysplasia; Fried syndrome; MSX-1; Tooth and Nail syndrome

## Introduction

Ectodermal dysplasias (ED) are abnormalities in the ectodermal structures such as the hair, teeth, nails, sweat glands, salivary glands, crania facial structure, digits and other parts of the body.<sup>[1]</sup> First described by Thurnam in 1848, more than 170 different clinical conditions have been recognized and defined as EDs over the years.<sup>[1]</sup>

Tooth and Nail Syndrome (TNS) is a rare genetic disorder and one of the common types of EDs. It is of two types: Fried syndrome and Witkop syndrome<sup>[2]</sup>. Witkop syndrome was first mentioned by Weech in 1929, later described by Witkop in 1965, and further expanded in 1975<sup>[3]</sup>. Fried, in 1977, described two cousins who showed distinct clinical similarity to the Witkop Syndrome except the pattern of inheritance. It was later called Fried syndrome<sup>[4]</sup>.

TNS is seen in one or two individuals in 10,000<sup>[3]</sup>. It affects both male and female equally. As the name suggests, it mainly affects the development of teeth and nails resulting in hypodontia of primary or permanent dentition and dysplasia of nails. Few cases have been reported with sparse hair but skin, sweat glands and other parts were not affected. There is no particular facial appearance associated with this syndrome, and no other systemic pathologies seen<sup>[5]</sup>. Contrary to that, children with ectodermal dysplasia irrespective of the subtypes tend to have similar facial appearance secondary to hypodontia and associated poor jaw development, scanty hair and dry skin<sup>[4]</sup>. This is a rare case report of Fried TNS which shows palmoplantar hyperkeratosis in an 8-year-old female. This could be due to the possibility of mutation in gene which is responsible for TNS.

## Case Report

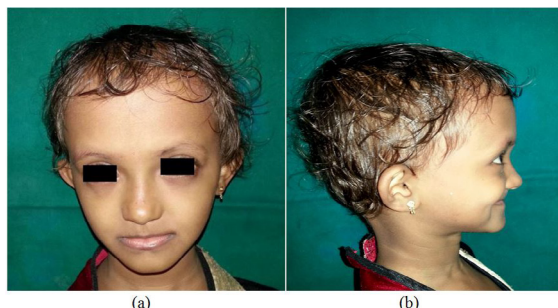
Parents of an 8-year-old female visited our private dental hospital complaining of unerupted permanent front teeth. The child was referred to the dentist by their family pediatrician for dental consultation regarding the same complaint.

The patient was of short stature, had thin hair on the scalp, sparse hair on eyebrows and lip was everted [Figures 1a and 1b]. The nails of the hands and toes were spoon shaped (koilonychias). Toe nails were more affected than fingernails [Figures 2a and 2b]. She also suffered from hyperhidrosis and had palmoplantar hyperkeratosis; the plantar surface was severely affected [Figures 3a and 3b]. There was no history of heat intolerance and psychological deficit and/or harassment. Child mingles socially with family members, friends and is active in school. On oral examination, there is no abnormality seen in oral mucosa, residual alveolar ridge, tongue or saliva. The patient had missing primary mandibular central and lateral incisors, canine and first molar were present and had grossly decayed mandibular second molars. Permanent incisors had not erupted, and she had very thin alveolar ridge in the mandibular anterior region. In the maxillary arch, all the primary teeth were present and had attrition [Figures 4a-4c].

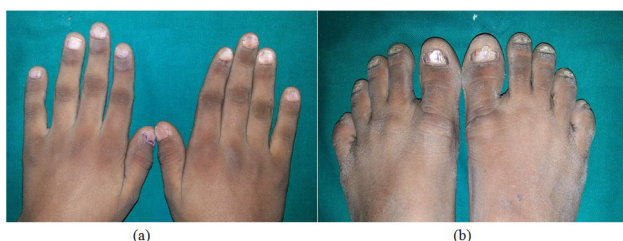This is an open access article distributed under the terms of the Creative Commons Attribution-NonCommercial-ShareAlike 3.0 License, which allows others to remix, tweak, and build upon the work non-commercially, as long as the author is credited and the new creations are licensed under the identical terms.

**How to Cite this Article:** Ashwin Devasya, Mythri Sarpangala, Ajeya Kumara EG, Rakshith S Shetty. Fried Tooth and Nail Syndrome with Possible Mutation - A Rare Entity. Ann Med Health Sci Res. 2017; 7: 305-307

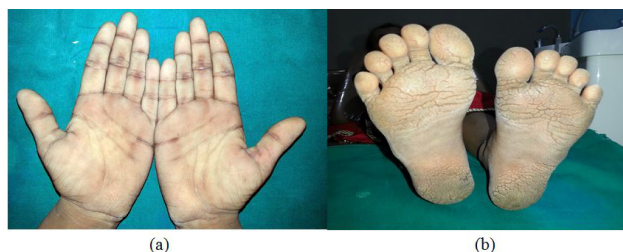Since there was failure of eruption of mandibular incisors, the parents were advised for Orthopantomograph (OPG), to examine the presence and developmental stage of permanent tooth buds. The OPG showed missing maxillary and mandibular permanent central and lateral incisor tooth buds. The tooth buds of the canine, premolars and first and second molars were visible but very underdeveloped for the patient's age [Figure 5].



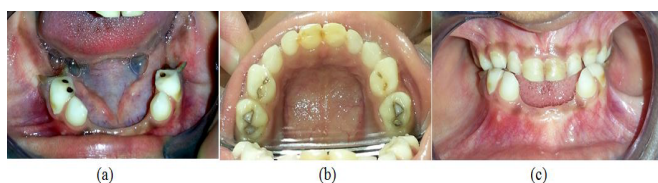
**Figure 1:** (a) Scanty eye brows; (b) Scanty scalp hairs.



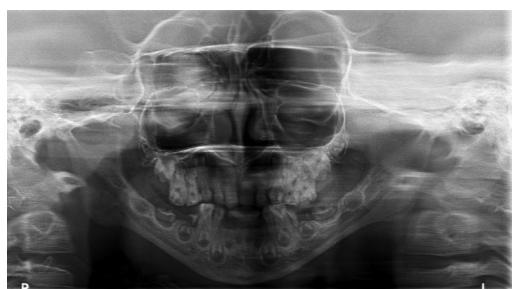
**Figure 2:** (a) Dysplasia of nails; (b) Dysplasia of toe nails.



**Figure 3:** (a) Hyperkeratosis of palms; (b) Hyperkeratosis of plantar surface.



**Figure 4:** (a) Missing primary incisors; (b) Primary maxillary teeth; (c) Attrited primary teeth.



**Figure 5:** OPG.

Medical history of the patient was negative. The parents of the patient, siblings and no other person in their family had these conditions.

Based on the clinical findings (hypodontia, nail dysplasia, sparse hairs), and autosomal recessive mode of inheritance, she was diagnosed of Fried TNS. She also had palmoplantar hyperkeratosis, which showed there might be a possibility of mutation of genes causing TNS.

## Discussion

TNS is a rare genetic disorder belongs to EDs. In patients with TNS, there will be variation in shape and number of teeth. Affected individuals have congenitally missing primary / permanent teeth. The permanent teeth most absent include mandibular incisors, maxillary canines, permanent first molars. Teeth might be underdeveloped, widely spaced and conical in shape [6,7].

Nails are thin and spoon-shaped. Toe nails are more affected than fingernails. The nail defect usually gets better with age and may not be easily detectable in adulthood. In some cases, hairs of scalp, eye brows are scaly and brittle [6,7].

Fried Syndrome is also known as Ectodermal Dysplasia's 8, Fried type (ECTD8), Ectodermal dysplasia's 8, Hair/Tooth/Nail type, and Tooth-and-Nail Syndrome (TNS) [8]. The difference between Witkop and Fried Syndrome is mainly inheritance pattern. Witkop's is autosomal dominant, whereas Fried's is recessive type. Although clinical features are similar, in Fried Syndrome, there is significant sparseness /slow-growing fine scalp hair, and/or thin scanty eyebrows as well as an everted lower lip. Sweat gland involvement also is seen. Eversion of lower lip is due to loss of vertical dimension [5,9].

So far, none or very few cases of Fried TNS had been reported. The condition was first described by Fried, in an Egyptian family [3]. Megarbane et al. described a case of 10 individuals of three generations having a similar tooth, hair and nail involvement but in a recessive pattern [10]. MSX gene is recognized to help in tooth formation. In a genetic study, it was shown that mutation of MSX-1 is the cause for TNS [7].

Witkop TNS, hypohidrotic ectodermal dysplasias, Curry-Hall syndrome and DOOR Syndrome also have similar clinical features and with slight changes in the involvement [11]. Therefore, proper familial history, evaluation of clinical and radiographic features are important while diagnosing a case of Fried TNS [6].

Presence of palmoplantar hyperkeratosis in TNS is uncommon, but seen in this case. This might be due to mutation of the gene causing TNS. Due to some limitations, genetic confirmation was not done in this case.

The treatment for TNS depends on the severity of the condition. The conditions of hair and nails get better when patients get older. For the dentition, removable partial dentures, fixed partial dentures, implants can be used for replacing missing teeth [11]. Patients might be psychologically affected due to their appearance, so psychological evaluation and counseling are also needed.

## Conclusion

In the present case, parents were suggested for extraction

of primary second molars and distal shoe space maintainers in the mandibular arch and removable partial denture in primary anterior region, and also restoration of carious teeth. Unfortunately, parents were not interested for any treatment. Hence they were suggested for regular visit to the dentist for the follow up on their child's oral condition.

### Conflict of Interest

All authors disclose that there was no conflict of interest.

### References

1. Pinheiro M, Freire-Maia N. Ectodermal dysplasia's: A clinical classification and a causal review. *Am J Med Genet* 1994;53:153-62.
2. Sybert V. Ectodermal Dysplasias. Freedberg (ed). In: Fitzpatrick's dermatology in general medicine. 6th ed. McGraw-Hill. New York, USA. 2003. p. 587-94.
3. Witkop CJ Jr. Genetic diseases of the oral cavity. In: Tietze RW Jr, (ed). *Oral Pathology*. New York, NY: Blackiston Division, McGraw-Hill, USA. 1965:p. 810-4.
4. Fried K. Autosomal recessive hydrotic (sic) ectodermal dysplasia. *J Med Genet* 1977; 14: 137-9.
5. Devadas S, Varma B, Mungara J, Joseph T, Saraswathi TR. Witkop tooth and nail syndrome: a case report. *Int J Paediatr Dent* 2005;15:364-9.
6. Hodges SJ, Harley KE. Witkop tooth and nail syndrome: report of two cases in a family. *Int J Paediatr Dent* 1999;9: 207-11.
7. Jumlongras D, Bei M, Stimson JM, Wang WF, DePalma SR, Seidman CE, et al. A nonsense mutation in MSX1 causes Witkop syndrome. *Am J Hum Genet* 2001; 69: 67-74.
8. Ectodermal dysplasia type-8. Online Manderian Inheritance of Man. <http://www.omim.org/entry/602401> as on 17th Aug 2017.
9. Gorlin RJ, Cohen MM Jr, Levin LS. Syndromes with unusual dental findings. In: Gorlin RJ, Cohen MM Jr, Levin LS, (eds). *Syndromes of the head and neck*. 3rd edN. New York, NY: Oxford University Press, UK. 1990:p 877.
10. Megarbane A, Noujeim Z, Fabre M, Der Kaloustian VM. New form of hidrotic ectodermal dysplasia in a Lebanese family. *Am J Med Genet* 1998; 75: 196-9.
11. Arora V, Agrawal KK, Mishra A, Chandra A. Witkop's syndrome: A case report. *J Oral Biol Craniofac Res* 2016;6:79-81.