



## Secondary Flame-like Retinal Hemorrhage

Cai C-X and Lin Y\*

State Key Laboratory of Ophthalmology, Zhongshan Ophthalmic Center, Sun Yat-sen University, China

### Clinical Image

A 13-year-old girl presented to the hospital complaining of painless visual loss in the left eye for 1 week. This patient had been diagnosed with Systemic Lupus Erythematosus (SLE) and received glucocorticoid treatment. The patient denied the history of trauma, hypertension and Diabetes Mellitus. Her best corrected visual acuity was hand move/before eye and the intraocular pressure was 15 mmHg in the left eye. The fundus photograph of the left eye showed optic disc edema, flame-like hemorrhage in the retina, and tortuous dilatation of retinal veins (Figure 1). There was no special in the right eye.

The patient was diagnosed with Central Retinal Vein Occlusion (CRVO) in the left eye and SLE. SLE is an autoimmune disease that damages its own organs and tissues mediated by autoantibodies and immune complexes [1]. Retinal disease occurs in approximately 25% to 30% of patients with SLE, and CRVO is one of the rare but severe complications [2]. SLE combined with CRVO is caused by immune complex-mediated vascular injury and microvascular thrombosis, systemic comorbidities, higher dosage of steroid and antiphospholipid antibodies are considered as associated risk factors [3-5]. Patients with CRVO combined with SLE are often blind, and their treatment requires a combination of both ocular and systemic conditions.

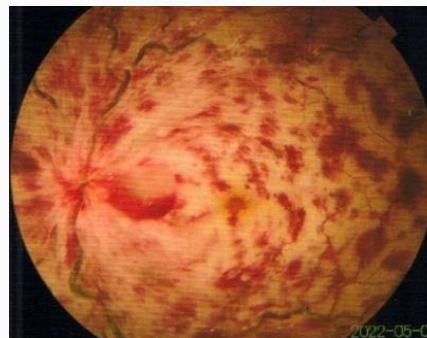


Figure 1: Photograph of the left eye.

### OPEN ACCESS

#### \*Correspondence:

Ying Lin, State Key Laboratory of Ophthalmology, Zhongshan Ophthalmic Center, Sun Yat-sen University, Guangzhou 510060, Guangdong Province, China, Tel: 00-86-13434364370; Fax: 020-86-20-

66683849;

E-mail: liny83@susu.edu.cn

Received Date: 01 Dec 2022

Accepted Date: 23 Dec 2022

Published Date: 27 Dec 2022

#### Citation:

Cai C-X, Lin Y. Secondary Flame-like Retinal Hemorrhage. *Ann Clin Case Rep.* 2022; 7: 2371.

ISSN: 2474-1655.

Copyright © 2022 Lin Y. This is an open access article distributed under the Creative Commons Attribution License, which permits unrestricted use, distribution, and reproduction in any medium, provided the original work is properly cited.

### References

1. Durcan L, O'Dwyer T, Petri M. Management strategies and future directions for systemic lupus erythematosus in adults. *Lancet.* 2019;393(10188):2332-43.
2. Silverman M, Lubeck MJ, Briney WG. Central retinal vein occlusion complicating systemic lupus erythematosus. *Arthritis Rheum.* 1978;21(7):839-43.
3. Yen YC, Weng SF, Chen HA, Lin YS. Risk of retinal vein occlusion in patients with systemic lupus erythematosus: A population-based cohort study. *Br J Ophthalmol.* 2013;97(9):1192-6.
4. Hernández JL, Sanlés I, Pérez-Montes R, Martínez-Taboada VM, Olmos JM, Salmón Z, et al. Antiphospholipid syndrome and antiphospholipid antibody profile in patients with retinal vein occlusion. *Thromb Res.* 2020;190:63-8.
5. Chiou YR, Chang YS, Su CF, Li TH, Lai CC, Hwang DK, et al. Risks of posterior segment ocular ischemic events in patients with systemic lupus erythematosus: A population-based cohort study in Taiwan. *Br J Ophthalmol.* 2022.