Diagnostic Approach to Diplopia

Marc Dinkin, MD

Address correspondence to Dr Marc Dinkin, Weill Cornell Ophthalmology, 1305 York Avenue, Floor 11, New York, NY 1002, *mjd2004@med.cornell.edu*.

Relationship Disclosure: Dr Dinkin has received personal compensation for medical record review and affidavit preparation from several law firms and has served on an advisory board for Acorda Therapeutics.

Unlabeled Use of Products/Investigational Use Disclosure: Dr Dinkin reports no disclosure.

© 2014, American Academy of Neurology.

ABSTRACT

Purpose of Review: This article offers a pragmatic roadmap to the practicing neurologist on how to approach the patient with double vision. Strategies of history taking and examination techniques are reviewed, followed by a broad overview of the causes of diplopia organized by neuroanatomic localization. Diplopia may be the first symptom of serious vision or life-threatening neurologic disease, and its correct localization and diagnosis are therefore essential. The systems responsible for ocular movement and alignment in the vertical and horizontal plane include complex supranuclear circuitry, brainstem nuclei, cranial nerves III, IV, and VI, and their respective neuromuscular junctions and target muscles. Disruption at any point within this system or within the vestibular afferents that govern eye movement in response to head movements may therefore produce diplopia, leading to a broad differential diagnosis for the patient with diplopia. With a careful history and examination, the neurologist should be able to observe the patterns of diplopia that reveal the site of dysfunction, thus generating a shorter localization-specific list of possible etiologies. Examination of ocular motility including smooth pursuit and saccadic function, followed, if necessary, by testing designed to uncover misalignments of the eyes, including cover and Maddox rod testing, are primary components of the efferent neurologic examination. Further testing designed to detect myasthenia (eg, lid testing and fatigable upgaze) and orbital disease (eg, measuring proptosis, testing for resistance to retropulsion) may be necessary.

Recent Findings: Recent advances in the diagnosis of diplopia include the observation that vertical diplopia from skew deviation is more likely to improve with supine positioning than that caused by trochlear nerve palsies. Advances in the field of ocular myasthenia include the observation of decreased conversion to the generalized form with treatment with either steroids or thymectomy, although these conclusions need to be confirmed by prospective, randomized trials. Rarely, pure ocular myasthenia may be associated with the muscle-specific tyrosine kinase (MuSK) antibody.

Summary: With proper skills, the neurologist can elucidate the localization of diplopia, even in cases of complex ocular misalignment, and generate a management plan that can address the underlying disease, and, in many cases, ameliorate or cure the diplopia.

Continuum (Minneap Minn) 2014;20(4):942–965.

Supplemental digital content: Videos accompanying this article are cited in the text as **Supplemental Digital Content.** Videos may be accessed by clicking on links provided in the HTML, PDF, and iPad versions of this article; the URLs are provided in the print version. Video legends begin on page 963.

INTRODUCTION

Double vision, or diplopia, is a common visual concern that may be the first warning of vision-threatening or life-threatening neurologic disease. While some cases of diplopia are accompanied by obvious ocular motility deficits that allow easy diagnosis of an underlying injury, often the physical findings are more subtle and can be vexing to neurologists and ophthalmologists alike. The evaluation of diplopia, using a detailed and targeted history, an examination of ocular alignment and motility, and, when appropriate, neuroimaging of the brain and orbits, is an essential skill for all practicing neurologists. This article will take a broad view of

Downloaded from https://journals.lww.com/continuum by BhDMf5ePHKav1zEoum1tQfN4a+kJLhEZgbsIHo4XMi0hCywCX1AWnYQp/IlQrHD3bmaqTQjPuGRXx5kyPdFZxo9C56RlNY1tvxtd6QzCr6PRM+bdgGw== on 06/18/2020

Copyright © American Academy of Neurology. Unauthorized reproduction of this article is prohibited.

diplopia, offering the reader a framework for the focused attainment of patient history as well as a comprehensive review of the efferent neuro-ophthalmic examination and how it may be used to distinguish the various categories of disease that may present with double vision.

ANATOMIC FRAMEWORK

This section provides a brief review of the neuroanatomic pathways that govern eye movements and stabilize them within the orbits during head movements. **Figure 8-1** summarizes the pathways responsible for horizontal eye movements, including yoked versions (conjugate movements of the eyes) and vergence (convergence and divergence) movements, as well as the horizontal vestibular ocular response. **Figure 8-2** addresses the same systems in the vertical plane.[1,2] In both figures, the boxed elements indicate

KEY POINT

- Diplopia may be the presenting symptom of potentially blinding or life-threatening disease. The ability to localize, work up, and appropriately manage double vision is essential to the practicing neurologist.

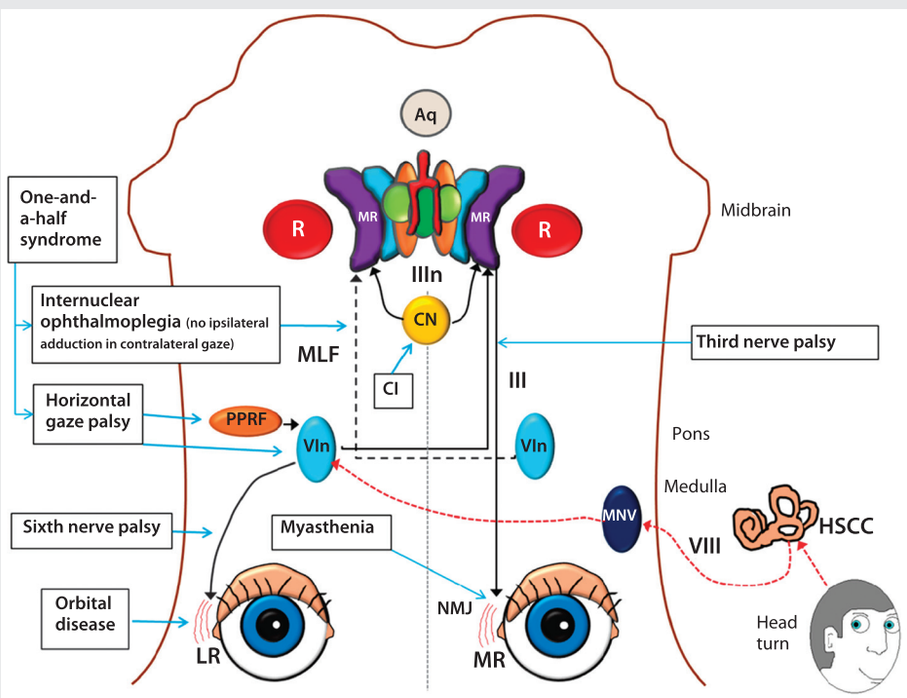

FIGURE 8-1 Control of horizontal eye movements. Voluntary lateral gaze is governed by the parapontine reticular formation (PPRF), under cortical control by the contralateral frontal eye field. The PPRF excites the adjacent abducens nucleus (VIn) which contains two major populations of neurons. The first are the cell bodies of the abducens nerve that stimulates the ipsilateral lateral rectus (LR). The second population of neurons are interneurons whose axons decussate and ascend within the medial longitudinal fasciculus (MLF) to synapse with the neurons of the medial rectus subnucleus (MR [*white text*]) of the oculomotor nucleus (IIIn). These neurons then form the branch of the third nerve to the medial rectus, resulting in yoked adduction of the contralateral eye together with abduction of the ipsilateral eye. The convergence nucleus (CN) activates as part of the accommodative reaction, resulting in bilateral MR (*white text*) activation. The horizontal vestibular ocular reaction is governed by the horizontal semicircular canal (HSCC). With left head turn, endolymphatic fluid deforms hair cells in the cupula of the HSCC, leading to activation of the vestibular nerve (VIII) and the ipsilateral medial vestibular nucleus (MVN). The contralateral VIn is stimulated in turn, leading to contralateral gaze, as described above. Pathologic conditions are shown in boxes: a lesion of the PPRF or VIn would cause an ipsilateral gaze palsy. Note that an internuclear ophthalmoplegia results from a lesion of the MLF. The VIn fires, resulting in abduction of the ipsilateral eye, but the message to adduct never reaches the contralateral medial rectus muscle (MR [*black text*]). One-and-a-half syndrome results from a lesion encompassing the VIn and the MLF on one side. Thus, there is an ipsilateral gaze palsy and a contralateral internuclear ophthalmoplegia.

Aq = aqueduct; R = red nucleus; CI = convergence insufficiency; NMJ = neuromuscular junction.

Copyright © American Academy of Neurology. Unauthorized reproduction of this article is prohibited.

KEY POINTS

- Yoked horizontal eye movements are controlled by a series of nuclei and tracts, including the parapontine reticular formation, abducens nucleus, medial longitudinal fasciculus, and the medial rectus subnucleus of cranial nerve III. The ability to distinguish central causes of horizontal diplopia from cranial neuropathies or orbital disease depends on an understanding of the relevant neuroanatomy.
- Vertical eye movements are governed by the rostral interstitial nucleus of the medial longitudinal fasciculus and interstitial nucleus of Cajal, both located in the mesencephalon. These nuclei control the oculomotor nuclei responsible for vertical gaze and the trochlear nucleus.
- A careful history of a patient's double vision may elucidate the etiology before the examination is started. Queries regarding the presence of diplopia with either eye closed, in the distance and near, and in various fields of gaze, may be used to confirm and localize a neurologic cause of diplopia.

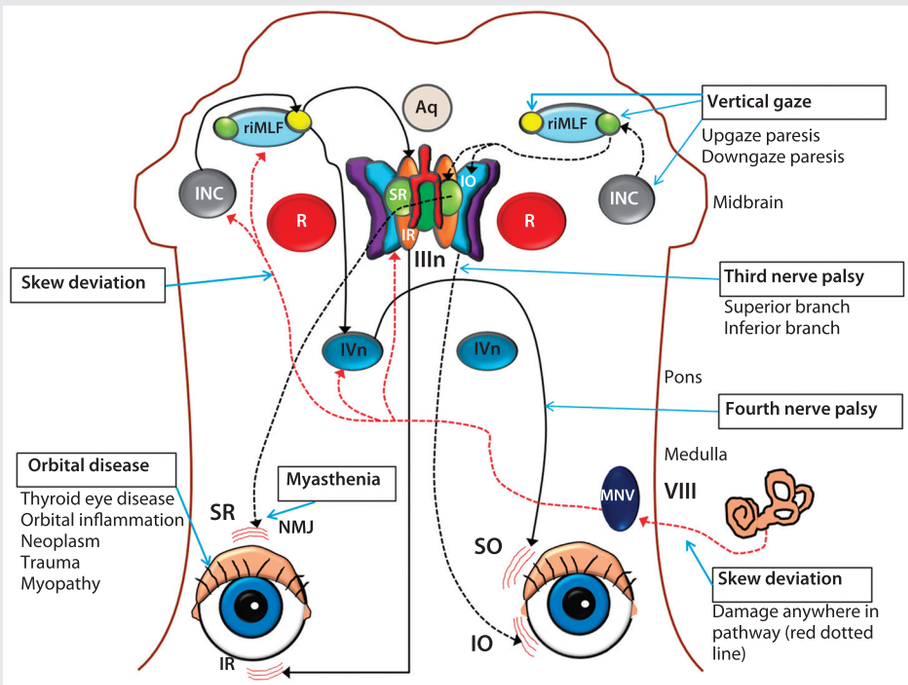

FIGURE 8-2 Control of vertical eye movements. Vertical saccades are governed by the rostral interstitial nucleus of the medial longitudinal fasciculus (riMLF), while the interstitial nucleus of Cajal (INC) is involved in smooth pursuit and maintenance of the eyes in eccentric vertical gaze. The medial riMLF stimulates the ipsilateral inferior rectus subnucleus of IIIn (IR [*white text*]) resulting in ipsilateral depression and IVth nucleus (IVn), whose fibers decussate and cause contralateral depression. There are also fibers from the INC that decussate to the opposite riMLF, so that its activation would result in activation of all four muscles of depression. Upgaze appears to be governed by the lateral riMLF, which stimulates the inferior oblique (IO [*white text*]) and superior rectus (SR [*white text*]) subnuclei of IIIn, resulting in ipsilateral and contralateral (the SR fibers decussate) elevation, respectively. The relative height of the two eyes is governed by afferents from the utricle that sense body or head tilt. Ipsilateral head tilt results in utricular activation, carried by the vestibular branch of the eighth nerve (VIII) to the medial vestibular nucleus (MVN), which in turn activates compensatory contralateral depression (*red dotted lines*) and ipsilateral elevation (*not shown*). Injury to this pathway mimics activation of the contralateral pathway, resulting in a pathologic vertical strabismus known as a skew deviation. Damage within the medulla prior to decussation would therefore result in ipsilateral depression, while injury to the midbrain portion above its decussation would result in hypertropia on the side of the lesion.

Aq = aqueduct; R = red nucleus; SR (black text) = superior rectus muscle; NMJ = neuromuscular junction; SO = superior oblique muscle; IR (black text) = inferior rectus muscle; IO (black text) = inferior oblique muscle.

points in the pathway where disruption may result in diplopia.

HISTORY

Taking a careful history can often localize the site of anatomic dysfunction causing diplopia and, in some cases, even delineate the underlying disease process, before even examining the patient or obtaining any neuroimaging.

Question 1: Does the Double Vision Go Away When Closing Either Eye?

If the diplopia persists with either eye open by itself, it is monocular, resulting from aberrant refraction, so that identical light rays land on different parts of the retina. The patient typically describes a second "ghost image." Astigmatism,[3] corneal pathology, dry eyes,

Copyright © American Academy of Neurology. Unauthorized reproduction of this article is prohibited.

complex cataracts, poorly centered intraocular lenses, and severe structural retinal pathology[4] should be considered. If the issue is refractive, the diplopia will usually resolve with application of a pinhole or proper correction of astigmatism. Diplopia caused by ocular misalignment (binocular) resolves with closure of either eye.

Question 2: Are the Two Images Separated Vertically, Horizontally, Obliquely, or Torsionally?

Once the diplopia is confirmed as binocular, the orientation of the two images should be elucidated. Pure horizontal diplopia suggests medial rectus or lateral rectus dysfunction (which can result from cranial neuropathies, orbital pathology, or myasthenia), or an internuclear ophthalmoplegia (INO). Pure vertical diplopia suggests either a trochlear nerve palsy or skew deviation, the latter of which reflects an imbalance in the vestibular-ocular signal governing ocular torsion and vertical alignment in response to body or head tilt. Oblique diplopia may result from oculomotor palsies (since muscles governing both horizontal and vertical motility can be affected), diffuse orbital disease, or ocular myasthenia. Trochlear nerve palsies may also result in torsional diplopia, caused by extorsion of the affected eye.

Question 3: Is the Diplopia Worse at Distance or at Near?

Worsening of horizontal diplopia at distance, such as when driving, is consistent with lateral rectus or abducens nerve dysfunction, since abduction is necessary for divergence. Worsening of horizontal diplopia at near, typically manifesting as trouble reading or seeing a smartphone, is consistent with medial rectus dysfunction, as may be found in an oculomotor palsy, since adduction is required for convergence, but may also reflect a convergence insufficiency, which manifests as a limitation of convergence in the presence of full medial rectus function.

Question 4: In Which Direction Is the Double Vision Worse?

Worsening of vertical diplopia in downgaze implicates either a trochlear palsy or inferior rectus weakness, while a worsening in upgaze will occur in complete third nerve palsies since there is weakness of both the superior rectus and inferior oblique. A worsening in upgaze also occurs in inferior oblique overaction, since the affected eye will elevate more than normal in upgaze. A worsening of horizontal diplopia in lateral gaze in one direction implicates either the ipsilateral lateral rectus or contralateral medial rectus. The answer to question 3 can distinguish the two.

Question 5: Is There a History of Congenital Strabismus or Abnormal Head Position?

The term strabismus refers to any ocular misalignment of the eyes, but may specifically be used to refer to a congenital misalignment which typically reflects a deficiency in higher-order neuromuscular control of eye position, and may also reflect cranial neuropathies or muscle defects. Chronic head turns or tilts are a common compensatory response. Surprisingly, many patients will not include a remote history of strabismus in their past medical history until specifically asked, and most will not consider an abnormal head position important. Since adult-onset diplopia may result from a decompensation of a childhood strabismus, the examiner should always inquire about prior strabismus, a ''lazy eye,'' eye patching as a child, childhood eye surgery, and any abnormal head positions.

Copyright © American Academy of Neurology. Unauthorized reproduction of this article is prohibited.

KEY POINTS

- The diplopia examination begins with testing of ductions (the movement of each eye individually), versions (both eyes moving in the same direction), and vergences (the eyes moving in opposite horizontal direction). Forced duction testing can be performed by an ophthalmologist and may reveal a restriction suggestive of orbital disease.
- A tropia is a misalignment of the eyes that manifests even with both eyes open. A phoria is a misalignment that is only present when binocular vision is disrupted, as when covering one eye.

Question 6: Are Associated Pain, Headache, or Neurologic Symptoms Present?

Headache may accompany aneurysmal third nerve palsies but also occurs in 62% of ''microvascular'' cranial neuropathies,[5] which refer to infarctions of the cranial nerves presumably due to insufficiency of the vasa nervorum, typically in patients with vascular risk factors such as hypertension or diabetes mellitus. In patients aged 55 or over, the presence of a concurrent headache, scalp tenderness, or jaw claudication should raise the question of temporal arteritis. Finally, pain with eye movement suggests orbital disease, such as idiopathic orbital inflammation, or an orbital apex lesion.

EXAMINATION

Motility: Ductions, Versions, and Vergences

A careful assessment of ocular motility is essential to localization and diagnosis of diplopia. Examining each eye individually (ductions) may reveal subtle limitations of movement in one eye that could be missed if visualized alongside a fellow eye with greater limitations. This is followed by an examination of both eyes together, versions. See **Supplemental Digital Content 8-1**, *links.lww.com/CONT/A124* for a demonstration of testing of versions. To test versions, the patient is asked to fixate on a target which is then slowly moved laterally, testing the lateral rectus of the abducting eye and medial rectus of the adducting eye. Once in lateral position, the target is moved superiorly and then inferiorly. This will test the superior rectus and inferior rectus, respectively, in the abducted eye and the inferior oblique and superior oblique, respectively, in the adducted eye. The same is then repeated in contralateral gaze. Torsional motility may be noted to occur in opposition to head or body tilting when aided by the presence of prominent conjunctival vessels. Convergence and divergence may be tested by the slow movement of the fixation target in toward the nose and outward again.

Forced Ductions

In cases of orbital disease, diplopia frequently results from restriction of an extraocular muscle due to infiltration, fibrosis, or bony entrapment following trauma. In such cases, a worsening in a certain direction suggests restriction of the antagonist muscle. For example, a vertical diplopia that worsens in upgaze in a patient with thyroid eye disease is likely to reflect inferior rectus restriction rather than superior rectus weakness. Ophthalmologists, after anesthetizing the cornea, may attempt to move the eye passively by gently grabbing hold of the conjunctiva with a forceps or even two Q-tips. If the eye still will not move in the direction of weakness, a restrictive etiology is likely.

Misalignment: Tropias and Phorias

In some cases, diplopia occurs in patients with full or near-full motility of both eyes but whose eyes are nevertheless misaligned. This suggests congenital strabismus but also is typical for skew deviations,[6] and even in cases of some ocular motor palsies, the limitations in motility may be subtle. When the misalignment is present with both eyes open, it is called a heterotropia or tropia, but if it manifests only when stereo fusion is disrupted (eg, with unilateral eye closure), it is termed a heterophoria or phoria. Prefixes may be used to qualify the direction of the misalignment: exotropia refers to outward deviation, esotropia to inward deviation, hypertropia to

Copyright © American Academy of Neurology. Unauthorized reproduction of this article is prohibited.

elevation of an eye, and hypotropia to a lower eye. Exophoria, esophoria, hyperphoria, and hypophoria are used to describe the misalignment for phorias. Several methods are used to determine the relative position of the two eyes in various fields of gaze and ultimately localize the cause of the diplopia.

Cover Testing

When the patient's visual acuity, ability to move the eyes, and ability to cooperate are all intact, cover testing may help indicate a tropia or phoria.

Cover-uncover test. The cover-uncover test differentiates a tropia from a phoria. First, one eye is occluded while the patient is fixating on a target. If the fellow eye shifts to pick up fixation, it must have been deviated prior to occlusion of the other eye, and one can conclude that a tropia is present. If, however, the fellow eye does not shift, but instead the occluded eye moves in the direction of weakness while covered (noted as the eye returns to fixation after the occluder is removed), a phoria is present. In either case, the type of tropia or phoria can be determined by noting the direction of refixation of the deviated eye. An inward movement of an eye when it is uncovered informs the examiner that the eye had been outwardly deviated when covered, which is called an exo (tropia or phoria). An outward movement with uncovering reflects a prior inward deviation or eso. If the uncovered eye moves downward, it is consistent with an ipsilateral hyper or contralateral hypo.

Alternate cover test. By alternating which eye is covered, the physician will bring out phorias and tropias, and can quickly determine the direction of deviation. Even when misalignment is the result of unilateral eye weakness, both eyes will move when uncovered during the alternate cover test. This results from the Hering law of equal innervation, which states that an equal force must be supplied to both eyes. In a mild left abducens palsy, for example, a covered left eye will deviate medially and refixate to the target when uncovered. When the right eye is covered, however, a good deal of leftward force must be applied to pull the weak left eye to fixation and that same force applied to the healthy right eye deviates it medially (secondary deviation). When it is uncovered, it too will have to refixate from an adducted position. Finally, a prism rod with multiple strengths may be placed over one eye and steadily increased until the refixation movements cease, thus estimating the prism required to ameliorate the diplopia. Typically, patients benefit from a strength of 50% to 75% of the measured prism, ensuring some continued effort on their part. The examiner may perform the alternate cover test in the nine cardinal fields of gaze to look for changes in the degree of refixation. In the case of vertical deviations, checking in right and left head tilt is also helpful. When the patient is gazing in the direction of an eye's weakness, the movements will be greater (**Supplemental Digital Content 8-2**, *links.lww.com/CONT/A125*).

Maddox Rod Testing

A Maddox rod is a red lens with multiple aligned prisms that will convert a white light into a red line. During testing, the lens is held over the right eye (by convention), while a light is shined at the patient. The left eye will see the white light, but the right eye will see a red line, which can be horizontal (to test vertical alignment) or vertical (to test horizontal alignment). Thus, akin to covering one eye, stereo fusion is disrupted, and phorias will emerge. A review of horizontal and vertical Maddox rod techniques is presented in **Figure 8-3** and **Figure 8-4**,

KEY POINT

- Ocular misalignments (phorias and tropias) may be observed using the alternate cover test or Maddox rod test. Testing in the nine cardinal fields of gaze as well as in head tilt can elucidate the pattern of weakness and help localize the responsible lesion.

Copyright © American Academy of Neurology. Unauthorized reproduction of this article is prohibited.

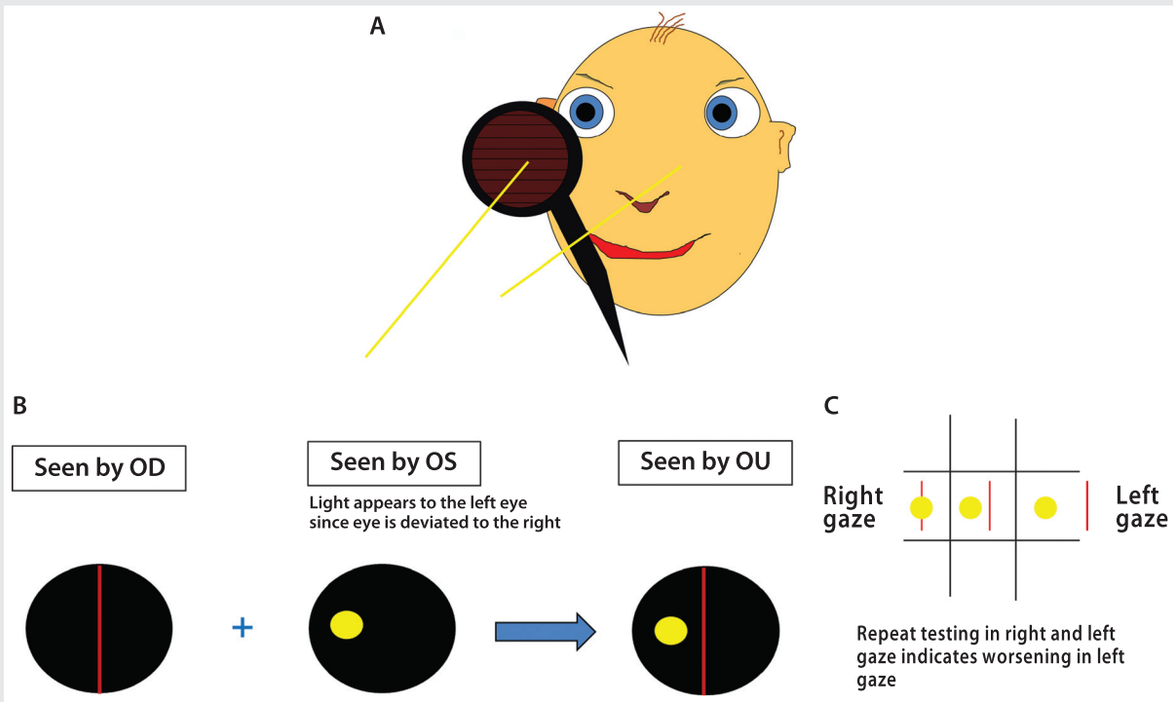

FIGURE 8-3 Horizontal Maddox rod. *A*, Patient with a left esotropia. *B*, The right eye (OD) sees a vertical red line in the middle, but the left eye (OS) sees the white light (yellow in the figure for illustrative clarity) deviated to the left. The result is a white light to the left of the red line with both eyes (OU) open. *C*, Repeat testing in right and left gazes indicates a worsening in left gaze, consistent with lateral rectus weakness of the left eye.

respectively. Although its limitations, including the induction of excessive esophoria and inability to see the red line in some patients, have been noted since the beginning of the 20th century,[7] Maddox rod testing remains a practical and fast means of assessing phorias in most patients.

Parks-Bielschowsky Three-Step Test

As described by Marshall Parks,[8] a superior oblique palsy can be identified in three steps:

1. Determine which eye is hypertropic.
2. Confirm that the hypertropia worsens in contralateral gaze.
3. Confirm that the hypertropia worsens in ipsilateral head tilt.

An ophthalmologist might answer these questions by measuring the prism needed to correct the hypertropia in each position, but the author finds that eliciting a subjective response from the patient regarding the distance between the red line and white light on the Maddox rod test (in each direction of gaze and in head tilt) provides a faster and, in most cases, equally reliable solution. The test is not perfect, as this pattern may be mimicked by orbital disease or ocular myasthenia gravis.

Double Maddox rod. Bilateral trochlear palsy may be seen after head trauma or congenitally occur. It may be elusive, as one palsy dominates in primary gaze, but will produce a characteristic pattern of a hypertropia in lateral gaze of whichever eye is adducted and a V-pattern esotropia (meaning that the esotropia is worse in downgaze) due to weakness of the

Copyright © American Academy of Neurology. Unauthorized reproduction of this article is prohibited.

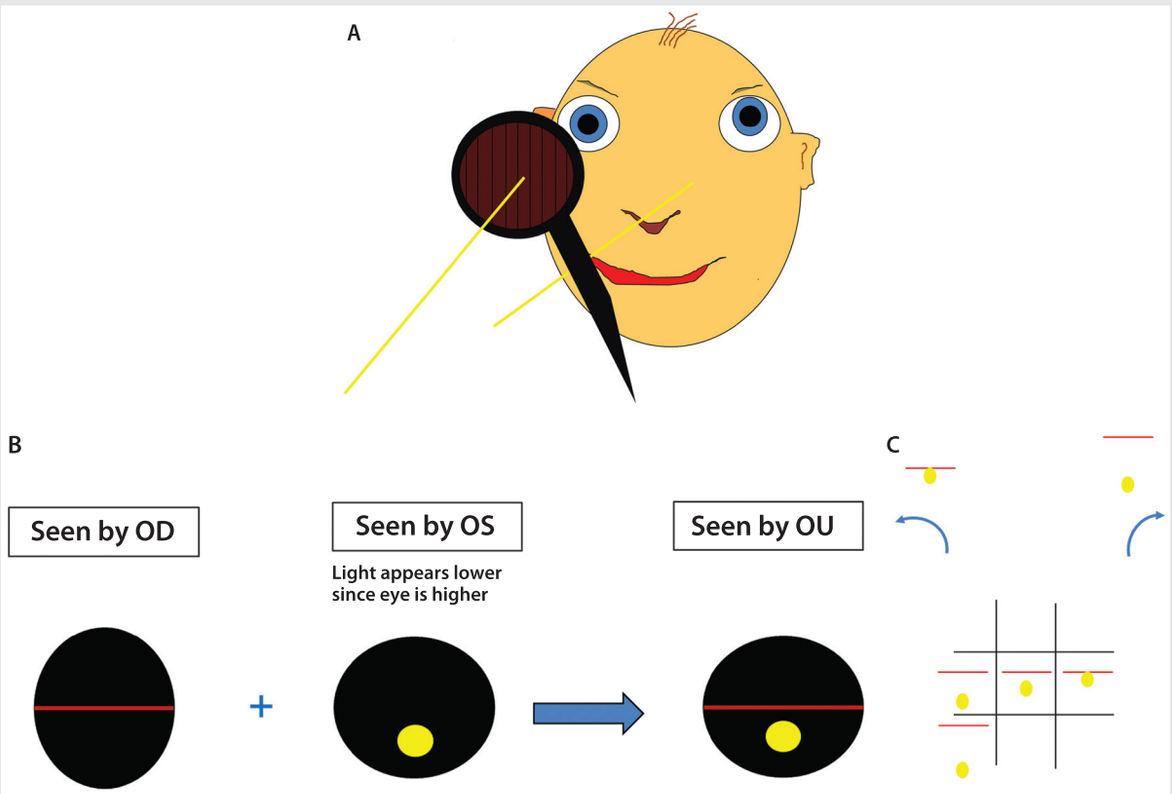

FIGURE 8-4 Vertical Maddox rod. *A*, Patient with a left hypertropia. *B*, The right eye (OD) sees a horizontal red line in the middle, but the left eye (OS) sees the white light (yellow in the figure for illustrative clarity) below it. The patient sees a white light under a red line with both eyes (OU) open, consistent with a left hypertropia. *C*, The hypertropia is worse in right gaze, downgaze, and left head tilt, all consistent with a fourth nerve palsy.

superior oblique's tertiary function, ie, abduction. Because the superior oblique intorts the eye (rolls it along the coronal plane so that the top of the eye rotates toward the nose), a unilateral fourth nerve palsy will result in extorsion of an eye (the top of the eye is rotated toward the ear), but by only 10 degrees or less. In bilateral trochlear palsies however, intorsion of both eyes is affected so that the combined extorsion is higher, at a median of 14.5 degrees.[9] The double Maddox rod test allows the neuro-ophthalmologist to quantify the relative extorsion of the two eyes and detect the presence of bilateral trochlear palsies. One Maddox lens is placed at 0 degrees while the other is offset by about 10 degrees and a light is shined at the patient. Using a knob, the patient is asked to rotate the second lens until the red lines "line up." The resulting deviation reflects the total relative extorsion between the two eyes.

Hirschberg Test

One may more easily detect a tropia by comparing the location of the reflection of a penlight on the cornea of both eyes, termed the Hirschberg test. This is particularly useful when poor vision or cooperation precludes cover testing or Maddox rod examination. In the case of an exotropia, for example, the reflection will fall medial

KEY POINT

- Using a Maddox rod over each eye (double Maddox rod test), the practitioner can estimate the degree of ocular torsion between the two eyes, as is seen in cases of fourth nerve palsy.

Copyright © American Academy of Neurology. Unauthorized reproduction of this article is prohibited.

KEY POINTS

- The general neurologic examination, testing of afferent visual function, and the funduscopic findings all may help localize the lesion responsible for diplopia.
- Extraneous workups can be avoided by the recognition of congenital strabismus patterns. A tolerance by the patient of strong prisms (fusional amplitude), the presence of chronic contralateral head tilt in past photographs in cases of trochlear nerve palsy, and globe in cases of abducens palsy (Duane syndrome) are all suggestive of congenital disease.

to the pupillary axis in at least one eye. In the Krimsky test, various prisms may be held in front of an eye until one normalizes the location of the reflection, thus estimating the degree of misalignment and required prism needed to treat the diplopia. This test has recently been shown to correlate well with measurements using cover testing.[10]

Funduscopy

Funduscopy may provide additional clues to the etiology of diplopia. Papilledema in the setting of esotropia suggests intracranial hypertension-related abducens palsies. Retinal pigmentary deposition in association with diffuse ophthalmoplegia and ptosis suggests the mitochondrial disease Kearns-Sayre syndrome. Finally, retinal artery occlusion or anterior ischemic optic neuropathy, in association with an acute ocular motor palsy, reflects temporal arteritis until proven otherwise.

Viewing the fundus under high magnification can help the neuro-ophthalmologist confirm torsional deviations of either eye. Dilation is necessary, as the optic disc and fovea would need to be seen simultaneously. A horizontal light beam projected across the fovea will typically cross the optic disc with approximately one-third of the disc below it.[11] Cyclotorsion (turning in the coronal plane) of the eye in either direction will cause the beam to intercept the disc either higher or lower than normally predicted.[12]

Afferent Neuro-ophthalmic Examination

In any patient with diplopia, assessment of afferent visual function is essential. A retrobulbar optic neuropathy accompanying cranial nerve III, IV, or VI dysfunction suggests an orbital apex syndrome, while a bitemporal hemianopia suggests a suprasellar lesion with chiasmal compression and spread to the cavernous sinus, such as a large pituitary adenoma or pituitary apoplexy. The recognition of amblyopia in an eye, which manifests as decreased acuity in the absence of specific optic nerve field defects, is helpful in identifying a decompensation of a congenital phoria that was associated with the amblyopia.

General Neurologic Examination

A complete neurologic examination is essential to the localization and diagnosis of most disorders responsible for diplopia. For example, the recognition of a hemiparesis contralateral to a third nerve palsy suggests injury at the level of the third nerve fascicle as it passes through the cerebral peduncle. Areflexia would suggest Guillain-Barré syndrome or the Miller-Fisher variant, while an associated delirium or amnesia raises the specter of Wernicke encephalopathy.

PATTERNS OF DISEASE

Detecting Infantile Strabismus

Patients with a strabismus of infantile onset may manage to fuse for years, until age, disease, or drug exposures lead to an eventual decompensation and associated diplopia. Determining when this is the case is crucial in preventing needless workups and anxiety. Examples of infantile strabismus syndromes include congenital trochlear nerve palsies, Duane syndrome (abducens palsy with globe retraction in adduction), Brown syndrome (congenital fibrosis of the superior oblique tendon with depression in adduction), and inferior oblique overaction with an associated V-pattern esotropia. Methods used to detect such cases are summarized in **Table 8-1**.

Ruling Out Orbital Disease

Double vision may be the first or only sign of diseases affecting the orbit, including thyroid eye disease, inflammatory disease, trauma, infection, neoplasm, and

Copyright © American Academy of Neurology. Unauthorized reproduction of this article is prohibited.

TABLE 8-1 Testing for Infantile Strabismus

Examination	Description
Fusional amplitude	In the case of vertical phorias, chronic compensation results in a tolerance for a wide range of vertical deviations such that the patient will fuse the images and not experience diplopia even when more prism is given than required. This range is known as the fusional amplitude. Scores of >3 diopters suggest chronicity.
Worsening of trochlear palsy in upgaze	This finding suggests secondary inferior oblique overaction that occurs over many years.
Family album tomography (''FAT scan'')	A review of older pictures of the patient may reveal a head tilt contralateral to the hypertropia, offering further reassurance of a congenital trochlear palsy.
Forced duction	In cases of Brown syndrome, the adducted eye will not elevate with passive attempts because of superior oblique tendon restriction. This distinguishes it from an inferior oblique paresis.

KEY POINTS

- Orbital disease is a frequent mimicker of neurogenic diplopia and is most frequently the result of orbital inflammation, thyroid eye disease, or orbital tumors.
- Signs of orbital disease include proptosis, conjunctival injection or swelling, resistance to retropulsion, and a positive forced duction test.

congenital myopathies. Such conditions may be missed by the neurologist who is not as accustomed to thinking about orbital disease. Red flags include proptosis, periorbital edema, resistance to retropulsion, and lid retraction. An ophthalmologist may quantify the degree of proptosis using a Hertel ophthalmometer, which uses angled mirrors to simultaneously project lateral views of both eyes with superimposed rulers. However, the general neurologist may be able to estimate the severity of proptosis simply by viewing the patient from the side and noting the anterior extent of one eye versus the other. Resistance to retropulsion refers to a limitation in the degree of backward movement of the globe when gently pushed on with two fingers during eye closure. Its presence suggests a retrobulbar tumor or thyroid eye disease, although in one study the physicians' estimation of the resistance did not reliably predict the actual force needed to push the eye back.[13]

As previously mentioned, the motility limitation in orbital disease often reflects antagonist muscle restriction rather than weakness of the agonist muscle. MRI of the brain only shows a few slices through the orbits and will often miss orbital disease. Thin cuts through the orbits, with T1 fat-saturated images (removing the bright T1 signal of intraorbital fat) increase sensitivity for orbital disease, while orbital CT is especially useful in cases of trauma and suspected bony abnormalities. As orbital disease is not covered elsewhere in this issue of CONTINUUM, special attention will be given here.

Orbital inflammation. Idiopathic orbital inflammation (formerly known as orbital pseudotumor) can affect the muscles, soft tissue, and even optic nerve, potentially resulting in blindness. In some cases, only one muscle is affected, producing an orbital myositis. In addition to diplopia, patients typically report pain, especially with

Copyright © American Academy of Neurology. Unauthorized reproduction of this article is prohibited.

eye movement, proptosis, and, in severe cases, vision loss. Sarcoidosis, rheumatoid arthritis, and some vasculitides (including granulomatosis with polyangiitis[14] and, rarely, giant cell arteritis[15]) may lead to orbital inflammation (**Figure 8-5**). Recently, some cases of idiopathic orbital inflammation, particularly with inflammation of the ocular adnexa (ie, eyelids, lashes, extraocular muscles, and lacrimal system), have been linked to IgG4, a subclass of IgG that appears linked with multiple forms of systemic inflammatory disease.[16] **Table 8-2** provides a review of inflammatory orbital disease and appropriate testing.

Treatment of idiopathic orbital inflammation includes corticosteroids, nonsteroidal anti-inflammatory drugs (NSAIDS), and, in rare cases, radiation therapy, but in one 10-year retrospective study evaluating all treatment modalities, only 63% showed a long-term complete remission.[17]

Thyroid eye disease. A lymphocytic inflammatory infiltration of the orbital tissues occurs in approximately 50% of patients with Grave disease and some with Hashimoto thyroiditis.[18] Smoking,

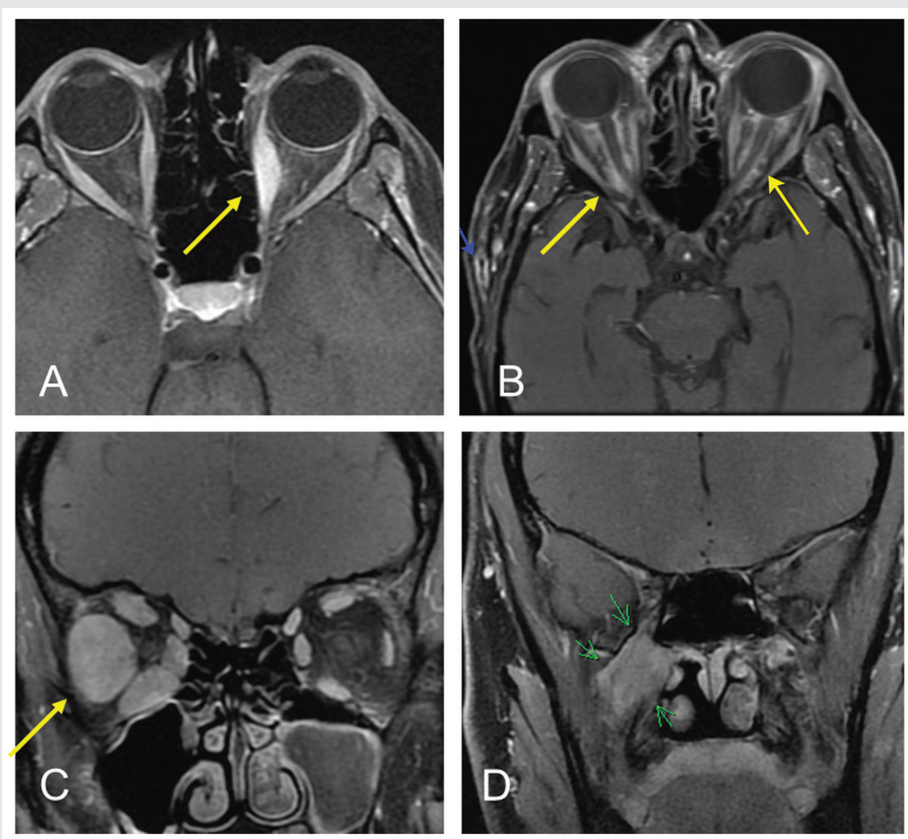

FIGURE 8-5 Examples of orbital inflammation in three patients. *A*, Orbital myositis of medial rectus (*yellow arrow*) seen on orbital MRI. The diagnosis was missed on multiple brain MRIs. *B*, Bilateral orbital inflammation (*yellow arrows*) was the first sign of disease in this patient with temporal arteritis. Note temporal artery enhancement (*blue arrow*). *C*, Massive infiltration of eye muscles on the right, especially lateral rectus (*yellow arrow*) was seen in this patient with proptosis. Elevated angiotensin-converting enzyme (ACE) level and extension outside of the orbit to the pterygopalatine fossa in the same patient (*D*, *green arrows*) suggested sarcoidosis.

Copyright © American Academy of Neurology. Unauthorized reproduction of this article is prohibited.

TABLE 8-2 **Types of Inflammatory Orbital Disease and Workup**

Type	Workup
Sarcoidosis	Chest CT, angiotensin-converting enzyme (ACE) level
Thyroid eye disease	Thyroid function tests, thyroid antibodies
Systemic lupus erythematosus	Antinuclear antibody (ANA)
Rheumatoid arthritis	Rheumatoid factor (RF)
Granulomatosis with polyangiitis	Central antineutrophilic cytoplasmic antibody (c-ANCA)
Giant cell arteritis	Erythrocyte sedimentation rate (ESR), C-reactive protein (CRP), temporal artery biopsy

family history, and female sex are risk factors. Clinical findings include proptosis, conjunctival injection (redness) over points of eye muscle insertion, chemosis (swelling of the conjunctiva), and lid edema and erythema (**Figure 8-6**). The difficult task of distinguishing thyroid eye disease from other inflammatory

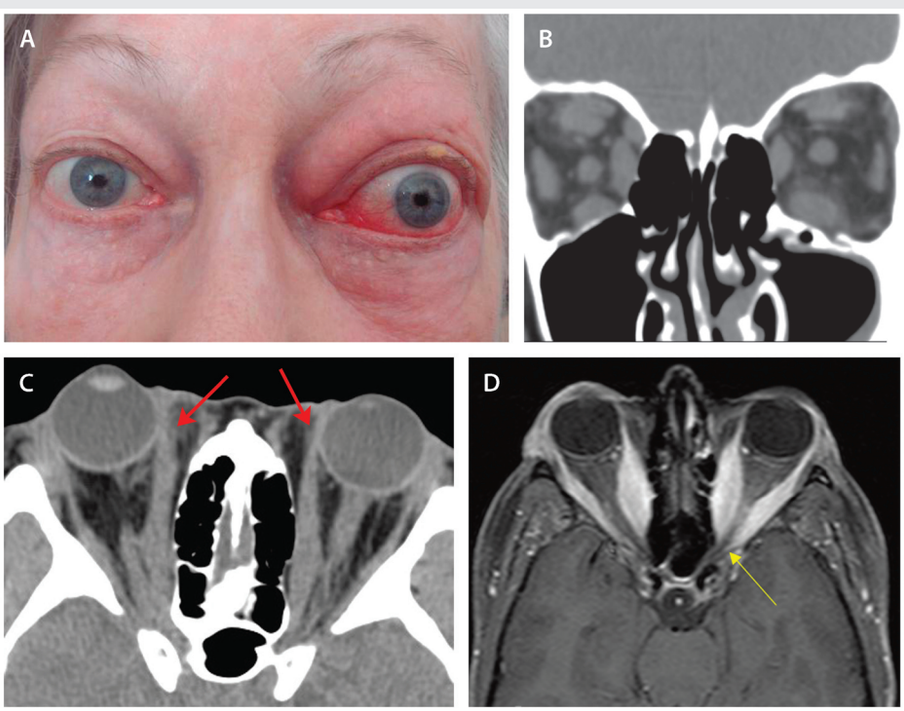

FIGURE 8-6 Thyroid eye disease. *A*, A 65-year-old woman presented with lid erythema and edema, lid retraction, conjunctival injection, chemosis, and proptosis of both eyes. Note the widening of the palpebral fissure of the left eye. *B*, Coronal noncontrast CT reconstruction of the orbits revealed thickening of multiple extraocular muscles. *C*, Axial noncontrast CT of the orbits. Note the relative sparing of the medial rectus tendons in both eyes (*red arrows*). *D*, Axial postcontrast MRI of a different patient who presented with diplopia and a left optic neuropathy. Note the crowding at the left orbital apex (*yellow arrow*) consistent with thyroid eye disease.

Copyright © American Academy of Neurology. Unauthorized reproduction of this article is prohibited.

KEY POINTS

- Signs of thyroid eye disease include lid retraction, lid lag, increased intraocular pressure in upgaze, and sparing of the tendons on orbital CT or MRI.
- The orbit may be affected by a wide variety of neoplasms that cause diplopia, including benign lesions (eg, dermoid cysts, cavernous hemangiomas) and malignant lesions (eg, non-Hodgkin lymphoma, adenoid cystic carcinoma, and metastases).
- Double vision may result from orbital trauma, typically due to muscle entrapment within a bony fracture. These lesions may be missed on general brain MRI, so orbital imaging should be pursued in any cases of suspected trauma-related diplopia.

diseases of the orbit is made easier by the recognition of several classic findings, described in **Table 8-3**.

Orbital neoplasm. Orbital neoplasm, whether in the form of a bulky tumor or diffuse infiltration of muscles and soft tissues, may present with diplopia. Proptosis and resistance to retropulsion are common features, but superior orbital tumors may result in a downward displacement of the globe in the orbit, hypoglobus, while metastatic breast cancer may cause enophthalmos, a recession of the globe within the orbit.[21] **Table 8-4** demonstrates the relative incidence of orbital tumors in one study.[22] While the lack of diffusion-weighted signal on MRI was shown to predict benign disease with a 75% concordance rate in one study,[23] biopsy is necessary for a definitive diagnosis. **Figure 8-7** describes the rare occurrence of a granulocytic sarcoma in the orbit presenting as diplopia.

Diplopia associated with trauma and defects in the bony orbit. As demonstrated by **Figure 8-8**, direct mechanical orbital trauma may cause ophthalmoparesis through restriction and entrapment of orbital muscles or even muscle disinsertion from the globe. Hypoglobus and enophthalmos are common. Orbital CT is the preferred imaging study in such cases as it clearly shows bony fractures and defects. Early surgical repair of the orbital wall with relaxation of involved muscles can help prevent scarring.

Rarely, obstruction of the ostium of the maxillary sinus can block aeration, producing a negative pressure that pulls down on the inferior wall of the orbit. This silent sinus syndrome may result in enophthalmos and a downward displacement (hypoglobus) of the eye, the latter of which may lead to a vertical diplopia.[24]

Iatrogenic Diplopia

Trauma to extraocular muscles may occur after cataract, retina, orbital, and sinus surgery. Diplopia occurs in 0.17% to 0.85% of patients following cataract extraction.[25] In one large study, approximately 25% of cases

TABLE 8-3 Findings in Thyroid Eye Disease

Finding	Description
Lid retraction	Results from circulating thyroid hormone and, eventually, infiltration and scarring of the levator palpebrae.
Lid lag (Von Graefe sign)	Up to 8% of patients with thyroid eye disease demonstrate a delay in the lowering of the lid with globe depression.[19] Both lid retraction and lag may result in secondary keratopathy.
Increased intraocular pressure in upgaze	Greater than 4 mm Hg, presumably a result of compression by inflamed inferior rectus; nonspecific and has been reported in controls.[20]
Tendon sparing	Orbital imaging demonstrates enlargement and increased enhancement of the muscles and/or soft tissue of the orbits in both thyroid eye disease and idiopathic orbital inflammation, the primary difference being that the muscle tendons are typically spared in thyroid eye disease.

Copyright © American Academy of Neurology. Unauthorized reproduction of this article is prohibited.

TABLE 8-4 **Orbital Tumors and Pseudotumors: Lesion Types in 268 Consecutive Patients Undergoing Biopsies of Suspected Orbital Tumors[a]**

Tumor	% of All Orbital Tumors
Secondary orbital tumor	26%
Lymphoproliferative lesion (74% of which were lymphoma)	25%
Metastatic tumor	10%
Epithelial lacrimal gland tumors (67% of which were adenoid cystic carcinoma)	10%
Inflammatory condition	8%
Vascular lesion	7%
Mesenchymal tumor	7%
Optic nerve or nerve sheath tumor	3%
Peripheral nerve tumor	1%
Histiocytic lesion	1%
Cystic lesion	1%
Miscellaneous	<1%

[a] Modified with permission from Shinder R, et al, Head Neck.[22] © 2010 Wiley Periodicals, Inc. *onlinelibrary.wiley.com/doi/10.1002/hed.21498/abstract*.

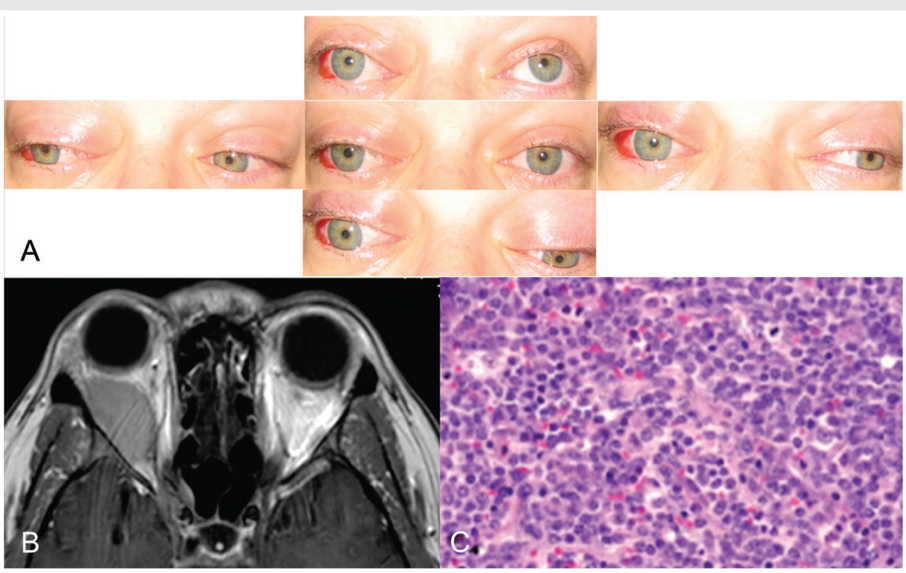

FIGURE 8-7 Orbital tumor. A 20-year-old painter presented with oblique diplopia and a red and proptotic eye on the right (*A*). Neuro-ophthalmic examination revealed limitation of adduction, elevation, and depression of the right eye. Thyroid eye disease was suspected, but MRI orbits revealed a mass lesion in the lateral-superior orbit (*B*). A complete cell blood count showed a leukocytosis with blasts, and biopsy of the lesion (*C*) confirmed a granulocytic sarcoma. Chemotherapy was initiated for systemic leukemia and, within days, visual symptoms resolved (*not shown*) and the patient remained in remission.

Copyright © American Academy of Neurology. Unauthorized reproduction of this article is prohibited.

KEY POINTS

- Ocular myasthenia presents with isolated fatigable ptosis and/or ophthalmoplegia and is often accompanied by fatigable upgaze, enhanced ptosis, and a lid twitch.
- Screening for ocular myasthenia includes the edrophonium test, sleep test, and ice test. The disease may be confirmed by the finding of acetylcholine receptor antibodies (although these are only 50% sensitive), or a decrement on repetitive nerve stimulation. The diagnosis is further supported by a finding of jitter on single fiber EMG.

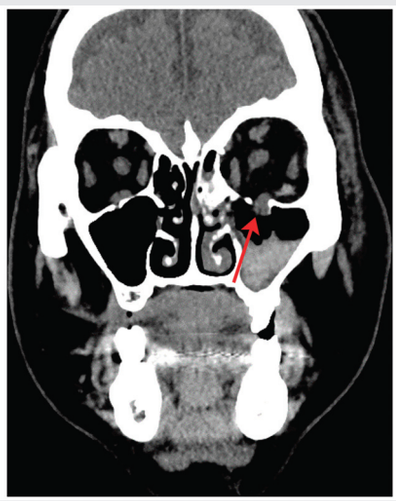

FIGURE 8-8 Muscle entrapment. A previously healthy 53-year-old woman reported vertical diplopia after falling down the stairs. Examination showed limitation of elevation, depression, and adduction of the left eye, suggestive of a posttraumatic, partial third nerve palsy. With an unremarkable MRI of the brain and magnetic resonance angiography (MRA) of the head, the patient was prepared for discharge. As no ptosis or mydriasis was present, a CT of the orbits was obtained and revealed a blowout fracture of the inferior orbit and protrusion of the inferior rectus through the defect with associated entrapment (*red arrow*).

involved muscle restriction or paresis,[26] ostensibly due to trauma to the muscle cone (where the origins of the extraocular muscles coalesce in the posterior orbit) from retro-orbital anesthesia, which occurs more frequently in the left eye because of a greater difficulty of left eye injections in right-handed surgeons. In these cases, most patients had either a hypotropia (54%) or hypertropia (44%) of the affected eye. Other mechanisms include an unmasking of a congenital phoria with resumption of binocular vision (34%), a prismatic effect by the implanted lens (4%), and concurrent onset of systemic disease (5%).

Detecting Myasthenia Gravis

Essentially any pattern of ophthalmoplegia or ocular deviation can be mimicked by myasthenia gravis, in which the neuromuscular blockade of acetylcholine receptors has a particular predilection for the highly metabolic and fatigable extraocular muscles. An inherently simplified folding of the postsynaptic endplate in extraocular muscles makes them susceptible to the effects of further simplification associated with acetylcholine receptor destruction, thus predisposing them to loss of the safety factor that ensures proper neuromuscular transmission.[27] A recent history of trouble breathing, swallowing, or walking may suggest the disease, but generalized symptoms may be absent (ocular myasthenia). The concurrent finding of fatigable ptosis is a red flag, but, in unclear cases, several examination techniques, summarized in **Table 8-5**, may prove pivotal in making the diagnosis.

These examination findings are complemented by further testing, which may include acetylcholine receptor antibodies (present in only 50% of ocular myasthenia cases), muscle-specific tyrosine kinase (MuSK) antibodies, repetitive stimulation nerve conduction testing, and single fiber EMG. **Figure 8-9** describes an examination of a patient with ocular myasthenia gravis. **Supplemental Digital Content 8-3**, *links.lww.com/CONT/A128*, demonstrates enhanced ptosis in a patient with the disease. Furthermore, improvement of either ptosis or ophthalmoplegia after injection of the acetylcholinesterase inhibitor edrophonium (edrophonium test),[35] or after 30 minutes of rest and lid closure (the sleep test),[36] or 2 minutes of application of ice (ice test)[37] suggests the diagnosis.

Trends

The existence of pure ocular myasthenia associated with the MuSK antibody is questionable. A large study of 110 patients with MuSK myasthenia described

Copyright © American Academy of Neurology. Unauthorized reproduction of this article is prohibited.

TABLE 8-5 Examination Findings in Ocular Myasthenia

Finding	Description
Fatigable upgaze	Maintain upgaze for at least 1 minute before assessing for fatigability.
''Cogan lid twitch[28]''	A rapid recovery in the neuromuscular junction while rested in downgaze results in enhanced release on return to primary gaze. Also described in cases of brainstem tumors,[29] parasellar tumors, and aneurysms.[30] Sensitivity is 50% and positive predictive value is 25%.[31]
Curtaining	Lifting of the weak lid leads to a slow drooping of the fellow lid, presumably related to the Hering law of equal innervation.
''Quiver movements[32]'' (lightning saccades)	Attributed to a relative preservation of the twitch fiber system responsible for the initiation of saccades, even as the tonic fiber system subserving later stages of the saccade is injured. Pale global singly innervated fibers, which fire at the onset of saccades and appear to govern the initial acceleration phase, possess a more complex postsynaptic folding than other extraocular muscle fibers,[33] which helps protect them from the effects of myasthenia. This may explain the presence of these lightning saccades.
Orbicularis weakness	Suggests ocular myasthenia gravis rather than cranial neuropathies.
Orbicularis ''peek'' sign	Small palpebral fissure widening with scleral show following a brief period of lid apposition against a patient's gentle closure. Seen in 3 of 25 patients with ocular myasthenia gravis and 0 of 200 control subjects.[34]

36% with purely ocular symptoms at onset, but all subsequently generalized.[38] However, some case reports have described chronic MuSK-related ocular myasthenia without generalization, in one case over a 10-year period without immunosuppression.[39] The management of ocular myasthenia remains controversial. Since 50% to 80% of patients progress to generalized myasthenia, prevention of this transformation is a central goal of treatment, in addition to ocular symptom control. Several studies have suggested that treatment of ocular myasthenia with steroids may decrease the conversion rate to generalized myasthenia,[40,41] although the conclusion is tempered by the retrospective, nonrandomized nature of these studies. Whether patients with ocular myasthenia without thymoma should undergo thymectomy has yet to be conclusively determined. In a recent retrospective study of 115 Chinese patients with ocular myasthenia who underwent transsternal thymectomy, none developed generalized disease over a mean follow-up of 44.5 months, suggesting a role for the surgery even in purely ocular patients, but prospective, controlled trials are needed to more conclusively confirm the benefits of thymectomy.[42]

Cranial Neuropathies

Disease of the cranial nerves is covered in detail in the article ''Diplopia Due to Ocular Motor Cranial Neuropathies'' by Wayne T. Cornblath, MD, FAAN, in this issue of CONTINUUM.

Copyright © American Academy of Neurology. Unauthorized reproduction of this article is prohibited.

KEY POINT

- In the presence of a complete third nerve palsy, fourth nerve function may be examined by looking for intorsion of the globe during combined abduction-depression.

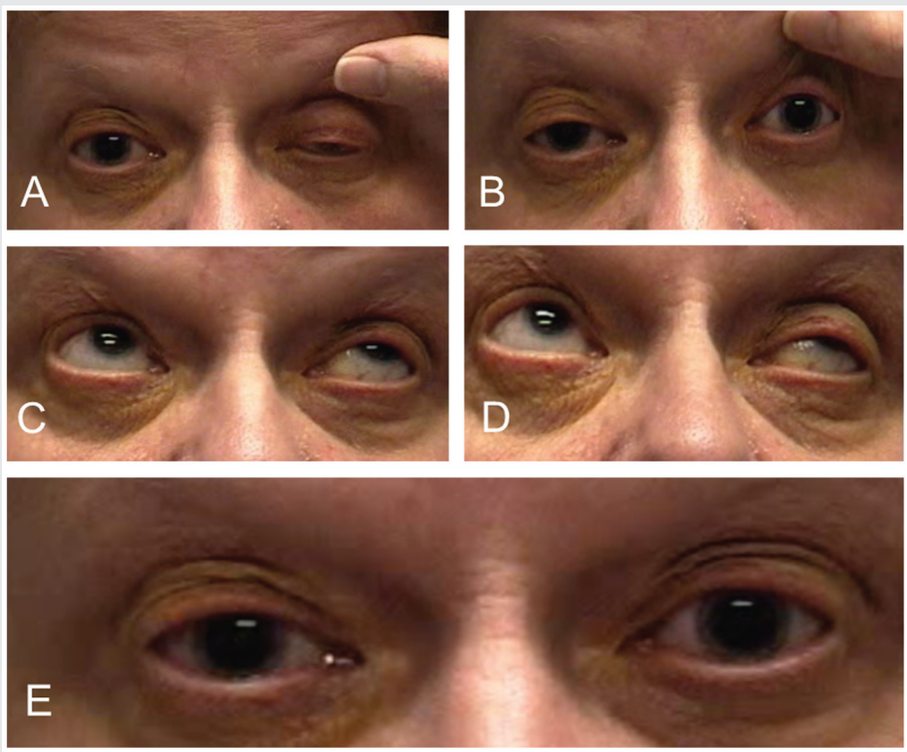

FIGURE 8-9 Ocular myasthenia. Eye appearance at rest (*A*) with prominent, nearly complete left ptosis. Demonstration of enhanced ptosis or curtaining (*B*) shows development of right ptosis with manual elevation of the left lid. Eye appearance after a few seconds of upgaze (*C*) shows left ptosis, but inferior third of the pupil and iris are visible. Eye appearance after 120 seconds of upgaze (*D*) shows increased left ptosis with nearly complete coverage of the pupil and iris. *E*, Positive edrophonium test. Resolution of left ptosis 15 seconds after administration of 1 mg of edrophonium.

Courtesy of Janet C. Rucker, MD.

The presence of an oculomotor, trochlear, or abducens palsy may reflect compression, infiltration, inflammatory disease, or, especially in older patients, ischemia to the nerve. Multiple cranial neuropathies suggest disease of the brainstem, subarachnoid space, cavernous sinus, or, in the presence of an optic neuropathy, the orbital apex. Infectious, inflammatory, or neoplastic meningitic processes may present with diplopia due to infiltration of one of the ocular motor cranial nerves, as evidenced by a case of primary CNS lymphoma presenting with a third nerve palsy (**Case 8-1**).

Checking for trochlear nerve palsy in the presence of a third nerve palsy. When a complete third nerve palsy results in paralysis of the medial rectus, it is difficult to test for ipsilateral superior oblique weakness since it acts in the vertical plane during adduction. To test its function, the practitioner may instead bring the eye into the abducted position and ask the patient to look down, which should result in intorsion of the globe if the superior oblique is functional. Identifying concomitant trochlear nerve palsy alongside an oculomotor nerve palsy is crucial, in that it is unlikely to be the result of the common and relatively benign microvascular etiology[43] and suggests a localization either at the orbital apex or within the cavernous sinus.

Copyright © American Academy of Neurology. Unauthorized reproduction of this article is prohibited.

Case 8-1

A 78-year-old woman with hypercholesterolemia presented with diplopia and ptosis. The ptosis began 1 year ago and worsened later in the day. Two weeks ago, she awoke in the morning and noticed an oblique diplopia (the second image was higher and over to the right) that resolved with closure of either eye. She had tenderness over the head, intense fatigue, and a history of mild pain with chewing that had since resolved. A noncontrast brain MRI was reported as normal.

On examination, there was an esotropia on left gaze consistent with a left abducens palsy. An exotropia on right gaze was consistent with a left medial rectus palsy, and a left hypotropia worse in upgaze (and present in both adduction and abduction) indicated left superior rectus and inferior oblique weakness. Together with mild left ptosis, these findings suggested a left oculomotor palsy. Serum tests for temporal arteritis were normal. An MRI of the brain and orbits, with and without contrast, revealed bilateral enlargement and enhancement of the oculomotor, trigeminal, and facial nerves (**Figure 8-10**). Spine MRI demonstrated diffuse nerve root enhancement. Gangliosides to asialo monosialotetrahexosylganglioside (GM)1 and GM2 were mildly elevated. Lumbar puncture revealed 74 white blood cells/μL (93% lymphocytes), an elevated protein level of 101 mg/dL, a normal glucose level of 56 mg/dL, and elevated β_2-microglobulin level, but cytology and flow cytometry were negative. Over the next month, two more lumbar punctures were performed, both with similar profiles and negative cytology, but a gene rearrangement analysis of the third sample was consistent with a primary T-cell CNS lymphoma.

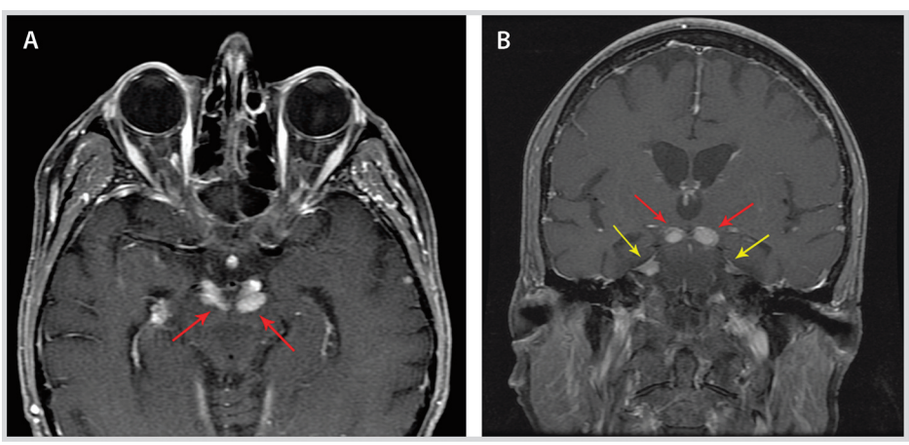

FIGURE 8-10 Imaging studies of the patient in **Case 8-1**. Enhancement and enlargement of bilateral oculomotor nerves is seen in an axial contrast-enhanced T1-weighted MRI (*A, red arrows*). *B,* Coronal contrast-enhanced T1-weighted MRI demonstrates enlargement and enhancement of the bilateral oculomotor nerves (*red arrows*) and facial nerves (*yellow arrows*).

Comment. This case demonstrates that diplopia may be one of the first and only symptoms of life-threatening disease, such as primary CNS lymphoma. Multiple diagnostic challenges were faced, including nonspecific symptoms suggestive of temporal arteritis and a reported fatigable ptosis, which, as shown here, may be present in third nerve palsies in addition to ocular myasthenia. The oblique nature of the patient's double vision helped predict the examination finding of a pupil-sparing oculomotor palsy, which in this age group is often microvascular. However, the examination revealed the unexpected finding of a concomitant abducens palsy. Once multiple cranial neuropathies were discovered, a leptomeningeal process was suspected. Finally, the limitation of noncontrast brain MRI in the diagnosis of diplopia is evidenced by the fact that a contrast MRI revealed obvious pathology of the cranial nerves soon after a noncontrast MRI was negative.

Copyright © American Academy of Neurology. Unauthorized reproduction of this article is prohibited.

Aberrant regeneration. Longstanding oculomotor nerve palsies may eventually result in regrowth of nerve fibers to the wrong target. Thus, the fibers meant for the medial rectus might innervate the levator palpebrae or constrictor pupillae muscles, resulting in lid elevation or pupillary constriction, respectively, during adduction. The presence of such aberrant regeneration confirms the chronicity of the injury and rules out a benign microvascular

FIGURE 8-11 A 23-year-old man presented with a left abduction defect (*A*) accompanied by a right gaze palsy (*B*). *C*, Fluid-attenuated inversion recovery (FLAIR) MRI (*left*) revealed a hyperintense mass lesion, which showed contrast enhancement on postcontrast T1-weighted MRI (*right*) within the pons. *D*, Funduscopic examination revealed evidence of a prior posterior uveitis. Further history revealed a history of chronic mouth ulcers. A diagnosis of neuro-Behçet disease was made. In addition to oral and genital ulcers, Behçet disease can cause a retinal vasculitis and brainstem inflammatory lesions. The clinical and radiologic examinations improved with steroid treatment (*not shown*).

Copyright © American Academy of Neurology. Unauthorized reproduction of this article is prohibited.

etiology (**Supplemental Digital Content 8-4**, *links.lww.com/CONT/A126*).

Supranuclear and Internuclear Diplopia

There are essentially two main causes of supranuclear or internuclear diplopia, which are discussed in greater detail in the article "Supranuclear Eye Movement Abnormalities" by Eric R. Eggenberger, DO, MSEpi, FAAN, in this issue of CONTINUUM.

Internuclear ophthalmoplegia. In the horizontal plane, disruption of the medial longitudinal fasciculus (**Figure 8-1**) results in failed adduction of the ipsilateral eye in contralateral gaze, with an abducting nystagmus of the contralateral eye, together termed an internuclear ophthalmoplegia. Sparing of convergence, if present, confirms internuclear ophthalmoplegia, as it would not be spared with dysfunction of the oculomotor nerve or the medial rectus muscle. Pontine disease may also affect the abducens nucleus or parapontine reticular formation, resulting in a conjugate gaze palsy in the direction opposite to the internuclear ophthalmoplegia, in which case it is known as one-and-a-half syndrome.[44] Alternatively, a conjugate gaze palsy may occur in one direction due to parapontine reticular formation injury, with an abducens palsy in the other direction due to injury of the abducens nerve fascicle (**Figure 8-11**).

Skew deviation. In the vertical plane, skew deviation is a vertical misalignment of the eyes resulting from inappropriate utricular-vestibular-ocular output, essentially mimicking the physiologic vertical deviations that normally compensate for head or body tilt. As can be seen in **Figure 8-2** (*red dashed line with arrows*), the responsible pathways emanating from the medial vestibular nucleus decussate in the pons, after which they travel along the medial longitudinal fasciculus, so that a mesencephalic skew is frequently accompanied by an internuclear ophthalmoplegia where the internuclear ophthalmoplegia is on the side of the higher eye. Because of this pontine decussation, a medullary skew will result in the ipsilateral eye being lower, while a mesencephalic skew will result in the ipsilateral eye being higher. **Figure 8-12** shows an example of skew.

KEY POINTS

- Internuclear ophthalmoplegia reflects a lesion of the medial longitudinal fasciculus and results in failure of adduction of the contralateral eye in attempted gaze to one side. When found in association with a contralateral gaze palsy, it is termed a one-and-a-half syndrome.
- When vestibular output from the utricle regarding tilt of the head or body is disrupted on one side, the result is a pathologic vertical misalignment of the eyes known as a skew deviation. The misalignment is often, but not always, comitant (equal in all directions of gaze).
- When skew deviation results from a medullary lesion, the ipsilateral eye is lower; when it results from a mesencephalic lesion, the ipsilateral eye is higher.

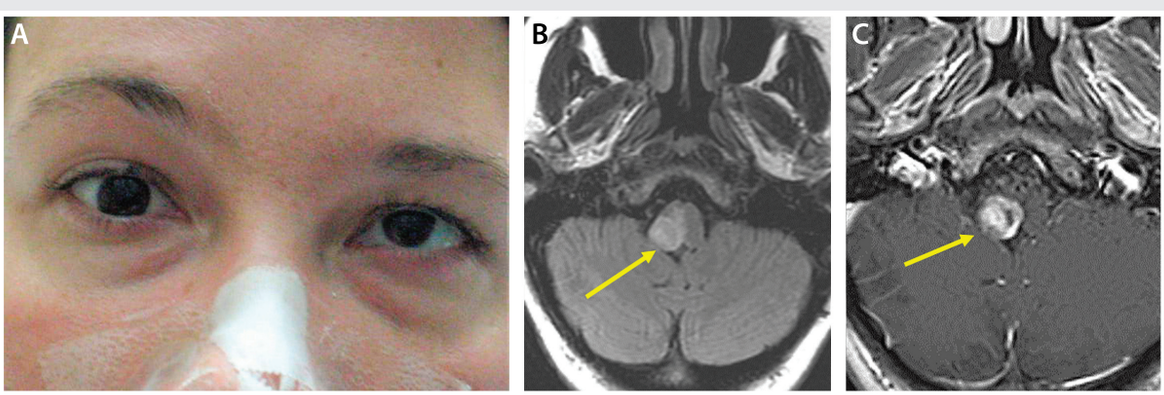

FIGURE 8-12 Skew deviation. A 22-year-old woman presented with a vertical diplopia and a left hypertropia. *A*, Trochlear nerve palsy was initially suspected until examination revealed a comitant hypertropia and improvement in the supine position, consistent with skew. Additional findings included a torsional nystagmus, right facial and left body numbness, and ocular-lateropulsion (a conjugate movement of the eyes toward the side of the lesion when the eyes are closed) all pointing to a right Wallenberg syndrome. MRI showed a fluid-attenuated inversion recovery (FLAIR) hyperintense (*B, arrow*) and enhancing (*C, arrow*) lesion in the right lateral medulla. Note that the lower eye was on the side of the lesion, which is the rule for medullary skew. Multiple sclerosis was diagnosed with the development of a subsequent lesion.

Copyright © American Academy of Neurology. Unauthorized reproduction of this article is prohibited.

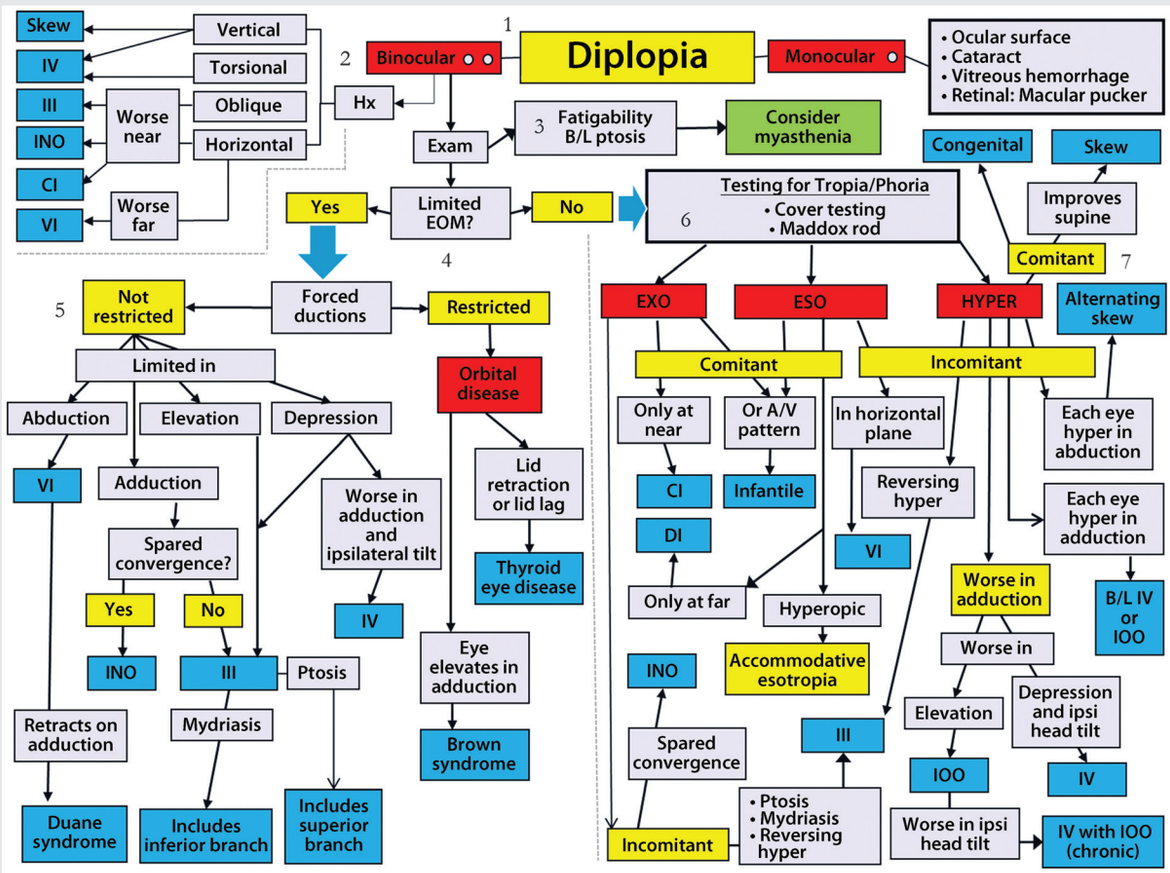

FIGURE 8-13 A framework for the assessment of the patient with diplopia. (1) Differentiate monocular from binocular diplopia. (2) If binocular, use history to predict localization. (3) Screen for fatigability and ptosis. If present, consider myasthenia. (4) If extraocular motility is limited, look for signs of orbital disease such as restriction, proptosis, or positive forced ductions. (5) If no restriction occurs, use the pattern of limitation to diagnose cranial neuropathy or internuclear ophthalmoplegia. (6) If extraocular motility is not limited but there is a tropia, use cover testing or Maddox rod to deduce the pattern of misalignment in multiple fields of gaze. (7) If vertical tropia is present, test for improvement in supine, indicative of skew. Note that exotropia or esotropia that is comitant in all directions suggests an infantile strabismus. Alternatively, an infantile esotropia or exotropia may be comitant in the horizontal plane, but worsen in upgaze or downgaze. When an exotropia is worse in upgaze (or an esotropia is worse in downgaze), it is termed a *V pattern*. When an exotropia is worse in downgaze (or an esotropia is worse in upgaze), it is termed an *A pattern*. These patterns are suggestive of infantile strabismus.

IV = fourth nerve palsy; III = oculomotor nerve palsy; Hx = history; INO = internuclear ophthalmoplegia; B/L = bilateral; CI = convergence insufficiency; VI = abducens palsy; EOM = extraocular movements; EXO = exotropia; ESO = esotropia; HYPER = hypertropia; A/V = A pattern or V pattern; DI = divergence insufficiency; IOO = Inferior oblique overaction.

KEY POINT

- The amplitude of the vertical misalignment appears to improve in the supine position in skew deviations but not with trochlear nerve palsies.

Distinguishing a skew deviation from a trochlear nerve palsy. While the typical pattern of skew deviation is comitant (meaning that the ocular misalignment is the same in all directions of gaze and in both directions of head tilt), alternative patterns may occur, and distinguishing skew from a fourth nerve palsy may be difficult. Some evidence suggests that the hypertropia of skew may improve in amplitude in the supine position, as the utricle is taken out of the plane of gravity.[45]

Convergence insufficiency. With Parkinson disease, or rarely with advancing age, convergence may become limited, and adduction of the dominant eye may be substituted, with the fellow eye left in primary position. Convergence insufficiency is also common in children, resulting in difficulty reading, often accompanied by horizontal diplopia. In

Copyright © American Academy of Neurology. Unauthorized reproduction of this article is prohibited.

childhood convergence insufficiency, improvement occurred in 73% of patients receiving office-based vergence/accommodative therapy with home reinforcement versus 35% with placebo therapy.[46] Prism glasses may be useful in adults with convergence insufficiency.

Trends

An esotropia at distance in patients over 65 years old in the absence of lateral rectus weakness has been termed distance esotropia of the elderly. A recent study suggests that this entity may progress over time, although the etiology for this condition remains unknown.[47]

The sensitivity of the third step of the Parks-Bielschowsky Three-Step Test for true bilateral superior oblique paresis was found to be only 40% in one study, although this limitation may in part result from false-positive errors using the study's criteria for the condition which was the observation of bilateral fundus extorsion (both fundi were observed to be rotated along the coronal plane so that the top of the retina was closer to the nose).[48]

A recent study reviewed 34 patients presenting to the emergency department with painful ophthalmoplegia. The authors found that third and sixth nerve palsies were the most common etiology, each accounting for 35% of the patients. Of note, CT and MRI of the head demonstrated low sensitivities for responsible etiologies (14% and 50%, respectively), while an erythrocyte sedimentation rate of greater than 50 mm/h was 100% sensitive for temporal arteritis, and pupillary mydriasis was 100% sensitive for aneurysmal causes.[49]

A ROADMAP FOR DIPLOPIA

Using the principles of history taking and examination discussed in this article, the neurologist should able to diagnose even the most challenging case of diplopia. An algorithm for the localization of diplopia can be found in **Figure 8-13**.

VIDEO LEGENDS

Supplemental Digital Content 8-1

Testing of versions in a man with a left orbital apex syndrome. Video shows a 75-year-old man who developed gradually progressive proptosis and ptosis in his left eye accompanied by an oblique diplopia. Visual field loss and a relative afferent pupillary defect ensued in the left eye as well. Neuro-ophthalmic examination reveals that the left eye is depressed and deviates laterally in primary gaze. Testing of versions show a lack of adduction and elevation of the left eye, and limited depression which, along with ptosis, is consistent with a left oculomotor palsy. Abduction of the left eye is also limited, consistent with a left abducens palsy.

The presence of a left oculomotor palsy and an ipsilateral abducens palsy is suggestive of either cavernous sinus syndrome or orbital apex syndrome. In this case, however, the presence of an optic neuropathy (*not shown*), which would not occur from a cavernous sinus lesion, is the clue that the site of the lesion is the orbital apex. The proptosis is also most consistent with an orbital apex mass, and MRI with contrast (see axial and coronal images at end of video) revealed a large left orbital apex meningioma in this patient.

links.lww.com/CONT/A124

© 2014 American Academy of Neurology.

Supplemental Digital Content 8-2

Alternate cover test. This video of the same patient as in **Supplemental Digital Content 8-1** shows an exotropia (reflective of left medial rectus weakness) and a left hypotropia (reflective of left superior rectus and inferior oblique weakness). Notice how the movements of the right eye are greater than the left eye during the test, even though it is not the paretic eye; the left eye is unable to move because of paresis. The deviation of the right eye (there is both an exotropia and hypertropia) is an example of a secondary deviation and results from the Hering law of equal innervation, which states that an equal force is provided to each eye.

links.lww.com/CONT/A125

© 2014 American Academy of Neurology.

Supplemental Digital Content 8-3

Enhanced ptosis (curtaining). When the examiner lifts the right eyelid, the left eyelid falls further, and when the left lid is lifted, the apparently normal right lid begins to droop,

KEY POINT

- Convergence insufficiency in children often responds to office-based vergence/accommodative therapy with home reinforcement, while adult patients with lesions of the convergence centers often require prismatic therapy.

Copyright © American Academy of Neurology. Unauthorized reproduction of this article is prohibited.

revealing an underlying ptosis in the right eye as well. This enhanced ptosis or ''curtaining'' is typical for ocular myasthenia gravis since the disease affects the neuromuscular junction of both eyes. The centrally mediated compensation for the left-sided ptosis was distributed to the milder right eye, initially obscuring its milder ptosis, as would be expected from the Hering law of equal innervation, which states that force applied to one eye is also applied to the other.

links.lww.com/CONT/A128

© 2014 American Academy of Neurology.

Supplemental Digital Content 8-4

Aberrant regeneration of the left oculomotor nerve. In adduction, the lid lifts, reflecting aberrant regeneration of the adduction fibers of the oculomotor nerve to the levator palpebrae muscle fibers. The presence of aberrant regeneration is consistent with chronic oculomotor palsy.

links.lww.com/CONT/A126

© 2014 American Academy of Neurology.

REFERENCES

1. Pierrot-Deseilligny CH, Chain F, Gray F, et al. Parinaud's syndrome: electro-oculographic and anatomical analyses of six vascular cases with deductions about vertical gaze organization in the premotor structures. Brain 1982;105(pt 4):667–696.
2. Bhidayasiri R, Plant GT, Leigh RJ. A hypothetical scheme for the brainstem control of vertical gaze. Neurology 2000;54(10):1985–1993.
3. Coffeen P, Guyton DL. Monocular diplopia accompanying ordinary refractive errors. Am J Ophthalmol 1988;105(5):451–459.
4. Lepore FE, Yarian DL. Monocular diplopia of retinal origin. J Clin Neuroophthalmol 1986;6(3):181–183.
5. Wilker SC, Rucker JC, Newman NJ, et al. Pain in ischaemic ocular motor cranial nerve palsies. Br J Ophthalmol 2009;93(12):1657–1659
6. Brodsky MC, Donahue SP, Vaphiades M, Brandt T. Skew deviation revisited. Surv Ophthalmol 2006;51(2):105–128.
7. Dolman P. The Maddox Rod Screen Test. Trans Am Ophthalmol Soc 1919;17:235–249.
8. Parks MM. Isolated cyclovertical muscle palsy. AMA Arch Ophthalmol 1958;60(6): 1027–1035.
9. Ohtsuki H, Hasebe S, Hanabusa K, et al. Intraoperative adjustable suture surgery for bilateral superior oblique palsy. Ophthalmology 1994;101(1):188–193.
10. Joo KS, Koo H, Moon NJ. Measurement of strabismic angle using the distance Krimsky test. Korean J Ophthalmol 2013;27(4):276–281.
11. Bixenman WW, von Noorden GK. Apparent foveal displacement in normal subjects and in cyclotropia. Ophthalmology 1982;89(1): 58–62.
12. Spierer A. Measurement of cyclotorsion. Am J Ophthalmol 1996;122(6):911–912.
13. Frueh BR, Musch DC, Grill R, et al. Orbital compliance in Graves' eye disease. Ophthalmology 1985;92(5):657–665.
14. Parelhoff ES, Chavis RM, Friendly DS. Wegener's granulomatosis presenting as orbital pseudotumor in children. J Pediatr Ophthalmol Strabismus 1985;22(3): 100–104.
15. Lee AG, Tang RA, Feldon SE, et al. Orbital presentations of giant cell arteritis. Graefes Arch Clin Exp Ophthalmol 2001;239(7): 509–513.
16. Berry-Brincat A, Rose GE. Idiopathic orbital inflammation: a new dimension with the discovery of immunoglobulin G4-related disease. Curr Opin Ophthalmol 2012;23(5): 415–419.
17. Yuen SJ, Rubin PA. Idiopathic orbital inflammation: distribution, clinical features, and treatment outcome. Arch Ophthalmol 2003;121(4):491–499.
18. Wiersinga WM, Bartalena L. Epidemiology and prevention of Graves' ophthalmopathy. Thyroid 2002;12(10):855–860.
19. Gaddipati RV1, Meyer DR. Eyelid retraction, lid lag, lagophthalmos, and von Graefe's sign: quantifying the eyelid features of Graves' ophthalmopathy. Ophthalmology 2008;115(6):1083–1088.
20. Spierer A, Eisenstein Z. The role of increased intraocular pressure on upgaze in the assessment of Graves ophthalmopathy. Ophthalmology 1991;98(10):1491–1494.
21. Kuzma BB, Goodman JM. Slowly progressive bilateral enophthalmos from metastatic breast carcinoma. Surg Neurol 1998;50(6):600–602.
22. Shinder R, Al-Zubidi N, Esmaeli B. Survey of orbital tumors at a comprehensive cancer center in the United States. Head Neck 2010;33(5):610–614.
23. Roshdy N, Shahin M, Kishk H, et al. MRI in diagnosis of orbital masses. Curr Eye Res 2010;35(11):986–991.
24. Saffra N, Rakhamimov A, Saint-Louis LA, Wolintz RJ. Acute diplopia as the presenting sign of silent sinus syndrome. Ophthal Plast Reconstr Surg 2013;29(5):e130–e131.

Copyright © American Academy of Neurology. Unauthorized reproduction of this article is prohibited.

25. Golnik KC, West CE, Kaye E, et al. Incidence of ocular misalignment and diplopia after uneventful cataract surgery. J Cataract Refract Surg 2000;26(8):1205–1209.

26. Nayak H, Kersey JP, Oystreck DT, et al. Diplopia following cataract surgery: a review of 150 patients. Eye 2008;22(8):1057–1064.

27. Spencer RF, Porter JD. Biological organization of the extraocular muscles. Prog Brain Res 2006;151:43–80.

28. Cogan DG. Myasthenia gravis: a review of the disease and a description of lid twitch as a characteristic sign. Arch Ophthalmol 1965;74:217–221.

29. Ragge NK, Hoyt WF. Midbrain myasthenia: fatigable ptosis, 'lid twitch' sign, and ophthalmoparesis from dorsal midbrain glioma. Neurology 1992;42(4):917–919.

30. Moorthy G, Behrens MM, Drachman DB, et al. Ocular pseudomyasthenia or ocular myasthenia 'plus': a warning to clinicians. Neurology 1989;39(9):1150–1154.

31. Van Stavern GP, Bhatt A, Haviland J, Black EH. A prospective study assessing the utility of Cogan's lid twitch sign in patients with isolated unilateral or bilateral ptosis. J Neurol Sci 2007;256(1–2):84–85.

32. Cogan DG, Yee RD, Gittinger J. Rapid eye movements in myasthenia gravis. I. Clinical observations. Arch Ophthalmol 1976;94(7):1083–1085.

33. Serra A, Ruff RL, Leigh RJ. Neuromuscular transmission failure in myasthenia gravis: decrement of safety factor and susceptibility of extraocular muscles. Ann N Y Acad Sci 2012;1275:129–135.

34. Osher RH, Griggs RC. Orbicularis fatigue: the 'peek' sign of myasthenia gravis. Arch Ophthalmol 1979;97(4):677–679.

35. Osserman KE, Kaplan LI. Rapid diagnostic test for myasthenia gravis: increased muscle strength, without fasciculations, after intravenous administration of edrophonium (tensilon) chloride. J Am Med Assoc 1952;150(4):265–268.

36. Odel JG, Winterkorn JM, Behrens MM. The sleep test for myasthenia gravis. A safe alternative to Tensilon. J Clin Neuroophthalmol 1991;11(4):288–292.

37. Sethi KD, Rivner MH, Swift TR. Ice pack test for myasthenia gravis. Neurology 1987;37(8): 1383–1385.

38. Guptill JT, Sanders DB, Evoli A. Anti-MuSK antibody myasthenia gravis: clinical findings and response to treatment in two large cohorts. Muscle Nerve 2011;44(1):36–40.

39. Zouvelou V, Papathanasiou A, Koros C, et al. Pure ocular anti-musk myasthenia under no immunosuppressive treatment. Muscle Nerve 2013;48(3):464.

40. Kupersmith MJ, Moster M, Bhuiyan S, et al. Beneficial effects of corticosteroids on ocular myasthenia gravis. Arch Neurol 1996;53(8):802–804.

41. Monsul NT, Patwa HS, Knorr AM, et al. The effect of prednisone on the progression from ocular to generalized myasthenia gravis. J Neurol Sci 2004;217(2):131–133.

42. Liu Z, Feng H, Yeung S-CJ, et al. Extended transsternal thymectomy for the treatment of ocular myasthenia gravis. Ann Thorac Surg 2011;92(6):1993–1999.

43. Keane JR. Multiple cranial nerve palsies: analysis of 979 cases. Arch Neurol 2005;62(11):1714–1717.

44. Wall MD, Wray SH. The one-and-a-half syndrome—a unilateral disorder of the pontine tegmentum: a study of 20 cases and review of the literature. Neurology 1983;33(8):971–980.

45. Wong AM. Understanding skew deviation and a new clinical test to differentiate it from trochlear nerve palsy. J AAPOS. 2010;14(1):61–67.

46. Convergence Insufficiency Treatment Trial Study Group. Randomized clinical trial of treatments for symptomatic convergence insufficiency in children. Arch Ophthalmol 2008;126(10):1336–1349.

47. Godts D, Mathysen DG. Distance esotropia in the elderly. Br J Ophthalmol 2013;97(11): 1415–1419.

48. Muthusamy B, Irsch K, Peggy Chang HY, Guyton DL. The sensitivity of the Bielschowsky head tilt test in diagnosing acquired bilateral superior oblique paresis. Am J Ophthalmol 2014. [Epub ahead of print].

49. Anagnostou E, Kouzi I, Kararizou E. Painful ophthalmoplegia: the role of imaging and steroid response in the acute and subacute setting. J Neurol Sci 2013;331(1–2):145–149.

Copyright © American Academy of Neurology. Unauthorized reproduction of this article is prohibited.