



# C5 Palsy of Patients with Proximal-Type Cervical Spondylotic Amyotrophy

Yasuaki Imajo, Norihiro Nishida, Masahiro Funaba, Yuji Nagao, Hidenori Suzuki, Takashi Sakai

*Department of Orthopaedic Surgery, Yamaguchi University Graduate School of Medicine, Ube, Japan*

**Study Design:** An observational cohort study design was adopted in this study.

**Purpose:** This study was designed to investigate preoperative factors that predict poor outcomes following surgery in patients with proximal-type cervical spondylotic amyotrophy (PCSA) using radiological findings.

**Overview of Literature:** We evaluated the preoperative factors associated with poor outcomes using electrophysiological and neurological findings. However, the preoperative factors associated with poor outcomes remained unclear.

**Methods:** Sixty patients with PCSA who underwent surgical treatment of the cervical spine were enrolled. The radiological findings on plain radiographs, computed tomography (CT), and magnetic resonance imaging (MRI) were evaluated. The cervical lordotic angles, C2–C7 sagittal vertical axis (SVA), and T1 slope were assessed on a lateral radiograph in the neutral position. CT was used to assess the width of the intervertebral foramen and the anterior protrusion of the superior articular process on the axial view. MRI was used to determine the number of levels of compression (NLC) and the presence of a high-intensity area in the spinal cord in the T2-weighted midsagittal view. The preoperative and postoperative strengths of the most atrophic muscles were evaluated using manual muscle testing. Improvements in strength were classified as excellent (five grades recovered), good (more than one grade recovered), fair (no improvement), or poor (worsened).

**Results:** The prevalence of C5 palsy was 17% (10/60). Patients with poor outcomes had higher NLC and  $\Delta$  C2–C7 SVA than patients with excellent, good, and fair outcomes ( $p=0.015$ ; odds ratio [OR], 5.758; 95% confidence interval [CI], 1.397–23.726 for a change of 10% and  $p=0.048$ ; OR, 1.068; 95% CI, 0.992–1.141 for a change of 10%, respectively).

**Conclusions:**  $\Delta$ C2–C7 SVA and NLC may be used as prognostic factors for achieving a poor outcome following surgery in patients with PCSA. More focus is needed on preventing the increase in  $\Delta$ C2–C7 SVA.

**Keywords:** C5 palsy; Sagittal vertical axis; T1 slope; Cervical spondylotic amyotrophy; Radiological findings

## Introduction

Cervical spondylotic amyotrophy (CSA) was first reported by Sobue et al. [1] in 1975 as a subtype of cervical spondylotic myelopathy (CSM). Crandall et al. [2] have indicated

that approximately  $\leq 7\%$  of patients with CSM present with minimal sensation loss. In a study by Imajo et al. [3], preoperative factors predicting fair outcomes following surgery in 54 patients with proximal-type CSA (PCSA) using electrophysiological examination were reported [3].

Received May 26, 2021; Revised Jul 9, 2021; Accepted Jul 29, 2021

Corresponding author: Yasuaki Imajo

Department of Orthopaedic Surgery, Yamaguchi University Graduate School of Medicine, Minami-kogushi, Ube, Yamaguchi, 755-8505, Japan

Tel: +81-836-22-2268, Fax: +81-836-22-2267, E-mail: [i-yasuak@yamaguchi-u.ac.jp](mailto:i-yasuak@yamaguchi-u.ac.jp)

Eight patients (14.8%) had C5 palsy. Moreover, Iizuka et al. [4] have reported that the prevalence of poor outcomes was 7.7% (1/13). Approximately 70% of patients with C5 palsy recover completely without treatment [5-7]. The mean time to full recovery is 4–5 months [5]. In a study by Imajo et al. [3], 12.5% of patients with C5 palsy could fully recover after 2 years. Postoperative C5 palsy was a significant issue following surgery for patients with PCSA because the prognosis for these patients was not good compared with that for patients with other compressive cervical myelopathies (CCMs) [3]. Therefore, preventing postoperative C5 palsy is important. The mean ratio of the compound muscle action potential (CMAP) amplitudes in the affected side to those in the normal side recorded in the deltoid and biceps brachii muscles could be used as a reliable predictive factor for a fair surgical outcome [3]. However, preoperative factors associated with poor outcomes remained unclear. Patients with poor outcomes should have achieved excellent outcomes as a result of the electrophysiological findings [3]. Ossification of the posterior longitudinal ligament (OPLL), cervical open-door laminoplasty together with posterior instrumented fusion, the width of the intervertebral foramen (WIF), a larger superior articular process (SAP), and a posterior shift of the spinal cord after laminoplasty were significant risk factors for postoperative C5 palsy for patients with other CCMs [6-10]. Factors associated with poor outcomes include long symptom duration, older age, and greater preoperative muscle weakness for patients with CSA [10-12]. This study was designed to investigate the factors associated with poor outcomes using radiological and neurological findings, instead of electrophysiological findings.

## Materials and Methods

In this study, 68 patients with PCSA who underwent surgical treatment of the cervical spine between April 1997 and September 2017 at Yamaguchi University Hospital were enrolled. Four patients underwent cervical surgery and multi-muscle transfers simultaneously, two had severe muscle atrophy bilaterally, and two had coexisting rotator cuff tears. Therefore, we excluded these eight patients. Finally, this retrospective study enrolled 60 patients. We collected data on age, hypertension, diabetes mellitus (DM), dialysis, corticosteroid use, Parkinson's disease, surgical approach, the duration of clinical history (DCH), the duration of postoperative follow-up (DPF), and radiological

findings. The mean age of the patients was  $61.3 \pm 9.8$  years. An anterior approach was the preferred method of treatment for multilevel cervical myelopathies when less than three surgical segments were involved, regardless of the alignment of the cervical spine. A posterior approach was the preferred method of treatment for multilevel cervical myelopathies when three or more surgical segments were involved. When the alignment of the cervical spine was kyphotic (see evaluation of radiological findings:  $\alpha < -5^\circ$ ), since 2014, we performed fixation with instrumentation in addition to laminoplasty. All 60 patients showed severe unilateral atrophy of the shoulder girdle muscles; however, the intrinsic muscles remained intact. When patients had muscle atrophy of the forearm and/or hand, in addition to the shoulder girdle muscles, we suspected amyotrophic lateral sclerosis (ALS) and other motor neuron diseases. To differentiate motor neuron diseases, such as ALS and PCSA, we performed preoperative electromyography on 35 patients. When ALS and other motor neuron diseases were suspected, we consulted neurologists preoperatively. Along with the neurologists, we determined that patients with PCSA did not have these diseases preoperatively.

This study was approved by the Institutional Review Board of Yamaguchi University Hospital (IRB approval no., H30-170). Informed consent was obtained from all individual participants included in the study.

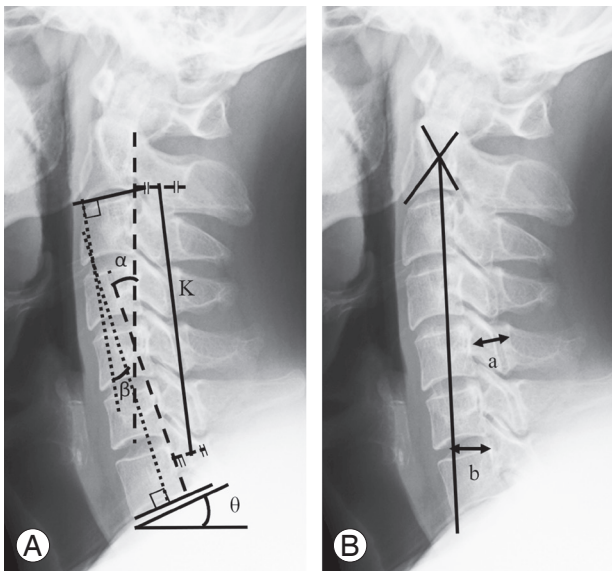
### 1. Evaluation of radiological findings (Table 1)

The radiological findings on plain radiographs, computed tomography (CT), and magnetic resonance imaging (MRI) were evaluated. The cervical lordotic angles (cervical curvature,  $\alpha$ ; Cobb angle,  $\beta$ ), K line, C2–C7 sagittal vertical axis (SVA), T1 slope, and diameter of the canal at the C5 vertebral level (C5 canal) were assessed on a lateral radiograph in the neutral position (Fig. 1A, B), and the intervertebral range at the C4–C5 ( $\gamma$ ) and C5–C6 ( $\delta$ ) intervertebral levels was assessed using lateral radiographs in the flexion and extension positions [13]. The alignment of the cervical spine was classified as lordosis ( $>5^\circ$ ), straight ( $-5^\circ \leq \alpha \leq 5^\circ$ ), sigmoid, or kyphosis ( $\alpha < -5^\circ$ ). CT was used to assess the WIF at the C4–C5 intervertebral levels in the axial view and the anterior protrusion of the C5 SAP at the C5 vertebral level (Fig. 2A, B). MRI was used to assess the number of levels of compression (NLC), the presence of a high-intensity area (HIA) in the spinal cord, and the distance between the posterior edge of the C4–C5 disks

**Table 1.** Measures and definitions on plain radiographs

Variable	Definitions
$\alpha$	The angle between parallel lines to the posterior surface of the C2 and C7 vertebral bodies.
$\beta$	The angle between the C2 and C7 lower endplates.
SVA	The distance between the C2 plumb line and the posterior superior endplate of C7.
T1 slope	The angle between the horizontal plane and the T1 upper endplate.
C5 canal	The diameter of the canal at the C5 vertebral level.
K-line	A straight line that connects the midpoints of the spinal canal at C2 and C7
$\gamma$	The intervertebral range at the C4–C5 intervertebral levels was assessed using lateral radiographs in flexion and extension positions.
$\delta$	The intervertebral range at the and C5–C6 intervertebral levels was assessed using lateral radiographs in flexion and extension positions.

$\alpha$ , cervical curvature;  $\beta$ , Cobb angle; SVA, the C2–C7 sagittal vertical axis.

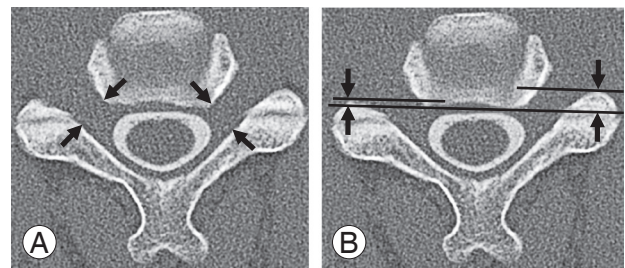


**Fig. 1.** (A, B) Plain radiograph.  $\alpha$ , cervical curvature;  $\beta$ , Cobb angle;  $\theta$ , T1 slope; K, K-line; a, C5 canal; b, C2–C7 sagittal vertical axis.

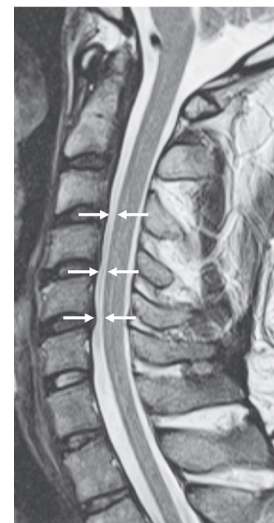
and the anterior aspect of the spinal cord (D) in the T2-weighted midsagittal view (Fig. 3). With D, we evaluated 27 patients who underwent surgery using the posterior approach. The difference between the preoperative and follow-up values for C2–C7 SVA and T1 slope was also investigated, and this result was defined as the  $\Delta$ value for each parameter.

**2. Assessment of muscle strength**

In this study, C5 palsy was defined as a motor decline of the deltoid muscle function by at least one level in a standard manual muscle testing (MMT) within a 6-week postoperative period [8]. Preoperative and postoperative strengths of the most atrophic muscles were evaluated



**Fig. 2.** Computed tomography. (A) The width of the C4–C5 foramen were measured at the narrowest point (arrows). (B) The anterior protrusion of the C5 superior articular process parallel to the posterior line of the vertebral column (arrows).



**Fig. 3.** Magnetic resonance imaging (MRI). Posterior shift of the spinal cord at C4–C5 on the mid-sagittal MRI (arrows).

using MMT. Improvements in strength were classified as excellent (five grades recovered), good (more than one grade recovered), fair (no improvement by MMT), or poor (worsened by MMT), which were assessed using MMT. We

classified surgical outcomes into two groups. Patients with poor outcomes were classified as group 1 and those with excellent, good, and fair outcomes were classified as group 2. Four surgeons who were certified by the Japanese Society for Spine Surgery and Related Research evaluated the MMT results at the first medical examination and the final follow-up. Two of the four surgeons evaluated one patient.

### 3. Evaluation of neurological findings

We examined the strength of the deltoid and biceps brachii muscles, forearm supination, and grip strength on the affected and healthy sides and the presence of sensory disturbance on the radial side in the affected upper extremity.

### 4. Statistical analysis

Statistical analyses were performed using StatFlex ver. 7.0 (Artech Co. Ltd., Osaka, Japan; <http://www.statflex.net/>), a general-purpose statistical software.

Parameters examined as possibly associated with the surgical outcomes, included surgical approaches (anterior approach versus posterior approach), K line, age, DCH, DPF, alignment,  $\alpha$ ,  $\beta$ , preoperative and postoperative C2–C7 SVA,  $\Delta$ C2–C7 SVA, preoperative and postoperative T1 slope,  $\Delta$ T1 slope, range of motion at C4–C5 and C5–C6 intervertebral levels, C5 canal, SAP and WIF at C4–C5 intervertebral levels on the bilateral side on axial CT, HIA, NLC, and D on T2-weighted sagittal MRI. Univariate statistical analyses were performed using the Mann-Whitney *U*-test to compare numerical parameters, and the chi-square test was used to compare categorical parameters. To identify the factors associated with poor and fair/good/excellent outcomes, multivariate logistic regression analysis (MLRA) was performed using a forward stepwise parameter selection procedure by setting  $p < 0.1$  as a criterion for inclusion in the regression model. The probability of patients belonging to group 1 (*p*-value) was computed from the following formula using the partial regression coefficients ( $\beta_0, \beta_1, \beta_2, \dots, \beta_k$ ) for explanatory variables ( $X_1, X_2, \dots, X_k$ ), where  $k$  represents the number of explanatory parameters included in the regression model.

$$p = \frac{1}{1 + e^{\beta_0 + \beta_1 X_1 + \beta_2 X_2 + \dots + \beta_k X_k}}$$

In this study, a dummy variable indicating the occurrence of poor outcomes was set as the objective variable,

and all aforementioned parameters were set as the explanatory variables.

## Results

The prevalence of C5 palsy was 17% (10/60). Postoperative C5 palsy was ipsilateral to the preoperative PCSA symptoms in nine of 10 patients. Paralysis was noted after a mean duration of 5.1 days (range, 0–18 days) postoperatively. Six patients underwent anterior decompression with spinal fusion (C4–C6), and four patients underwent laminoplasty (C3–C7) with foraminotomy (two patients: C5–C6 and two patients: C4–C5 and C5–C6). No patient underwent fixation with instrumentation. One patient had full recovery after 2 years and was categorized into group 2. However, nine patients with C5 palsy did not show adequate improvements even after  $\geq 2$  years postoperatively. These patients were categorized into group 1. The characteristics and neurological findings of the patients in groups 1 and 2 are shown in Table 2. No significant difference in preoperative neurological findings was observed between groups 1 and 2. However, significant differences in MMT of the deltoid and biceps brachii muscles, forearm supination on the affected side, and sensory disturbance in postoperative neurological findings ( $p < 0.05$ ) were noted between groups 1 and 2. No significant difference in grip strength on the healthy and affected sides was observed between groups 1 and 2. Furthermore, 28 patients (47%) presented with at least one comorbidity, the most common being hypertension (10 patients, 17%) and DM (six patients, 10%). In group 1, one patient had hypertension and one patient had DM.

### 1. Association between poor outcome and factors

We used univariate analyses to compare the aforementioned parameters between the two groups. Postoperative C2–C7 SVA,  $\Delta$ C2–C7 SVA, and NLC differed significantly between groups 1 and 2 ( $p < 0.05$ ) (Table 3).  $\Delta$ C2–C7 SVA and NLC differed significantly between groups 1 and 2 in the anterior approach ( $p < 0.05$ ) (Table 3). Ten patients had the K line (–) in this study. Moreover, seven patients had the K line (–) in the anterior approach and three patients in the posterior approach (Tables 3, 4). Only one patient in group 1 who had the K line (–). No significant difference in the K line (–) was observed between groups 1 and 2 (Table 3).

**Table 2.** Comparison of patients population and neurological findings between the two groups

Characteristic	Group 1 (n=9)	Group 2 (n=51)	p-value
Age (yr)	61.8±12.0	61.2±9.6	0.86
Sex			0.58
Male	9	45	
Female	0	6	
Duration of clinical history (mo)	9.0 (5.8–13.3)	8.0 (4.3–14.0)	0.66
Duration of postoperative follow-up (mo)	24.0 (12.0–32.3)	26.0 (12.3–60.0)	0.44
Surgical procedure			1.0
Posterior approach	4	23	
Anterior approach	5	28	
Preoperative neurological findings			
MMT of the deltoid on the affected side	2.2±0.7	2.4±0.7	0.54
MMT of the biceps brachii muscle on the affected side	3.2±0.7	2.8±0.9	0.20
MMT of the forearm supination on the affected side	3.5±0.6	2.7±0.9	0.09
Grip strength on the affected side (kg)	31.6±10.7	26.6±9.8	0.25
Grip strength on the normal side (kg)	41.2±6.9	34.3±9.9	0.11
Sensory disturbance			0.28
Hypesthesia	4	28	
Normal	5	15	
Postoperative neurological findings			
MMT of the deltoid on the affected side	1.8±0.8	3.9±1.5	0.0003
MMT of the biceps brachii muscle on the affected side	2.3±1.1	3.9±1.2	0.001
MMT of the forearm supination on the affected side	0.7±0.6	3.5±1.2	0.001
Grip strength on the affected side (kg)	23.5±10.4	32.3±11.1	0.16
Grip strength on the normal side (kg)	36.4±7.4	37.4±0.7	0.84
Sensory disturbance			0.03
Hypesthesia	8	23	
Normal	1	24	

Values are presented as mean±standard deviation, number, or median (interquartile range).  
MMT, manual muscle testing.

Postoperative C2–C7 SVA and  $\Delta$ C2–C7 SVA significantly differed between groups 1 and 2 in the posterior approach ( $p<0.05$ ) (Table 4). Regarding NLC, one patient had spinal cord compression from C3–C4 to C6–C7 at four levels, four patients from C3–C4 to C5–C6 at three levels, one patient from C3–C4 to C4–C5 at two levels, two patients from C4–C5 to C6–C7 at three levels, and one patient from C4–C5 to C5–C6 at two levels in group 1.

## 2. Factors in group 1

In the MLRA, the dummy variable representing group 1 was set as the objective variable, and all factors were set

as the explanatory variables. Using the forward stepwise method, group 1 had higher NLC and  $\Delta$ C2–C7 SVA than group 2 ( $p=0.015$ ; odds ratio [OR], 5.758; 95% confidence interval [CI], 1.397–23.726 for a change of 10% and  $p=0.048$ ; OR, 1.068; 95% CI, 0.992–1.141 for a change of 10%, respectively) (Table 5).

## Discussion

The prevalence of C5 palsy was 17% (10/60). It was 18% and 15% in the anterior and posterior approaches, respectively. The average reported prevalence of C5 palsy following surgery for CCM for the anterior approach is

**Table 3.** Comparison of radiological findings between the two groups

Variable	Anterior and posterior approach			Anterior approach		
	Group 1 (n=9)	Group 2 (n=51)	p-value	Group 1 (n=5)	Group 2 (n=28)	p-value
Plain radiography						
$\alpha$ (°)	10.3±10.4	10.4±12.7	0.98	6.6±12.1	9.3±12.5	0.66
$\beta$ (°)	12.3±12.2	12.1±14.6	0.97	6.6±11.9	10.9±13.8	0.52
Alignment						0.21
Straight	0 of 9	2 of 50	0.16	0 of 5	1 of 28	
Lordosis	7	29		3	15	
Kyphosis	0	17		0	11	
Sigmoid	2	2		2	1	
K-line (-)	1	9	1.00	1	6	1.00
Pre C2–C7 SVA (mm)	24.1±9.3	21.3±10.6	0.48	19.8±10.2	21.6±11.0	0.72
Post C2–C7 SVA (mm)	37.1±18.4	23.1±13.2	0.01*	31.0±15.1	21.6±11.0	0.10
$\Delta$ C2–C7 SVA (mm)	13.1±16.8	2.2±8.5	0.004*	11.2±18.2	1.0±8.2	0.047*
Pre T1 slope (°)	26.3±4.5	24.3±7.6	0.47	26.3±4.1	24.5±7.5	0.67
Post T1 slope (°)	25.2±6.3	23.6±8.5	0.62	23.3±2.0	23.4±7.5	0.98
$\Delta$ T1 slope (°)	-1.2±5.2	-0.2±6.2	0.66	-2.9±4.8	-0.1±6.9	0.44
Pre T1 slope- $\beta$ (°)	15.7±14.3	11.5±10.1	0.30	14.4±17.8	11.3±11.0	0.61
$\gamma$ (°)	12.2±5.2	9.6±5.0	0.17	12.1±5.7	8.9±4.7	0.20
$\delta$ (°)	8.9±3.7	7.3±4.0	0.28	7.5±3.0	7.4±4.1	0.96
C5 canal (mm)	14.0±1.2	14.4±1.3	0.45	14.2±1.4	14.7±1.2	0.44
Computed tomography						
SAP at C5 level (mm)						
Affected side	6.3±1.6	6.3±2.2	0.99	6.8±1.5	6.6±2.1	0.85
Normal side	6.4±1.6	5.2±2.0	0.08	6.7±1.5	5.2±2.0	0.13
WIF at C4–C5 level (mm)						
Affected side	2.4±1.1	2.3±0.7	0.75	2.6±1.3	2.4±0.7	0.59
Normal side	2.5±1.0	2.8±1.3	0.58	2.7±1.3	2.9±1.3	0.69
Magnetic resonance imaging						
No. of levels of compression	2.9 (2–4)	1.6 (0–3)	0.001*	3.0 (2–4)	1.4 (0–3)	0.002*
The presence of HIA (%)	4 of 9 (44)	20 of 49 (41)	1.0	2 of 5 (40)	10 of 27 (37)	1.0

Values are presented as mean±standard deviation, number, number (range), or number (%), unless otherwise stated.

$\alpha$ , C2–C7 curvature;  $\beta$ , C2–C7 Cobb angle; Pre, preoperative; Post, postoperative; SVA, sagittal vertical axis; ROM, range of motion;  $\gamma$ , ROM at the C4–C5 intervertebral level;  $\delta$ , ROM at the C5–C6 intervertebral level; SAP, superior articular process; WIF, width of the intervertebral foramen; HIA, high-intensity area.

\* $p$ <0.05.

6.7% (range, 1.6%–9.1%) [7]. For the posterior approach, it is 5.8% [14]. Imajo et al. [15] have reported that the prevalence of C5 palsy was 4.6% in 219 patients who underwent anterior decompression with fusion (ADF) for cervical degenerative disease. Kalisvaart et al. [16] have reported that the prevalence of C5 palsy was 2.8%–12.1% in patients with CSM, 2.1%–14% in those with OPLL, and 0%–3% in patients with cervical disk herniation. The

prevalence of C5 palsy in patients with PCSA was higher than that in patients with other diseases. Imajo et al. [15] have reported that the prognosis was good for patients with a CMAP amplitude of the deltoid muscle on the C5 palsy side that exceeded 1.5 mV. Even though patients with PCSA had a CMAP amplitude that exceeded 1.5 mV for the deltoid on the C5 palsy side, their deltoid function had not recovered. However, no difference in postopera-

**Table 4.** Comparison of radiological findings between the two groups in posterior approach

Variable	Group 1 (n=4)	Group 2 (n=23)	p-value
<b>Plain radiography</b>			
$\alpha$ (°)	15.0±6.5	11.9±13.1	0.64
$\beta$ (°)	19.5±9.2	13.7±15.8	0.49
Alignment			0.15
Straight	0 of 4	1 of 20	
Lordosis	4	14	
Kyphosis	0	6	
Sigmoid	0	1	
K-line (-)	0	3	1.00
Pre C2–C7 SVA (mm)	29.4±5.0	21.0±11.3	0.17
Post C2–7 SVA (mm)	44.8±21.6	25.1±15.8	0.04*
$\Delta$ C2–C7 SVA (mm)	15.4±17.4	3.6±8.8	0.04*
Pre T1 slope (°)	26.4±5.5	24.1±7.2	0.56
Post T1 slope (°)	27.0±9.0	23.9±9.8	0.56
$\Delta$ T1 slope (°)	0.6±5.7	-0.2±5.3	0.78
Pre T1 slope- $\beta$ (°)	7.0±4.7	11.3±10.8	0.45
$\gamma$ (°)	12.3±5.3	10.6±5.3	0.56
$\delta$ (°)	10.7±4.1	7.3±3.9	0.13
C5 canal (mm)	13.8±1.1	14.0±1.4	0.81
<b>Computed tomography</b>			
SAP at C5 level (mm)			0.76
Affected side	5.4±1.4	5.8±2.3	
Normal side	6.2±2.1	5.1±1.9	0.39
WIF at C4–C5 level (mm)			0.92
Affected side	2.2±1.1	2.3±0.8	
Normal side	2.4±0.7	2.6±1.2	0.72
<b>Magnetic resonance imaging</b>			
No. of levels of compression	2.8 (2 to 3)	2.0 (0 to 3)	0.13
The presence of HIA (%)	2 of 4 (50)	10 of 22 (45.5)	1.0
Pre D at C4–C5 level (mm)	0.6±0.7	0.8±0.9	0.93
Post D at C4–C5 level (mm)	1.8±1.3	2.3±1.0	0.41

Values are presented as mean±standard deviation, number, number (range), or number (%), unless otherwise stated.

$\alpha$ , C2–C7 curvature;  $\beta$ , C2–C7 cobb angle; Pre, preoperative; Post, postoperative; SVA, sagittal vertical axis; ROM, range of motion;  $\gamma$ , ROM at the C4–C5 intervertebral level;  $\delta$ , ROM at the C5–C6 intervertebral level; SAP, superior articular process; WIF, width of the intervertebral foramen; HIA, high-intensity area; D, distance between posterior edge of C4–C5 disc and anterior aspect of spinal cord.

\* $p$ <0.05.

tive neurological results between patients with PCSA and those with other CCMs [15].

Factors associated with group 1 were  $\Delta$ C2–C7 SVA

and NLC. NLC was a preoperative factor. Thus, avoiding an increase in  $\Delta$ C2–C7 SVA is important for surgeons. Rao et al. [17] have reported that the preoperative T1 slope- $\beta$  had significant correlations with T1 slope,  $\beta$ , and preoperative C2–C7 SVA.  $\Delta$ C2–C7 SVA,  $\Delta\beta$ , and  $\Delta$ T1 slope- $\beta$  were correlated with surgical outcomes [17]. Sakai et al. [18] have reported the following important findings: (1) the postoperative  $\alpha$  and cervical sagittal balance after ADF were maintained; however, those after laminoplasty worsened, especially in patients with a preoperative cervical sagittal imbalance; (2) the postoperative decrease in  $\alpha$  was correlated with the preoperative center of gravity of the head–C7 SVA in laminoplasty, but not in ADF. Postoperative  $\alpha$  was maintained; however, C2–C7 SVA was not maintained in this study (Table 3). Sakaura et al. [19] have reported that an increase in postoperative C1–C7 SVA was associated with older patients with CSM ( $\geq 75$  years old) and operative levels. The patients were divided into two groups according to the most caudal level of laminoplasty (C6 group [C3–C6] and C7 group [C3–C7]). The C6 group had significantly shorter postoperative C1–C7 SVA than the C7 group. In this study, no significant age differences were observed between groups 1 and 2 (Table 4). Recently, various minimally invasive posterior decompression laminoplasty procedures, such as skip laminoplasty and selective laminoplasty, have been reported [20]. Shiraishi et al. [21] have shown a cervical curvature index after skip laminectomy that was superior to that after the conventional procedure. Therefore, we considered that selective laminoplasty was better than laminoplasty of the C6 and C7 groups. Some authors have reported that the surgical outcomes of selective laminoplasty (one above and one below the affected intervertebral level) for patients with CSM were almost the same as those of laminoplasty from C3 to C7 [22,23]. The  $\Delta$ C2–C7 SVA after selective laminoplasty was significantly smaller than that after laminoplasty from C3 to C7 [24]. Selective laminoplasty for patients with PCSA may be important to prevent C5 palsy.

In this study, a larger SAP, WIF narrowing, and a posterior shift of the spinal cord were not associated with C5 palsy (Tables 3, 4). NLC was associated with poor outcomes in this study (Table 5). Hashimoto et al. [7] have reported that preexisting asymptomatic damage of the anterior horn cells at the C3–C4 and C4–C5 levels may contribute to developing motor weakness along with nerve root lesions that occur after ASF. Kaneko et al. [25]

**Table 5.** Factors associated with poor outcomes

Variable	p-value	Odds ratio (95% CI)
No. of levels of compression	0.015	5.758 (1.397–23.726)
$\Delta$ C2–C7 sagittal vertical axis	0.048	1.068 (0.992–1.141)

CI, confidence interval.

have reported the pathology of C5 palsy. The C5 nerve root was innervated predominantly for the deltoid compared with those at other cervical intervertebral lesions, probably due to the segmental gray matter lesions of the C6 spinal cord in patients with cervical myelopathy at the C4–C5 level. The weakness of the deltoid muscle must be clinically obvious if postoperative C5 radiculopathy has occurred in patients whose C5 nerve root predominantly innervates the deltoid muscles [25]. Similar to patients with cervical myelopathy at the C4–C5 level, the weakness of the deltoid muscle must be clinically obvious if postoperative C5 radiculopathy has occurred in patients with cervical myelopathy at the C3–C4 level. We regarded this pathology as a sure indication of PCSA. One patient with spinal cord compression at only the C4–C5 level had complete recovery 2 years postoperatively. All nine patients in group 1 had spinal cord compression from the anterior side at the C4–C5 intervertebral level. Therefore, they had compression of the C6 anterior horn and C5 root. In group 1, eight patients had spinal cord compression at the C5–C6 intervertebral level and six patients had spinal cord compression at the C3–C4 intervertebral level along with spinal cord compression at the C4–C5 intervertebral level. The former had compression of the C6 root, and the latter had compression of the C5 anterior horn in addition to compression of the C6 anterior horn and C5 root. The deltoid and biceps brachii muscles are innervated by the C5 and C6 anterior horns. Patients with lesions in the C5 anterior horn and/or C6 root in addition to compression of the C6 anterior horn and C5 root may have C5 palsy.

This study has few limitations that should be kept in mind when interpreting the results. The sample size was relatively small. The study may have been underpowered to identify any significant difference in surgical outcomes. However, to the best of our knowledge, this is the first study that identified preoperative factors related to poor outcomes using radiological examinations.

## Conclusions

In conclusion,  $\Delta$ C2–C7 SVA and NLC may be used as prognostic factors for achieving poor surgical outcomes following surgical treatment in patients with PCSA. More focus is needed on preventing the increase in  $\Delta$ C2–C7 SVA.

## Conflict of Interest

No potential conflict of interest relevant to this article was reported.

## Acknowledgments

The authors acknowledge Prof. Kiyoshi Ichihara, Department of Clinical Laboratory Sciences, Faculty of Health Sciences, Yamaguchi University Graduate School of Medicine, who performed all of the statistical analysis and supported manuscript preparation.

## Author Contributions

Yasuaki Imajo gathered and analyzed data. Norihiro Nishida, Masahiro Funaba, Yuji Nagao, and Hidenori Suzuki gathered data. Takashi Sakai was an advisor. All authors read and approved the final manuscript.

## References

1. Sobue I, Kato H, Yanagi T. Clinical characteristics and classification of cervical spondylotic myelopathy. *Rinsho Seikei Gaku* 1975;10:999-1006.
2. Crandall PH, Batzdorf U. Cervical spondylotic myelopathy. *J Neurosurg* 1966;25:57-66.
3. Imajo Y, Nishida N, Funaba M, Suzuki H, Sakai T. Preoperative factors that predict fair outcomes following surgery in patients with proximal cervical spondylotic amyotrophy: a retrospective study. *Spinal Cord* 2020;58:348-55.
4. Iizuka Y, Iizuka H, Mieda T, et al. Prognostic factors for cervical spondylotic amyotrophy: are signs of spinal cord involvement associated with the neurological prognosis? *Spinal Cord* 2014;52:364-7.
5. Currier BL. Neurological complications of cervical spine surgery: C5 palsy and intraoperative monitoring. *Spine (Phila Pa 1976)* 2012;37:E328-34.



6. Imagama S, Matsuyama Y, Yukawa Y, et al. C5 palsy after cervical laminoplasty: a multicentre study. *J Bone Joint Surg Br* 2010;92:393-400.
7. Hashimoto M, Mochizuki M, Aiba A, et al. C5 palsy following anterior decompression and spinal fusion for cervical degenerative diseases. *Eur Spine J* 2010;19:1702-10.
8. Bydon M, Macki M, Kaloostian P, et al. Incidence and prognostic factors of c5 palsy: a clinical study of 1001 cases and review of the literature. *Neurosurgery* 2014;74:595-604.
9. Wu FL, Sun Y, Pan SF, Zhang L, Liu ZJ. Risk factors associated with upper extremity palsy after expansive open-door laminoplasty for cervical myelopathy. *Spine J* 2014;14:909-15.
10. Hitchon PW, Moritani T, Woodroffe RW, et al. C5 palsy following posterior decompression and instrumentation in cervical stenosis: single center experience and review. *Clin Neurol Neurosurg* 2018;174:29-35.
11. Tauchi R, Imagama S, Inoh H, et al. Risk factors for a poor outcome following surgical treatment of cervical spondylotic amyotrophy: a multicenter study. *Eur Spine J* 2013;22:156-61.
12. Luo W, Li Y, Xu Q, Gu R, Zhao J. Cervical spondylotic amyotrophy: a systematic review. *Eur Spine J* 2019;28:2293-301.
13. Fujiyoshi T, Yamazaki M, Kawabe J, et al. A new concept for making decisions regarding the surgical approach for cervical ossification of the posterior longitudinal ligament: the K-line. *Spine (Phila Pa 1976)* 2008;33:E990-3.
14. Shou F, Li Z, Wang H, Yan C, Liu Q, Xiao C. Prevalence of C5 nerve root palsy after cervical decompressive surgery: a meta-analysis. *Eur Spine J* 2015;24:2724-34.
15. Imajo Y, Kanchiku T, Suzuki H, Funaba M, Nishida N, Taguchi T. The etiology and prognosis of C5 palsy after anterior decompression with spinal fusion. *J Spine Neurosurg* 2017;6:3.
16. Kalisvaart MM, Nassr A, Eck JC. C5 palsy after cervical decompression procedures. *Neurosurg Q* 2009;19:276-82.
17. Rao H, Huang Y, Lan Z, Xu Z, Li G, Xu W. Does preoperative T1 slope and cervical lordosis mismatching affect surgical outcomes after laminoplasty in patients with cervical spondylotic myelopathy? *World Neurosurg* 2019;130:e687-93.
18. Sakai K, Yoshii T, Hirai T, Arai Y, Shinomiya K, Okawa A. Impact of the surgical treatment for degenerative cervical myelopathy on the preoperative cervical sagittal balance: a review of prospective comparative cohort between anterior decompression with fusion and laminoplasty. *Eur Spine J* 2017;26:104-12.
19. Sakaura H, Ohnishi A, Yamagishi A, Ohwada T. Differences in postoperative changes of cervical sagittal alignment and balance after laminoplasty between cervical spondylotic myelopathy and cervical ossification of the posterior longitudinal ligament. *Global Spine J* 2019;9:266-71.
20. Shiraishi T, Fukuda K, Yato Y, Nakamura M, Ikegami T. Results of skip laminectomy-minimum 2-year follow-up study compared with open-door laminoplasty. *Spine (Phila Pa 1976)* 2003;28:2667-72.
21. Shiraishi T, Kato M, Yato Y, et al. New techniques for exposure of posterior cervical spine through intermuscular planes and their surgical application. *Spine (Phila Pa 1976)* 2012;37:E286-96.
22. Kato Y, Kojima T, Kataoka H, et al. Selective laminoplasty after the preoperative diagnosis of the responsible level using spinal cord evoked potentials in elderly patients with cervical spondylotic myelopathy: a preliminary report. *J Spinal Disord Tech* 2009;22:586-92.
23. Kanchiku T, Imajo Y, Suzuki H, Yoshida Y, Nishida N, Taguchi T. Results of surgical treatment of cervical spondylotic myelopathy in patients aged 75 years or more: a comparative study of operative methods. *Arch Orthop Trauma Surg* 2014;134:1045-50.
24. Kaneoka T, Kanchiku T, Suzuki H, et al. Surgical outcomes of selective laminoplasty for patients with cervical spondylotic myelopathy. *J West Jpn Soc Orthop Surg Traumatol* 2016;65:780-2.
25. Kaneko K, Hashiguchi A, Kato Y, Kojima T, Imajo Y, Taguchi T. Investigation of motor dominant C5 paralysis after laminoplasty from the results of evoked spinal cord responses. *J Spinal Disord Tech* 2006;19:358-61.