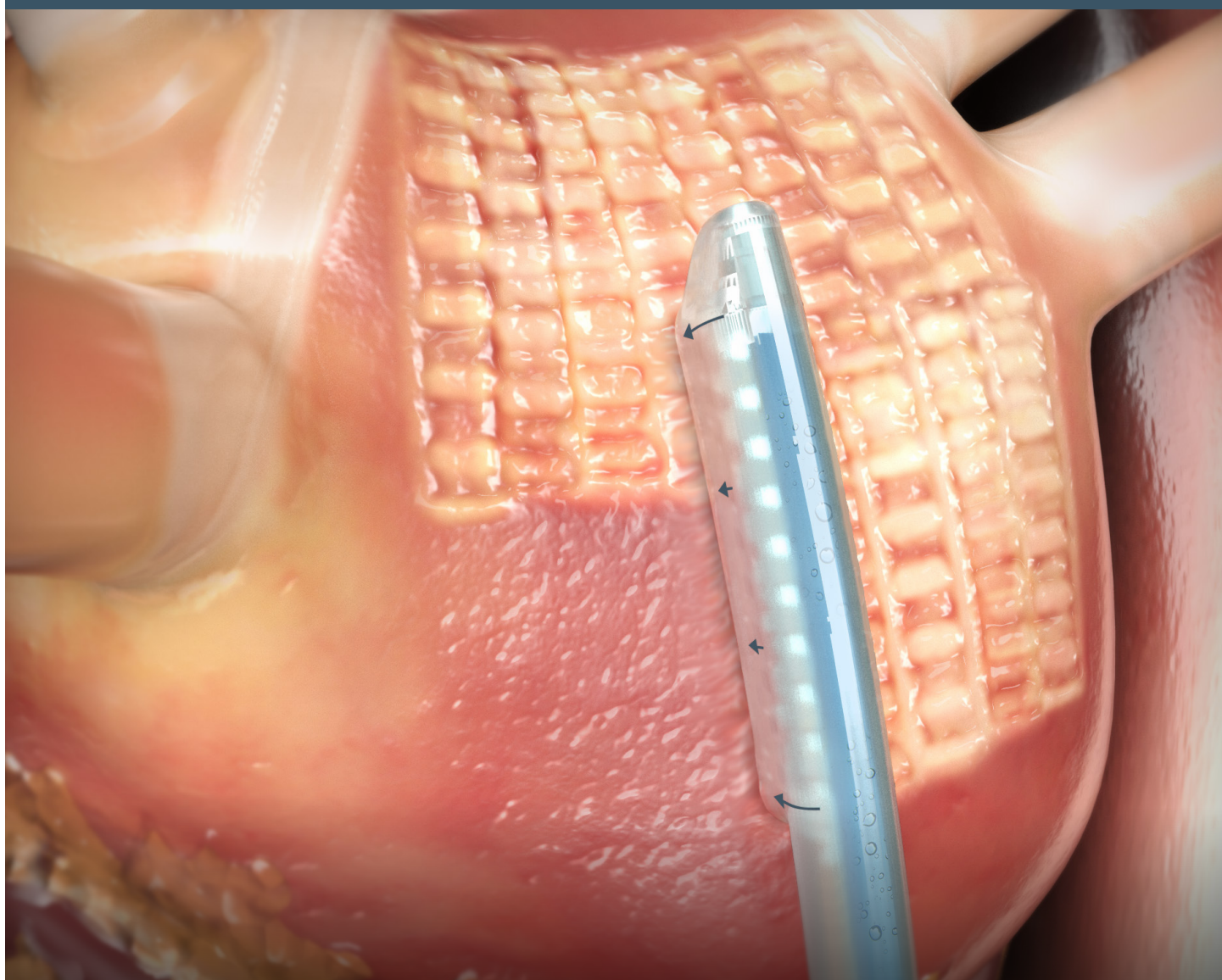


Hybrid AF™ Convergent Therapy Sub-Xiphoid Physician Training Guide

————— for Sub-Xiphoid Access and Lesion Creation —————



This material is intended to provide and reinforce previous training addressing the closed-chest approach options and is intended for educational purposes only. Such information is not intended to be a substitute for professional medical advice, diagnosis or treatment. The material is not intended to direct clinical care in any specific circumstance. The judgment regarding a particular clinical procedure or treatment plan must be made by a qualified physician in light of the clinical data presented by the patient and the diagnostic and treatment options available.

AtriCure

Table of Contents

Overview	1
Equipment Required	1
Product Description	1
Ablation Device	1
Coagulation Device Warnings and Precautions	2
Improper Device Positioning or Movement of Device During Power Application	4
Manipulation of Device with Cannula—Warnings	4
Cannula	4
Cannula Setup and Use	4
Cannula Use Warnings and Precautions	5
Potential Complications During Use of Cannula	5
Incorrect Manipulation of Cannula Guidewire	5
Posterior Wall Access Options	5
Temperature Probe Placement	5
Sub-Xiphoid Access	6
Cannula Placement and Manipulation	6
Endoscopic Visualization	7
Epicardial Lesion Creation	7
Electrogram Utilization with EPI-Sense® Device	8
Posterior Left Atrial Lesions	8
Left Antral Lesions (Optional)	9
Right Antral Lesions (Optional)	10
Closing the Access Site	11
Procedure Tips	11
Sub-Xiphoid Access	11
Endoscopic Visualization	11
Cannula Manipulation	12
Epicardial Lesion Positioning	12
Esophageal Temperature Monitoring	12
Post-Epicardial Ablation—Pericardial Drain	12
Epicardial Lesion Creation	12
Device Attributes	13
In Vitro Lesion Study	13
Effect of Impedance	13
In Vitro Temperature Measure of Coagulation Device	13
In Vitro Effect of Epicardial Fat	14
In Vivo—Lesion on Right Ventricle	14
Rationale for Decision to Re-Ablate a Lesion	14

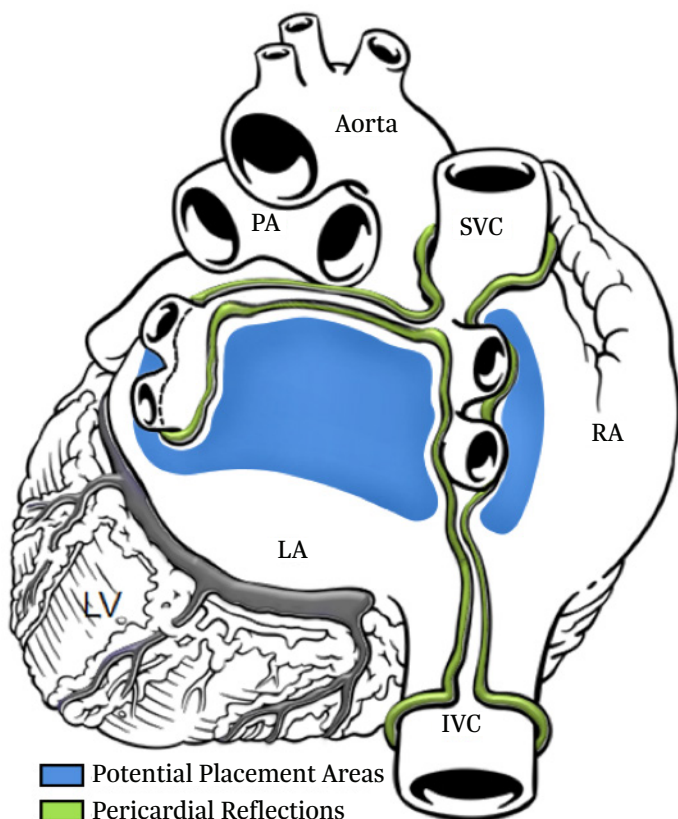
Overview

Closed-chest access using the cannula allows the surgeon to access the atria through a small sub-xiphoid incision. The technology allows for the creation of long linear epicardial lesions that constitute the epicardial component of the Hybrid AF Convergent approach with no chest incisions, ports, lung deflation or heart dissections.

Creating a pericardial window permits access to the posterior surface of the heart for ablating cardiac tissue epicardially. Accessing the heart in this manner allows the Epi-Sense coagulation device to produce epicardial lesions without chest incisions.

A lesion can be created on the atria through the sub-xiphoid access. Figure 1 shows potential locations for the epicardial lesions.

Figure 1. Potential Epicardial Lesion Locations



Equipment Required

As with most endoscopic procedures, general anesthesia and its ancillary equipment are required.

An OR table with reverse Trendelenburg should be utilized.

To create the pericardial window, the following tools and equipment are recommended: video monitor, endoscopic camera, 0-degree 5-mm scope light source.

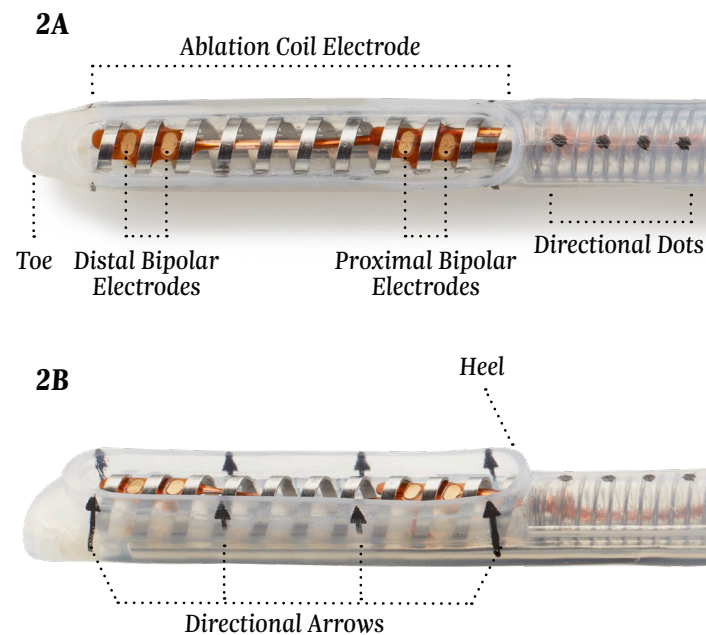
Once through the pericardium, the cannula permits visualization of the pericardial space and the placement of the Epi-Sense ablation device.

Product Description

Ablation Device

Figure 2 shows the bottom (2A) and side (2B) views of the ablation end of the device. As indicated, the **toe** is the distal portion, and the **heel** is the proximal portion of the ablation coil electrode. Eighty percent (80%) of the ablation coil is insulated with silicone, directing the radiofrequency (RF) energy into the targeted tissue. Figure 2A also shows the bipolar electrodes in between the RF coils. Figure 2B shows the arrows on the side of the device, indicating the direction of the exposed area of the ablating coil and RF energy. Figure 4 illustrates the integration of suction and perfusion into the exposed ablation coil region of the ablation device as well as illustrating the insulating silicone.

Figure 2. Bottom and Side View of 3-cm Device

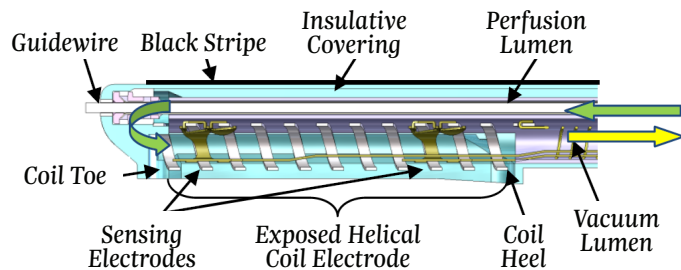


As a comparison, Figure 3 shows the ablation coil of the 3-cm device vs. a 3.5-mm 7Fr ablation catheter. Vacuum, integral to the device, is used to maintain contact between the EPI-Sense ablation coil and the epicardial heart tissue. The amount of power necessary to create a lesion is 30 W (3-cm devices).

Figure 3. Size Comparison 3-cm Device vs. 3.5-mm Catheter

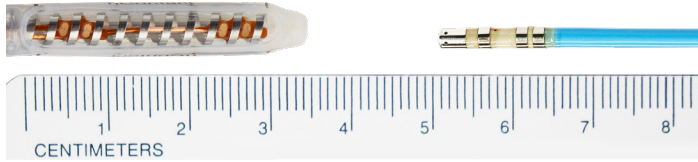

Figure 4. Active Electrode Site on the Device



Coagulation Device Warnings

- Care should be taken to ensure that the device is not in contact with tissue that is not going to be coagulated (e.g., vascular and nerve tissue), in order to avoid inadvertent tissue damage.
- To avoid unintentional coagulation, always ensure that the device or device combined with optional guidewire is oriented toward the desired coagulation location.
- Avoid contact with other surgical instruments, scopes, staples, or other objects while coagulating. Inadvertent contact with objects while coagulating could lead to conduction of RF energy or heat and unintentional coagulation of tissues in contact with those objects.
- The device is provided sterile and is intended for single patient use only. Do not reprocess or reuse. Reuse can cause damage to device, patient injury, and/or the communication of infectious disease(s) from one patient to another.
- Do not scrape or scratch off the gold surface of the sensing electrodes when cleaning the RF coagulation electrode to avoid an adverse patient reaction due to copper exposure.
- To avoid unintentional coagulation, care should be taken to ensure overlapping structures are separated and thermally isolated when anatomy allows.
- Inspect all devices and packaging prior to use. If any breach of the packaging is found the sterility of the product cannot be ensured, which poses a risk of patient injury. Do not use product if breach is found.

- The risk of igniting flammable gases or other materials is inherent in the application of RF energy. Precautions must be taken to restrict flammable materials from the area where tissue coagulation is performed.
- Care should be taken to ensure that device is not moved during RF power delivery. Device movement may cause loss of suction and tissue tear and/or unintentional coagulation.
- Care should be taken to ensure that no vessels (or other structures) are restricted during device manipulation. Vessel restriction could cause hemodynamic instabilities or patient harm.
- Care should be taken to confirm device placement before power application to avoid collateral tissue damage.
- Care should be taken to fill cannula with room temperature saline or sterile water during ablation to avoid collateral tissue damage.
- Care should be taken to ensure that device is perfused during ablation to avoid unintentional tissue damage.
- Physicians should implement a comprehensive anti-coagulation protocol including pre-operative, intra-operative and post-operative anticoagulation management to prevent potential thromboemboli.
- Physicians should use esophageal temperature monitoring as was conducted during the clinical investigation of the device to monitor for potential collateral tissue damage. Throughout the procedure ensure the probe is located directly behind the ablation probe to ensure an accurate reading.
- Physicians should consider post-operative anti-inflammatory medication to decrease the potential for post-operative pericarditis and/or delayed post-procedure inflammatory pericardial effusions.
- Physicians should obtain post-procedural imaging (i.e. 1-3 weeks post-procedure) for detection of post-procedure inflammatory pericardial effusions.

Coagulation Device Precautions

- Precautionary measures should be taken prior to considering treatment of patients:
 - Deemed to be high risk and who may not tolerate a potential delayed post-procedure inflammatory pericardial effusion.
 - Who may not be compliant with needed follow-ups to identify potential safety risks.
- To ensure patients undergoing treatment with the EPI-Sense device are well informed, the benefits, potential risks and procedural outcomes associated with the EPI-Sense Hybrid Convergent procedure should be discussed with the patient. Physicians should document accordingly in the medical record.
- Qualified operators are physicians authorized by their institution to perform surgical sub-xyphoid pericardial access.

- Operators should complete training on the use of EPI-Sense device before performing the procedure.
 - The coils on the distal end of the device must be kept clean of coagulum during surgery to avoid loss of power. Do not clean coagulum off the electrode of the device with an abrasive cleaner or electrosurgical tip cleaner. The electrodes could be damaged, resulting in device failure.
 - Implantable defibrillators can also be adversely affected by RF signals.
 - Interference produced by the operation of high-frequency surgical equipment may adversely affect the operation of other electronic medical equipment such as monitors and imaging systems. This can be minimized or resolved by rearranging monitoring device cables so they do not overlap the Coagulation System cables.
 - The use and proper placement of an Indifferent Electrode (grounding pad) is a key element in the safe and effective use of electrosurgery, particularly in the prevention of patient burns. Ensure that entire area of electrode is reliably attached to the patient's body.
 - While the distal portion of the device is designed to be malleable to conform to the anatomy of the area to be coagulated, excessive manipulation, torquing, rough shaping, or forcing the movement of the device may damage or deform the distal end and cause potential patient harm. This may also cause the sensing electrodes to become detached and or break off the device.
 - Care should be taken when handling the distal end of the device, near the electrode, with surgical instruments—do not squeeze or clamp the electrode. Do not cut or tear the silicone.
 - The coagulation device is only compatible with the nContact generator, cables, and accessories. Use of another manufacturer's accessories may cause damage to the device and/or injury to the patient.
 - Coagulation devices have been tested and have preset power and time settings for optimal coagulation. Changing these settings may cause coagulation dimension to vary from the values given in this document.
 - Care should be taken to ensure that the path to position the device is large enough to advance the device easily—forcing the device may damage the device, cause tissue damage or patient harm.
 - Care should be taken to ensure that device is not twisted or over manipulated during procedure. Twisting/torquing/over manipulating device can cause damage to the device, the lumen to collapse, fracture of electrodes or vacuum lumen spring, separation of electrodes from device, kinking of PEEK guide tube, loss of suction, disconnection of perfusion/IV tubing, kinked perfusion/IV tubing, or patient harm.
 - Connection of multiple devices to one vacuum unit may reduce vacuum functionality.
 - Care should be taken to ensure that the optional guidewire stays on the sterile field during manipulation.
 - Care should be taken to visualize the devices and/or guidewire components when in the body, during introduction and/or removal from the cannula. Always fully retract devices and components prior to insertion and removal in order to avoid inadvertent tissue damage with the devices and or guidewire.
 - Before coagulation of tissue, ensure guidewire and/or scope are not between tissue and coagulation device electrode.
 - If a guidewire is used with guided device, ensure that insulative covering is intact along the exposed guidewire.
 - The coagulation devices should be used by physicians trained in the techniques of minimally invasive endoscopic surgical procedures and in the specific approach to be used, namely the Hybrid AF Convergent Therapy approach used in treating long-standing persistent atrial fibrillation.
 - If using a TEE probe, care should be taken to withdraw the TEE probe prior to ablation to avoid compressing the esophagus against the left atrium during ablation.
 - If the device is used near a pacemaker, a potential hazard exists due to possible interference with the action of the pacemaker and potential damage to the pacemaker. A pacemaker, in a patient undergoing any surgery with RF energy, must be temporarily reprogrammed to an asynchronous mode before application of RF energy.
 - Safety and effectiveness of concomitant left atrial appendage closure was not evaluated in the CONVERGE study.
- Closely monitor device positioning before and after power application to avoid collateral tissue damage.**
- Ensure that the device is NOT in contact with vascular and nerve tissue.
 - Ensure that overlapping structures are separated and thermally isolated when anatomy allows.
 - Ensure that no vessels are restricted during device manipulation to avoid hemodynamic instabilities.
 - Thin target tissue must be thermally isolated before application of power, such as the atrial appendage.
 - The ablation device utilizes preset power and time settings; adjustment of these settings may result in excess or inadequate energy transmission.

Improper Device Positioning or Movement of Device During Power Application Can Result in:

- Power exposure to nontarget tissue; unintentional coagulation
- Inadequate coagulation depth
- Constriction of vessels
- Loss of suction

Manipulation of Device with Cannula—Warnings

- When inserting or retracting cannula from body, ablation device and guidewire should NOT be extended beyond tip of cannula.
- Before advancing device out of the cannula, ensure that the deployment path is large enough to avoid tissue damage.
- Excessive flexing and/or improper manipulation with surgical tools can result in:
 - Damage to device
 - Collapse of lumens
 - Fracture of electrodes or vacuum lumen spring
 - Separation of electrodes from device
 - Kinking of PEEK guide tube (rigid tube inside the guidewire lumen, within the ablation catheter)
 - Disconnection of tubing from handle
 - Breaking bond between PEEK guide tube and the distal end of the device

Cannula

The cannula is the conduit from the sub-xiphoid incision into the pericardial space, through which an endoscope and ablation device are introduced. The endoscope facilitates visualization of anatomy and positioning of the ablation device. Figure 5 indicates the top (5A) and side (5B) views of the distal end of the cannula.

Figure 5 shows the cannula used to facilitate the creation of atrial lesions. The cannula is supplied as either a 30-cm or 40-cm length device. The inner diameter of the cannula is 0.65 in.

Figure 5 also designates specific nomenclature describing the cannula. The cleft is the small opening which faces the atrium and improves working visibility. The tip is the farthest point on the bevel end of the cannula. This should face the pericardium during the procedure.

Figure 5. Top and Side View of the Cannula

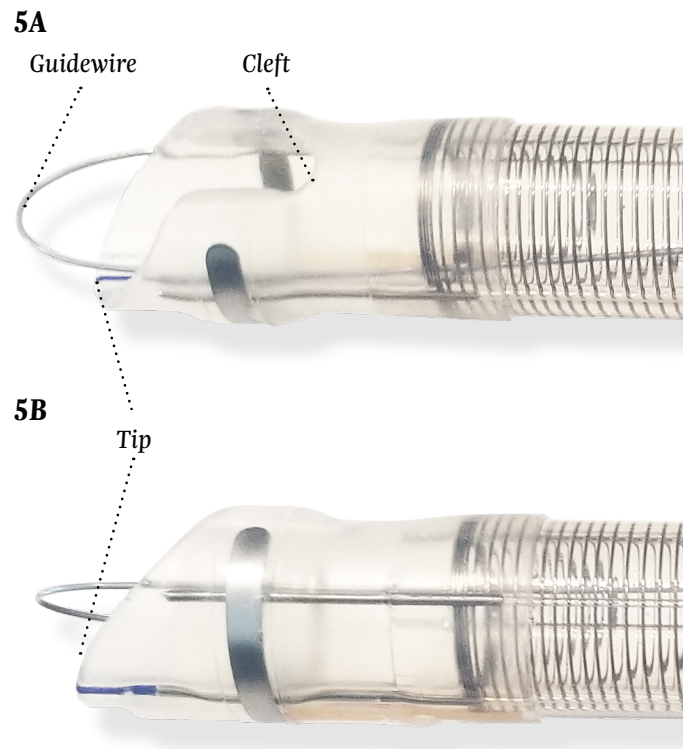
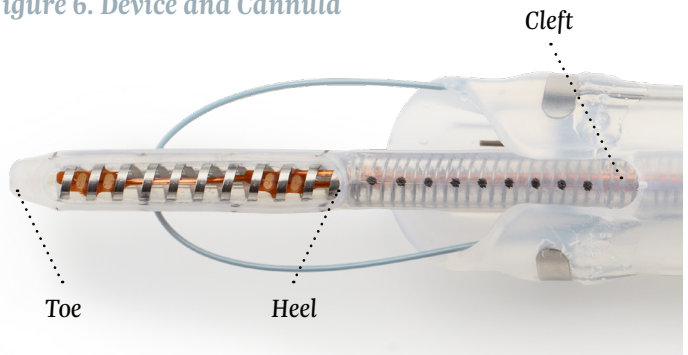


Figure 6 shows the relative position between the device and the cannula.

Figure 6. Device and Cannula



Cannula Setup and Use

- Fully retract guidewire into lumen of cannula before insertion into body.
- If desired, connect vacuum tubing to vacuum port of the cannula and set vacuum pressure to -200 mmHg to remove fluid; do not exceed a vacuum pressure of -550 mmHg.
- Before inserting instruments, lubricate cannula lumen by injecting approximately 20 cc sterile saline through hole in center of cannula.
- Insert scope into cannula as required for visualization.
- Insert cannula into body as desired to create space and visibility.
- Follow device instructions for use (IFU) for setup and manipulation of device.

Cannula Use Warnings

- The cannula is provided sterile and is intended for single use only. Do not reprocess or reuse. Reuse can cause patient injury and/or the communication of infectious disease(s) from one patient to another.
- Inspect the device packaging prior to use. If any breach of the packaging is found, the sterility of the product cannot be assured, and the product should not be used.

Cannula Use Precautions

- Endoscopic procedures should be performed only by physicians with adequate training in endoscopic techniques.
- Inspect the cannula and guidewire prior to use. Ensure that cannula distal end and guidewire are smooth with no sharp edges. Sharp edge can cause potential patient harm. If sharp edge is found, device should not be used.
- Avoid over-rotating the cannula. Over-rotation can cause the vacuum tubing of the cannula to kink, reducing the cannula suction, thus causing reduced visibility.
- Care should be taken when inserting the cannula. Applying excess force could cause potential patient harm. To reduce friction during insertion, lubricate the cannula with sterile saline.
- Care should be taken when manipulating the guidewire. Always ensure no tissue is caught by the guidewire and brought into the cannula lumen.
- Care should be taken when manipulating the guidewire. Excessive force may damage the cannula and/or guidewire.
- Avoid over-inserting the cannula into patient. Over insertion may reduce cannula suction.
- Avoid excessive pulling on the torquer. Excessive pulling on torquer may damage the cannula and/or guidewire.

Potential Complications During Use of Cannula

- Blunt trauma to adjacent organs
- Pericardial effusion
- Vessel injury
- Tissue perforation
- Hemodynamic instabilities
- Arrhythmias
- Thromboembolic complication
- Pneumothorax
- Infection

Incorrect Manipulation of Cannula Guidewire

Applying excessive force while pulling on guidewire could damage distal end of cannula and break guidewire.

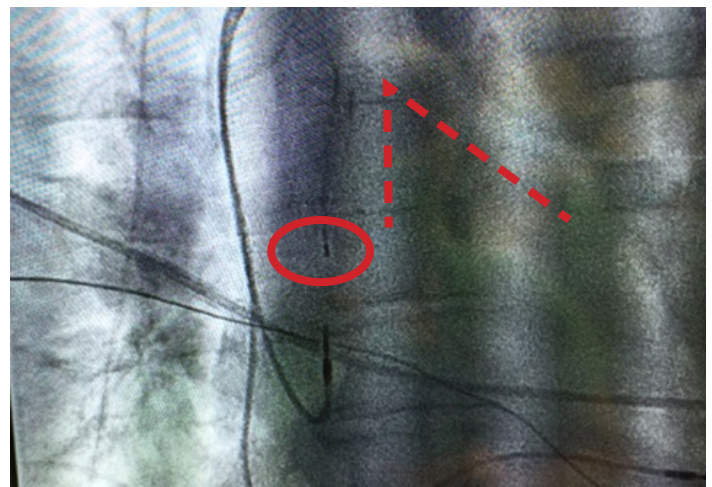
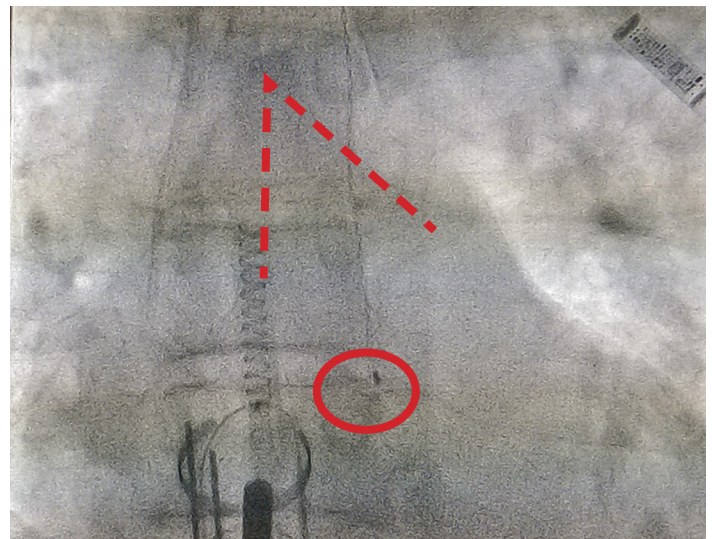
Posterior Wall Access Options

Temperature Probe Placement (Figure 7)

Ablations should be performed with continuous esophageal temperature monitoring. The probe placement may be confirmed in one of the following ways:

- **Probe Placement Option 1:** After the cannula is inserted into the pericardium, fluoroscopy can be obtained prior to ablation. Metallic aspects of the cannula and ablation device clearly delineate the appropriate level.
- **Probe Placement Option 2:** After removing the TEE probe, the temperature probe is placed in the esophagus and placement is confirmed by fluoroscopy prior to patient skin preparation. The probe should be placed approximately 1½ to 2 vertebral bodies caudal to the bronchial carina. This also corresponds with the bulge of the atria of the cardiac silhouette.

Figure 7. Temperature Probe Placement



*Souba, W. W. (©2007). *AcS Surgery: Principles and Practice* (6th ed., p. 1). New York, NY: WebMD Professional Pub.

Sub-Xiphoid Access

A small vertical incision is made from the xiphisternal junction downward to a point slightly below the tip of the xiphoid process (see Figure 8). The upper extent of the linea alba is divided, with care taken not to enter the peritoneum. Peritoneal openings are easily repaired but can make the procedure technically more difficult, in that abdominal contents tend to impede visualization, especially in spontaneously breathing patients. The soft tissue attachments to the xiphoid are divided, the veins running along either side of the xiphoid are controlled, and the xiphoid process may be removed. Coagulation may be used when creating the pericardial window to ensure hemostasis of the microvasculature. Caution must be exercised when using coagulation to ensure that no damage is done to the underlying heart, and no ectopy is induced. The tissue plane behind the lower sternum is developed by means of blunt dissection. This maneuver exposes the retrosternal space to allow visualization of the pericardium. To enhance exposure, the sternum may be retracted upward by an assistant. The anterior pericardial surface is then exposed by sweeping away the remaining mediastinal fat. If necessary, the confluence of the pericardium and the diaphragm may be retracted caudally to improve exposure.

The location of the pericardial incision can be confirmed by palpating cardiac motion through the exposed pericardium. The pericardium is then opened with the energy source of choice; shallow strokes should be employed to reduce the chances of injury to the underlying myocardium that may be adherent to the pericardium. Upon entry into the pericardium, there is an initial outrush of fluid. A sanguineous effusion can be difficult to differentiate from cardiac injury; therefore, the patient's hemodynamics should be carefully monitored during this time. When the pressure placed on the heart by effusion is released, blood pressure will usually rise and heart rate fall. However, if the heart has been accidentally injured, administration of a diuretic (e.g., furosemide) should be considered to reduce the risk of pulmonary edema developing as a result of systemic fluid retention.

Figure 8. Sub-Xiphoid Pericardial Window

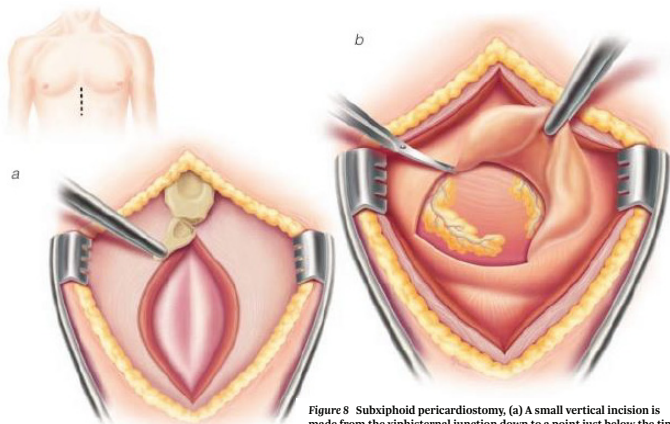
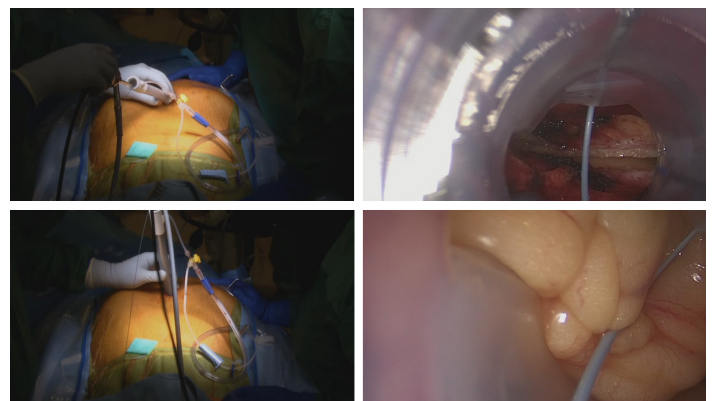


Figure 8 Subxiphoid pericardiostomy, (a) A small vertical incision is made from the xiphisternal junction down to a point just below the tip of the xiphoid, the upper extent of the linea alba is divided, and the xiphoid is removed. (b) The pericardium is opened, and the edge of the opening is grasped and elevated. A pericardial specimen several square centimeters in size is then resected to create the pericardial window.

The opening in the pericardium is enlarged by finger dissection until it is approximately 7 cm in width, large enough to allow passage of the cannula. The cannula is inserted with the endoscope inside the cannula providing visualization. The incision in the pericardium should be visualized through the cannula as seen in Figure 9; the cannula should then be positioned to nearly vertical (see Figure 9) and inserted into the pericardial space. Ensure appropriate visualization of the diaphragmatic aspect of the pericardium. Position the cannula so the tip of the cannula is against the pericardium and away from the IVC. Insert the cannula, following the pericardium around the RV to the posterior of the heart and the posterior left atrium. In this location the cannula angle will be closer to 45 degrees and there might be pressure on the ventricle.

Figure 9. Sub-Xiphoid Cannula Insertion



Arterial blood pressure should be monitored throughout the procedure. Volume administration to increase blood pressure should be monitored to limit the potential for dilatation of the right atrium.

Cannula Placement and Manipulation

The cannula should be positioned through the incision and into the pericardial space. Positioning the tip of the cannula at approximately 12 o'clock, cleft at 6 o'clock, rotate the cannula clockwise 180 degrees (Figure 10) to separate the heart from the pericardium and provide space through which the cannula can be inserted (Figure 11). As the cannula is advanced into the pericardial space, it should be directed towards the left of the patient, away from the IVC.

Do not connect the cannula vacuum port to suction until after placing the cannula through the pericardial window, otherwise tissue inside the pericardium will be pulled into the distal vacuum holes and clog the vacuum lumen.

Figure 10. Cannula Tip at Pericardial Window

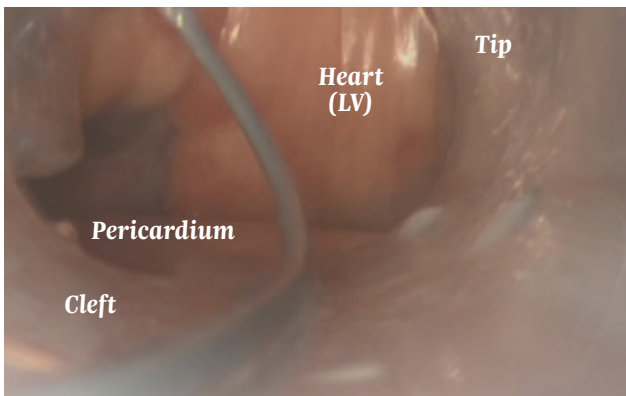
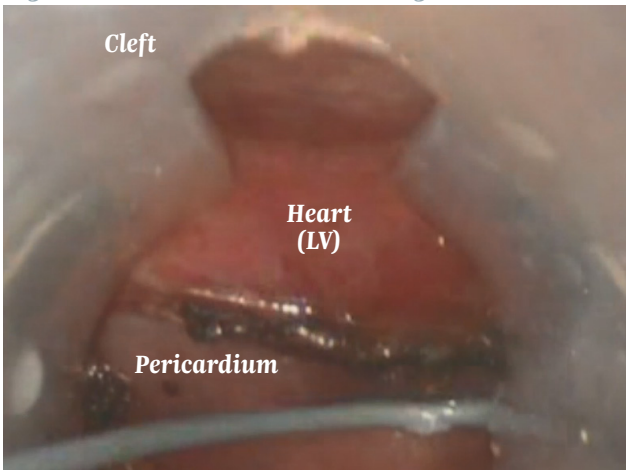


Figure 11. Cannula Rotated Through Incision



Endoscopic Visualization

Use the cannula to create space so that an endoscope can provide direct visualization of the posterior left atria. When the pericardium is intact and free of adhesions, the cannula will gently separate the heart from the pericardium and create a cavity into which the device may be advanced under endoscopic visualization.

The cannula may be manipulated along the posterior heart surface to visualize the left pulmonary veins (LPV) (Figure 12A), the right pulmonary veins (RPV) (Figure 12B), the inferior vena cava (IVC), the coronary sinus (CS), and the posterior left ventricle (LV). To manipulate the cannula, use the bevel end to lift the heart. Rotate the cannula during manipulations to separate the heart from the pericardium and facilitate delineation of anatomic structures. Use the cleft to visualize tissue structures and assist in creating space. It is best to have the tip of the cannula against the pericardium as opposed to the heart surface.

Figure 12A. Posterior View of Inferior Near LPV

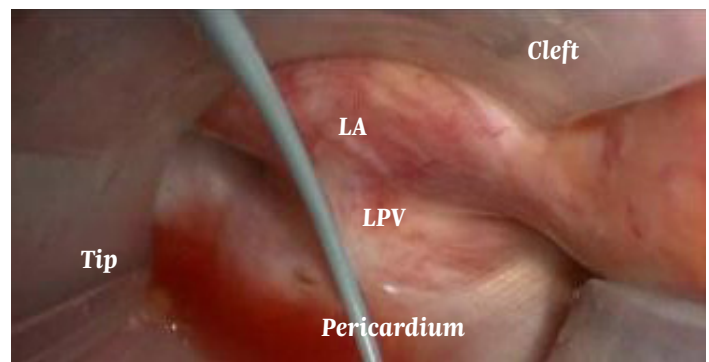
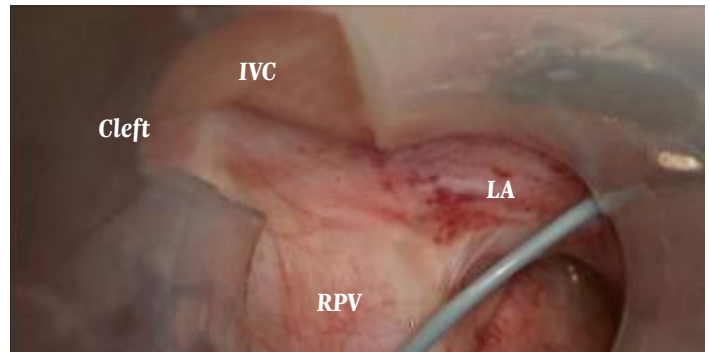


Figure 12B. Posterior View of Inferior Near RPV



Epicardial Lesion Creation

Prior to creating any lesions, be sure to remove the TEE probe and the NG/OG tube (if used), or at the very least pull far back relative to the esophagus, so that the probe is nowhere near the atrium.

The upper alarm limit of the temperature probe should be set to 38.0°C. The preset power and time settings for ablation with the coagulation device are based on extensive testing; changing the settings may cause excessive heating and tissue damage. Prior to ablation, connect a stopcock in-line between the vacuum port and the tapered adaptor to control vacuum through the cannula. During ablation, room temperature saline should be administered through the cannula to cool and hydrate the pericardium and underlying anatomy. Before injecting the saline, turn the cannula vacuum off by closing the in-line stopcock.

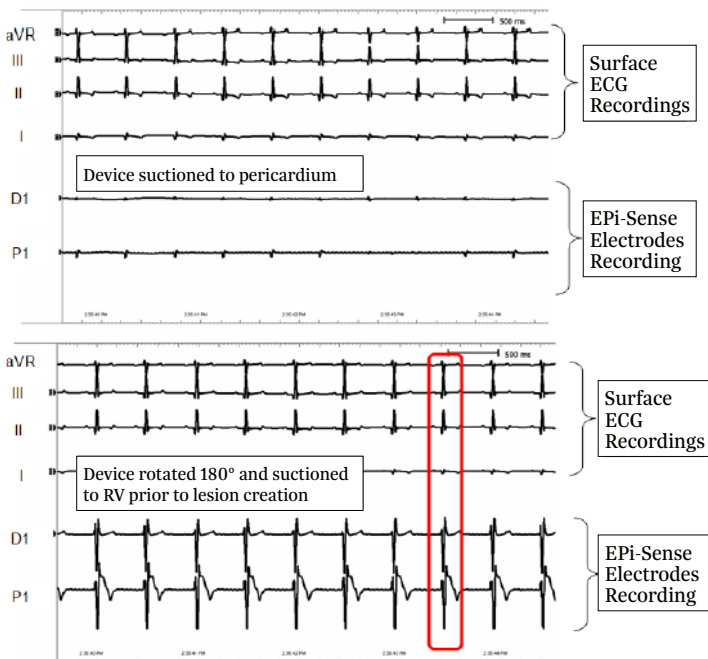
If the esophageal temperature increases to either >38.0°C, or 0.5°C over baseline,* RF energy delivery should be stopped until the temperature returns to <37°C or to baseline.

**Note: Baseline temperature should be taken prior to any lesion creation.*

Electrogram Utilization with Epi-Sense Device

The two bipolar sensing electrodes embedded in the Epi-Sense device may be connected to an electrophysiology (EP) workstation or ECG recorder to visualize the electrical signals of the tissue to which the device is suctioned. Figure 13 illustrates the ECG signals as measured with an Epi-Sense device. In this figure the amplitude of the electrical signal can be seen to demonstrate the difference between having the device suctioned to pericardium versus epicardium. Positioning of the Epi-Sense device should be determined based on direct visualization through the endoscope; the ECG signals from the Epi-Sense device should be used to confirm direct visibility. The device should be fully suctioned to the desired tissue prior to reviewing the ECG signals.

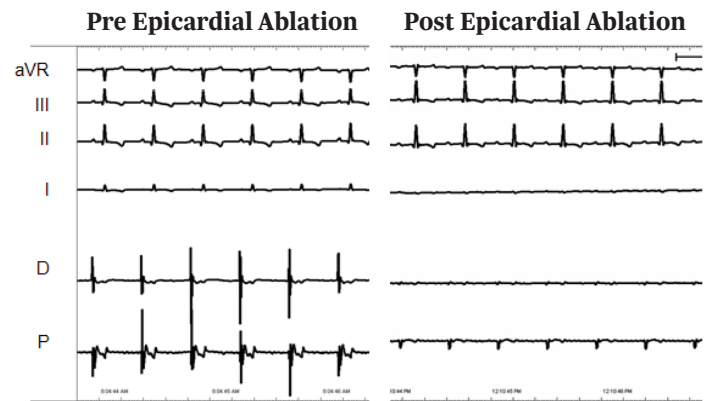
Figure 13. Electrogram Recording: Pericardium vs. Epicardium



The ECG signals may also be utilized to verify the coagulation of the tissue during lesion creation. As the tissue is coagulated during the lesion creation process the ECG amplitude will decrease.

Electrophysiologists follow this process of observing ECG amplitude decrement to determine lesion completeness, typically relying on a 90% decrement to correspond to a complete lesion. Figure 14 illustrates the decrement of amplitude as measured by an Epi-Sense device before and after the creation of an atrial lesion.

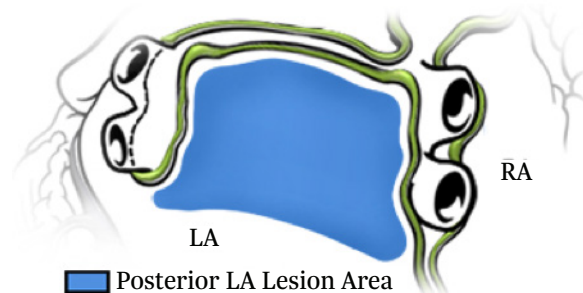
Figure 14. Electrogram Recording: Pre- and Post-Ablation



Posterior Left Atrial Lesions

To achieve more desired lesion locations, the physician will determine the best device deployment method. This training guide gives examples of different approaches to deploy the device (Figure 15).

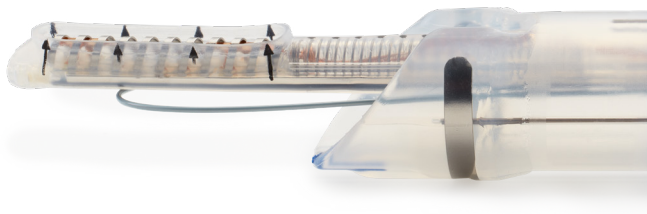
Figure 15. Posterior Left Atrial Lesions



To create lesions along the posterior left atrium, parallel to the RPVs or the LPVs, position the cannula under the left atrium. Once in the proper location, use the cannula to separate the pericardium to create space and allow visualization of the posterior anatomy. This is achieved with the tip of the cannula facing the pericardium (cleft facing the heart). This maneuver will create a space for the device (Figure 16). Once the cannula is at the desired location, advance the device such that the ablating coil is in the appropriate location, with coils facing the heart (Figure 17A).

Retract the cannula while maintaining the device placement. This will allow the heart to better sit against the device. Always ensure proper orientation of the exposed ablation coil electrode under endoscopic visualization, utilizing the directional arrows and black stripe on the back of the device to confirm contact with atrial tissue only (Figure 17B).

Figure 16. Lateral View of Device



Ablation Device—RF Coil Facing Left Atrium (Arrow Direction)

Figure 17A. Positioning the Device and Cannula in the Desired Location

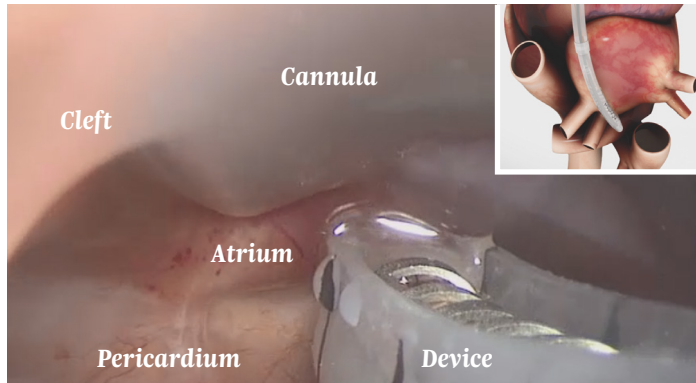
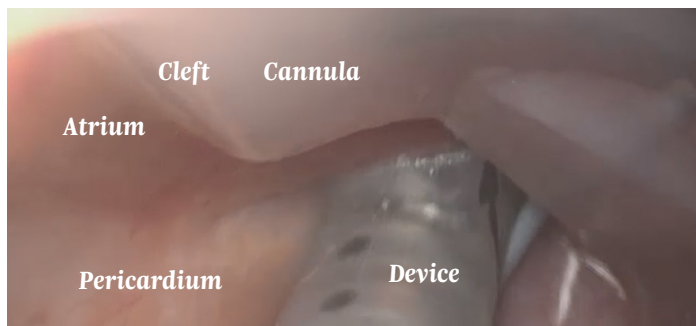


Figure 17B. Retracting the Cannula While Maintaining the Device Position



Continue to manipulate the cannula and device such that lesions on the posterior LA are adjacent to one another. Repeat lesions until ablation of posterior LA is complete.

To avoid deformation of the pericardial reflections or the ablation device and the misdirection of RF energy delivery, do not use excessive force when advancing the device against the reflections, and slightly pull back on the cannula to retract the deployed device from the reflections.

Multiple applications of RF energy may be required to create the desired posterior left atrial lesion, with the 3-cm device. Always confirm that the ablation coil arrows are directed toward the heart, away from the pericardium.

Epical lesions are visible and connection of discrete lesions provides confirmation of lesion continuity. Use the endoscope to facilitate manipulation of the cannula when confirming that the lesions intersect.

Left Antral Lesions (Optional)

To position the device along the anterior LPV (Figure 18), orient the cannula around the inferior LPV such that direct access to the anterior surface is obtained. To locate this area, position the cannula around the LPVs, locate the inferior LPV with the cannula, rotate the tip to 2 o'clock, and use the endoscope to assist the cannula around the LPVs. Once in position, gently rotate the cannula clockwise to create space between the left atrium and the pericardium.

When the desired cannula location is obtained, advance the device such that it passes anterior to the superior LPV and the exposed side of the RF coil (arrows pointing towards the left atrium) faces the left atrium. Remember that in most cases, the superior LPV is anterior to the inferior LPV. Use caution when advancing the device, do not exert excessive force. Engage the vacuum and retract the cannula (Figure 19).

Figure 18. Left Antral Lesions

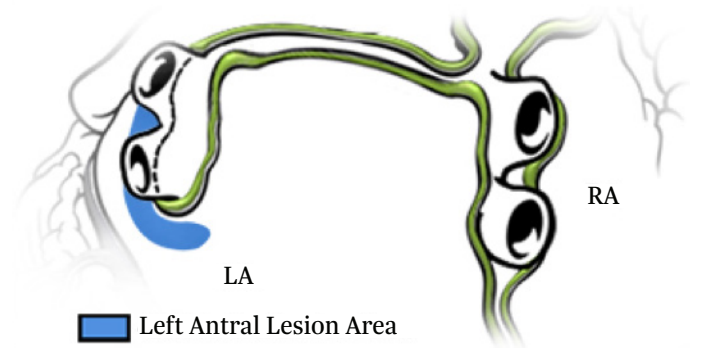
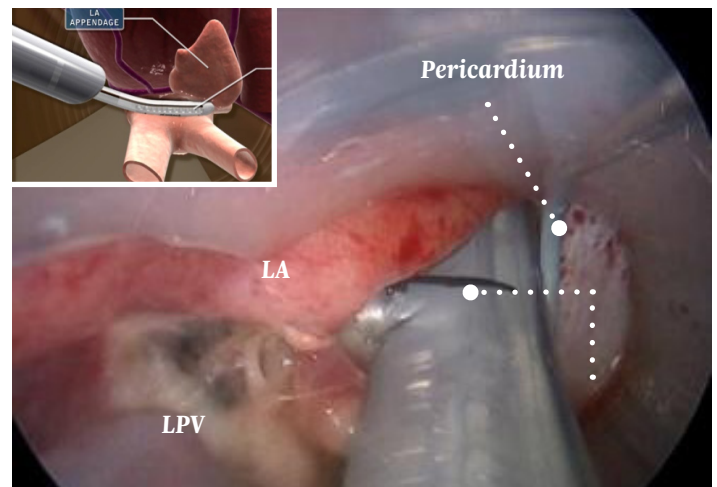
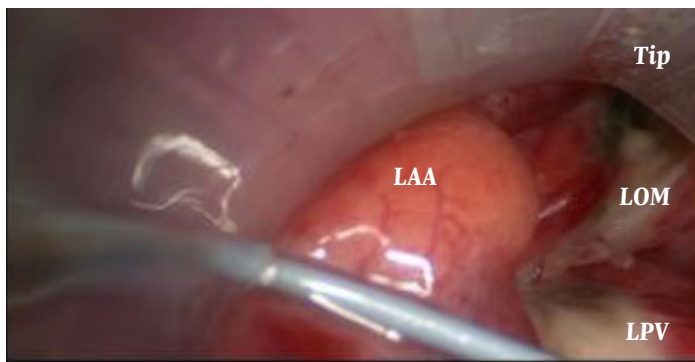


Figure 19. Left Antral Device Placement



This region may provide access to the ligament of Marshall (LOM), the left atrial appendage (LAA), the transverse sinus and the anterior portion of the LPV (Figure 20).

Figure 20. Ligament of Marshall Lesion

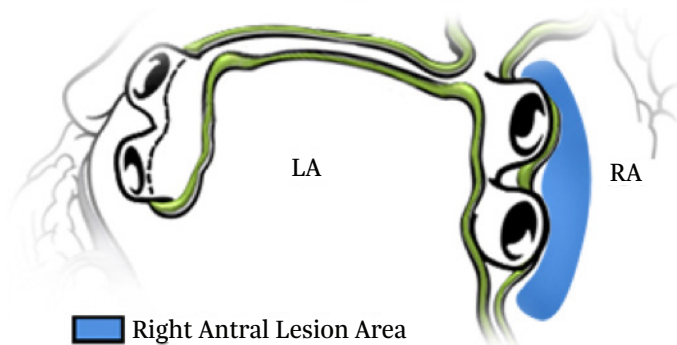


Right Antral Lesions (Optional)

The anterior right atrium (Figure 21) can be accessed by rotating the cannula over the IVC. To position the cannula over the IVC, place it adjacent to the IVC from the posterior left atrium (cleft directed towards 10 o'clock) to visualize the IVC. Retract the cannula to identify the opening around the IVC, with visible confirmation of the IVC, right atrium, and pericardium. As the tip of the cannula (which extends beyond the cleft) is retracted past the IVC, it may be rotated counterclockwise, orienting the tip to 9 o'clock, and positioned between the right atrium and the pericardium. The cannula may be used to create space to assist in identifying the anterior RPVs.

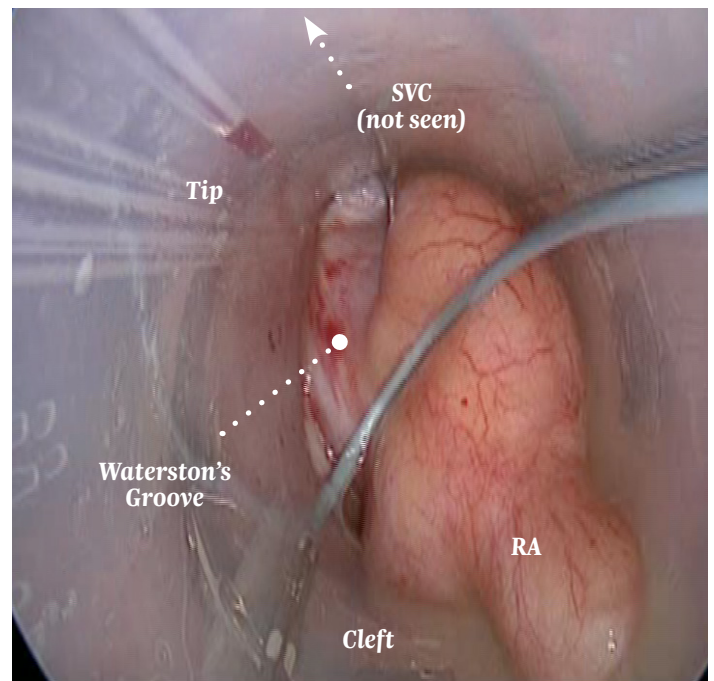
With the cannula positioned over the IVC, the ablation device may be advanced such that the coagulation electrode is located along the anterior orifice, between the RPV antrum and the right atrium. The cannula may be used to create space between the pericardium and the atria, allowing the coagulation electrode to sit against tissue. The cannula also helps separate the pericardium (and phrenic nerve) from the atrium, permitting the ablation device to be positioned along the Waterston's groove region that defines the interatrial junction. A lesion may be created at the left orifice to the RPV antrum.

Figure 21. Right Antral Lesions



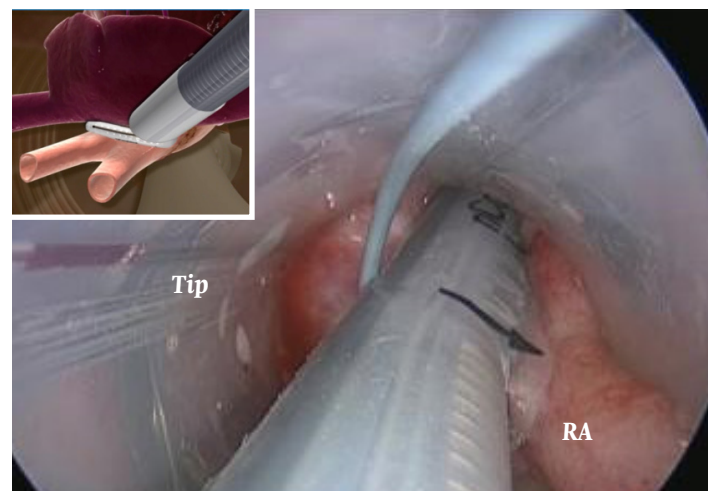
Before creating lesions along the anterior RPV antrum, identify landmarks such as the SVC and the superior and inferior branches of the RPV (Figure 22). Some atria incorporate a long common antrum with the inferior and superior branches bifurcating at the level of or after the pericardium.

Figure 22. Visualizing Waterston's Groove



When positioning the ablation device along the RPV antrum 'off the cannula guidewire,' identify the RPVs and SVC, and position the device with the arrows directed towards 4 o'clock. The exposed electrode should be oriented parallel to the interatrial groove with the toe of the device along the RPV antrum, under the SVC, and adjacent the superior RPV branch (Figure 23). Ensure the heel lip contacts atrial tissue at the level of the orifice, between the RPV antrum and the left atrium.

Figure 23. Right Antral Placement



When positioning the ablation device—especially when targeting the inferior RPV region—orient the cannula with the tip against the pericardium and the cleft facing the left atrium. Identify the RPVs and advance the ablation device such that the exposed side of the RF coil (direction of arrows) faces the left atrium. The RF coil should run parallel to the RPV orifice. Avoid applying excess force against the pericardium or over advancing the cannula or ablation device.

Closing the Access Site

After the creation of all desired epicardial lesions, insert a pericardial drain (19 to 24 Fr Blakemore or JP Drain) through the cannula and position it through the pericardial window and under the posterior surface of the heart (Figure 24). The fluted end of the drain may be cut to ensure that the drainage portion is in the pericardium, not in the epicardial space.

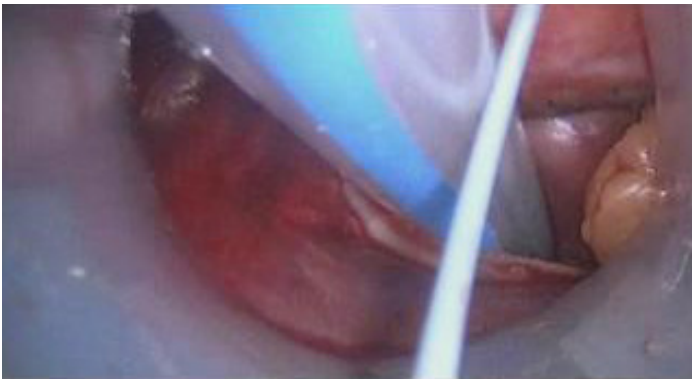
Figure 24. Place Pericardial Drain Under Heart



Once the drain is inserted into the pericardial space and positioned under the left atrium, the cannula may be slowly retracted under endoscopic visualization.

Properly positioned, the vacuum ports of the pericardial drain should reside within the pericardium (Figure 25). This should be confirmed prior to retracting the cannula from the abdomen.

Figure 25. Ensure Drain Is in the Pericardial Space



The free end of the drain should be fully advanced through the cannula, as the cannula is completely retracted from the incision. The free end of the drain may then be pulled through a peripheral drain-outlet incision with the help of a chest tube clamp or another surgical grasper.

Procedure Tips

Sub-Xiphoid Access

- Initial incision should be longitudinal (approximately 3 cm in length) directly over the xiphoid process.
- Divide the linea alba with electrocautery.
- Surgeon may elect to remove some—or all—of the xiphoid process to aid in visualization and cannula access.
- Using a combination of sharp and blunt dissection, expose the pericardium.
- Make a transverse pericardiotomy just over the diaphragm approximately 7 cm in length.
- One may extend the pericardiotomy vertically in the midline approximately 1.5 cm if desired.
- With tip rotated to 12 o'clock, introduce cannula into the incision and gently advance towards the pericardiotomy. Do not connect suction to cannula until the cannula is determined to be in the oblique sinus.
- Once the tip of the cannula is inside the pericardium, and trending behind the heart, introduce the scope into the cannula.
- Gradually rotate the cannula clockwise 180 degrees while slowly—and gently—advancing the cannula behind the left atrium.
- The cannula tip should now be at 6 o'clock pointing towards the pericardium (and away from the heart).
- While advancing the cannula, bias slightly towards patient's left (to avoid contact with the inferior vena cava).

Endoscopic Visualization

- When visualizing the posterior heart surface, standard landmarks must be identified. The right and left pulmonary veins, the inferior vena cava, and the coronary sinus define the working region along the posterior atria where devices are positioned, and lesions may be created.
- Right is left and left is right. When moving the view to the posterior heart surface, images from the endoscope are reversed. The right pulmonary vein and inferior vena cava are located on the left side of the viewing screen and the left pulmonary vein is located on the right side of the screen.
- Use the suction feature of the cannula to keep the field dry. Any fluid contacting the scope will cloud the field of view and require removing the scope for cleaning.

Cannula Manipulation

- Rotating the cannula facilitates gross and fine movements between the heart and the pericardium. All cannula movements should be accompanied by rotation.
- Use the bevel tip and cleft of the cannula when advancing and rotating the cannula, to facilitate separation of the heart from the pericardium and to create a cavity to visualize the posterior heart.
- A 5-mm scope is used inside the cannula to initially position the cannula at the desired location within the pericardium. The stiffness of the scope facilitates the movement of the cannula along the posterior or lateral heart.
- Ensure the cannula tip does not push into anatomic structures. The tip extends beyond the cleft of the cannula and care should be taken to recognize the location of the tip while manipulating the cannula.

Epicardial Lesion Positioning

- When manipulating the ablation device through the cannula, use a 5-mm scope to provide enough room for both the scope and the guided device.
- Before advancing the ablation device into contact with the heart, ensure that the arrows indicating the direction of the RF coil are oriented such that the device electrode contacts epicardial tissue, not the pericardium.
- If necessary, to improve the vacuum seal of the device to the atrium, slightly retract the cannula so the atrium sits onto the coagulation electrode.
- With the cleft of the cannula facing up, the guided device sits with the toe towards to the right side of the cannula, where the guidewire is affixed. To reverse the orientation so the toe is facing left, rotate the cannula 180 degrees. The tip will now be at 12 o'clock and the cleft at 6 o'clock. To confirm proper orientation, observe the printed arrows on the side of the device are pointing towards the epicardium.

Esophageal Temperature Monitoring

- **Temperature in the esophagus should be measured throughout the ablation procedure.**
- **Fluoroscopy should be used to position the esophageal temperature probe behind the heart and adjacent to the left atrium.**
- **If esophageal temperature exceeds 38°C, or more than 0.5°C from the baseline temperature, RF energy delivery should be discontinued until the esophageal temperature returns to baseline.**
- **Saline may be injected through the cannula to reduce temperature in the pericardial space prophylactically or upon observation of esophageal temperature rise.**

Post-Epicardial Ablation—Pericardial Drain

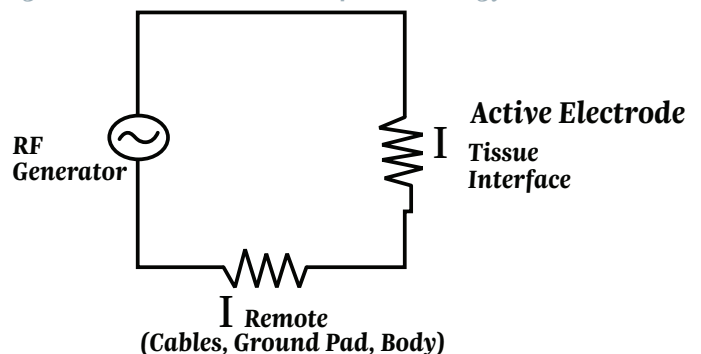
- A drain should be placed through the pericardial window to remove excess fluid during the immediate post-operative period.
- A 19 to 24 Fr Blakemore or JP Drain may be used. Hydroglide drains are also effective and easy to place.
- Saline may be injected through the pericardial drain to cool the pericardial space.

Epicardial Lesion Creation

Creating an RF ablation lesion requires a complete electrical circuit. The coagulation system requires the following elements to complete the circuit (Figure 26):

1. An RF generator to produce the electrosurgical current
2. Cables (insulated) to connect active electrodes to generator
3. Electrode to deliver RF current to coagulate target tissue
4. A patient to receive the energy
5. A grounding pad with cord to complete the circuit and return energy back to generator safely

Figure 26. Electrical Circuit for RF Energy



The body will act as a conductor of RF energy. The tissue under the grounding pad will have minimal heating due to the difference in surface area between the active electrode (1.048 cm²) and the grounding pad (137 cm²).

The lesion is created by using alternating current (about 480 kHz) which passes from the RF electrode to the tissue. The alternating current causes ionic vibration as ions attempt to follow the change in direction of the alternating current. The heat is created by the friction of the vibrating ions, not the electrode probe. With a higher current, the more vigorously the ions move, and thus the higher the temperature. The goal of RF ablations is to achieve local temperatures such that tissue coagulation occurs, not vaporization.

Reversible thermal injury to cells begins as 42°C. Immediate tissue coagulation will occur as the temperature moves above 60°C. The “sweet spot” for RF ablation is 50° to 90°C. This will induce irreversible block and reduction of microvasculature perfusion without overheating tissue.

Device Attributes

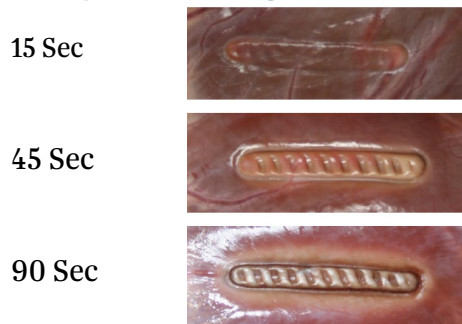
The suction capabilities of the Epi-Sense allow consistent tissue contact with the RF coils. This creates consistent energy transmission and complete transmural lesions without gaps.

The posterior of the coagulation device (opposite the RF coil) is cooled via saline solution. This solution constantly circulates through the device as suction is applied. This cooling perfusion prevents thermal spread and keeps the posterior of the device cool.

In Vitro Lesion Study

Observe lesions created on porcine left ventricle model. A 3-cm coagulation device set at 30 W for 90 seconds was used. The device was perfused with 0.9% NS solution. The photos show epicardial views after the device was removed (Figure 27).

Figure 27. Surface Lesion Progression



Effect of Impedance

As lesions were created with porcine left ventricle model, impedance was controlled by addition of salt to interface between heart tissue and return electrode. A 5-cm coagulation device set at 50 W for 60 seconds was used. The coagulation device was perfused with 0.9% NS.

The goal of this study was to determine the effect of low impedance on lesion creation. The results demonstrate that low impedance lesions may not penetrate the tissue as deeply as lesions within a higher impedance range (Figures 28 and 29).

Figure 28. Low Impedance Lesion (Avg Imp 34)

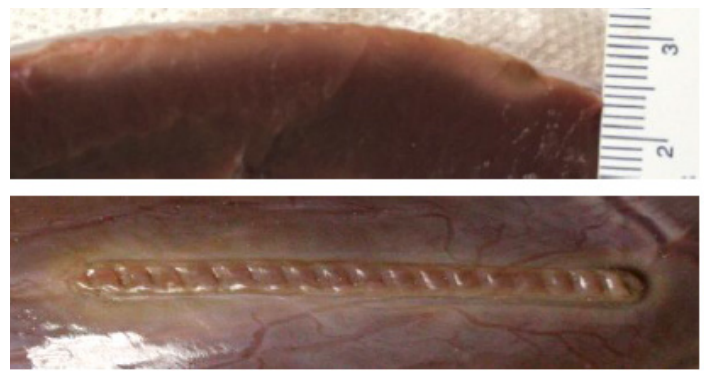
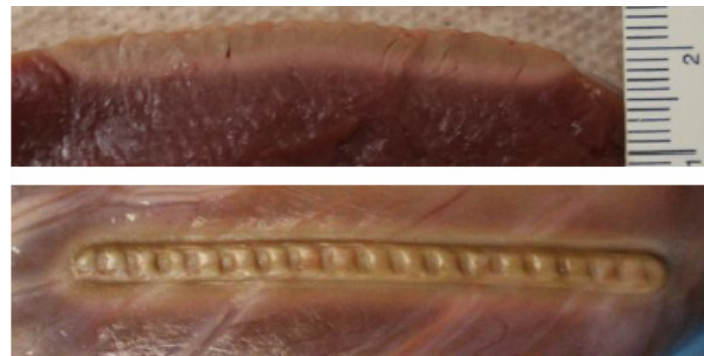

Figure 29. Normal Impedance (Avg Imp 61)



In Vitro Temperature Measure of Coagulation Device

As lesions were created with porcine left ventricle model, temperatures were measured with 3 thermistors simultaneously (Figures 30 and 31).

Figure 30. Temperature of Coagulation Device During Lesion Creation

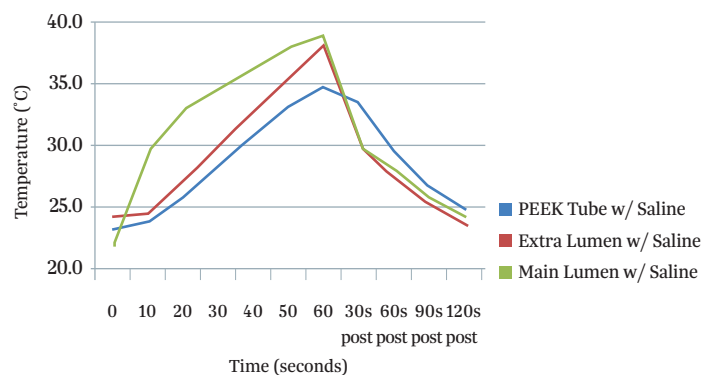
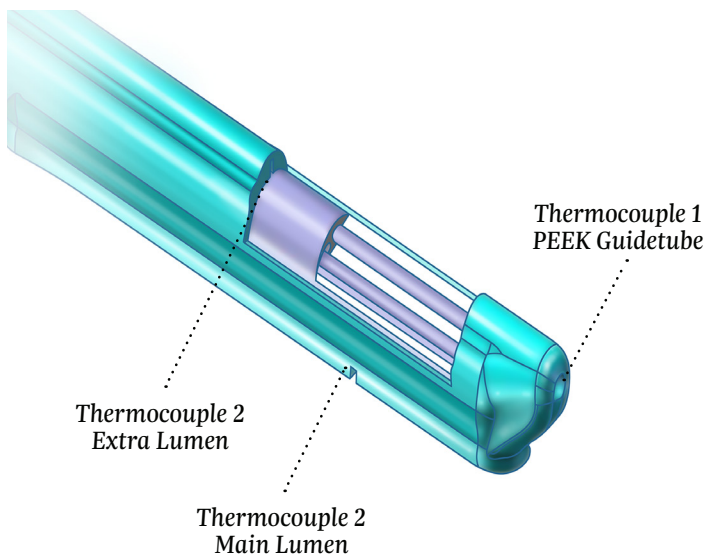


Figure 31. Position of Temperature Sensors

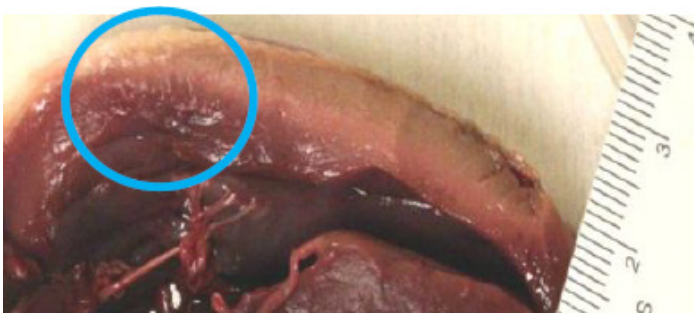

In Vitro Effect of Epicardial Fat

To create lesions on a porcine left ventricle model, a 5-cm coagulation device was set at 50 W for 60 seconds. The device was perfused with 0.9% NS.

This study was conducted to demonstrate the effect of epicardial fat on lesion creation. In Figure 32, the lesion created over fat did not have surface discoloration. The result of fat on epicardium is reduction in depth of lesion, as demonstrated in these figures below.

Figure 32. Effect of Epicardial Fat

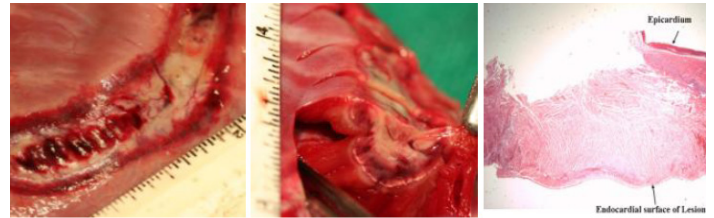


In Vivo—Lesion on Right Ventricle

To create lesions on a porcine right ventricle model, a 3-cm coagulation device was set at 30 W for 90 seconds. The device was perfused with 0.9% NS.

This study demonstrated the full depth of a lesion on thicker myocardium as well as histological stain of denatured myocardial proteins (Figure 33).

Figure 33. In Vivo Right Ventricle Lesions



Rationale for Decision to Re-Ablate a Lesion

This may be from any one or a combination of following:

1. Observation of anatomy/fat underneath device
2. Visual inspection of lesion for non-continuous surface discoloration
3. Interrogate the electrograms from the EPI-Sense device
4. Notation of impedance decrease of > 10%

Using the above rationale to decide to re-ablate a lesion can improve the success of delivering the appropriate amount of RF energy to the tissue.





EPI-Sense® Guided Coagulation System

U.S. Indications: The EPI-Sense Guided Coagulation System is intended for the treatment of symptomatic long-standing persistent atrial fibrillation (continuous atrial fibrillation greater than 12 months duration) when augmented in a hybrid procedure with an endocardial catheter listed in the instructions for use, in patients (1) who are refractory or intolerant to at least one Class I and/or III antiarrhythmic drug (AAD); and (2) in whom the expected benefit from rhythm control outweighs the potential known risks associated with a hybrid procedure such as delayed post-procedure inflammatory pericardial effusions. **Contraindications** include patients with Barrett's Esophagitis, left atrial thrombus, a systemic infection, active endocarditis, or a localized infection at the surgical site at the time of surgery. **Adverse Events:** Reported adverse events associated with epicardial ablation procedure may include, but are not limited to, the following: pericardial effusion/cardiac tamponade, pericarditis, excessive bleeding, phrenic nerve injury, stroke/TIA/neurologic complication. Please review the Instructions for Use for a complete listing of contraindications, warnings, precautions and potential adverse events located at the following AtriCure web address: <https://www.AtriCure.com/EPI-Sense-Coagulation-Device>. **Warnings:** Physicians should consider post-operative anti-inflammatory medication to decrease the potential for post-operative pericarditis, and/or delayed post-procedure inflammatory pericardial effusions. Physicians should consider post-procedural imaging (i.e. 1-3 weeks post-procedure) for detection of post-procedure inflammatory pericardial effusions. **Precautions:** Precautionary measures should be taken prior to considering treatment of patients: (1) Deemed to be high risk and who may not tolerate a potential delayed post-procedure inflammatory pericardial effusion. (2) Who may not be compliant with needed follow-ups to identify potential safety risks. To ensure patients undergoing treatment with the EPI-Sense device are well informed, the benefits, potential risks and procedural outcomes associated with the EPI-Sense Hybrid Convergent procedure should be discussed with the patient. Physicians should document accordingly in the medical record. Qualified operators are physicians authorized by their institution to perform surgical sub-xyphoid pericardial access. The coagulation devices should be used by physicians trained in the techniques of minimally invasive endoscopic surgical procedures and in the specific approach to be used. Operators should undergo training on the use of EPI-Sense device before performing the procedure. Safety and effectiveness of concomitant left atrial appendage closure was not evaluated in the CONVERGE study. Follow-up should be conducted at approximately 30 days post-procedure to monitor for signs of delayed onset pericarditis or pericardial effusion. **Rx Only.**

ATRICURE, INC.

7555 Innovation Way
Mason, OH 45040 USA
+1 (866) 349-2342
www.AtriCure.com

PE-US-0048D122.3-G

AtriCure