

15

AUTOPSY CLASS: A B C Examination Only D

Date 2/9/02 Time 0830 Dr. Schaber

FINAL ON 3/21/02 By Schaber print

APPROXIMATE INTERVAL BETWEEN ONSET AND DEATH

02-01119
BRIDGES, ELISA
NAT
LAPD-WLA

100

DEATH WAS CAUSED BY: (Enter only one cause per line for A, B, C, and D)

IMMEDIATE CAUSE

(A) Acute Intoxication by the combined

DUE TO, OR AS A CONSEQUENCE OF

(B) effects of Heroin, Methamphetamine,

DUE TO, OR AS A CONSEQUENCE OF

and Meperidine, And Al prazolan.

DUE TO, OR AS A CONSEQUENCE OF

(D)

Other conditions contributing but not related to the immediate cause of death:

UKW

PRIOR EXAMINATION REVIEW BY DME

- BODY TAG
- X-RAY (No. _____)
- SPECIAL PROCESSING TAG
- AT SCENE PHOTOS (No. 5)
- CLOTHING
- FLUORO
- MED. RECORDS
- EMS

TYPING BLOOD TAKEN BY Schaber
SOURCE Heart

TOXICOLOGY

- NO BLOOD
 - Embalmed
 - >24 hr in hospital
 - Decomposed
 - Other _____
- Reason _____

SPECIMENS

- Collected by Schaber
- HEART BLOOD
 - FEMORAL BLOOD
 - _____ BLOOD
 - _____ BLOOD
 - BILE
 - LIVER
 - URINE
 - STOMACH CONT.
 - BRAIN
 - SPLEEN
 - KIDNEY
 - VITREOUS
 - _____
 - _____

STORAGE JARS

- Regular (No. 3)
- Oversize (No. _____)
- Histopath Cut: Autopsy Lab

NO TOXICOLOGY REQUESTED

TOXICOLOGICAL ANALYSES ORDERED

- SCREEN: H T S
- ALCOHOL ONLY
 - CARBON MONOXIDE
 - NEOGEN SCREEN
 - OTHER (specify drug and tissue)

Varay

REQUESTED MATERIAL ON PENDING CASES

- Police Report
- Tox
- Microbiology
- Radiology Cons.
- Consult on _____
- Brain Submitted
- Criminalistics
- GSR
- Med History
- Histo
- Investigations
- Eye Path. Cons.
- Neuro Consult
- DME to Cut
- Sexual Assault
- Other _____

- NATURAL
- ACCIDENT
- SUICIDE
- HOMICIDE
- COULD NOT BE DETERMINED

If other than natural causes
HOW DID INJURY OCCUR? Drug Intake

WAS OPERATION PERFORMED FOR ANY CONDITION STATED ABOVE: YES NO

TYPE SURGERY _____ DATE _____

ORGAN PROCUREMENT TECHNICIAN A-

WITNESSES TO AUTOPSY EVIDENCE RECOVERED AT AUTOPSY

Item Description:

28 yo W♀ Found unresponsive in bed; NO injuries
Tox panel.

Resident _____

[Signature]
DME



**County of Los Angeles, Department of Coroner
Investigator's Narrative**



Case Number: 2002-01119

Decedent: BRIDGES, ELISA REBECA

Information Sources:

1. Officer Cortina (#35632) and Officer Johnigan (#35017), LAPD West Los Angeles, 1663 Butler Ave., Los Angeles, CA 90025, (310) 575-8404.
2. Edward Nahem, Friend, 9723 Oak Pass Road, Los Angeles, CA 90210, (310) 288-██████.
- 3.
4. On scene investigation.

Investigation:

Officer Johnigan reported this residential death to this office on 02-07-2002 at 1949 hours. Lt. Robert Fierro assigned me this case at 2100 hours. I responded to the scene at 2107 hours and arrived at 2145 hours. I completed my field investigation and returned to the FSC at 2257 hours.

Location:

Residence, 9723 Oak Pass Road, Los Angeles, CA 90210.

Witness Statements:

Upon my arrival on scene I met with Officer Cortina and Officer Johnigan and they related the following: On 02-07-2002 at approximately 1750 hours the decedent was found lying unresponsive in bed. The decedent was a houseguest and was discovered by the homeowner, Edward Nahem and another resident, Frank Lupera. 911 was called and Los Angeles City Fire Dept. RA 99 responded. Paramedics Finlay (#RF8081) and Spring (#GS5871) pronounced death on scene without medical intervention at 1758 hours. Paramedics noted there were no signs of trauma. The decedent was last seen alive at approximately 0030 hours when she went to bed. The decedent had an appointment at noon. Upon their return home, Nahem and Lupera became concerned when they noted her car still parked in the driveway. Nahem and Lupera performed CPR as instructed by 911 operators. They tried to pick the decedent up and also attempted to revive her by splashing water in her face. They found the decedent lying supine in the bed with the blankets pulled up to her chin.

I spoke to Nahem while on scene and he related the following: He had known the decedent for approximately 4 or 5 years. The decedent would stay at his home often as a guest. She always used the guest bedroom. She did not have her own key to the residence. The decedent traveled often between Los Angeles, Miami, and Hawaii as a professional model and actress. He was unaware of any medical history. The decedent did not smoke and he described her as a social drinker only. He stated the decedent probably used drugs, but he was not sure what type or how often. He was unaware of any suicidal ideations or attempts. The decedent was known to be a little depressed at times.

I spoke to Bridges via telephone on 02-08-2002 at 0145 hours and he related the following: He last spoke to his daughter approximately three days ago and she did not relate any complaints or illnesses. He was unaware of any medical history. He was unaware of any recent mishaps or accidents. He stated the decedent did drink alcohol, but he was uncertain if she ever drank to excess. He stated the decedent did use marijuana and she possibly used cocaine. He was unaware of any suicidal ideations or attempts. The decedent did suffer from depression.

Scene Description:

The scene is a large, luxurious home in an upscale neighborhood in Benedict Canyon. The home is accessed through a security gate. The residence is spacious and ornately decorated with artwork and antiques. The entire residence is clean and in good repair. The decedent is found in the guest bedroom, lying supine on a large bed and covered with blankets. The feet are pointing



**County of Los Angeles, Department of Coroner
Investigator's Narrative**



Case Number: 2002-01119

Decedent: BRIDGES, ELISA REBECA

west. The head is supported by a pillow. The decedent's clothing and personal effects are seen piled on a chair near the bed. A bottle of Xanax is found in the decedent's purse. A bathroom is seen immediately to the decedent's left. The bathroom is clean and organized. A plastic cup with a white powdery substance is seen in the wastebasket near the sink. No illegal drugs or drug paraphernalia could be located. No signs of forced entry or a struggle are visible.

Evidence:

I collected a bottle of the prescription medication Xanax and a plastic cup with a white powdery residue at the scene. The evidence was returned to the FSC and booked on the investigation floor. See Form #3A for further.

Body Examination:

I viewed the decedent's body at the scene. The decedent appears as a thin 28-year-old Caucasian female with no unusual physical characteristics and no visible deformities. No signs of foul play or trauma are visible. The decedent is wearing an orange top with matching thong underpants. The underpants have been pulled down slightly on the left side and back. A trace amount of light brown emesis is seen trailing from the right side of the mouth. The eyes appear clear and uncongested. The decedent has all natural teeth. A small scar is noted on the right side of the neck. No other identifying scars, marks, or tattoos are visible. Rigor mortis is a 4+ throughout the body. Purple lividity is consistent with the position found and blanches to firm fingertip pressure.

Identification:

The decedent was identified at the scene by her California driver's license # B8962567.

Next of Kin Notification:


I notified the decedent's father via telephone on 02-08-2002 at 0145 hours.

Tissue Donation:

SCOPC contacted family.

Autopsy Notification:

None requested.


John Kades, #474887

Supervisor's Name

02/08/2002

Date of Report

COUNTY OF LOS ANGELES

PRELIMINARY EXAMINATION REPORT - FIELD

DEPARTMENT OF CORONER

6WAS ORIGINAL SCENE DISTURBED BY OTHERS? YES NO

IF YES, NOTE CHANGES IN NARRATIVE FORM #3.

DATE 02-07-20022002-01119Bridges, Elisa

AMBIENT #1 _____ °F

TIME _____

AMBIENT #2 _____ °F

TIME _____

WATER _____ °F

TIME _____

LIVER TEMPERATURE #1 _____ °F

TIME _____

LIVER TEMPERATURE #2 _____ °F

TIME _____

THERMOMETER # _____

DATE & TIME FOUND 02-07-2002, 1750 hrs. LAST KNOWN ALIVE 02-07-2002, 0030 hrs.APPROX. AGE 28 SEX F EST. HEIGHT 60 EST. WEIGHT 90 CLOTHED? YES NO IF YES, DESCRIBE:Orange top, orange underpants

DESCRIPTION AS TO WHERE REMAINS FOUND AND CONTACT MATERIAL TO BODY:

Lying supine in bed, covered w/ blankets.SCENE TEMPERATURE REGULATED? YES NO IF YES, THERMOSTAT SET AT _____ DEGREES F.LIVOR MORTIS: TIME OBSERVED 2153RIGOR MORTIS: TIME OBSERVED 2159

NECK FLEXION:

ANTERIOR 4+POSTERIOR 4+RT. LATERAL 4+LT. LATERAL 4+JAW 4+ HIP 4+SHOULDER 4+ KNEE 4+ELBOW 4+ ANKLE 4+WRIST 4+

SCALE

0 = ABSENT/NEGATIVE

1 +

2 +

3 +

4 = EXTREME DEGREE

USE SCALE TO DESCRIBE INTENSITY OF RIGOR MORTIS.

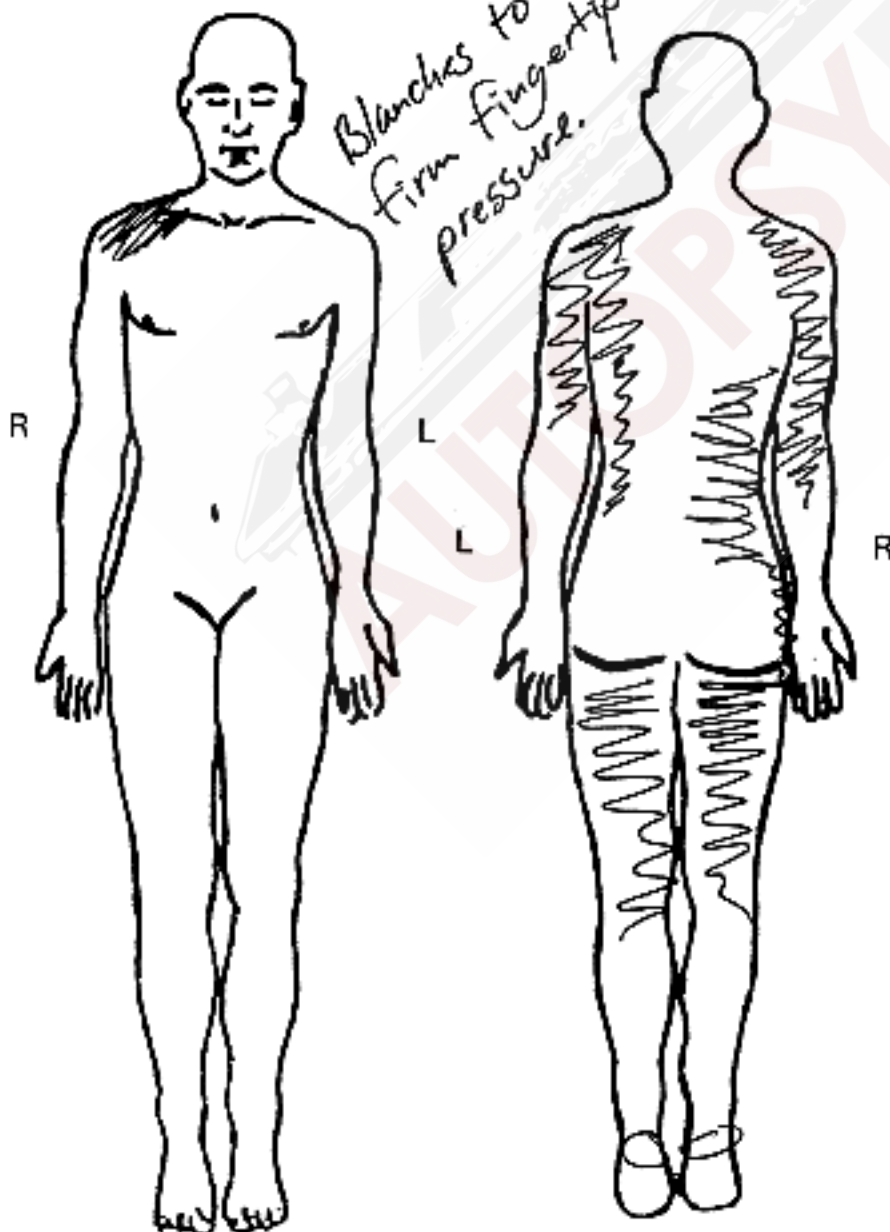
SHADE DIAGRAMS TO ILLUSTRATE THE LOCATION OF LIVOR MORTIS.

DESCRIBE INTENSITY OF COLORATION AND WHETHER LIVOR MORTIS IS PERMANENT OR BLANCHES UNDER PRESSURE.

J Kades, #474887

CORONER'S INVESTIGATOR

REVIEWED BY:



12**AUTOPSY REPORT**

No.

2002-01119

BRIDGES, ELISA R.

I performed an autopsy on the body of  at _____ the DEPARTMENT OF CORONER

Los Angeles, California

on FEBRUARY 9, 2002 @ 0830 HOURS
(Date) (Time)

From the anatomic findings and pertinent history I ascribe the death to:


(A) ACUTE INTOXICATION BY THE COMBINED EFFECTS OF HEROIN,
 DUE TO, OR AS A CONSEQUENCE OF METHAMPHETAMINE, MEPERIDINE, AND ALPRAZOLAM

(B)
 DUE TO, OR AS A CONSEQUENCE OF

(C)
 DUE TO, OR AS A CONSEQUENCE OF

(D)
 OTHER CONDITIONS CONTRIBUTING BUT NOT RELATED TO THE IMMEDIATE CAUSE OF DEATH.

Anatomical Summary:

- I. Acute multiple drug intoxication:
 -  A. Toxicology heart blood positive for free morphine, Alprazolam, and methamphetamine; urine positive for meperidine and 6-monoacetylmorphine.
 - B. See Toxicology Report.
- II. Minor blunt impact injuries of the extremities.
- III. Probable superficial gastritis with gastric hemorrhage, 120 cc, etiology undetermined.

12**AUTOPSY REPORT**

No.

2002-01119

BRIDGES, ELISA R.

Page 2

CIRCUMSTANCES:

See the Investigator's Report.

I hereby certify that I, Bethann Schaber, M.D., Deputy Medical Examiner, have performed an autopsy on the body of Elisa Rebeca Bridges on 2/09/02, commencing at 0830 hours in the mortuary of the Los Angeles Department of Coroner.

EXTERNAL EXAMINATION:

The body is that of a well-developed, thin, small-framed, 60-inch, 90-pound Caucasian woman, whose appearance is consistent with the given age of 28 years.

The wavy, light brown hair with blonde highlights measures up to 12 inches. The nose and facial bones are intact by palpation. The eyes have cloudy corneas and brown irides, and the conjunctivae are without hemorrhage, petechiae or jaundice. The oral cavity has natural teeth, in good repair and an atraumatic mucosa. There is red-brown discoloration on the lips (Comment: Consistent with drying artifact). The torso is unremarkable. The extremities show no puncture sites or track marks. There is pink nailpolish on the toenails. An obliquely oriented, well-healed, 1 inch scar is on the right side of the neck. The earlobes are pierced. There are no tattoos. The external genitalia are of a normal atraumatic adult woman.

POSTMORTEM CHANGES:

There is mild symmetrical rigor mortis of the upper and lower extremities, neck and jaw. Lividity is pink-purple, posterior and fixed with blanching over pressure spots. The body is cold (refrigeration).

There are early putrefactive changes, manifested by grown-green skin discoloration over the right lower quadrant of the abdomen.

12**AUTOPSY REPORT**

No.

2002-01119

BRIDGES, ELISA R.

Page 3**INJURIES, EXTERNAL AND INTERNAL:**

There are minor blunt impact injuries of the extremities.

Red abrasions, measuring 1/4 and 1/2 inch in diameter, are on the right elbow. A 1-1/2 inch red abrasion is on the left knee. An obliquely oriented 1 inch abrasion is on the right hip. Punctate red abrasions with surrounding pink-purple contusion are on the lateral aspect of the right knee, covering an area 1-1/2 inches x 1 inch.

INTERNAL EXAMINATION:

Central nervous system: The scalp has no contusion. The skull has no fracture. There is no epidural, subdural or subarachnoid hemorrhage. The brain weighs 1300 grams. The cerebral hemispheres are symmetrical with the usual pattern of sulci and gyri. The leptomeninges are thin and glistening. The cerebral vessels are without aneurysm. The cranial nerves are unremarkable. The white and gray matter, deep nuclei and ventricles are unremarkable. There are no focal lesions. The brainstem and cerebellum have the usual patterns on cut surface.

Neck: The cervical vertebrae, hyoid bone, trachea and laryngeal cartilages and peritracheal soft tissues are without trauma. The upper airway is patent. The tongue is unremarkable.

Body cavities: The organs are in their normal situs. The pleural and peritoneal cavities contain no fluid, hemorrhage or adhesion.

Cardiovascular system: The heart weighs 190 grams and has a normal distribution of widely patent right predominant coronary arteries. The myocardium is homogeneous, red and firm without pallor, hemorrhage, softening or fibrosis. The left ventricular wall is 1.1 cm, and the right ventricular wall is 0.2 cm thick. The endocardial surfaces and four cardiac valves are unremarkable. The aorta has fatty streaks. The venae cavae and pulmonary arteries are without thrombus or embolus.

12**AUTOPSY REPORT**

No.

2002-01119

BRIDGES, ELISA R.

Page 4

Respiratory system: The right lung weighs 500 grams, and the left lung weighs 460 grams. The purple-red parenchyma shows posterior dependent lividity with mild edema and congestion. Cross-sectioning reveals no masses, hemorrhage or consolidation. The bronchi are unremarkable.

Liver, gallbladder and pancreas: The liver weighs 1240 grams and has an intact capsule and a congested, red-brown parenchyma without fibrosis or slippery texture. The gallbladder contains approximately 4 cc of yellow bile without stones. The pancreas is unremarkable in lobulation, color and texture.

Hemic and lymph nodes: The spleen weighs 130 grams and has an intact capsule and an unremarkable purple-red parenchyma. There are no lymph node enlargements. The bone marrow is unremarkable.

Genitourinary system: The right kidney weighs 80 grams, and the left kidney weighs 90 grams. Each kidney has a smooth, red-brown surface and unremarkable architecture and vasculature. The ureters maintain a uniform caliber into an unremarkable bladder, containing approximately 10 cc of yellow urine. The ovaries, fallopian tubes and uterus are unremarkable. The endometrium is hemorrhagic and measures 0.2 cm in thickness (Comment: Consistent with menstrual-type). The vagina is atraumatic.

Endocrine system: The pituitary, thyroid and adrenal glands are normal in color, size and consistency.

Digestive system: The esophagus and gastroesophageal junction are unremarkable. There are no varices. The stomach contains approximately 120 cc of red hemorrhagic fluid without food particles, tablets or capsules. The gastric mucosa is autolyzed with no ulceration or focal lesion. The proximal small intestine contains hemorrhagic mucoid material. The mucosa is autolyzed with no ulceration or focal lesion. The large intestine is unremarkable. The rectum contains firm, brown stool. The appendix is present.

12**AUTOPSY REPORT**

No.

2002-01119

BRIDGES, ELISA R.

Page 5

Musculoskeletal system: The vertebrae, clavicles, sternum, ribs and pelvis are without fracture. The musculature is normally distributed and is unremarkable.

TOXICOLOGY:

Specimens are submitted for toxicologic analysis. A separate report will be issued.

PHOTOGRAPHY:

Photographs are taken prior to and during the autopsy.


DIAGRAMS USED:

Diagram 20 was used in the preparation of this autopsy report.

OPINION:

This 28-year-old Caucasian woman died as a result of acute multiple drug intoxication. Toxicology results are positive for heroin, methamphetamine, Alprazolam, and meperidine.

Based on the history, Investigator's Report, Police Report, and autopsy findings as currently known, the manner of death is accident.



BETHANN SCHABER, M.D.
DEPUTY MEDICAL EXAMINER

04-16-2002
DATE

BS:am/dv:c/f
D-02/09/02-1120 hours
T-02/12/02