

Refractory Status Epilepticus as the First Presentation in an Infant with Alpers Disease

Saleh M. Al-Qahtani, MD* Ibrahim A. Al Zaydani Asiri, MD** Obaid Mohammed Albulym, MD*** Mansour Y Otaif, MD****

ABSTRACT

Objective: Alpers Huttenlocher disease although is a rare mitochondrial disease, but is still present in different nervous systems and other system's features. Seizures and neurodegeneration are one of the early pictures encountered.

Case: A case of 11-month-old girl with acute onset of epileptic seizures has been reported along with her brother who died two years before this event following the same disease and symptoms. Her lab work values were normal for which she was planned for MRI. However, because of her general condition, only CT scan of brain was done which showed normal study.

Results: The electroencephalographic findings show a pattern of continuous, anterior, high-voltage, 1-to-3-Hz spike-and-wave like activity that persists despite intermittent focal seizures. Death is not unusual in the setting of persistent seizures, and valproic acid should be avoided unless polymerase gamma γ level in genetic testing produces normal level. Whole exome sequencing identified the homozygous missense mutation c.3286C>T in *POLG* gene which corresponds to the p.R1096C amino acid change.

Conclusion: Alpers Huttenlocher disease should be considered in different diagnosis of refractory status epilepticus in infants even in absence of liver disease signs.

Keywords: Alpers Huttenlocher, Epilepsy, Infant, Refractory Status Epilepticus, Seizures

INTRODUCTION

Clinical difficulties and management concerns are always present when a child has refractory status epilepticus (RSE). This case study details the death of a brother and sister from Alpers Huttenlocher disease, which manifested with RSE but no acute liver damage. Although familial occurrence is not widespread, it is a negative prognostic sign for both parents and doctors.

CASE REPORT

An eleven-month-old girl was admitted in our hospital with acute onset of epileptic seizures. Her seizures started prior the day of admission in the form of generalized tonic-clonic attacks, which was not responded by any initial medical therapy at her local nearby hospital. Afterwards, she was transferred to our neurology unit with impression of refractory status epilepticus. The occurrence of a refractory status epilepticus was observed during the course of her disease, which was controlled by sodium valproate started in the previous treating hospital. Subsequently, she had repeated vomiting, become jaundiced, and flaccid. Valproic acid was stopped due to the significant increase found in the results of liver enzyme assays. Her progressive mental deterioration was followed by flaccidity and generalized myoclonic status. Her seizures were refractory and stopped clinically only after IV paralysation as per status epilepticus protocol. Her death was caused after three months

of illness following aspiration pneumonia. Cerebral atrophy has been reported by a brain CT scanning.

She was perfectly well before the attacks, had no fever, trauma or other medical illnesses. She had normal antenatal records with appropriate development for age. The illness of patient had begun seven months ago with sudden onset of focal myoclonic jerks, which was ended in a generalized myoclonic status epilepticus three days later and hospitalization. No abnormality was reported at that time. Afterwards, she became hypotonic, so she could not sit regardless of any support and even lost her head control.

Unfortunately, two years earlier, her brother at the age of one year suddenly started seizing in an aggressive pattern. Before this occurrence, he also had no clinical issues. He was admitted to Pediatric intensive care unit (PICU) immediately, screened for infections, toxins, metabolic crises, neoplasm which was thought to be a cause. None of them were conclusive and he died 3 weeks after with no seizure control. They both were living with caring parents in their thirties, non-consanguineous and they have no history of epilepsy, children deaths or developmental delay. They live in an area with no apparent known exposures to toxins or radiations.

Her clinical examination showed no dysmorphic features and had normal head circumference. Her systemic and neurological examination

* Department of Child Health
College of Medicine
King Khalid University

** Department of Pediatrics
Abha Maternity and Children Hospital

*** Department of Biology
College of Science

**** Department of Pediatric Neurology, Abha Maternity and Children Hospital
Saudi Arabia
E-mail: mansourotaif@gmail.com

(she was under effect IV sedation and antiepileptic) did not show any signs of systemic disease or focal motor deficit. She had normal optic discs and macula exam, with no neurocutaneous stigmata. Her course in the hospital was less than 7 days, but she started to require maximum ventilator and hemodynamic support upon admission. She was covered initially with broad spectrum antibiotics and antiviral, screened for infections and her medications were adjusted accordingly. Following investigations were conducted: CBC, sugar, sodium, potassium, magnesium, renal profiles, hepatic profiles, ammonia, and lactate and blood gases. Toxicology screening was provided to measure the approximate amount of drug given, but showed negative findings. Her lab work values were normal for which she was planned for MRI. However, because of her general condition, only brain CT scan was done, which showed normal study (Figure 1). Moreover, her electroencephalography (EEG), showed slow background with high amplitude Delta waves with superimposed poly spikes (RHADS) as shown in figure 2.

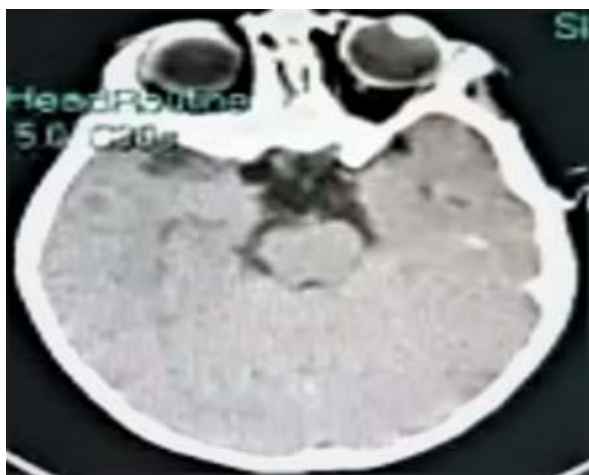

Figure 1: Normal axial view non contrasted CT brain

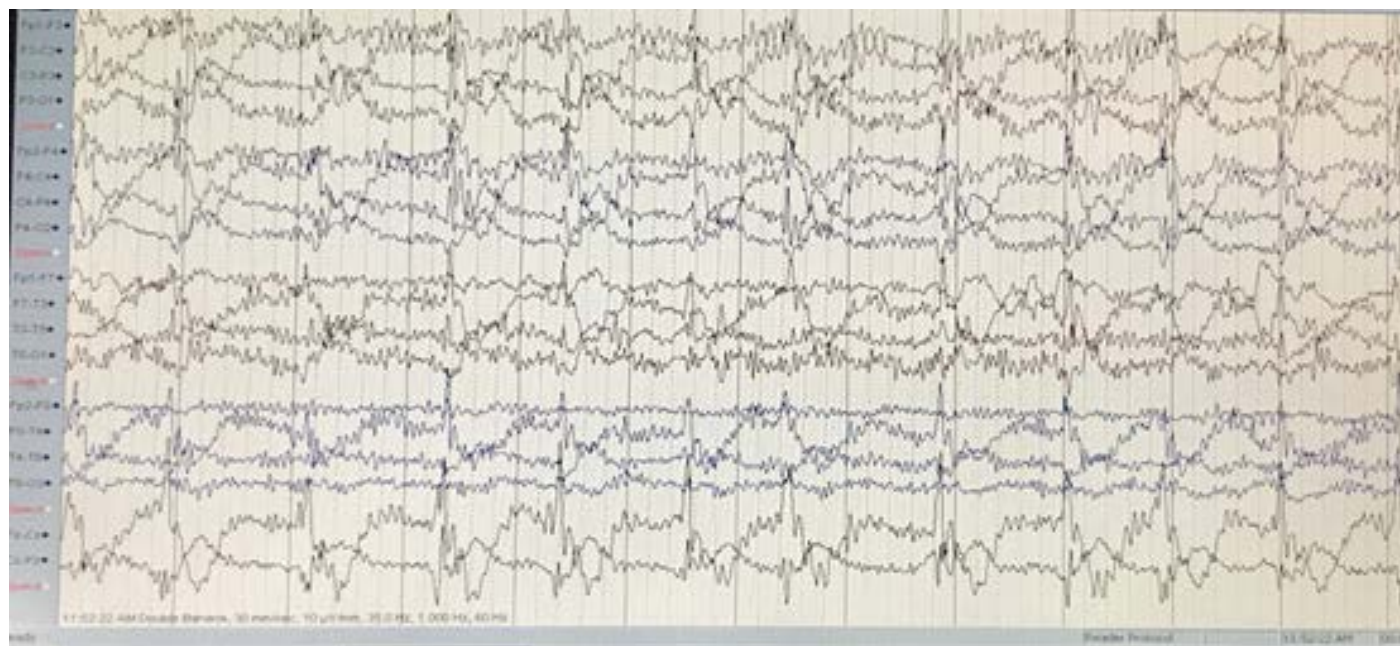

Figure 2: Slow background with High Amplitude Delta waves with superimposed poly Spikes (RHADS)

(Table 1) shows whole exome sequencing results conducted for her. Likely, pathogenic missense variant (c.3286C>T, p.Arg1096Cys) was identified in homozygous form in Polymerase, DNA, Gamma; POLG gene (OMIM#174763). This variant is known to cause Mitochondrial DNA depletion syndrome 4A (OMIM# 203700). Upon reviewing her brother's records, following findings were reported in (Figure 3A, 3B, and 3C). (Figure 4) shows EEG report for her brother.

DISCUSSION

Alpers-Huttenlocher syndrome (AHS, OMIM203700) is a fatal hepatocerebral degenerative mitochondrial (mtDNA) depletion illness that is genetically diverse. It's been described by Bernard Alpers as a specific diffuse progressive degeneration of the grey matter of the cerebrum with persistent generalised seizures. It was found by Huttenlocher et colleagues as a unique disease of progressive neurodegeneration and hepatic failure¹. Epilepsy is frequent in polymerase gamma (POLG) patients and is linked to a high rate of mortality and morbidity². In the available data on the frequency of epilepsy in individuals with mitochondrial disease, seizures were observed in 35-60% of patients with biochemically confirmed mitochondrial impairment³. Patients with POLG mutations were found to have a higher rate of epilepsy⁴. The mechanisms involved in POLG-related seizures appear to be the first and most important determinant in the subsequent development of cellular dysfunction caused by mtDNA depletion.

Energy metabolism is disabled as a result of the loss of MRC components, which is caused by the loss of mtDNA. Due to this delicately balanced neuronal energy consumption, two outcomes are possible. First, it causes the neuron to be unable to cope with increased demand, which can result in a potentially catastrophic cycle leading in acute localised necrosis; second, it causes chronic and continual attrition^{1,2}. Even if hepatic involvement is missing in some situations,

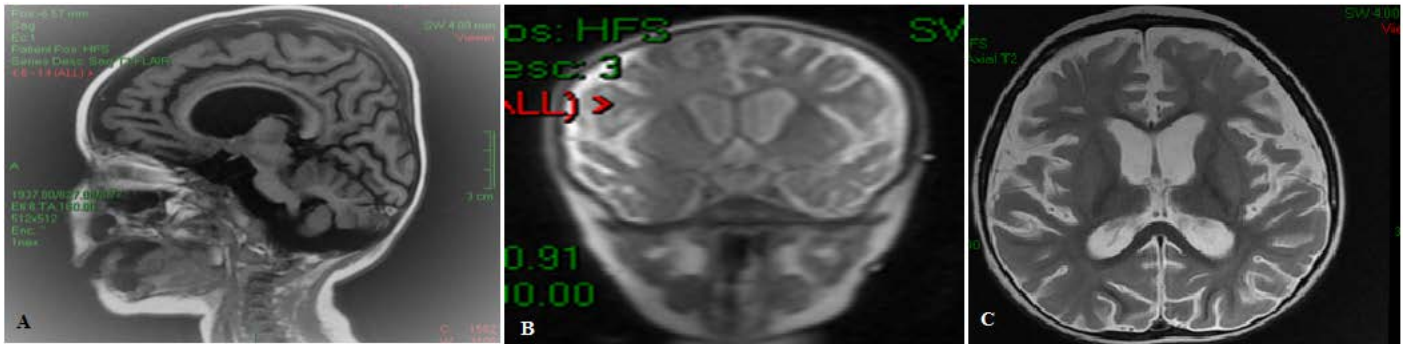


Figure 3: (A) SagittalT1, coronal T2 and axialT2 showed nonspecific atrophic changes; (B) SagittalT1, coronal T2 and axialT2 showed nonspecific atrophic changes and (C): SagittalT1, coronal T2 and axialT2 showed nonspecific atrophic changes.

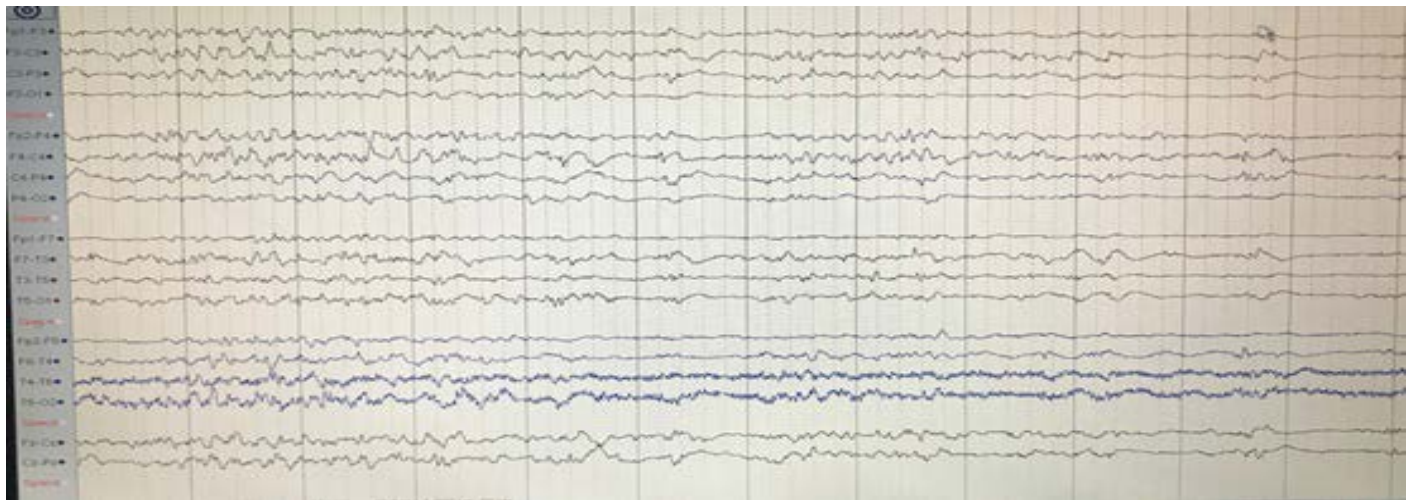


Figure 4: Brother’s EEG Report (Intermittent slow activities with @ frontal & temporal sharp waves)

Table 1: Whole Exome Sequencing

GenaTi #	Sequence variants Classification	Gene	Transcript	DNA variation	Predicted Effect
PBG-820-18	likely pathogenic	POLG	NM 002693.2	c.3286C>T Homozygous missense variant	p.Arg1096Cys

seizure disorder usually has a negative beginning when compared to clinical symptoms of liver illness. Although biochemical evidence of liver illness is present before the start of seizures, normal liver functions were described in our patient⁵. The condition, according to Frydman et al⁶, can sadly run-in families, as in our case.

The electroencephalographic data reveal a pattern of continuous, anterior, high-voltage, 1-to-3-Hz spike-and-wave activity that persists despite the occurrence of sporadic focal seizures. As the disease progressed, there was also a gradual decrease in background activity⁷. Early detection may be aided by the presence of Rhythmic High Amplitude Delta waves with superimposed poly Spikes (RHADS), but this is not always the case⁸. Patients with well-documented EEG abnormalities and clinical seizures are more likely to have occipital lobe findings. As the condition advances, the majority of patients experience recurrent status epilepticus episodes and epilepsy partialis continua.

In the case of chronic seizures, death is not uncommon, and valproic acid should be avoided unless the polymerase gamma level in genetic testing is normal. Cortical blindness due to neuronal loss in the striate and calcarine cortices, sensory neuropathy in older children, and ataxia have also been documented⁷. Although neuroimaging is not a

diagnostic technique in this disease, typical MRI scans reveal various abnormalities. White matter loss and cortical thinning in the frontal, posterotemporal, and occipital lobes, as well as nonspecific thalamic signals, have all been described⁹⁻¹¹.

The POLG gene produces a 140-kDa catalytic subunit of the human DNA polymerase, which is important for mitochondrial genome replication. POLG mutations have been found in a variety of mitochondrial depletion syndromes, including Alpers-Huttenlocher syndrome¹². Other genes have been linked to Alpers-Huttenlocher syndrome, including FARS2, PARS2, NARS2, and TWNK¹³. However, POLG mutations are the most common in Alpers-Huttenlocher syndrome, with 70 percent of cases being caused by POLG mutations^{12,13}. As a result, genetic testing for this gene should be prioritised in such patients. It is obvious that the problem of phenotypic variability in POLG-related disorders persists, and further research is needed to enhance clinical diagnosis.

DIAGNOSTIC CRITERIA FOR ALPERS-HUTTENLOCHER SYNDROME¹⁴

1. A clinical trial of refractory seizures, psychomotor regression, and hepatopathy.

2. In the absence of hepatopathy or additional findings, the diagnosis can only be confirmed by polymerase-gamma gene sequencing, liver biopsy, or postmortem examination.
3. Additional clinical findings (at least two of the 11 findings must be present) for:
 - a. Cranial proton magnetic resonance spectroscopy indicating reduced N-acetyl aspartate, normal creatine, and elevated lactate.
 - b. Elevated cerebrospinal fluid protein (>100 mg/dL).
 - c. Cerebral volume loss (central more than cortical, with ventriculomegaly) on repeated magnetic resonance imaging or computed tomography.
 - d. At least one electroencephalogram revealing multifocal paroxysmal activity with high-amplitude δ slowing (200-1000 μ V) and spikes/polyspikes (10-100 μ V, 12-25 Hz).
 - e. Cortical blindness or optic atrophy.
 - f. Abnormal visual-evoked potentials and normal electroretinogram findings.
 - g. Quantitative mitochondrial DNA depletion in skeletal muscle or liver (35% of the mean).
 - h. Deficiency in polymerase- γ enzymatic activity \leq 10% in skeletal muscle or liver.
 - i. Elevated blood or cerebrospinal fluid lactate (3 mM) on at least one occasion in the absence of acute liver failure.
 - j. Isolated complex IV or a combination of complex I, III, and IV electron transport defects \leq 20% of normal) upon liver respiratory chain testing.
 - k. A sibling confirmed as manifesting Alpers-Huttenlocher syndrome

CONCLUSION

Alpers Huttenlocher disease should be considered in the differential diagnosis of refractory status epilepticus in infants even in the absence of liver disease signs.

Authorship Contribution: All authors share equal effort contribution towards (1) substantial contributions to conception and design, acquisition, analysis and interpretation of data; (2) drafting the article and revising it critically for important intellectual content; and (3) final approval of the manuscript version to be published. Yes.

Potential Conflict of Interest: None.

Competing Interest: None.

Sponsorship: None.

Acceptance Date: 29 September 2021

Acknowledgment: The author is very thankful to all the associated personnel in any reference that contributed in/for the purpose of this research. The author declares no conflict of interest.

REFERENCES

1. Kentab AY. Alpers-Huttenlocher Syndrome presenting with epilepsipartialis continua. *J Neurol Stroke* 2019;9(1):29-32.
2. Hikmat O, Eichele T, Tzoulis C, et al. Understanding the epilepsy in POLG related disease. *Int J Mol Sci* 2017;18(9):1845.
3. Debray FG, Lambert M, Chevalier I, et al. Long-term outcome and clinical spectrum of 73 pediatric patients with mitochondrial diseases. *Pediatrics* 2007;119(4):722-33.
4. Horvath R, Hudson G, Ferrari G, et al. Phenotypic spectrum associated with mutations of the mitochondrial polymerase gamma gene. *Brain* 2006;129(7):1674-84.
5. Barzegar M, Hashemilar M. Alpers disease: Report of two familial cases. *Pak J o Med Sci* 2007;23(4):643.
6. Naviaux RK, Nguyen KV. POLG mutations associated with Alpers syndrome and mitochondrial DNA depletion. (Letter) *Ann Neurol* 2005;55(5):706-12.
7. Saneto RP, Cohen BH, Copeland WC, et al. Alpers-Huttenlocher syndrome. *Pediatr Neurol* 2013;48(3):167-78.
8. Wolf NI, Rahman S, Schmitt B, et al. Status epilepticus in children with Alpers disease. *Epilepsia* 2009;50(6):1596-607.
9. Brick JF, Westmoreland BF, Gomez M. The electroencephalogram in Alpers disease. In *electroencephalography and clinical neurophysiology* 1984;58(2):P31.
10. Walton A. A case study of Alper's disease in siblings. *Am J EEG Technol* 1996;36(1):18-27.
11. Barkovich AJ, Good WV, Koch TK, et al. Mitochondrial Disorders: Analysis of their clinical and imaging characteristics. *Am J Neuroradiol* 1993;14(5):1119-37.
12. Rahman S, Copeland WC. POLG-related disorders and their neurological manifestations. *Nat Rev Neurol* 2019;15(1):40-52
13. Hikmat O, Tzoulis C, Chong WK, et al. The clinical spectrum and natural history of early-onset diseases due to DNA polymerase gamma mutations. *Genet Med* 2017;19(11):1217-25
14. Nguyen KV, Sharief FS, Chan SSL, et al. Molecular diagnosis of Alpers syndrome. *J Hepatol* 2006;45(1):108-16.