

Esophageal Motility Disorders: Current Approach to Diagnostics and Therapeutics



Dhyanesh A. Patel,¹ Rena Yadlapati,² and Michael F. Vaezi¹

¹Division of Gastroenterology, Hepatology and Nutrition, Vanderbilt University Medical Center, Nashville, Tennessee; and
²Division of Gastroenterology, University of California San Diego, San Diego, California

Dysphagia is a common symptom with significant impact on quality of life. Our diagnostic armamentarium was primarily limited to endoscopy and barium esophagram until the advent of manometric techniques in the 1970s, which provided the first reliable tool for assessment of esophageal motor function. Since that time, significant advances have been made over the last 3 decades in our understanding of various esophageal motility disorders due to improvement in diagnostics with high-resolution esophageal manometry. High-resolution esophageal manometry has improved the sensitivity for detecting achalasia and has also enhanced our understanding of spastic and hypomotility disorders of the esophageal body. In this review, we discuss the current approach to diagnosis and therapeutics of various esophageal motility disorders.

Keywords: Absent Contractility; Achalasia; Barium Esophagram; Distal Esophageal Spasm; Esophagogastric Junction; Esophageal Motility Disorders; FLIP; High-Resolution Manometry; Hypercontractile Esophagus; Ineffective Esophageal Motility.

The esophagus is a complex muscular tube that uses coordinated peristalsis and deglutitive relaxation of the upper and lower esophageal sphincter (LES) to transport a bolus from the pharynx into the stomach. Disruption in either the peristalsis of the esophageal body or deglutitive relaxation of the LES can lead to obstructive symptoms, which include dysphagia, noncardiac chest pain, and regurgitation. Based on population-based surveys, nearly half of the US population might have esophageal symptoms including heartburn, regurgitation, or dysphagia.^{1,2} Classically, dysphagia to solids raises suspicion for a primary mechanical pathology, whereas dysphagia to liquids with or without dysphagia to solids is more suggestive of an esophageal motility disorder. Upper endoscopy with biopsy is the recommended first-line diagnostic test for esophageal dysphagia, with esophageal motility testing as the next step in evaluation if a mechanical or mucosal source of dysphagia (such as infectious, pill, reflux, or eosinophilic esophagitis) has been ruled out.³

Chest pain is frequently attributed to “esophageal spasm” by medical providers in clinical practice, but it is important to recognize that only 1%–2% of patients undergoing esophageal manometry have findings of a spastic disorder.^{4,5} On the other hand, 1 person dies every 36 seconds in the United States from coronary artery disease,

leading to, overall, 1 in every 4 deaths.⁶ The prevalence of gastroesophageal reflux disease is also significantly higher compared with spastic motor disorders affecting 1 in 3 persons in the United States.¹ Hence, in patients with chest pain as the solo symptom, thorough work-up for cardiac etiology followed by reflux should precede any consideration of esophageal dysmotility.

Our diagnostic armamentarium was primarily limited to endoscopy and barium esophagram until the advent of manometric techniques in the 1970s, which provided the first reliable tool for assessment of esophageal motor function.⁷ Subsequently, in the 1990s, Clouse et al.^{8,9} developed high-resolution manometry (HRM), which revolutionized motility testing by giving us a complete spatial and temporal depiction of esophageal motor function. Over time, HRM testing has become the gold standard in evaluation of patients with suspected motility disorders of the esophagus. In this review, we discuss the current approach to diagnosis and therapeutics of various esophageal motility disorders. We start with review of the diagnostic tools followed by evaluation and management of disorders of esophagogastric junction (EGJ) and disorders of esophageal peristalsis. Lastly, we briefly discuss the impact of esophageal mucosal diseases, systemic disease, medications, and altered foregut anatomy on esophageal motility.

Diagnostic Tools

Endoscopy

Esophagogastroduodenoscopy is a requisite in the evaluation of patients with suspected esophageal dysmotility because it can enable direct mucosal visualization and exclude benign (peptic stricture, hiatal hernia, Schatzki's ring, eosinophilic esophagitis, altered foregut anatomy) or malignant conditions that can lead to secondary motility

Abbreviations used in this paper: CC, Chicago Classification; DCI, distal contractile integral; DES, distal esophageal spasm; DI, distensibility index; DL, distal latency; EGJ, esophagogastric junction; EoE, eosinophilic esophagitis; FLIP, Functional Lumen Imaging Probe; GERD, gastroesophageal reflux disease; HRM, high-resolution manometry; IEM, ineffective esophageal motility; IRP, integrated relaxation pressure; LES, lower esophageal sphincter; LHM, laparoscopic Heller myotomy; MRS, multiple rapid swallow; EGJOO, esophagogastric junction outflow obstruction; PD, pneumatic dilation; POEM, per-oral endoscopic myotomy; RDC, rapid drink challenge; TBE, timed barium esophagram.

Most current article

© 2022 by the AGA Institute
0016-5085/\$36.00

<https://doi.org/10.1053/j.gastro.2021.12.289>

Table 1. Adjunctive Diagnostic Tests to Conventional HRM Available for Evaluation of Esophageal Motility Disorder

Diagnostic test	Protocol	Supportive evidence
Endoscopy	Careful attention to esophageal diameter, LES tone, retention of liquid/saliva on insertion	Puckered gastroesophageal junction with resistance to passage of scope with retained liquid in the esophagus is supportive of obstructive process such as achalasia Presence of “foam” in the esophagus suggest dysmotility but is not specific for a manometric diagnosis.
FLIP	Placed transorally with balloon traversing the EGJ Volumetric distention of the balloon to predetermined volumes based on catheter type	EGJ-DI of $<2.0 \text{ mm}^2/\text{mm Hg}$ is abnormal EGJ diameter of $<13 \text{ mm}$ is likely abnormal Role in various manometric diagnoses is evolving
TBE with barium tablet (13 mm)	Perform in upright position using 8 oz or 236 mL of barium Evaluate barium height at 1, 2, and 5 min	Barium column height to support outflow obstruction (such as achalasia) >5 cm at 1 min >2 cm at 5 min 13-mm barium tablet retention supports obstructive process 3% improvement (decrease) in pre- to post-treatment barium height at 5 min might predict long-term clinical remission in achalasia Corkscrew appearance may be suggestive of distal esophageal spasm
MRS (HRM)	5 swallows of 2-mL liquid at 2–3 s intervals	Absence of esophageal body contractility (DCI $<100 \text{ mm Hg}\cdot\text{s}\cdot\text{cm}$) with complete deglutitive inhibition of LES during MRS Augmentation (peristaltic reserve) present if post-MRS esophageal body peristaltic contraction is normal (DCI $>450 \text{ mm Hg}\cdot\text{s}\cdot\text{cm}$) and any of 3 post-contractions with increased contractile vigor (DCI $>$ single swallow mean DCI)
RDC (HRM)	Rapid drink of 200 mL of liquid	Absence of esophageal body contractility (DCI $<100 \text{ mm Hg}\cdot\text{s}\cdot\text{cm}$) with complete deglutitive inhibition of LES during RDC IRP $>12 \text{ mm Hg}$ (Medtronic software) and pan-esophageal pressurization ($>20 \text{ mm Hg}$) are supportive of outflow obstruction

abnormalities. Endoscopy also allows delivery of therapeutics with esophageal dilation when a stricture is encountered. Findings of retained saliva or liquid in the esophageal lumen along with puckered LES and longitudinal superficial wrinkles of esophageal mucosa (pinstripe mucosa) are suggestive of a major esophageal motility disorder and are found in 41%–94% of patients with achalasia.¹⁰ In this scenario, careful evaluation of gastroesophageal junction, gastric fundus, and gastric cardia should be performed to exclude malignancy that can cause pseudo-achalasia. Table 1 shows the various diagnostic tests and how they can provide adjunctive evidence to esophageal manometry testing in evaluation of patients with suspected esophageal motility disorder. It is important to recognize that a clinical diagnosis depends on information obtained from various tests combined with patient symptom presentations, which provide complementary data in completing the diagnostic puzzle.

Functional Lumen Imaging Probe

Functional Lumen Imaging Probe (FLIP) is the newest Food and Drug Administration–approved diagnostic tool to assess esophageal physiology and is still in early clinical phases. The FLIP catheter includes a distensible balloon

encasing multiple pairs of impedance sensors and a single distal pressure sensor. During a sedated upper gastrointestinal endoscopy, the FLIP catheter is placed transorally such that the balloon traverses the EGJ. Then the balloon is distended with a conductive fluid through a mechanical pump. The FLIP system converts the readings into a 3-dimensional rendering of the esophageal lumen in real time and measures the relationship between the cross-sectional area (mm^2) over the distensive pressure to generate a luminal distensibility.^{11,12} The most recent FLIP version 2.0 or FLIP topography converts the readings to color-coded luminal diameter plots enabling evaluation of distensibility across the EGJ as well as contractile response to distension in the esophageal body. Data from healthy volunteers suggests that a normal EGJ distensibility index (EGJ-DI) is $>2.8 \text{ mm}^2/\text{mm Hg}$ and normal EGJ diameter is $>13 \text{ mm}$.¹³ Further, the presence of repetitive antegrade contractions is considered a normal response to distension.¹⁴ On the other hand, reduced EGJ-DI and/or diameter is often seen in patients with disorders of EGJ outflow such as achalasia or EGJ outflow obstruction (EGJOO). EGJ-DI of $<2 \text{ mm}^2/\text{mm Hg}$ is considered to be definitely abnormal, whereas EGJ diameter of $<13 \text{ mm}$ is likely abnormal and can serve as a supportive measure when EGJ-DI is indeterminate ($2\text{--}3 \text{ mm}^2/\text{mm Hg}$).¹³

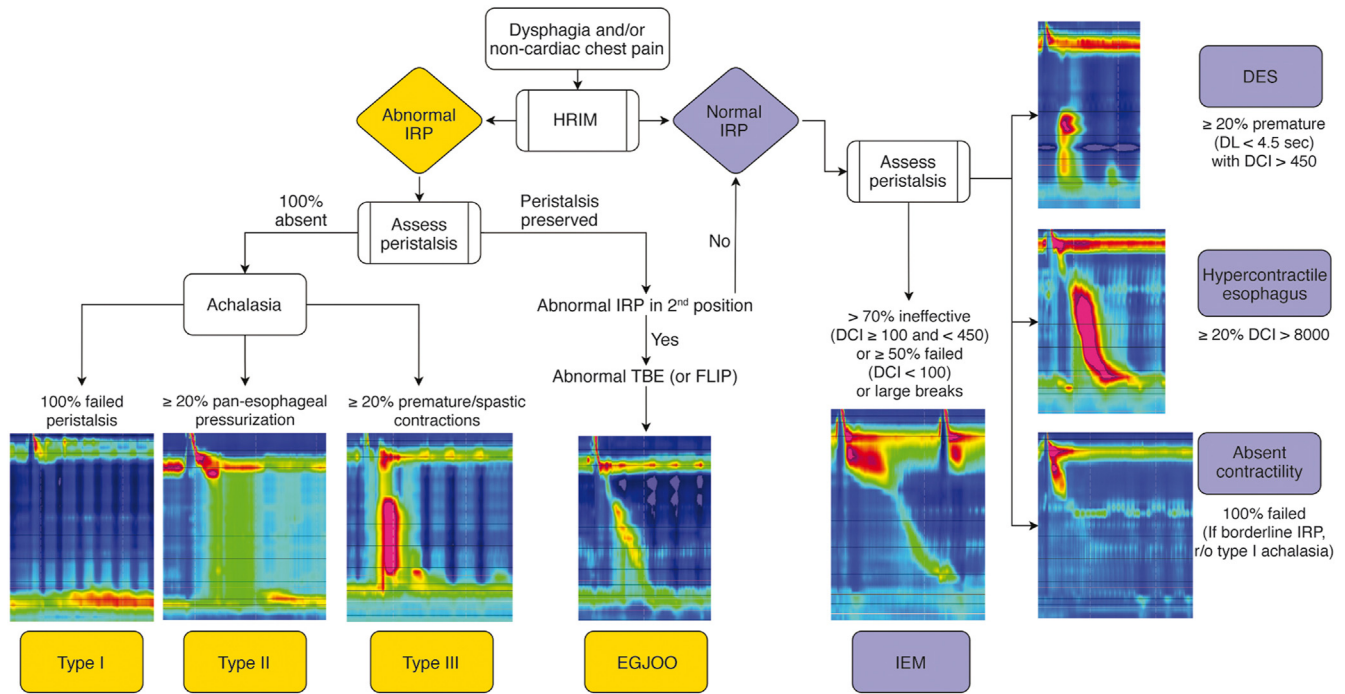


Figure 1. Manometric classification of various esophageal motility disorders based on CC v4.0. HRIM, high-resolution impedance manometry.

Although HRM remains the gold standard for motility testing, FLIP is recommended in recent guidelines as a complementary tool to HRM in instances of manometric EGJOO or other inconclusive patterns.³ FLIP has been shown to predict treatment outcomes and have a role in tailoring foregut interventions such as per-oral endoscopic myotomy (POEM) or laparoscopic Heller myotomy (LHM).^{15,16} In a study of 143 patients undergoing POEM, intraoperative use of FLIP during POEM resulted in additional real-time myotomy in 65% of cases and improved clinical outcomes compared with scenarios when intraoperative FLIP was not used.¹⁷ Studies have also identified that FLIP performs superiorly to HRM in evaluation of bolus emptying against the gold standard of barium esophagram.¹⁸ Therefore, while the role of a FLIP as a first-line tool for clinical evaluation of esophageal motility is evolving, its role as a supportive test to HRM as well as monitoring post-treatment outcomes is increasingly appreciated.

High-Resolution Esophageal Manometry

HRM is the current gold standard to assess for esophageal motor dysfunction. HRM combined with impedance sensors is recommended if available given the added ability to assess intrabolus pressure and for bolus transit in relation to manometric properties. Although commercially available HRM systems provide similar information, technological differences can influence measurements and normative values. Figure 1 depicts manometric classification of various esophageal motility disorders based on Chicago Classification version 4.0 (CC v4.0).¹⁹

HRM Protocol

The recent publication of CC v4.0 introduced a recommended HRM protocol to standardize the HRM procedure

across motility laboratories.¹⁹ Historically, HRM protocols varied with regard to patient position, number of test swallows, and inclusion of provocative maneuvers. Standardization of the protocol was needed to optimize generalizability and reliability of HRM interpretation. According to the CC v4.0 protocol, after HRM catheter placement, the study can begin in either the supine or upright position.²⁰ A minimum of 60 seconds of quiet rest allows for an adaptation period, followed by a minimum of 3 deep inspirations to confirm catheter placement, and subsequently a baseline period of at least 30 seconds to enable identification of anatomic landmarks including the upper esophageal sphincter, LES, respiratory inversion point, and basal EGJ pressure. A series of 10 5-mL single wet swallows are then performed. In equivocal cases, the patient is then transitioned from supine to upright or upright to supine position, again with a 60-second adaptation period, 3 deep inspirations, and a 30-second baseline period, followed by a series of 5 single wet swallows. The recommendation for data acquisition in both supine and upright position has been shown to increase diagnostic yield of esophageal motility disorders, as well as uncover borderline or discordant findings that require further investigation.^{21,22} Thus, unless the diagnosis is clear cut, positional changes may help in identifying any underlying motility disorders.

HRM Metrics

The key HRM metrics that help with interpretation include assessment of deglutitive relaxation across the LES using integrated relaxation pressure (IRP) and metrics of esophageal body peristalsis based on contraction vigor (distal contractile integral [DCI]) and latency of deglutitive inhibition (distal latency [DL]).

IRP. IRP assesses the adequacy of swallow-induced LES relaxation and is defined by the median 4-second nadir of EGJ pressure in the 10-second postswallow period.²³ Normal median IRP suggests adequate relaxation of the LES to deglutition and rules out disorders of EGJ. Normative values for IRP differ based on patient position and type of software system used. Median supine IRP of <15 mm Hg and upright of <12 mm Hg is considered normal for Medtronic systems.^{24–26} On the other hand, median supine IRP of <22 mm Hg and upright of <15 mm Hg is considered normal for Laborie/Diversatek systems.^{19,22,25}

DCI. DCI is a three-dimensional metric to assess the contraction vigor of esophageal smooth muscle, taking length, amplitude, and duration of contraction into consideration. It can help differentiate between normal (DCI of 450 mm Hg•s•cm–8000 mm Hg•s•cm), hypercontractile swallow (DCI >8000 mm Hg•s•cm), weak contraction (DCI 100 mm Hg•s•cm and <450 mm Hg•s•cm), and failed peristalsis (DCI <100 mm Hg•s•cm).

DL. DL measures timing of peristalsis based on the interval between upper esophageal sphincter relaxation to contractile deceleration point of the peristaltic wave in the distal esophagus. It can help differentiate between a premature (DL <4.5 seconds) vs peristaltic contraction.

Provocative maneuvers such as multiple rapid swallow (MRS) sequences in the supine position and a rapid drink challenge (RDC) in the upright position might increase diagnostic sensitivity and specificity of HRM studies. The recently updated CC v4.0 includes these maneuvers in the standardized protocol for all patients undergoing HRM study because they can provide supportive data regarding outflow obstruction across the EGJ and provide an assessment of peristaltic reserve in the setting of ineffective esophageal motility (IEM). Of note, if time and resources constrain the ability to conduct the recommended HRM protocol, clinicians can modify the protocol as long as normative values are applied and tests are used appropriately. It is important to highlight that the goal of HRM protocol is to acquire sufficient information to provide a conclusive diagnosis that explains patient symptoms and guide management. Hence, applicability of these tests should be individualized to every patient and further studies are needed to determine if universal application of these maneuvers leads to change in clinician outcomes.

MRS

During the MRS sequence, 2 mL of fluid in sequence of 5 swallows, each separated by a few seconds, is administered. An intact response to MRS is defined as absence of esophageal body contractility (DCI <100 mm Hg•s•cm) with complete deglutitive inhibition of the LES during the repetitive swallows, with an augmented post-MRS contraction. Augmentation is present if the DCI is in the normal range (ie, DCI >450 mm Hg•s•cm) and any of 3 postcontractions have increased contractile vigor compared with the mean DCI from 10 single water swallows in the same position (ratio >1). In clinical practice, this provocative test might help assess peristaltic reserve

in patients with IEM who are undergoing evaluation for anti-reflux surgery.^{27,28} The absence of an augmented contraction after MRS in esophageal studies performed is associated with increased likelihood of postoperative dysphagia in patients referred for consideration of antireflux surgery.^{28–30}

RDC

The RDC is administered, if needed, in the upright position with intake of 200 mL of water in a series of rapid water swallows without stopping. An intact response to RDC is defined as absence of esophageal body contractility (DCI <100 mm Hg•s•cm) with complete deglutitive inhibition of the LES during the RDC. When assessing response to RDC, IRP >12 mm Hg (using Medtronic software) and pan-esophageal pressurization >20 mm Hg are criteria for outflow obstruction.^{31–35} Similar to MRS, RDC is not necessary in the majority of cases, but might help in patients with suspected EGJOO and achalasia with inconclusive or discordant findings with single wet swallows. Lastly, additional manometric maneuvers such as solid test meals and postprandial high-resolution impedance manometry are currently being studied and do not currently have a routine role outside of specialized motility centers.^{21,36–38}

Barium Esophagram

Radiographic imaging with ingested barium contrast to assess bolus transport through the esophagus and into the gastric lumen has remained an important adjunctive diagnostic modality in patients with dysphagia. It can identify any structural lesions such as strictures, neoplasms, or hiatal hernia, but can also identify some major motility disorders such as achalasia and distal esophageal spasm. However, the overall sensitivity of barium esophagram for motility disorders is fairly limited, ranging from 56%–69%.^{39,40} Addition of 13-mm barium tablet to the esophagram protocol along with evaluation of esophageal emptying (timed barium esophagram [TBE]) at 1, 2, and 5 minutes can increase sensitivity and also be used to monitor treatment response in disorders of EGJOO.^{41,42} It can also show classic findings of dilated esophagus with a “bird’s beak” narrowing distally due to hypertonic LES in patients with achalasia. A barium column empties completely in most normal subjects at 1 minute and in all by 5 minutes.⁴³ Hence, barium column height of >5 cm at 1 minute and >2 cm at 5 minutes should be suggestive of EGJOO and can provide valuable complementary information in patients with manometric diagnosis of EGJOO.⁴⁴ TBE can also help with postachalasia treatment monitoring because a 3% improvement from pre- to post-treatment barium height at 5 minutes rather than absolute cutoff value of <5 cm on post-treatment TBE might be a better indicator of long-term clinical remission.⁴⁵

Disorders of EGJ Outflow

Achalasia

Achalasia represents the classic esophageal motility disorder thought to arise from a selective loss of inhibitory

neurons in the myenteric plexus of the distal esophagus and LES resulting in a neuronal imbalance with unopposed excitatory activity and localized decrease of inhibitory activity, resulting in failure of LES relaxation and disrupted esophageal peristalsis.^{46–48} Typical symptoms of achalasia include progressive dysphagia to solids and liquids, regurgitation, chest pain, heartburn, and weight loss.^{49,50} A first step in evaluation of suspected achalasia is upper gastrointestinal endoscopy to rule out mechanical source of symptoms such as esophageal strictures or pseudoachalasia. Endoscopic findings in achalasia include retained saliva with puckered gastroesophageal junction as well as esophagitis from effects of stasis and/or candidiasis. In type I or type II achalasia absence of peristalsis and/or dilation of esophageal lumen is often appreciated, and in type III achalasia an increased presence of peristalsis and/or corkscrewing of esophageal lumen is seen.⁵¹

HRM is the gold standard to diagnose and subtype achalasia. All 3 subtypes require impaired LES relaxation demonstrated by an elevated median IRP. There are 3 manometric subtypes of achalasia. Type I achalasia is considered the classic presentation of achalasia, and typically a later state of disease progression.⁵² On HRM type I achalasia is diagnosed when the median IRP across the LES is elevated and 100% of single wet swallows are failed (DCI < 100 mm Hg•s•cm), and with <20% of swallows exhibiting panesophageal pressurization. Type II achalasia is considered an earlier stage of disease and carries the most favorable prognosis to treatments.⁵³ On HRM type II achalasia is diagnosed when the median IRP is elevated, 100% of single wet swallows are failed, and 20% or more of swallows exhibit panesophageal pressurization.⁵² Type III achalasia is akin to spastic achalasia, and may reflect a different pathophysiological consequence than the other subtypes, with less evidence of progressive neuronal cell loss of the myenteric ganglion cells of the distal esophagus and LES.^{52,54} On HRM the median IRP is elevated and at least 20% of swallows are premature or spastic, defined as a DL <4.5 seconds in the setting of a DCI \geq 450 mm Hg•s•cm, with all other swallows failed.^{55,56}

At times, the HRM findings and patient symptoms may or may not align, in which case complementary tests such as TBE could serve as an important complementary diagnostic tool for achalasia, where retained barium at 1, 2, and 5 minutes after barium ingestion and bird beak are supportive of achalasia. If available, FLIP may also be another complementary diagnostic tool for achalasia, where a reduced DI and/or diameter across the EGJ is supportive of the diagnosis. Endoscopic ultrasound or cross-sectional imaging may be considered in patients with potential for pseudoachalasia, and particularly in elderly patients with a significant short-term weight loss and suspicion for achalasia.

Treatment Options

First-Line Treatment Options for Achalasia. Three first-line treatment options are available for patients with achalasia who are appropriate candidates. These include pneumatic dilation (PD), surgical LHM, and POEM.

POEM is one of the more recent therapeutic options available for patients with achalasia with very high clinical success rates of up to 90% response at 5 to 7 years.⁵⁷ Due to the ability of POEM to endoscopically extend the myotomy in the proximal esophagus and target areas of esophageal spasticity, POEM is the preferred first-line treatment option in patients with type III achalasia, with superior response rates (93%) compared with LHM (71%).⁵⁸ Overall rates of reflux esophagitis are higher in POEM (44%) compared with 29% with LHM (with partial fundoplication) at 2 years, but rates of severe esophagitis (Los Angeles Classification grade C or D) are comparable between POEM and LHM as demonstrated in a head-to-head randomized controlled trial.⁵⁹ Because POEM is not classically performed with an antireflux intervention, it is important to discuss higher potential risk of reflux with POEM and potential need for lifelong acid suppression with patients.^{51,60}

PD is performed with a nonradiopaque graded size polyethylene balloon (RigiFlex), which comes in 3 sizes (3.0, 3.5, and 4.0 cm) and are often used in graded fashion. This procedure can be performed with or without fluoroscopy.⁶¹ There is also a novel 30-mm hydrostatic balloon dilator (EsoFLIP, Medtronic, Minneapolis, MN) that is available and uses impedance planimetry to provide live real-time feedback during endoscopy on esophageal luminal diameter without the need for fluoroscopy, but use is limited due to availability of only 30-mm size balloons.⁶² PD is overall safe with risk of perforation being 1.0% with 30-mm balloon.⁶³ The risk of perforation is higher at 3.2% when a 35-mm balloon is used for initial dilation, whereas risk of perforation is lower at 0.97% when graded dilation is used with a long-term success rate of 90% at 6 months and 44% at 6 years.^{63,64} Predictors of favorable clinical response to PD include older age (>45 years), female sex, narrow (non-dilated) esophagus, and type II achalasia.⁶⁴ Hence, most patients undergoing PD should undergo initial dilation using the 30-mm balloon, followed by symptomatic and objective assessment in 4–6 weeks.⁵¹ Endoscopic visualization of the postdilation tear should be performed to rule out a perforation and patients should be monitored for any signs or symptoms in the recovery area. There is no role for routine esophagram after PD unless there is clinical suspicion for perforation.⁵¹ In those who continue to be symptomatic, graded PD with the next size dilator should be performed and/or POEM or LHM can be offered.

LHM performed with or without partial fundoplication (Dor or Toupet) also provides excellent symptom relief, with efficacy rates ranging from 88%–95% and lasting 6–10 years.^{65,66} The most common side effect after surgical myotomy is the development of gastroesophageal reflux disease (GERD) and partial fundoplication can reduce the incidence from 41.5% to 14.5%.⁶⁷ Hence, the most recent American College of Gastroenterology guidelines recommended doing either Dor or Toupet fundoplication to control esophageal acid exposure in patients with achalasia undergoing surgical myotomy.⁵¹ Predictors of favorable outcomes with LHM include younger men, tortuous esophagus, and an esophageal diverticulum. Furthermore, similar to PD, patients with type II achalasia respond better (93%)

than patients with type I (81%) or III (86%).⁶⁸ When comparing outcomes of POEM vs LHM, clinical success rates were similar at 2 years (83% with POEM compared with 81.7% with LHM), but rates of reflux esophagitis were higher in patients who underwent POEM (44%) compared with LHM with Dor fundoplication (29%).⁵⁹

Pharmacologic options. Therapeutic options for achalasia have evolved significantly over the last decade. Oral pharmacologic therapy is the least effective treatment option and currently has a minimal role in management of patients with achalasia. Two of the most common medications that have been previously studied in achalasia include calcium channel blocker (sublingual nifedipine 10–30 mg before meals)⁶⁹ and nitrates (sublingual isosorbide dinitrate 5 mg before meals).⁷⁰ However, effectiveness varies and patients often develop significant side effects including headaches, hypotension, peripheral edema, and tachyphylaxis, which results in loss of response to these medications after short-term use.^{71,72} Due to availability of significantly more effective and durable treatment options, oral pharmacologic therapy should only be considered in very few select patients with achalasia as a bridge to more effective therapy or in those for whom botulinum toxin injections were not effective and who are not candidates for any modes of myotomy.

Endoscopic botulinum toxin injection should be considered as the primary treatment option in patients who are not candidates for pneumatic dilation or myotomy due to significant comorbidities. During an upper endoscopy, 100 U of botulinum toxin is injected into the LES in 4 quadrants. Symptom relief is reported in 79% of patients at 30 days, 70% at 3 months, 53% at 6 months, and 41% at 12 months.⁶⁷ Hence, botulinum toxin can provide effective initial treatment results, but the benefit dissipates over time and nearly half of the patients might need repeat injections for symptom relief at 6 months.

Choosing the correct type of intervention. We suggest shared decision making with patients regarding treatment options available for achalasia and reviewing potential risks and benefits. Graded PD, LHM, and POEM are the first-line treatment options with all having equal efficacy for type I or type II achalasia, but POEM and LHM are both more invasive procedures with higher rates of postmyotomy GERD.⁵¹ In patients with achalasia and a medium to large hiatal hernia, LHM with partial fundoplication is preferred to correct the hiatus defect. In patients with type III achalasia, POEM is preferred over LHM due to ability to perform a tailored longer myotomy. In patients who are not candidates for either of the 3 definitive treatment options, endoscopic botulinum toxin injection is preferred. [Figure 2](#) shows the various treatment options for achalasia.

EGJOO

In the setting of nonmechanical obstructive symptoms, such as dysphagia and/or noncardiac chest pain, and absence of achalasia on HRM, a diagnosis of EGJOO should be considered in those with high IRP and normal esophageal

peristalsis. Prior iterations of the CC defined EGJOO as a median elevated IRP in the supine position with presence of preserved peristalsis in the esophageal body.⁷³ According to these criteria, the prevalence of manometric EGJOO ranged from 5%–24% of patients undergoing HRM.^{74–91} Although some of these patients may represent an incomplete or variant form of achalasia, the majority of patients with manometric EGJOO are not related to a primary functional EGJOO and this may be due to falsely elevated IRP. An estimated 21%–28% of elevated IRP cases have been attributed to structural abnormalities,^{75–78} including postoperative anatomic distortion related to fundoplication or bariatric surgery, cancer or other infiltrative processes, luminal stricture or extraluminal compression due to paraesophageal hernia (or cardiovascular compression, etc), or an artifactual increase of the IRP from the catheter effect.^{75,76,78,89} Opioid analgesics have also been associated with impaired LES relaxation resulting in functional EGJOO.^{84,92–94} The overdiagnosis of EGJOO on HRM without any clinical implications has led to concerns of unneeded treatments and was a driving reason to update the CC. Therefore, a priority in CC v4.0 was to increase the stringency of manometric criteria for EGJOO and provide context as to which clinical scenarios are relevant to EGJOO and may merit therapeutic action. As such, EGJOO is diagnosed on HRM when the median IRP is elevated in both the supine and upright positions. For instance, in patients with a small hiatal hernia or central obesity, an IRP that is elevated in the supine position normalizes in the upright position. Further, intrabolus pressurization must be present in at least 20% or more of swallows, and preserved peristalsis is present such that a diagnosis of achalasia is not met. A clinically conclusive diagnosis of EGJOO requires the presence of obstructive symptoms (dysphagia and/or noncardiac chest pain) as well as corroboration of obstructive findings on a second diagnostic study (such as TBE, preferably with a barium tablet or FLIP). Thus, a clinically conclusive diagnosis of EGJOO requires: (1) conclusive manometric diagnosis, (2) appropriate symptom presentation, and (3) confirmation of findings on supportive testing.

Treatment Options for EGJOO

Given that EGJOO may be an artifact of HRM testing, therapy should only be considered in the setting of other collaborative data. Therapeutic management of conclusive and clinically relevant EGJOO is highly variable and should be based on predominant symptom and severity of symptoms because 52%–92% of patients with mild symptoms might have spontaneous resolution.^{74,87,89} Standard endoscopic dilation might provide symptomatic relief with a pooled response rate of 69.6%, whereas botulinum toxin injection to the LES has a pooled response rate of 63.6%.⁹⁵ In a cohort of 33 patients with EGJOO, PD had response rate of 66.7% with an average follow-up of 1.7 years.⁹⁶ POEM has been evaluated in very small case series showing high symptom resolution ranging from 82%–93% with median follow-up of 195 days.^{97,98} We recommend a conservative approach with botulinum toxin injection and/or endoscopic dilation as the first option. Consideration of more aggressive

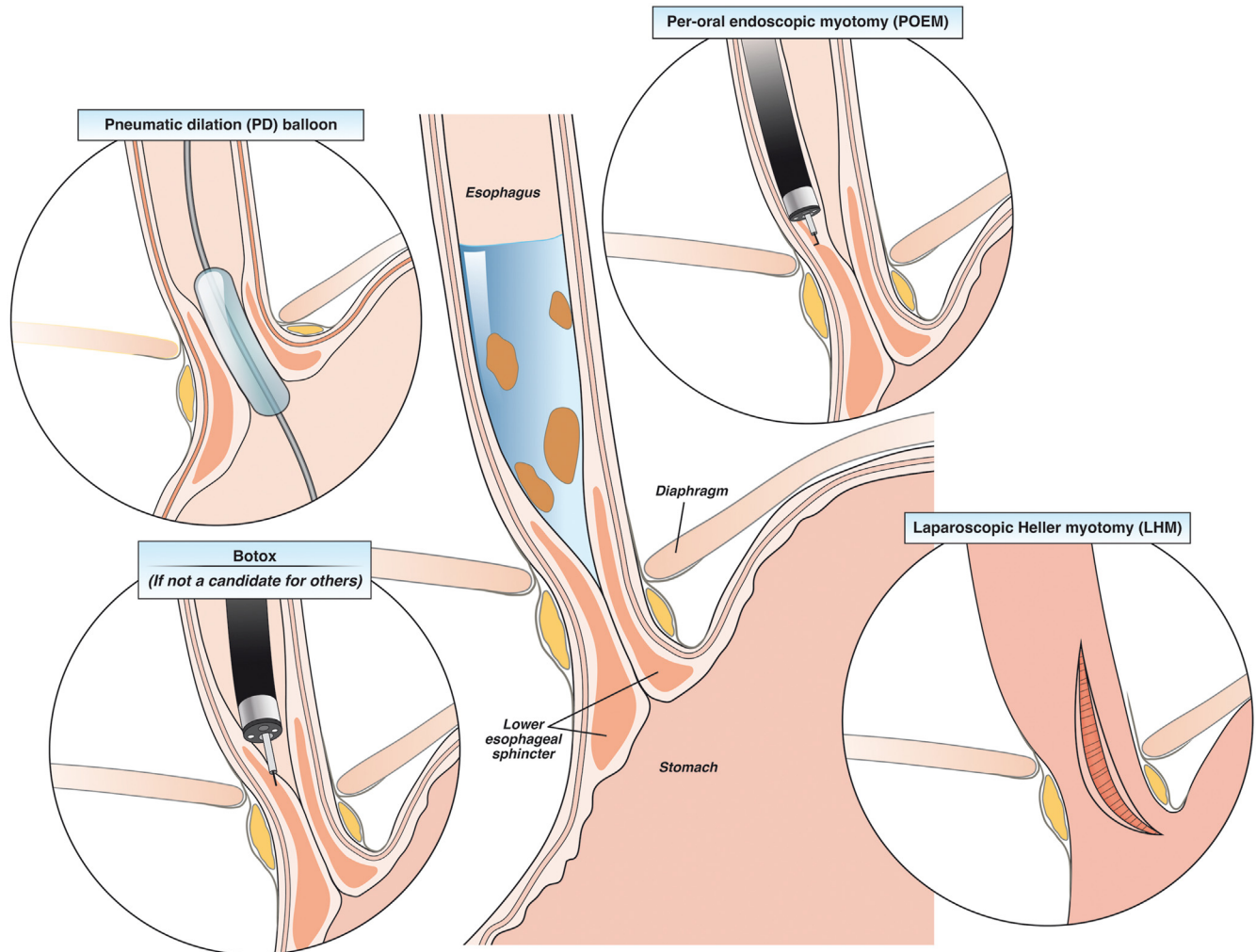


Figure 2. Treatment options in patients with achalasia.

therapy such as PD or myotomy must be based on other collaborative data as response to these therapies have only been studied in small uncontrolled studies with highly variable response rates. Hence, patients should be educated about potential risks of perforation, variable response rates, and long-term risks of reflux. In patients with noncardiac chest pain as the dominant symptom, medications (smooth muscle relaxers or tricyclic antidepressants) should be considered initially with symptom relief in 41% at 3–6 months.^{89,99} If patients have concomitant reflux symptoms (heartburn and/or regurgitation), reflux testing followed by trial of acid-suppressive therapy with proton pump inhibitors might also be effective.⁹⁵ Overall, a diagnosis of EGJOO does not always warrant therapy and treatment options should only be considered in patients with moderate to severe symptoms.

Disorders of Esophageal Peristalsis

Spastic Motor Disorders

Disordered esophageal motor function can be due to hyperactivity such that peristalsis is premature or contractile vigor is increased. Primary symptoms of such spastic

esophageal motor disorders include dysphagia and noncardiac chest pain and are often accompanied by heartburn and regurgitation. On HRM 2 groups of spastic esophageal disorders include distal esophageal spasm (DES) and hypercontractile esophagus.¹⁰⁰ In the recent CC v4.0 update the manometric criteria for both DES and hypercontractile esophagus remain unchanged, however, clinically conclusive diagnoses of DES and hypercontractile esophagus require the presence of clinically relevant obstructive symptoms (dysphagia and/or noncardiac chest pain).

DES

DES is characterized by premature contractions in 20% or more of swallows on manometry in the setting of intact deglutitive relaxation (normal median IRP) (Figure 1). Premature contractions are defined by a distal latency of <4.5 seconds in the setting of a DCI of 450 mm Hg•s•cm or greater.¹⁰¹ The greater the number of premature swallows on HRM, the greater the confidence in the DES diagnosis. A manometric diagnosis of DES can be supported by lack of peristaltic inhibition during MRS or abnormal contractions

with stress of a bolus load. Importantly, true primary DES is rare, and when identified is considered along the spectrum of type III achalasia. TBE can be very helpful as supportive testing in this group of patients because it can identify tertiary contractions, rosary bead, or corkscrew esophagus associated with DES. Retention of barium during TBE is an important distinction between DES and achalasia diagnosis.

Hypercontractile Esophagus

Hypercontractile esophagus is defined on HRM by 20% or more swallows with hypercontractility (DCI >8000 mm Hg•s•cm) with a normal IRP (Figure 1). The term “jackhammer esophagus” is no longer synonymous with hypercontractile esophagus.¹⁰² To make a conclusive manometric diagnosis of hypercontractile esophagus, criteria for achalasia and DES must not be met and underlying EGJOO excluded. Supportive findings for manometric hypercontractile esophagus include intrabolus pressurization, abnormal patterns with RDC, or absence of peristaltic reserve on MRS.¹⁰² A multitude of manometric patterns can meet criteria for hypercontractile esophagus, more commonly single peak hypercontractile peristalsis over jackhammer esophagus with repetitive prolonged contractions, the latter considered to portend greater pathologic significance. Recently, a new entity has been described involving LES hypercontraction and, along with these other phenotypes, is under active investigation.¹⁰²

Treatment of Spastic Disorders

Spastic esophageal disorders can be due to a primary motor dysfunction, opioid-induced, or a reactive clearance mechanism to gastroesophageal refluxate. Evaluation for underlying reflux should be the initial step in determining best treatment option for patients with symptomatic spastic disorders of the esophageal body (Figure 3). In 1 study of 108 patients with DES, 34% of patients had pathologic acid exposure on pH testing or endoscopy.¹⁰³ When gastroesophageal reflux is driving the spasticity, treatment should focus on antireflux management because antispasmodic therapy has the potential to augment gastroesophageal reflux physiology and worsen symptoms. In patients with heartburn and/or regurgitation, a regimen of proton pump inhibitor for 6–8 weeks can be trialed and/or ambulatory reflux monitoring off acid suppression can be pursued. Furthermore, careful inspection for any esophageal strictures should also be performed during endoscopy and empirical esophageal dilation can be considered as a treatment modality given spastic contractions of esophageal body can also be a result of a subtle distal esophageal stricture. In most patients with mild symptoms, monitoring is also a reasonable alternative given that these disorders do tend to have a benign long-term course with 1 study looking at natural history over 3–10 years showing that symptoms of dysphagia and noncardiac chest pain improved significantly over time.¹⁰⁴

Pharmacotherapy. In patients with a spastic esophageal disorder and dysphagia and noncardiac chest pain, smooth muscle relaxants can be trialed such as calcium

channel blockers,¹⁰⁵ nitrates,¹⁰⁶ and phosphodiesterase-5 inhibitors,¹⁰⁷ but their use may be limited due to side effects (headaches, hypotension, and dizziness). Some of the authors prefer a trial of sublingual hyoscyamine 30 minutes before meals based on anecdotal successes and ease of availability and favorable side effect profile, but this has not been studied for spastic disorders. In patients with dysphagia as the predominant symptom and lack of response to esophageal dilation or smooth muscle relaxant, esophageal botulinum toxin injection at the LES, 2 cm, and 7 cm above the LES might result in symptom improvement in 50% of patients at 1 month and 30% at 1 year.¹⁰⁸ Although botulinum toxin injection can be offered to patients with noncardiac chest pain as the predominant symptom without dysphagia, limited open label studies suggest that the improvement might be transient and only last for 6 months.^{109,110} In patients with chest pain as the predominant symptom with suspicion of overlapping visceral hypersensitivity, neuromodulation with low-dose tricyclic antidepressants (imipramine or amitriptyline) or trazodone may be more effective than targeting the esophageal dysmotility.^{111,112} Table 2 shows a list of smooth muscle relaxers and neuromodulators with level of evidence, dosage, side effects, and potential special considerations that might allow clinicians to personalize selection based on patient profile and concomitant symptoms. However, it should be noted that most of the data is from patients with noncardiac chest pain and the level of evidence is limited by very small sample sized studies.

Myotomy. In patients who fail pharmacotherapy, we recommend performing a TBE and/or FLIP to evaluate esophageal emptying and see if there is significant retention of barium or obstruction at the EGJ. If consistent with an obstructive physiology, myotomy might be considered. In a meta-analysis of 8 observational studies (total of 18 patients with DES and 37 with jackhammer esophagus), POEM had clinical success rates of 88% and 72%, respectively.¹¹³ Another retrospective study involving 11 centers that included 17 patients with DES and 18 with jackhammer esophagus found that POEM improved chest pain in 87% with clinical success (based on Eckardt score) of 84.9% with median follow-up of 272 days.⁹⁸ Surgical myotomy has also been studied in a small prospective study of 20 patients with extended myotomy for DES and found that both dysphagia and chest pain improved in 100% and 90%, respectively, during a 50-month follow-up.¹¹⁴ Due to lack of well-controlled long-term randomized controlled trials, myotomy for treatment of spastic esophageal body disorders should be reserved for highly selected patients because long-term prognosis even without treatment seems to be good for these disorders.

Hypomotility Disorders

IEM

Manometric diagnosis of IEM has evolved over time and now require more than 70% ineffective swallows (DCI ≥ 100 mm Hg•s•cm and < 450 mm Hg•s•cm) or at least 50% failed peristalsis (DCI < 100 mm Hg•s•cm)

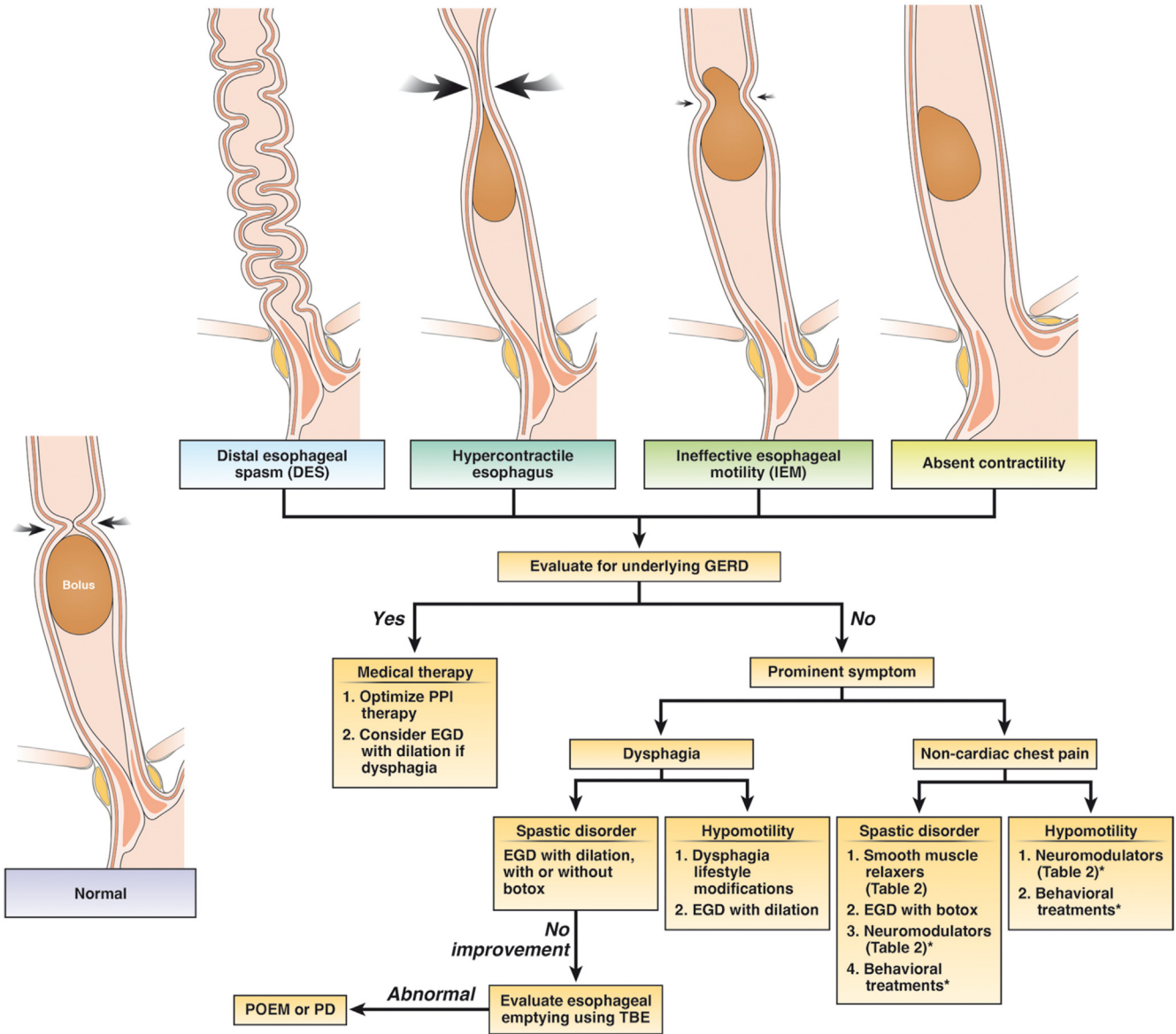


Figure 3. Treatment options in patients with disorders of esophageal peristalsis after a careful endoscopy is performed to rule out a mechanical or mucosal disease (such as eosinophilic esophagitis). *In patients with chest pain as the primary symptom, overlapping esophageal hypersensitivity might play a major role in symptom generation and neuromodulators or behavioral treatments might be beneficial based on studies on noncardiac chest pain.

(Figure 1).¹⁹ Clinical relevance of IEM has been under debate¹¹⁵ because several studies have shown no correlation between IEM and esophageal symptoms,^{116,117} but it has been associated with higher esophageal reflux burden.

Findings of IEM might affect decision making before antireflux surgery due to risk of postoperative dysphagia, although some studies show similar outcomes after a partial (Dor or Toupet) or Nissen fundoplication.^{118–121} Provocative maneuvers such as MRS might identify contractile reserve in this group of patients and predict risk of postoperative dysphagia with sensitivity and specificity of 67% and 64%, respectively.²⁸ Hence, presence of IEM and findings on MRS might alter the type of fundoplication offered to the patient. Minimum of 3 MRS sequences should be performed to demonstrate adequate contraction reserve.¹²²

Contrary to surgical fundoplication, it should be noted that IEM is a relative contraindication for magnetic sphincter augmentation because esophageal peristalsis is necessary to distend the magnetic band and allow the bolus to enter the stomach.^{123,124}

Absent Contractility

Absent contractility is defined as 100% failed peristalsis (DCI <100 mm Hg•s•cm) with a normal median IRP in the supine and upright position (Figure 1).¹⁹ This is also commonly characterized in clinical practice as “scleroderma-like esophagus” due to higher prevalence in patients with connective tissue disease. However, if dysphagia is a prominent symptom and manometric evaluation shows a borderline median IRP in supine position of 10 mm Hg–15

Table 2. Smooth Muscle Relaxers and Neuromodulators That Might Be Used in Patients With Disorder of Esophageal Peristalsis and NCCP as the Primary Symptom

		Dosage	Level of evidence	Side effects	Special considerations
Smooth muscle relaxers	Peppermint oil	5 drops in 10 mL of water (or 2 Altoid mints sublingual before every meal)	Case series ¹⁴⁷	Might worsen reflux symptoms	Decreases simultaneous contractions and amplitude, but less effect on pain
	Calcium channel blockers	Diltiazem 60–90 mg 4 times a day Nifedipine 10 mg 30 min before meals	RCT in nutcracker esophagus ¹⁰⁵	Hypotension, peripheral edema, headaches, dizziness, and tachyphylaxis	Improves chest pain and decreases esophageal amplitude
	Phosphodiesterase-5 inhibitor	Sildenafil 25–50 mg twice a day	RCT in spastic motor disorder ¹⁴⁸	Headache, hypotension, and dizziness	Might improve manometric findings, but less effect on symptoms
TCA	Imipramine Amitriptyline	50 mg daily 10–25 mg at night	RCT for NCCP ^{111,149} RCT for NCCP ¹⁵⁰	QT prolongation, dry mouth, excessive sleeping, dizziness, and constipation	Might use nortriptyline (less anticholinergic effects in hypomotility disorder and NCCP)
SNRI	Venlafaxine	75 mg daily	RCT for NCCP ¹⁵¹	Sleep disturbances, nausea, hypertension	Less constipation compared with TCA, but similar pain relief
SSRI	Sertraline	50–200 mg daily	RCT for NCCP ^{152,153}	Nausea, restlessness, dry mouth, diarrhea	Might be beneficial if concomitant anxiety disorder or symptom hypervigilance
	Paroxetine	10–50 mg daily	RCT for NCCP ¹⁵⁴		More drug-drug interactions due to inhibition of P450 isoenzymes Short half-life, risk of discontinuation syndrome if stopped abruptly Fluoxetine preferred in patients who may miss doses (due to longer half-life)
Miscellaneous	Trazadone	100–150 mg daily	RCT in spastic motor disorder ¹¹²	Nausea, dizziness, and drowsiness	Less effect on manometric abnormalities, but significant improvement in chest pain

Smooth muscle relaxers should only be used in patients with DES or hypercontractile esophagus. NCCP, noncardiac chest pain; RCT, randomized controlled trial; SNRI, serotonin-norepinephrine re-uptake inhibitor; SSRI, selective serotonin reuptake inhibitor; TCAs, tricyclic antidepressants.

mm Hg (using the Medtronic software), type I achalasia should be considered in the differential. In this setting, correlating the manometric findings with TBE, FLIP, or endoscopy to ensure that LES is open is essential in avoiding misdiagnosis.

Treatment of Hypomotility Disorders

Management of IEM and absent contractility is very challenging given lack of clear association with symptoms. Given there is no effective pharmacotherapy to improve esophageal contractile vigor, management should be focused toward improving predominant symptoms and treating any concurrent reflux if present (Figure 3). In patients with dysphagia as the predominant symptom, endoscopy to evaluate for a mechanical stricture (such as Schatzki's ring or peptic stricture) should be performed and, even in cases of normal examination, empiric esophageal dilation might be considered in this group due to lack of other reliable options. Lifestyle modifications, such as chewing carefully, maintaining positional gravity, and chasing solid bolus with liquids, can be helpful. Newer agents such as prucalopride may increase the amplitude of primary esophageal contractions in patients with GERD¹²⁵ and might have a role in patients with either concomitant gastroparesis or chronic idiopathic constipation, although is not a primary treatment option for esophageal hypomotility. Buspirone, a mixed dopamine D2 receptor antagonist and partial 5HT-1A agonist, has been shown to increase esophageal contraction amplitude in patients with scleroderma,^{126,127} but was not better than placebo in a small placebo-controlled crossover trial of 10 patients with IEM in improving dysphagia.¹²⁸ Overall, it is important to recognize that, in most cases, natural history of IEM suggests that it does not progress over time and quality of life is not impacted.¹²⁹ In patients with chest pain as the primary symptom, esophageal hypersensitivity might be the major driving factor and neuromodulators or behavioral therapies might be beneficial based on studies in patients with noncardiac chest pain (Table 2).

Impact of Esophageal Mucosal Disease, Systemic Disease, and Medications on Motility

Recent advances in diagnostics have improved our knowledge on how various inflammatory esophageal disorders, rheumatologic disorders, and medications cause secondary motility abnormalities (Figure 4). Previously, GERD has been commonly associated with both hypomotility and spastic disorders of the esophageal body, but recent studies show that certain phenotypes of other disorders such as eosinophilic esophagitis (EoE) might also affect motility. Hence, careful endoscopic examination and clinical history are paramount in distinguishing primary (idiopathic) motility disorders from secondary diseases, which can significantly alter treatment options and long-term clinical outcomes.

EoE

One study of 109 patients with EoE found that 38% of the cohort had abnormal findings on HRM with the majority (59%) of those being minor disorders (23 with IEM, 1 with fragmented peristalsis), but 41% had major motor disorders (8 with achalasia, 1 DES, 2 jackhammer esophagus, 5 EGJOO, and 1 absent contractility).¹³⁰ Another study with 20 symptomatic EoE patients evaluated manometric changes before and after 8 weeks of topical steroid treatment with budesonide. They found that minor motility abnormalities of early pan-esophageal pressurizations and weak peristalsis were found in 35% of patients, but 86% of them had resolution of the abnormalities after budesonide therapy and achieving histologic remission.¹³¹ Hence, eosinophils might cause reversible esophageal motility disturbances, but presence of mucosal eosinophilia in major motility disorder such as achalasia might need to be interpreted with caution because this can also be seen as a consequence of prolonged esophageal stasis of retained food/saliva that causes mucosal irritation.

Connective Tissue Disorders

Sjogren's syndrome and systemic sclerosis are the 2 most common connective tissue disorders associated with esophageal motility disorders. Dysphagia is a common symptom reported by 26%–65% of patients with these disorders.^{132,133} Most common manometric findings include hypotensive LES pressure along with esophageal dysmotility with up to 68.5% with systemic sclerosis having absent contractility and 35% of patients with Sjogren's syndrome having dysmotility.^{133–135} However, it should be noted that severity of dysphagia in this population has not been associated with any specific motility pattern.¹³⁶ Furthermore, there is also a high incidence of reflux symptoms and erosive esophagitis in up to 32% of patients, which is also associated with hypomotility disorders.¹³⁷ Thus, management of esophageal dysmotility in patients with connective tissue disorders should be focused toward optimization of reflux management (acid-suppressive therapy) and potential consideration of esophageal dilation in patients with dysphagia because they are at higher risk of developing peptic stricture.

Opioid-Induced Esophageal Dysfunction

Opioid medications have recently been associated with spastic disorders of the esophagus. In a recent retrospective study of 2342 patients (224 on chronic daily opioids), 62% of patients on opioids reported dysphagia and they were also more likely to have the following manometric abnormalities: type III achalasia (13% vs 1%; $P < .01$), EGJOO (13% vs 3%; $P < .01$), and DES (3% vs 0.5%; $P < .01$).¹³⁸ Given there is no gold standard test to determine idiopathic vs medication effect on esophageal motility, withdrawing the opioid if feasible and repeating the manometry study are ideal to see if the abnormality resolves.¹³⁹ Provocative testing evaluating amyl nitrate-induced rebound contraction of the LES and paradoxical esophageal contraction during the first phase of cholecystokinin

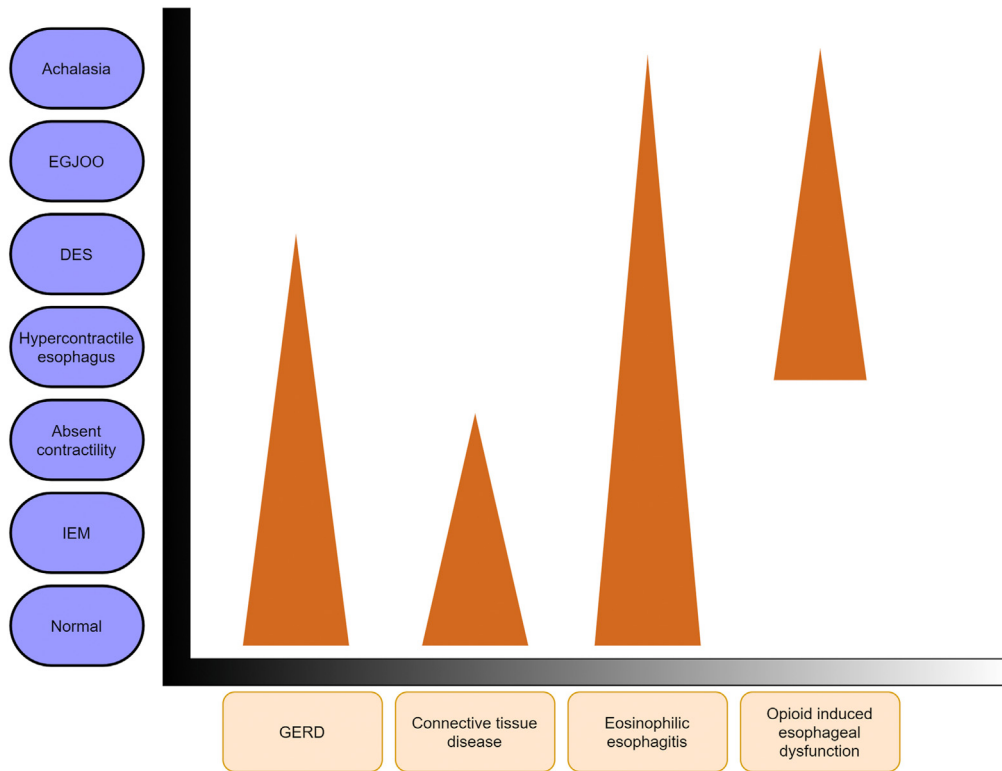


Figure 4. Impact of mucosal diseases, opioids, and connective tissue disease on esophageal motility. Figure shows presence of various secondary motility abnormalities, and the *triangle* indicates visual approximations of the prevalence of those motility abnormalities with each disease state. Most patients will have normal motility testing. For instance, in opioid-induced esophageal dysfunction, there is higher prevalence of hypercontractile esophagus and distal esophageal compared with achalasia. On the other hand, the majority of patients with GERD will have normal esophageal motility followed by hypomotility disorders and lower prevalence of DES.

response might be able to differentiate opioid effect from idiopathic type III achalasia.¹⁴⁰ However, these are available in only a few centers across the United States. Given that opioid-induced esophageal dysfunction has just been recently described with very few studies in the literature, there is currently a lack of evidence on optimal management strategy.¹⁴¹ Given that withdrawal of opioids might reverse the motility abnormality, invasive treatment options such as POEM or surgical myotomy should be reserved in highly selected cases given the lack of data on long-term outcomes. If opioid withdrawal is not an option, consideration should be made toward changing to a partial agonist because they are not associated with motility abnormalities.⁹⁴ If symptoms persist, we prefer to use endoscopic dilation with botulinum toxin injection targeting spasticity of the esophagus as the next step before proceeding with myotomy interventions that have higher risks.¹⁴¹

Postsurgical Esophageal Motility Disorders

Fundoplication

Postoperative dysphagia after antireflux surgery is present in 6%–26% of patients.^{26,142} Esophageal dysmotility can be found in up to 7% of patients after Nissen fundoplication with the majority having nonspecific motility abnormalities followed by secondary achalasia and DES.¹⁴³ Evaluation should include esophagogastroduodenoscopy, with FLIP if available, to assess the fundoplication wrap and barium esophagram to evaluate esophageal emptying. Symptom of dysphagia in most of these patients is

generated due to inability of the esophageal propulsive force to distend the wrap for bolus transport into the stomach. Lack of contraction reserve on MRS has been independently associated with late postfundoplication dysphagia.³⁰ Studies show that conventional endoscopic dilation of the wrap leads to symptom resolution in the majority of these patients with very few needing wrap takedown.^{26,30,142} In patients with lack of response to conventional esophageal dilation (up to 20 mm), PD can be considered in patients with abnormal esophageal emptying, but might not be effective in patients with dysphagia and no signs of obstruction from the wrap.^{144,145}

Bariatric Surgery

The rising incidence of obesity and use of bariatric surgery has brought the impact of altered foregut anatomy on esophageal motility to the forefront of clinical care. Dysphagia has been reported in 51% of patients after laparoscopic sleeve gastrectomy and 46% of patients after Roux-en-Y gastric bypass.¹⁴⁶ In a recent study of 97 patients who underwent high resolution impedance manometry (HRIM) after bariatric surgery, 61.5% had manometric abnormalities per CC v3.0 with 29.9% of them being major motility disorders (achalasia, EGJOO, DES, and jackhammer).¹⁴⁶ The remaining had ineffective esophageal motility. They also found that 5.2% had a unique achalasia-like pattern defined by aperistalsis and increased intragastric pressure, which was defined as postobesity surgery esophageal dysfunction. Hence, secondary esophageal dysmotility may be an under-recognized complication of bariatric surgery because up to 13.7% of patients continued to

have dysphagia at a mean of 3.9 years after surgery.¹⁴⁶ Treatment in this group of patients should be focused toward assessment of the gastric pouch, sleeve, and/or anastomosis and improving any source of mechanical or functional outflow obstruction.

Conclusion

Significant advances have been made during the last 3 decades in our understanding of various esophageal motility disorders due to improvement in diagnostics with high-resolution esophageal manometry. Barium esophagram and possibly FLIP may serve as complementary tools in assessment of patients with suspected motility disorders, but ultimately it is the overall clinical picture along with diagnostic tests that complete the clinical assessment for patients. Achalasia remains as the most-studied motility disorder with highly effective therapeutic options for palliation of symptoms. However, there has been a lack of advancement in studying therapeutics for nonachalasia motility disorders, which should be a priority for the next decade.

References

1. Delshad SD, Almario CV, Chey WD, et al. Prevalence of gastroesophageal reflux disease and proton pump inhibitor-refractory symptoms. *Gastroenterology* 2020; 158:1250–1261.e2.
2. Adkins C, Takakura W, Spiegel BMR, et al. Prevalence and characteristics of dysphagia based on a population-based survey. *Clin Gastroenterol Hepatol* 2020; 18:1970–1979.e2.
3. Gyawali CP, Carlson DA, Chen JW, et al. ACG Clinical Guidelines: Clinical Use of Esophageal Physiologic Testing. *Am J Gastroenterol* 2020;115:1412–1428.
4. Pandolfino JE, Roman S, Carlson D, et al. Distal esophageal spasm in high-resolution esophageal pressure topography: defining clinical phenotypes. *Gastroenterology* 2011;141:469–475.
5. Pandolfino JE, Ghosh SK, Rice J, et al. Classifying esophageal motility by pressure topography characteristics: a study of 400 patients and 75 controls. *Am J Gastroenterol* 2008;103:27–37.
6. Virani SS, Alonso A, Benjamin EJ, et al. Heart Disease and Stroke Statistics-2020 Update: A Report From the American Heart Association. *Circulation* 2020; 141:e139–e596.
7. Arndorfer RC, Stef JJ, Dodds WJ, et al. Improved infusion system for intraluminal esophageal manometry. *Gastroenterology* 1977;73:23–27.
8. Clouse RE, Staiano A. Topography of the esophageal peristaltic pressure wave. *Am J Physiol* 1991; 261:G677–G684.
9. Clouse RE, Staiano A, Alrakawi A, et al. Application of topographical methods to clinical esophageal manometry. *Am J Gastroenterol* 2000;95:2720–2730.
10. Minami H, Isomoto H, Miuma S, et al. New endoscopic indicator of esophageal achalasia: “pinstripe pattern”. *PLoS One* 2015;10:e0101833.
11. Hirano I, Pandolfino JE, Boeckxstaens GE. Functional lumen imaging probe for the management of esophageal disorders: expert review from the Clinical Practice Updates Committee of the AGA Institute. *Clin Gastroenterol Hepatol* 2017;15:325–334.
12. Carlson DA, Lin Z, Kahrilas PJ, et al. High-resolution impedance manometry metrics of the esophagogastric junction for the assessment of treatment response in achalasia. *Am J Gastroenterol* 2016;111:1702–1710.
13. Savarino E, di Pietro M, Bredenoord AJ, et al. Use of the functional lumen imaging probe in clinical esophagology. *Am J Gastroenterol* 2020;115:1786–1796.
14. Carlson DA, Kou W, Masihi M, et al. Repetitive antegrade contractions: a novel response to sustained esophageal distension is modulated by cholinergic influence. *Am J Physiol Gastrointest Liver Physiol* 2020; 319:G696–G702.
15. Attaar M, Su B, Wong HJ, et al. Intraoperative impedance planimetry (EndoFLIP) results and development of esophagitis in patients undergoing peroral endoscopic myotomy (POEM). *Surg Endosc* 2021;35:4555–4562.
16. Su B, Callahan ZM, Novak S, et al. Using impedance planimetry (EndoFLIP) to evaluate myotomy and predict outcomes after surgery for achalasia. *J Gastrointest Surg* 2020;24:964–971.
17. Holmstrom AL, Campagna RAJ, Cirera A, et al. Intraoperative use of FLIP is associated with clinical success following POEM for achalasia. *Surg Endosc* 2021; 35:3090–3096.
18. Jain AS, Carlson DA, Triggs J, et al. Esophagogastric junction distensibility on functional lumen imaging probe topography predicts treatment response in achalasia-anatomy matters. *Am J Gastroenterol* 2019; 114:1455–1463.
19. Yadlapati R, Kahrilas PJ, Fox MR, et al. Esophageal motility disorders on high-resolution manometry: Chicago classification version 4.0((c)). *Neurogastroenterol Motil* 2021;33:e14058.
20. Fox MR, Sweis R, Yadlapati R, et al. Chicago classification version 4.0((c)) technical review: update on standard high-resolution manometry protocol for the assessment of esophageal motility. *Neurogastroenterol Motil* 2021;33:e14120.
21. Misselwitz B, Hollenstein M, Butikofer S, et al. Prospective serial diagnostic study: the effects of position and provocative tests on the diagnosis of oesophageal motility disorders by high-resolution manometry. *Aliment Pharmacol Ther* 2020;51:706–718.
22. Triggs JR, Carlson DA, Beveridge C, et al. Upright integrated relaxation pressure facilitates characterization of esophagogastric junction outflow obstruction. *Clin Gastroenterol Hepatol* 2019;17:2218–2226.e2.
23. Ghosh SK, Pandolfino JE, Rice J, et al. Impaired deglutitive EGJ relaxation in clinical esophageal manometry: a quantitative analysis of 400 patients and 75 controls. *Am J Physiol Gastrointest Liver Physiol* 2007;293:G878–G885.
24. Herregods TV, Roman S, Kahrilas PJ, et al. Normative values in esophageal high-resolution manometry. *Neurogastroenterol Motil* 2015;27:175–187.

25. Rengarajan A, Rogers BD, Wong Z, et al. High-resolution manometry thresholds and motor patterns among asymptomatic individuals. *Clin Gastroenterol Hepatol* 2020;20:e398–e406.
26. Athanasiadis DI, Selzer D, Stefanidis D, et al. Post-operative dysphagia following esophagogastric fundoplication: does the timing to first dilation matter? *J Gastrointest Surg* 2021;25:2750–2756.
27. Elvevi A, Mauro A, Pugliese D, et al. Usefulness of low- and high-volume multiple rapid swallowing during high-resolution manometry. *Dig Liver Dis* 2015;47:103–107.
28. Shaker A, Stoikes N, Drapekin J, et al. Multiple rapid swallow responses during esophageal high-resolution manometry reflect esophageal body peristaltic reserve. *Am J Gastroenterol* 2013;108:1706–1712.
29. Stoikes N, Drapekin J, Kushnir V, et al. The value of multiple rapid swallows during preoperative esophageal manometry before laparoscopic antireflux surgery. *Surg Endosc* 2012;26:3401–3407.
30. Hasak S, Brunt LM, Wang D, et al. Clinical characteristics and outcomes of patients with postfundoplication dysphagia. *Clin Gastroenterol Hepatol* 2019;17:1982–1990.
31. Ang D, Hollenstein M, Misselwitz B, et al. Rapid drink challenge in high-resolution manometry: an adjunctive test for detection of esophageal motility disorders. *Neurogastroenterol Motil* 2017;29:e12902.
32. Woodland P, Gabieta-Sonmez S, Arguero J, et al. 200 mL rapid drink challenge during high-resolution manometry best predicts objective esophagogastric junction obstruction and correlates with symptom severity. *J Neurogastroenterol Motil* 2018;24:410–414.
33. Marin I, Serra J. Patterns of esophageal pressure responses to a rapid drink challenge test in patients with esophageal motility disorders. *Neurogastroenterol Motil* 2016;28:543–553.
34. Krause AJ, Su H, Triggs JR, et al. Multiple rapid swallows and rapid drink challenge in patients with esophagogastric junction outflow obstruction on high-resolution manometry. *Neurogastroenterol Motil* 2020;33:e14000.
35. Sanagapalli S, McGuire J, Leong R, et al. The clinical relevance of manometric esophagogastric junction outflow obstruction can be determined using rapid drink challenge and solid swallows. *Am J Gastroenterol* 2020;116:280–288.
36. Wang YT, Tai LF, Yazaki E, et al. Investigation of dysphagia after antireflux surgery by high-resolution manometry: impact of multiple water swallows and a solid test meal on diagnosis, management, and clinical outcome. *Clin Gastroenterol Hepatol* 2015;13:1575–1583.
37. Ang D, Misselwitz B, Hollenstein M, et al. Diagnostic yield of high-resolution manometry with a solid test meal for clinically relevant, symptomatic oesophageal motility disorders: serial diagnostic study. *Lancet Gastroenterol Hepatol* 2017;2:654–661.
38. Fox M, Hebbard G, Janiak P, et al. High-resolution manometry predicts the success of oesophageal bolus transport and identifies clinically important abnormalities not detected by conventional manometry. *Neurogastroenterol Motil* 2004;16:533–542.
39. Ott DJ, Richter JE, Chen YM, et al. Esophageal radiography and manometry: correlation in 172 patients with dysphagia. *AJR Am J Roentgenol* 1987;149:307–311.
40. O'Rourke AK, Lazar A, Murphy B, et al. Utility of esophagram versus high-resolution manometry in the detection of esophageal dysmotility. *Otolaryngol Head Neck Surg* 2016;154:888–891.
41. Neyaz Z, Gupta M, Ghoshal UC. How to perform and interpret timed barium esophagogram. *J Neurogastroenterol Motil* 2013;19:251–256.
42. Vaezi MF, Baker ME, Achkar E, et al. Timed barium oesophagram: better predictor of long term success after pneumatic dilation in achalasia than symptom assessment. *Gut* 2002;50:765–770.
43. Vaezi MF, Baker ME, Richter JE. Assessment of esophageal emptying post-pneumatic dilation: use of the timed barium esophagram. *Am J Gastroenterol* 1999;94:1802–1807.
44. Blonski W, Kumar A, Feldman J, et al. Timed barium swallow: diagnostic role and predictive value in untreated achalasia, esophagogastric junction outflow obstruction, and non-achalasia dysphagia. *Am J Gastroenterol* 2018;113:196–203.
45. Blonski W, Kumar A, Feldman J, et al. Timed barium swallow for assessing long-term treatment response in patients with achalasia: absolute cutoff versus percent change - a cross-sectional analytic study. *Neurogastroenterol Motil* 2021;33:e14005.
46. Singaram C, Sengupta A, Sweet MA, et al. Nitrinergic and peptidergic innervation of the human oesophagus. *Gut* 1994;35:1690–1696.
47. Park W, Vaezi MF. Etiology and pathogenesis of achalasia: the current understanding. *Am J Gastroenterol* 2005;100:1404–1414.
48. Mearin F, Mourelle M, Guarner F, et al. Patients with achalasia lack nitric oxide synthase in the gastro-oesophageal junction. *Eur J Clin Invest* 1993;23:724–728.
49. Vaezi MF, Pandolfino JE, Vela MF. ACG clinical guideline: diagnosis and management of achalasia. *Am J Gastroenterol* 2013;108:1238–1249; quiz 1250.
50. Francis DL, Katzka DA. Achalasia: update on the disease and its treatment. *Gastroenterology* 2010;139:369–374.
51. Vaezi MF, Pandolfino JE, Yadlapati RH, et al. ACG Clinical Guidelines: Diagnosis and Management of Achalasia. *Am J Gastroenterol* 2020;115:1393–1411.
52. Pandolfino JE, Gawron AJ. Achalasia: a systematic review. *JAMA* 2015;313:1841–1852.
53. Zhou MJ, Kamal A, Freedberg DE, et al. Type II achalasia is increasing in prevalence. *Dig Dis Sci* 2020;66:3490–3494.
54. Rieder E, Fernandez-Becker NQ, Sarosiek J, et al. Achalasia: physiology and diagnosis. *Ann N Y Acad Sci* 2020;1482:85–94.
55. Kim TH, Patel N, Ledgerwood-Lee M, et al. Esophageal contractions in type 3 achalasia esophagus: simultaneous or peristaltic? *Am J Physiol Gastrointest Liver Physiol* 2016;310:G689–G695.

56. Park S, Zifan A, Kumar D, et al. Genesis of esophageal pressurization and bolus flow patterns in patients with achalasia esophagus. *Gastroenterology* 2018; 155:327–336.
57. Modayil RJ, Zhang X, Rothberg B, et al. Peroral endoscopic myotomy: 10-year outcomes from a large, single-center U.S. series with high follow-up completion and comprehensive analysis of long-term efficacy, safety, objective GERD, and endoscopic functional luminal assessment. *Gastrointest Endosc* 2021;94:930–942.
58. Andolfi C, Fisichella PM. Meta-analysis of clinical outcome after treatment for achalasia based on manometric subtypes. *Br J Surg* 2019;106:332–341.
59. Werner YB, Hakanson B, Martinek J, et al. Endoscopic or surgical myotomy in patients with idiopathic achalasia. *N Engl J Med* 2019;381:2219–2229.
60. Kahrilas PJ, Katzka D, Richter JE. Clinical practice update: the use of per-oral endoscopic myotomy in achalasia: expert review and best practice advice from the AGA Institute. *Gastroenterology* 2017;153:1205–1211.
61. Patel DA, Vaezi MF. Bringing real-time live feedback to esophageal dilations, but not ready for prime time. *Gastrointest Endosc* 2020;92:1258–1260.
62. Sloan JA, Triggs JR, Pandolfino JE, et al. Treatment experience with a novel 30-mm hydrostatic balloon in esophageal dysmotility: a multicenter retrospective analysis. *Gastrointest Endosc* 2020;92:1251–1257.
63. van Hoeij FB, Prins LI, Smout A, et al. Efficacy and safety of pneumatic dilation in achalasia: a systematic review and meta-analysis. *Neurogastroenterol Motil* 2019;31:e13548.
64. Vela MF, Richter JE, Khandwala F, et al. The long-term efficacy of pneumatic dilatation and Heller myotomy for the treatment of achalasia. *Clin Gastroenterol Hepatol* 2006;4:580–587.
65. Boeckstaens GE, Annese V, des Varannes SB, et al. Pneumatic dilation versus laparoscopic Heller's myotomy for idiopathic achalasia. *N Engl J Med* 2011; 364:1807–1816.
66. Persson J, Johnsson E, Kostic S, et al. Treatment of achalasia with laparoscopic myotomy or pneumatic dilatation: long-term results of a prospective, randomized study. *World J Surg* 2015;39:713–720.
67. Campos GM, Vittinghoff E, Rabl C, et al. Endoscopic and surgical treatments for achalasia: a systematic review and meta-analysis. *Ann Surg* 2009;249:45–57.
68. Rohof WO, Salvador R, Annese V, et al. Outcomes of treatment for achalasia depend on manometric subtype. *Gastroenterology* 2013;144:718–725; quiz e13–e14.
69. Traube M, Dubovik S, Lange RC, et al. The role of nifedipine therapy in achalasia: results of a randomized, double-blind, placebo-controlled study. *Am J Gastroenterol* 1989;84:1259–1262.
70. Gelfond M, Rozen P, Gilat T. Isosorbide dinitrate and nifedipine treatment of achalasia: a clinical, manometric and radionuclide evaluation. *Gastroenterology* 1982; 83:963–969.
71. Vaezi MF, Richter JE. Current therapies for achalasia: comparison and efficacy. *J Clin Gastroenterol* 1998; 27:21–35.
72. Bassotti G, Annese V. Review article: pharmacological options in achalasia. *Aliment Pharmacol Ther* 1999; 13:1391–1396.
73. Kahrilas PJ, Bredenoord AJ, Fox M, et al. The Chicago Classification of esophageal motility disorders, v3.0. *Neurogastroenterol Motil* 2015;27:160–174.
74. Perez-Fernandez MT, Santander C, Marinero A, et al. Characterization and follow-up of esophagogastric junction outflow obstruction detected by high resolution manometry. *Neurogastroenterol Motil* 2016;28: 116–126.
75. Scherer JR, Kwiatek MA, Soper NJ, et al. Functional esophagogastric junction obstruction with intact peristalsis: a heterogeneous syndrome sometimes akin to achalasia. *J Gastrointest Surg* 2009;13:2219–2225.
76. van Hoeij FB, Smout AJ, Bredenoord AJ. Characterization of idiopathic esophagogastric junction outflow obstruction. *Neurogastroenterol Motil* 2015; 27:1310–1316.
77. DeLay K, Austin GL, Menard-Katcher P. Anatomic abnormalities are common potential explanations of manometric esophagogastric junction outflow obstruction. *Neurogastroenterol Motil* 2016;28:1166–1171.
78. Clayton SB, Patel R, Richter JE. Functional and anatomic esophagogastric junction outflow obstruction: manometry, timed barium esophagram findings, and treatment outcomes. *Clin Gastroenterol Hepatol* 2016; 14:907–911.
79. Blais P, Patel A, Sayuk GS, et al. Upper esophageal sphincter (UES) metrics on high-resolution manometry (HRM) differentiate achalasia subtypes. *Neurogastroenterol Motil* 2017;29:e13136.
80. Okeke FC, Raja S, Lynch KL, et al. What is the clinical significance of esophagogastric junction outflow obstruction? Evaluation of 60 patients at a tertiary referral center. *Neurogastroenterol Motil* 2017; 29:e13061.
81. Biasutto D, Mion F, Garros A, et al. Rapid drink challenge test during esophageal high resolution manometry in patients with esophago-gastric junction outflow obstruction. *Neurogastroenterol Motil* 2018;30:e13293.
82. Liu A, Woo M, Nasser Y, et al. Esophagogastric junction outflow obstruction on manometry: outcomes and lack of benefit from CT and EUS. *Neurogastroenterol Motil* 2019;31:e13712.
83. Song BG, Min YW, Lee H, et al. Clinicomanometric factors associated with clinically relevant esophagogastric junction outflow obstruction from the Sandhill high-resolution manometry system. *Neurogastroenterol Motil* 2018;30:e13221.
84. Babaei A, Shad S, Szabo A, et al. Pharmacologic interrogation of patients with esophagogastric junction outflow obstruction using amyl nitrite. *Neurogastroenterol Motil* 2019;31:e13668.
85. Triggs JR, Carlson DA, Beveridge C, et al. Upright integrated relaxation pressure facilitates characterization of esophagogastric junction outflow obstruction. *Clin Gastroenterol Hepatol* 2019;17:2218–2226.e2.
86. Beveridge CA, Falk GW, Ahuja NK, et al. Low yield of cross-sectional imaging in patients with

- esophagogastric junction outflow obstruction. *Clin Gastroenterol Hepatol* 2019;18:1643–1644.
87. Schupack D, Katzka DA, Geno DM, et al. The clinical significance of esophagogastric junction outflow obstruction and hypercontractile esophagus in high resolution esophageal manometry. *Neurogastroenterol Motil* 2017;29:1–9.
 88. Song BG, Min YW, Lee H, et al. Combined multichannel intraluminal impedance and high-resolution manometry improves detection of clinically relevant esophagogastric junction outflow obstruction. *J Neurogastroenterol Motil* 2019;25:75–81.
 89. Lynch KL, Yang YX, Metz DC, et al. Clinical presentation and disease course of patients with esophagogastric junction outflow obstruction. *Dis Esophagus* 2017;30:1–6.
 90. Zheng E, Gideon RM, Sloan J, et al. Esophagogastric junction outflow obstruction is often associated with coexistent abnormal esophageal body motility and abnormal bolus transit. *Dis Esophagus* 2017;30:1–4.
 91. Su H, Ge H, Liu H, et al. High-resolution manometry in the upright position could improve the manometric evaluation of morbidly obese patients with esophagogastric junction outflow obstruction. *Neurogastroenterol Motil* 2020;32:e13924.
 92. Ratuapli SK, Crowell MD, DiBaise JK, et al. Opioid-induced esophageal dysfunction (OIED) in patients on chronic opioids. *Am J Gastroenterol* 2015;110:979–984.
 93. Babaei A, Szabo A, Shad S, et al. Chronic daily opioid exposure is associated with dysphagia, esophageal outflow obstruction, and disordered peristalsis. *Neurogastroenterol Motil* 2019;31:e13601.
 94. Snyder DL, Crowell MD, Horsley-Silva J, et al. Opioid-induced esophageal dysfunction: differential effects of type and dose. *Am J Gastroenterol* 2019;114:1464–1469.
 95. Zikos TA, Triadafilopoulos G, Clarke JO. Esophagogastric junction outflow obstruction: current approach to diagnosis and management. *Curr Gastroenterol Rep* 2020;22:9.
 96. Clayton SB, Shin CM, Ewing A, et al. Pneumatic dilation improves esophageal emptying and symptoms in patients with idiopathic esophago-gastric junction outflow obstruction. *Neurogastroenterol Motil* 2019;31:e13522.
 97. Filicori F, Dunst CM, Sharata A, et al. Long-term outcomes following POEM for non-achalasia motility disorders of the esophagus. *Surg Endosc* 2019;33:1632–1639.
 98. Khashab MA, Familiari P, Draganov PV, et al. Peroral endoscopic myotomy is effective and safe in non-achalasia esophageal motility disorders: an international multicenter study. *Endosc Int Open* 2018;6:E1031–E1036.
 99. Beveridge C, Lynch K. Diagnosis and management of esophagogastric junction outflow obstruction. *Gastroenterol Hepatol (N Y)* 2020;16:131–138.
 100. Roman S, Kahrilas PJ. Management of spastic disorders of the esophagus. *Gastroenterol Clin North Am* 2013;42:27–43.
 101. Roman S, Lin Z, Pandolfino JE, et al. Distal contraction latency: a measure of propagation velocity optimized for esophageal pressure topography studies. *Am J Gastroenterol* 2011;106:443–451.
 102. Chen JW, Savarino E, Smout A, et al. Chicago Classification Update (v4.0): technical review on diagnostic criteria for hypercontractile esophagus. *Neurogastroenterol Motil* 2021;33:e14115.
 103. Almansa C, Heckman MG, DeVault KR, et al. Esophageal spasm: demographic, clinical, radiographic, and manometric features in 108 patients. *Dis Esophagus* 2012;25:214–221.
 104. Spencer HL, Smith L, Riley SA. A questionnaire study to assess long-term outcome in patients with abnormal esophageal manometry. *Dysphagia* 2006;21:149–155.
 105. Cattau EL Jr, Castell DO, Johnson DA, et al. Diltiazem therapy for symptoms associated with nutcracker esophagus. *Am J Gastroenterol* 1991;86:272–276.
 106. Konturek JW, Gillessen A, Domschke W. Diffuse esophageal spasm: a malfunction that involves nitric oxide? *Scand J Gastroenterol* 1995;30:1041–1045.
 107. Fox M, Sweis R, Wong T, et al. Sildenafil relieves symptoms and normalizes motility in patients with oesophageal spasm: a report of two cases. *Neurogastroenterol Motil* 2007;19:798–803.
 108. Vanuytsel T, Bisschops R, Farre R, et al. Botulinum toxin reduces dysphagia in patients with nonachalasia primary esophageal motility disorders. *Clin Gastroenterol Hepatol* 2013;11:1115–1121.e2.
 109. Miller LS, Pallela SV, Parkman HP, et al. Treatment of chest pain in patients with noncardiac, nonreflux, non-achalasia spastic esophageal motor disorders using botulinum toxin injection into the gastroesophageal junction. *Am J Gastroenterol* 2002;97:1640–1646.
 110. Storr M, Allescher HD, Rosch T, et al. Treatment of symptomatic diffuse esophageal spasm by endoscopic injections of botulinum toxin: a prospective study with long-term follow-up. *Gastrointest Endosc* 2001;54:754–759.
 111. Cannon RO 3rd, Quyyumi AA, Mincemoyer R, et al. Imipramine in patients with chest pain despite normal coronary angiograms. *N Engl J Med* 1994;330:1411–1417.
 112. Clouse RE, Lustman PJ, Eckert TC, et al. Low-dose trazodone for symptomatic patients with esophageal contraction abnormalities. A double-blind, placebo-controlled trial. *Gastroenterology* 1987;92:1027–1036.
 113. Khan MA, Kumbhari V, Ngamruengphong S, et al. Is POEM the answer for management of spastic esophageal disorders? A systematic review and meta-analysis. *Dig Dis Sci* 2017;62:35–44.
 114. Leconte M, Douard R, Gaudric M, et al. Functional results after extended myotomy for diffuse oesophageal spasm. *Br J Surg* 2007;94:1113–1118.
 115. Gyawali CP, Sifrim D, Carlson DA, et al. Ineffective esophageal motility: concepts, future directions, and conclusions from the Stanford 2018 symposium. *Neurogastroenterol Motil* 2019;31:e13584.
 116. Shetler KP, Bikhtii S, Triadafilopoulos G. Ineffective esophageal motility: clinical, manometric, and outcome

- characteristics in patients with and without abnormal esophageal acid exposure. *Dis Esophagus* 2017;30:1–8.
117. Xiao Y, Kahrilas PJ, Nicodeme F, et al. Lack of correlation between HRM metrics and symptoms during the manometric protocol. *Am J Gastroenterol* 2014; 109:521–526.
 118. Booth M, Stratford J, Dehn TC. Preoperative esophageal body motility does not influence the outcome of laparoscopic Nissen fundoplication for gastroesophageal reflux disease. *Dis Esophagus* 2002;15:57–60.
 119. Ravi N, Al-Sarraf N, Moran T, et al. Acid normalization and improved esophageal motility after Nissen fundoplication: equivalent outcomes in patients with normal and ineffective esophageal motility. *Am J Surg* 2005; 190:445–450.
 120. Rydberg L, Ruth M, Abrahamsson H, et al. Tailoring antireflux surgery: a randomized clinical trial. *World J Surg* 1999;23:612–618.
 121. Fibbe C, Luyer P, Keller J, et al. Esophageal motility in reflux disease before and after fundoplication: a prospective, randomized, clinical, and manometric study. *Gastroenterology* 2001;121:5–14.
 122. Mauro A, Savarino E, De Bortoli N, et al. Optimal number of multiple rapid swallows needed during high-resolution esophageal manometry for accurate prediction of contraction reserve. *Neurogastroenterol Motil* 2018;30: e13253.
 123. Smith CD, DeVault KR, Buchanan M. Introduction of mechanical sphincter augmentation for gastroesophageal reflux disease into practice: early clinical outcomes and keys to successful adoption. *J Am Coll Surg* 2014; 218:776–781.
 124. Asti E, Bonitta G, Lovece A, et al. Longitudinal comparison of quality of life in patients undergoing laparoscopic Toupet fundoplication versus magnetic sphincter augmentation: observational cohort study with propensity score analysis. *Medicine (Baltimore)* 2016;95: e4366.
 125. Lei WY, Hung JS, Liu TT, et al. Influence of prucalopride on esophageal secondary peristalsis in reflux patients with ineffective motility. *J Gastroenterol Hepatol* 2018; 33:650–655.
 126. Scheerens C, Tack J, Rommel N. Bupirone, a new drug for the management of patients with ineffective esophageal motility? *United European Gastroenterol J* 2015; 3:261–265.
 127. Karamanolis GP, Panopoulos S, Denaxas K, et al. The 5-HT_{1A} receptor agonist bupirone improves esophageal motor function and symptoms in systemic sclerosis: a 4-week, open-label trial. *Arthritis Res Ther* 2016;18:195.
 128. Aggarwal N, Thota PN, Lopez R, et al. A randomized double-blind placebo-controlled crossover-style trial of bupirone in functional dysphagia and ineffective esophageal motility. *Neurogastroenterol Motil* 2018; 30:e13213.
 129. Ravi K, Friesen L, Issaka R, et al. Long-term outcomes of patients with normal or minor motor function abnormalities detected by high-resolution esophageal manometry. *Clin Gastroenterol Hepatol* 2015;13:1416–1423.
 130. Ghisa M, Laserra G, Marabotto E, et al. Achalasia and obstructive motor disorders are not uncommon in patients with eosinophilic esophagitis. *Clin Gastroenterol Hepatol* 2020;19:1554–1563.
 131. Nennstiel S, Bajbouj M, Becker V, et al. High-resolution manometry in patients with eosinophilic esophagitis under topical steroid therapy—a prospective observational study (HIMEOS-study). *Neurogastroenterol Motil* 2016;28:599–607.
 132. Mandl T, Ekberg O, Wollmer P, et al. Dysphagia and dysmotility of the pharynx and oesophagus in patients with primary Sjogren’s syndrome. *Scand J Rheumatol* 2007;36:394–401.
 133. Anselmino M, Zaninotto G, Costantini M, et al. Esophageal motor function in primary Sjogren’s syndrome: correlation with dysphagia and xerostomia. *Dig Dis Sci* 1997;42:113–118.
 134. Karamanolis GP, Denaxas K, Panopoulos S, et al. Severe oesophageal disease and its associations with systemic sclerosis. *Clin Exp Rheumatol* 2017;35(Suppl 106):82–85.
 135. Rosztoczy A, Kovacs L, Wittmann T, et al. Manometric assessment of impaired esophageal motor function in primary Sjogren’s syndrome. *Clin Exp Rheumatol* 2001; 19:147–152.
 136. Grande L, Lacima G, Ros E, et al. Esophageal motor function in primary Sjogren’s syndrome. *Am J Gastroenterol* 1993;88:378–381.
 137. Marie I, Ducrotte P, Denis P, et al. Oesophageal mucosal involvement in patients with systemic sclerosis receiving proton pump inhibitor therapy. *Aliment Pharmacol Ther* 2006;24:1593–1601.
 138. Babaei A, Szabo A, Shad S, et al. Chronic daily opioid exposure is associated with dysphagia, esophageal outflow obstruction, and disordered peristalsis. *Neurogastroenterol Motil* 2019;31:e13601.
 139. Kraichely RE, Arora AS, Murray JA. Opiate-induced oesophageal dysmotility. *Aliment Pharmacol Ther* 2010; 31:601–606.
 140. Babaei A, Shad S, Massey BT. Motility patterns following esophageal pharmacologic provocation with amyl nitrite or cholecystokinin during high-resolution manometry distinguish idiopathic vs opioid-induced type 3 achalasia. *Clin Gastroenterol Hepatol* 2020; 18:813–821.e1.
 141. Patel D, Callaway J, Vaezi M. Opioid-induced foregut dysfunction. *Am J Gastroenterol* 2019;114:1716–1725.
 142. Yang H, Meun C, Sun X, et al. Outcome following management of dysphagia after laparoscopic anti-reflux surgery. *World J Surg* 2012;36:838–843.
 143. Wehrli NE, Levine MS, Rubesin SE, et al. Secondary achalasia and other esophageal motility disorders after laparoscopic Nissen fundoplication for gastroesophageal reflux disease. *AJR Am J Roentgenol* 2007; 189:1464–1468.
 144. Hui JM, Hunt DR, de Carle DJ, et al. Esophageal pneumatic dilation for postfundoplication dysphagia: safety, efficacy, and predictors of outcome. *Am J Gastroenterol* 2002;97:2986–2991.

145. Schuitemaker JM, van Hoeij FB, Schijven MP, et al. Pneumatic dilation for persistent dysphagia after antireflux surgery, a multicentre single-blind randomised sham-controlled clinical trial. *Gut* 2021; 71:10–15.
146. Miller AT, Matar R, Abu Dayyeh BK, et al. Postobesity surgery esophageal dysfunction: a combined cross-sectional prevalence study and retrospective analysis. *Am J Gastroenterol* 2020;115:1669–1680.
147. Pimentel M, Bonorris GG, Chow EJ, et al. Peppermint oil improves the manometric findings in diffuse esophageal spasm. *J Clin Gastroenterol* 2001;33:27–31.
148. Eherer AJ, Schwetz I, Hammer HF, et al. Effect of sildenafil on oesophageal motor function in healthy subjects and patients with oesophageal motor disorders. *Gut* 2002;50:758–764.
149. Cox ID, Hann CM, Kaski JC. Low dose imipramine improves chest pain but not quality of life in patients with angina and normal coronary angiograms. *Eur Heart J* 1998;19:250–254.
150. Park SW, Lee H, Lee HJ, et al. Low-dose amitriptyline combined with proton pump inhibitor for functional chest pain. *World J Gastroenterol* 2013; 19:4958–4965.
151. Lee H, Kim JH, Min BH, et al. Efficacy of venlafaxine for symptomatic relief in young adult patients with functional chest pain: a randomized, double-blind, placebo-controlled, crossover trial. *Am J Gastroenterol* 2010; 105:1504–1512.
152. Varia I, Logue E, O'Connor C, et al. Randomized trial of sertraline in patients with unexplained chest pain of noncardiac origin. *Am Heart J* 2000;140:367–372.
153. Keefe FJ, Shelby RA, Somers TJ, et al. Effects of coping skills training and sertraline in patients with non-cardiac chest pain: a randomized controlled study. *Pain* 2011; 152:730–741.
154. Doraiswamy PM, Varia I, Hellegers C, et al. A randomized controlled trial of paroxetine for noncardiac chest pain. *Psychopharmacol Bull* 2006;39:15–24.

Received July 16, 2021. Accepted December 12, 2021.

Correspondence

Address correspondence to: Dhyanes A. Patel, MD, Assistant Professor of Medicine, Center for Esophageal Disorders, Division of Gastroenterology, Hepatology, and Nutrition, Vanderbilt University Medical Center, 1211 Medical Center Drive, Nashville, Tennessee 37232. e-mail: Dan.patel@vmc.org.

Authorship Contributions

Dhyanes Patel (acquisition of data and drafting of the manuscript), Rena Yadlapati (acquisition of data and drafting of the manuscript), and Michael Vaezi (concept and critical revision of the manuscript).

Conflicts of interest

Rena Yadlapati discloses the following: institutional consulting agreement with Medtronic, Ironwood Pharmaceuticals, and Diversatek; consultant for Phantom Pharmaceuticals; research support for Ironwood Pharmaceuticals; and advisory board with stock options for RJS Mediagnostix. The other authors disclose no conflicts.

Funding

Rena Yadlapati is supported by National Institutes of Health K23 DK125266 (Principal Investigator: Rena Yadlapati).