

Biliary Tree Ultrasound - In a nutshell

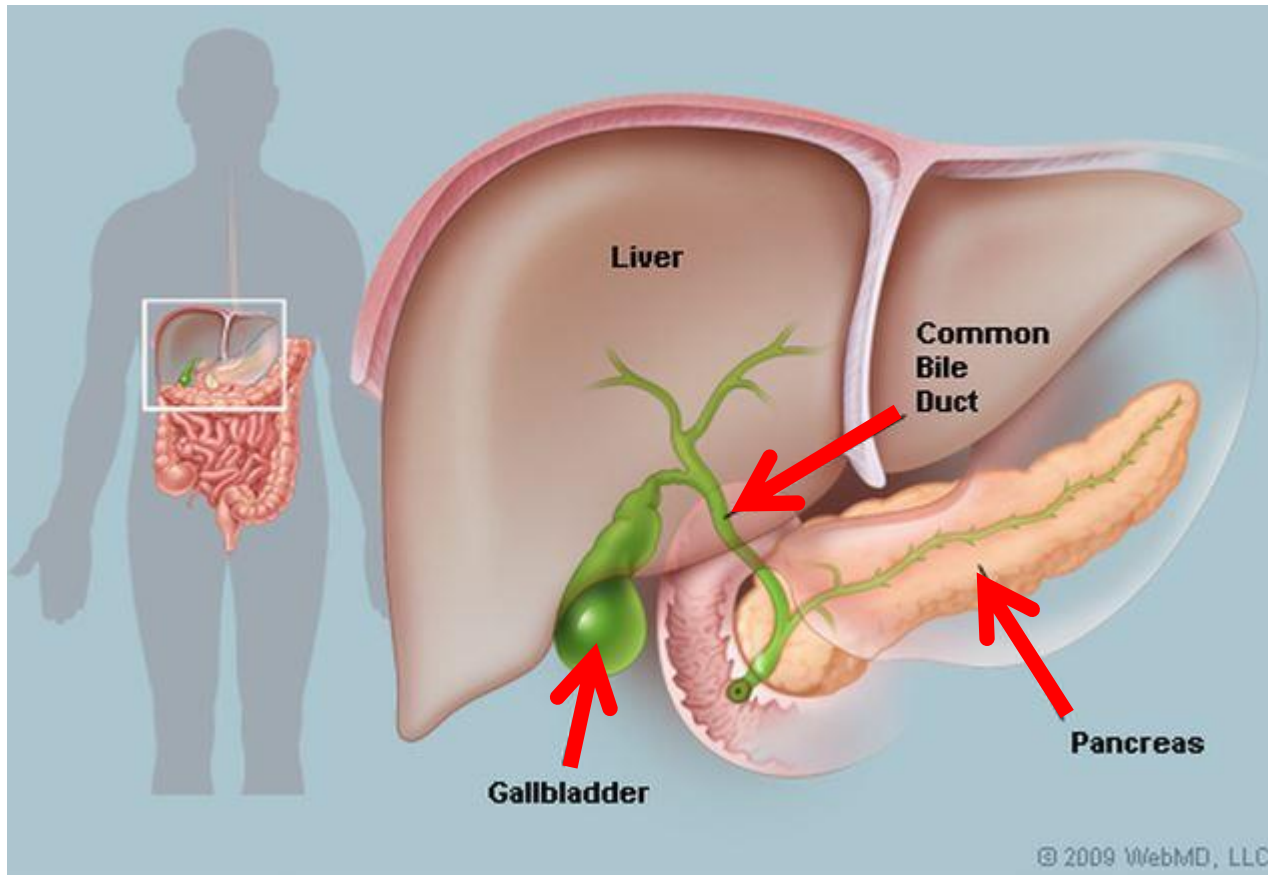
Pamela Parker
Lead Sonographer



Aims

- Review what we know about the biliary system
- Common pathologies
- Pitfalls
- Reporting tips

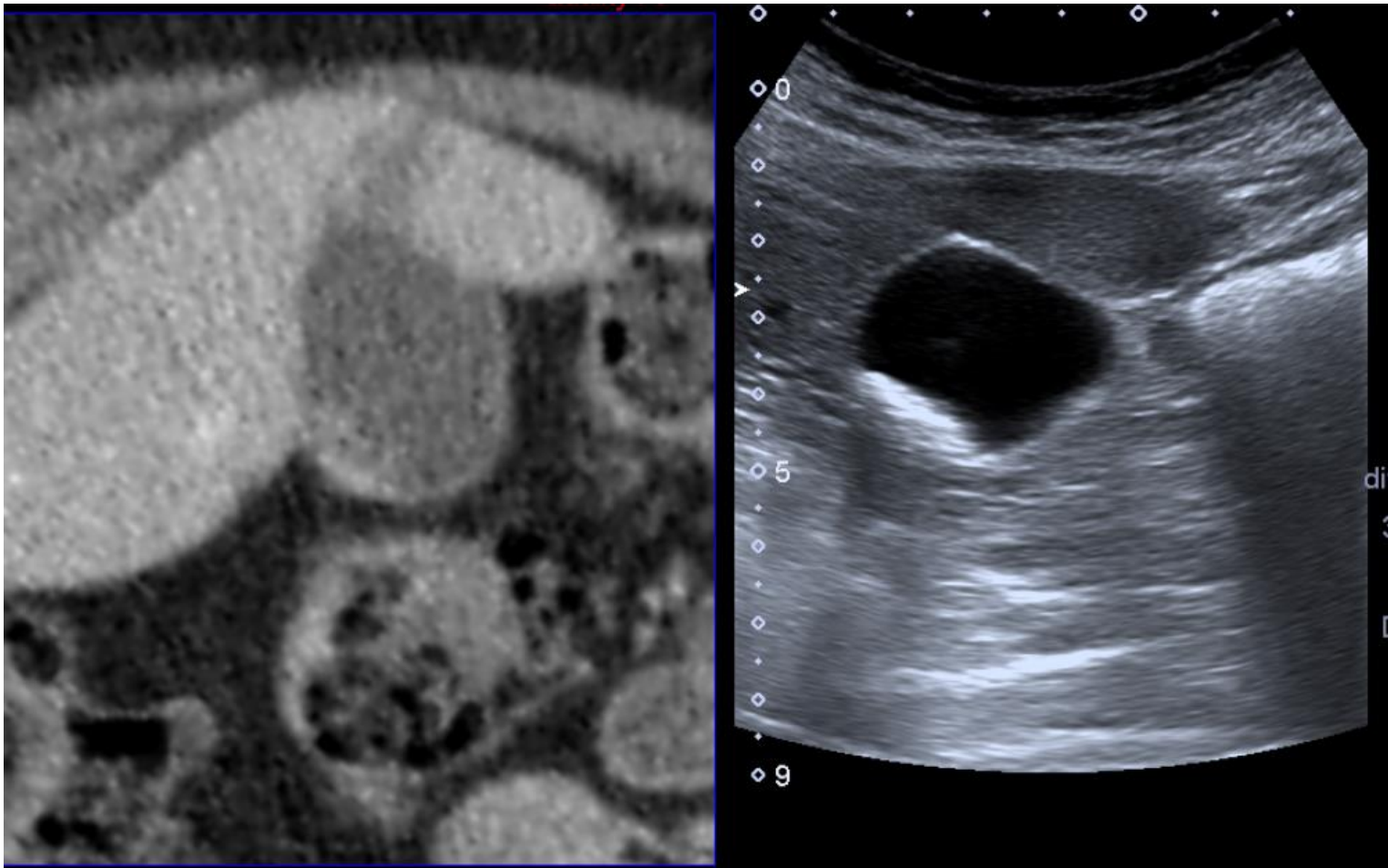
The Nutshell



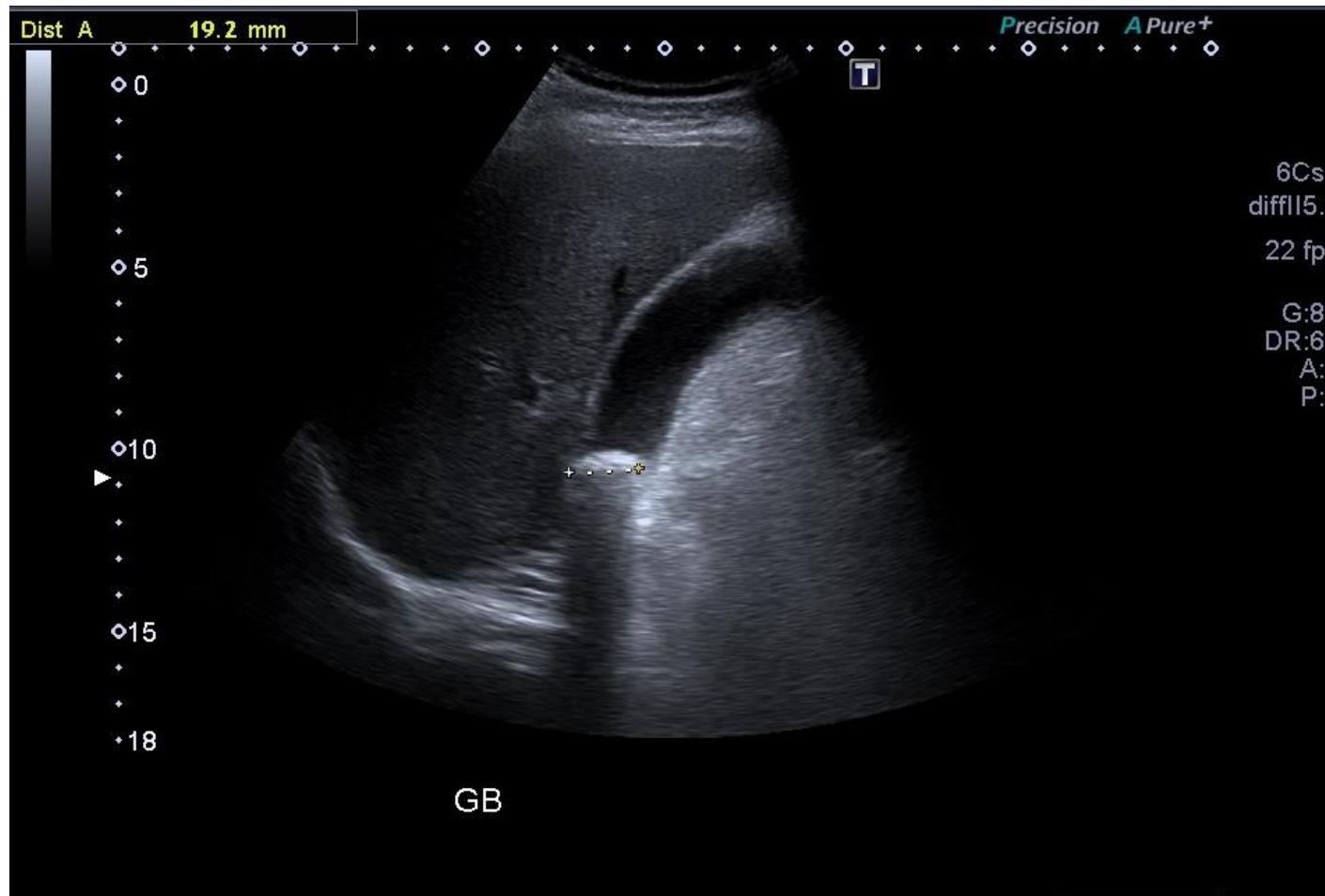Background

- Biliary examinations most appropriate and efficacious uses of US
- Inherently high contrast due to cystic nature of GB and bile ducts, particularly when dilated
- High quality examination in the majority of pts

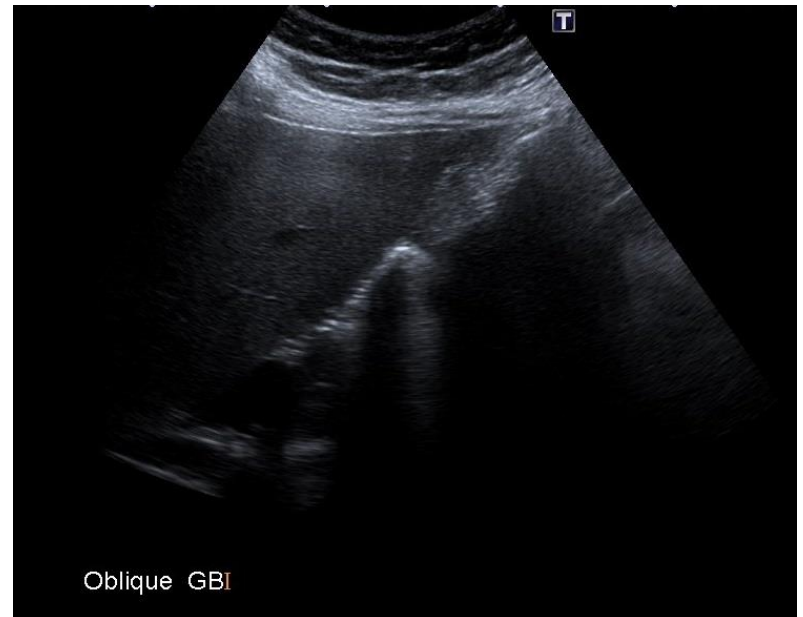
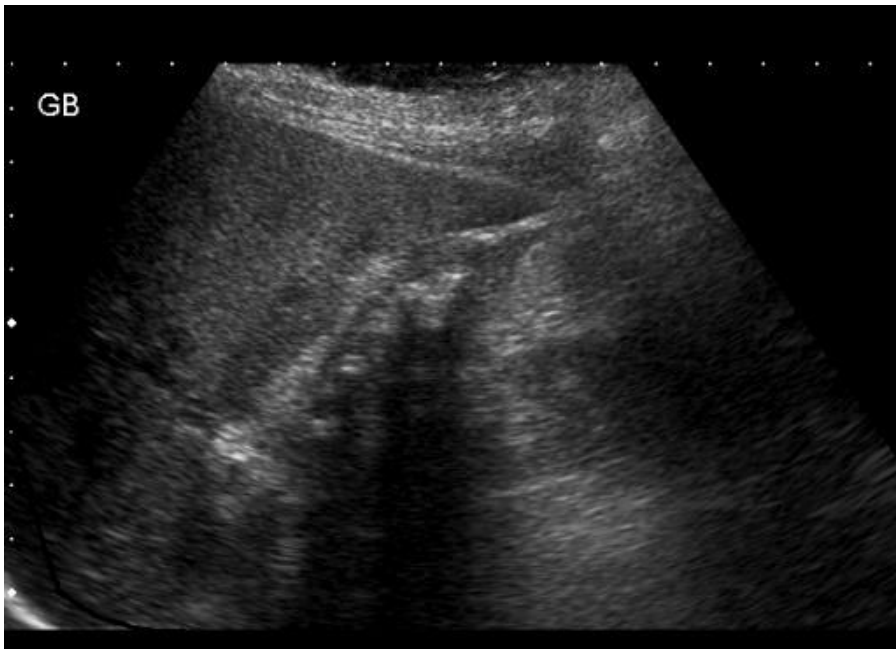
Modality of choice



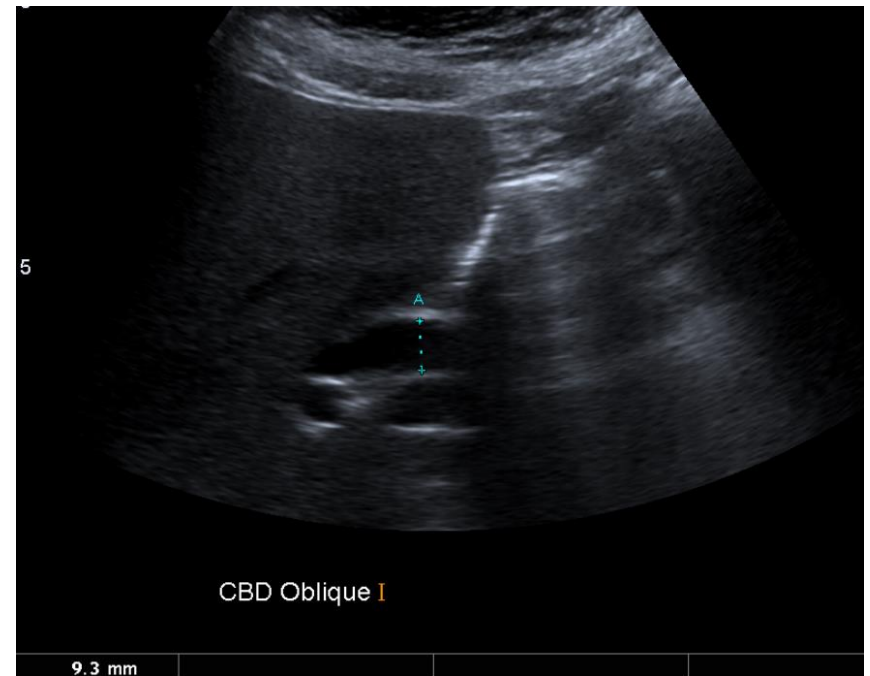
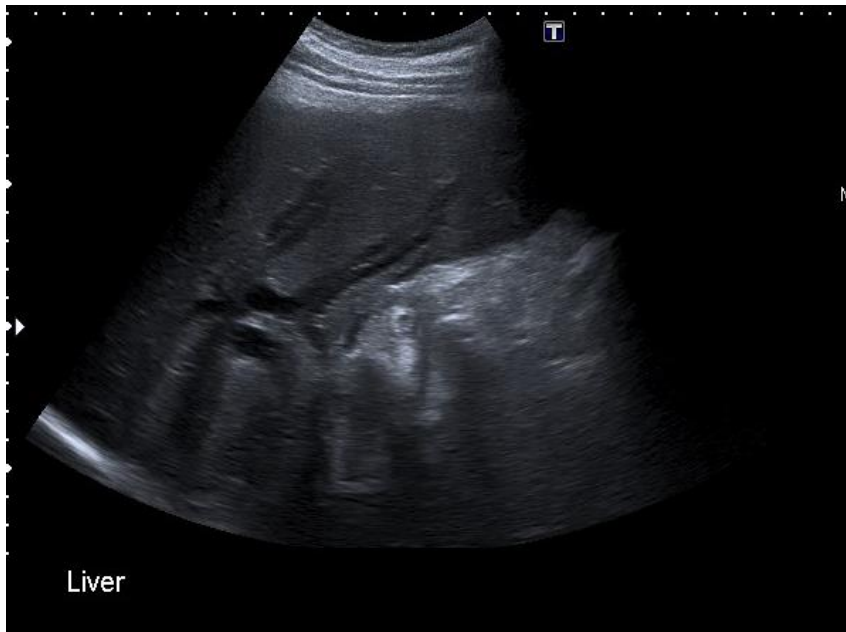
The things we are good at



The things we are good at

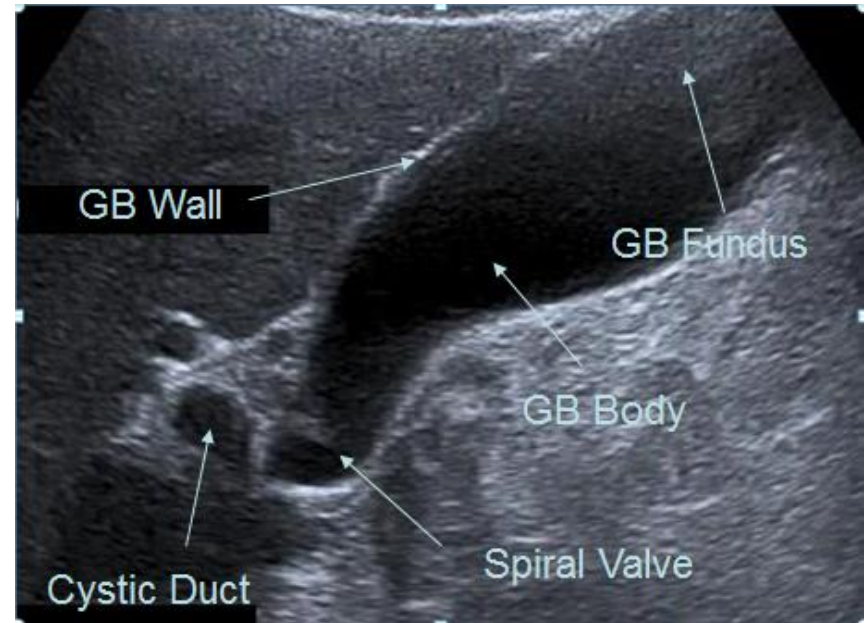


The things we are good at



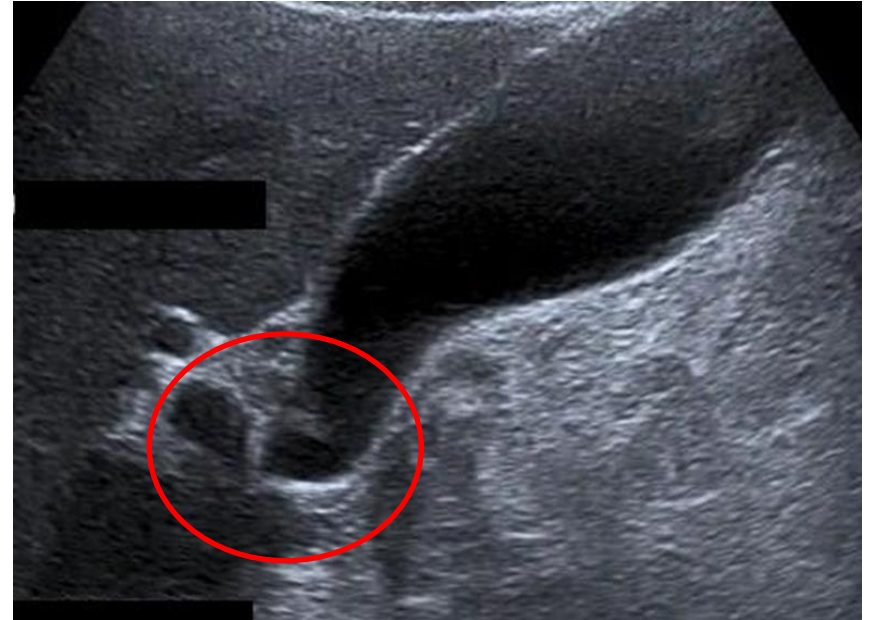
Gallbladder

- The ultrasound appearance of the GB are of a elongated pear-shaped cystic structure.
- The gallbladder is well delineated and has smooth thin walls



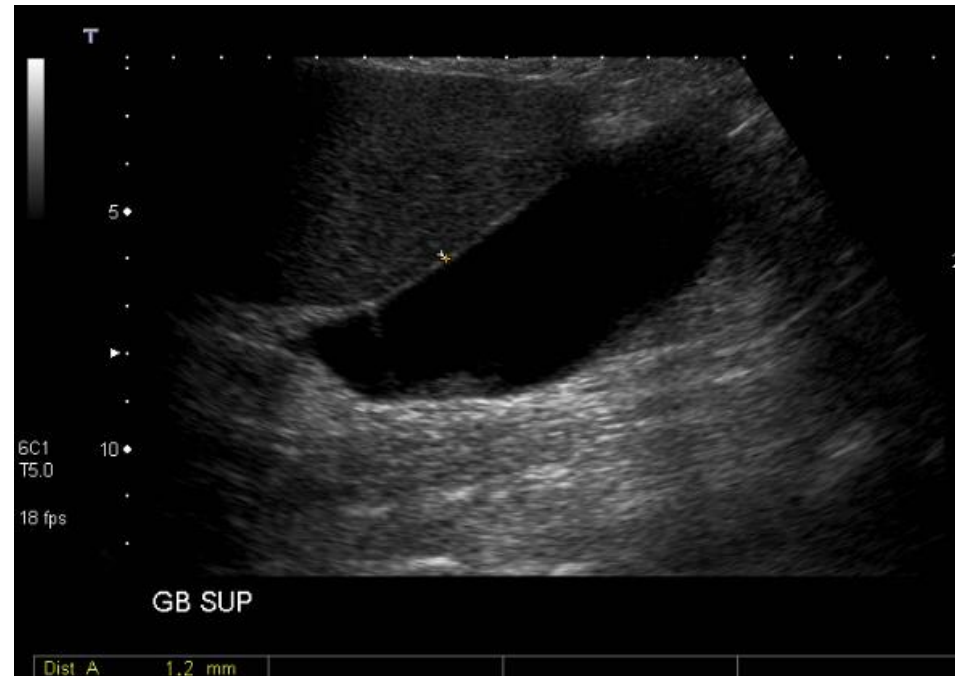
Gallbladder

- Spiral valves are small mucosal folds within the cystic duct
- ****Pitfall alert****
- Can mimic stones within GB neck



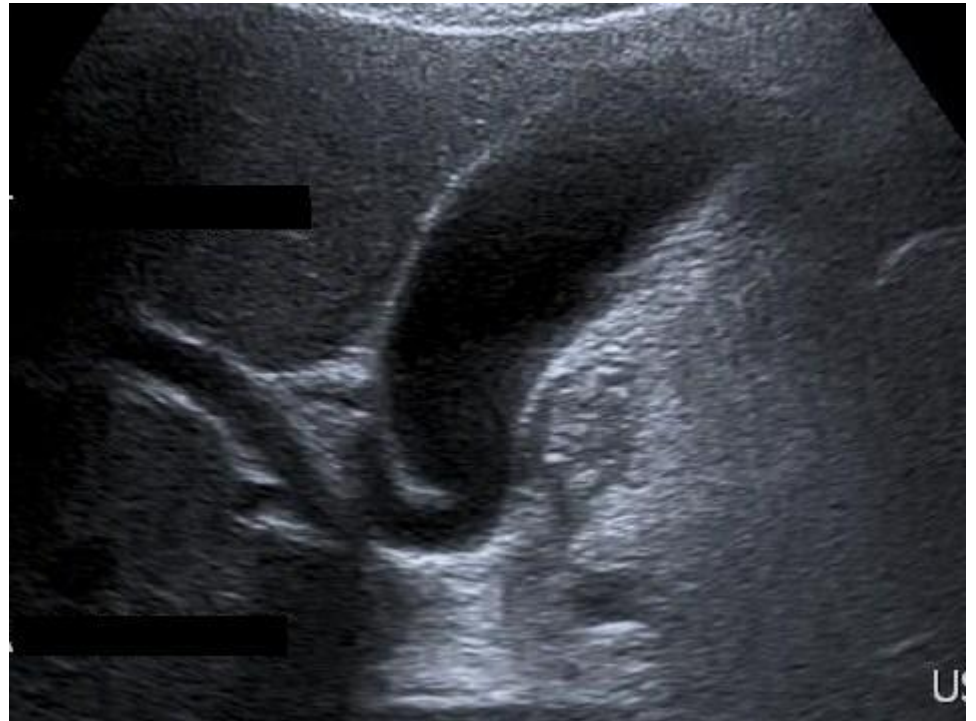Gallbladder

- The walls are uniform and thin measuring less than 3mm in diameter.
- 3mm is the upper limit of the normal range.
- There is no lower limit of normal.

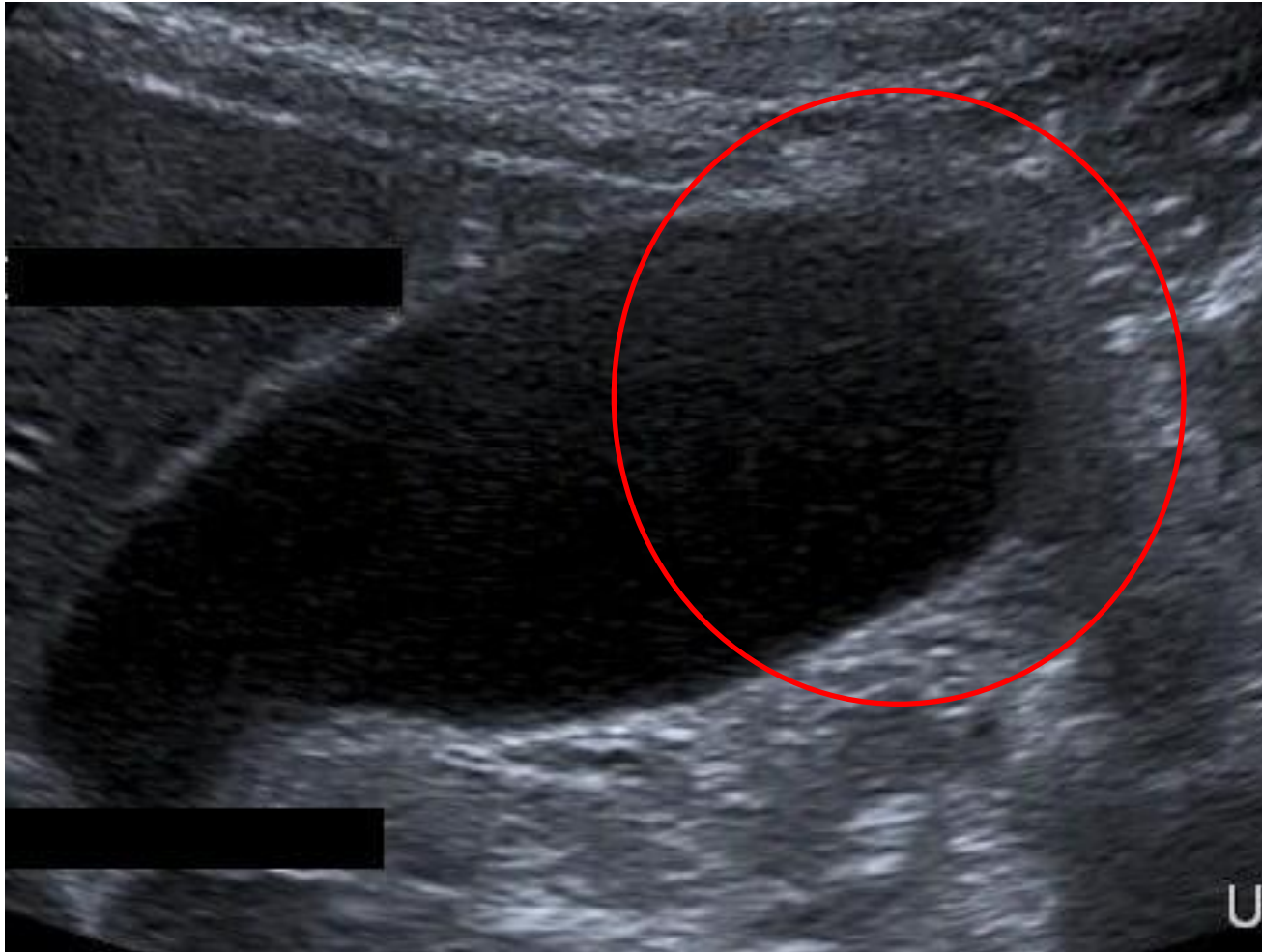


Gallbladder

- This image could be improved if the fundus was more clearly
- Evaluate fully the whole of the gallbladder during every examination.
- May need to evaluate the neck separately to the fundus.



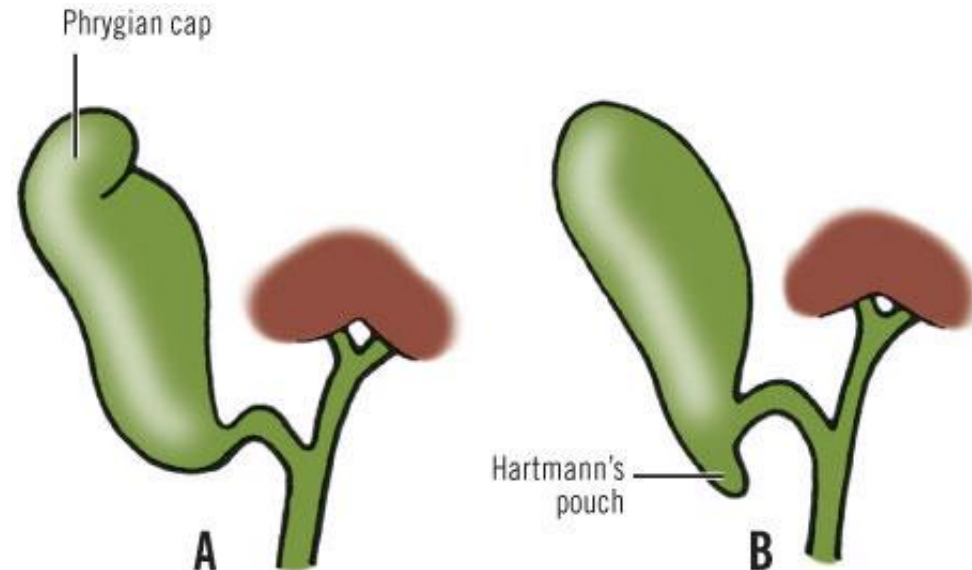
Gallbladder



Gallbladder

Normal Variants

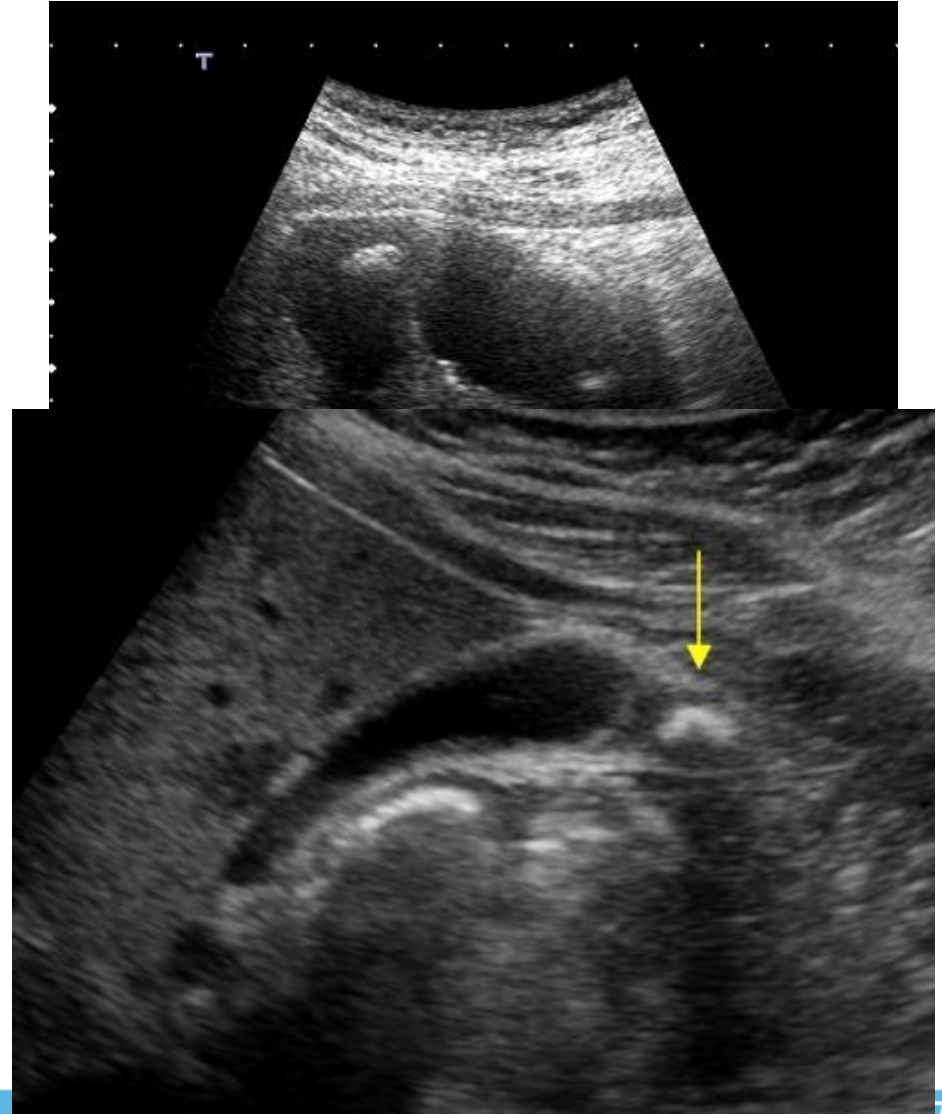
- Fundal fold known as a Phrygian cap can also be present
- An infundibulum (cavity), called Hartmann's Pouch, can be present in the region of the gallbladder neck,



Copyright ©2006 by The McGraw-Hill Companies, Inc.
All rights reserved.

Gallbladder

- GS can migrate to the fundus, particularly if fold present
- The fundus has a separate blood supply and this can be reduced, particularly in the elderly
- Fundus is prone to pathology developing related to chronic cholecystitis leading to adenomyomatosis



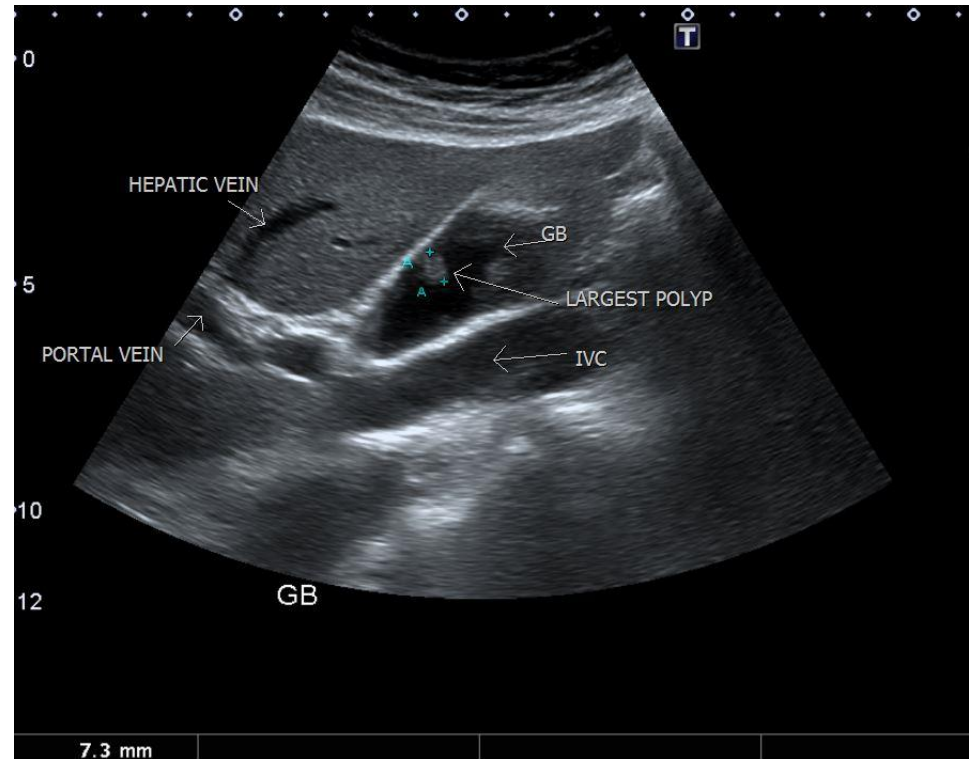
Gallbladder

- Polyps
- Gallstones
- Acute Cholecystitis
- Chronic Cholecystitis
- Adenomyomatosis
- Cancer



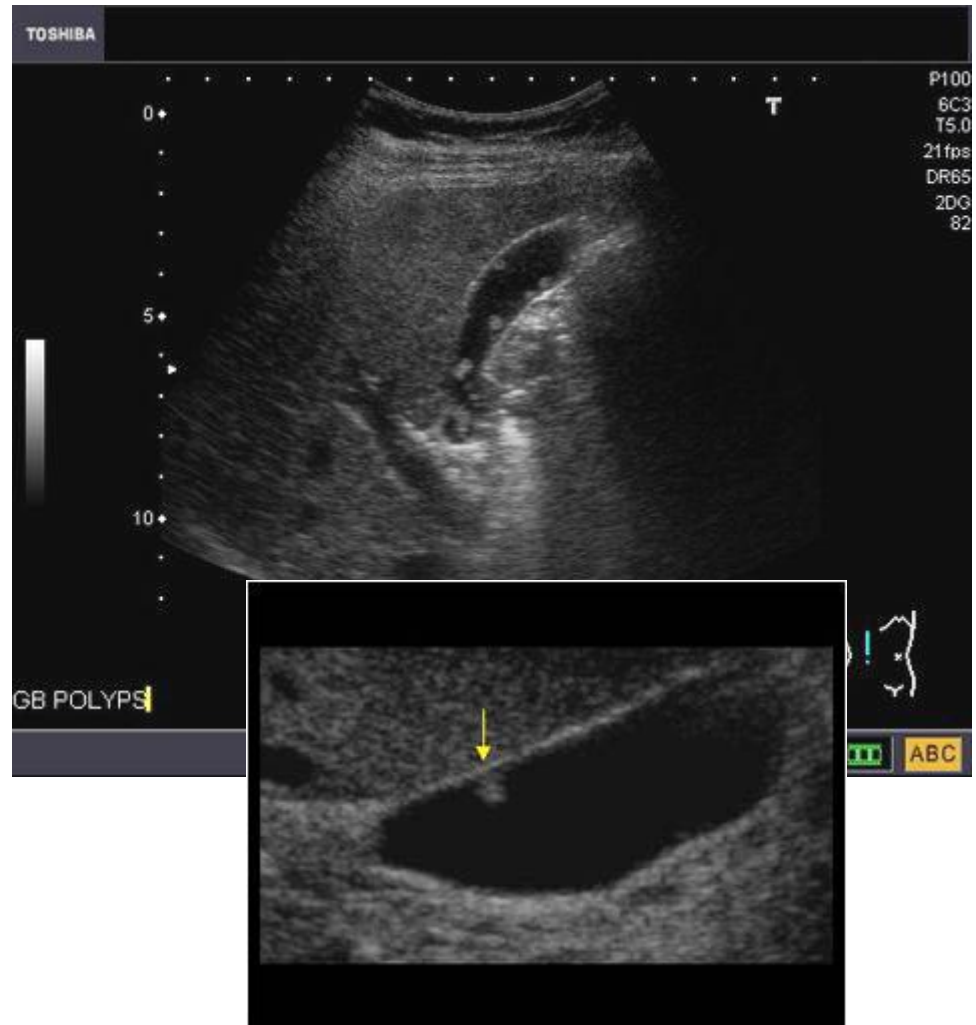
Gallbladder Polyps

- A **gallbladder polyp** is defined as any elevated lesion of the mucosal surface of the gallbladder, and as such includes a variety of both benign and malignant entities.
- Solitary
- Multiple



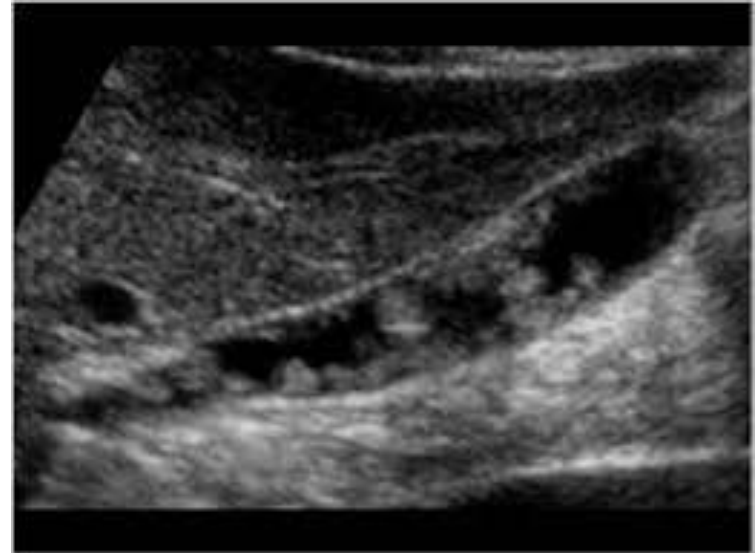
Gallbladder Polyps

- Relatively frequent, seen in up to 5% of the population.
- Over 90% are benign, and the majority are cholesterol polyps
- Frequently identified in patients between 40 and 50 years of age, and are more common in women



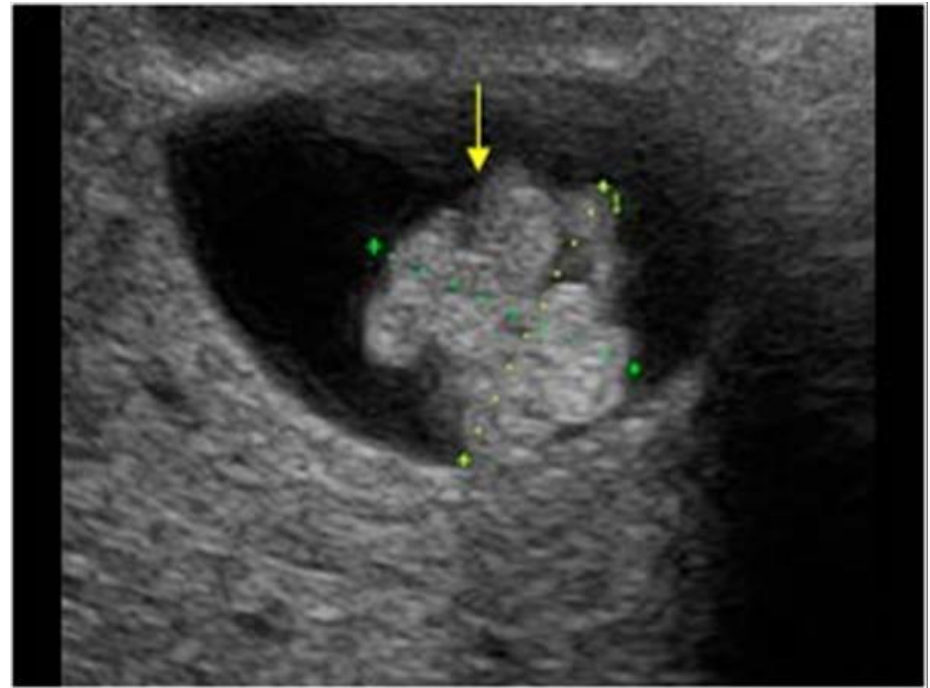
Gallbladder Polyps

- 95% of all polyps are benign
- cholesterol polyps : > 50% of all polyps
- adenoma : ~ 30%, possibly premalignant
- inflammatory polyps
- adenomyomatosis



Gallbladder Polyps

- 5% of all polyps are malignant
- adenocarcinoma : ~ 90% of malignant polyps
- other rare entities including
 - metastases to gallbladder
 - squamous cell carcinoma
 - angiosarcoma



Gallbladder Polyps

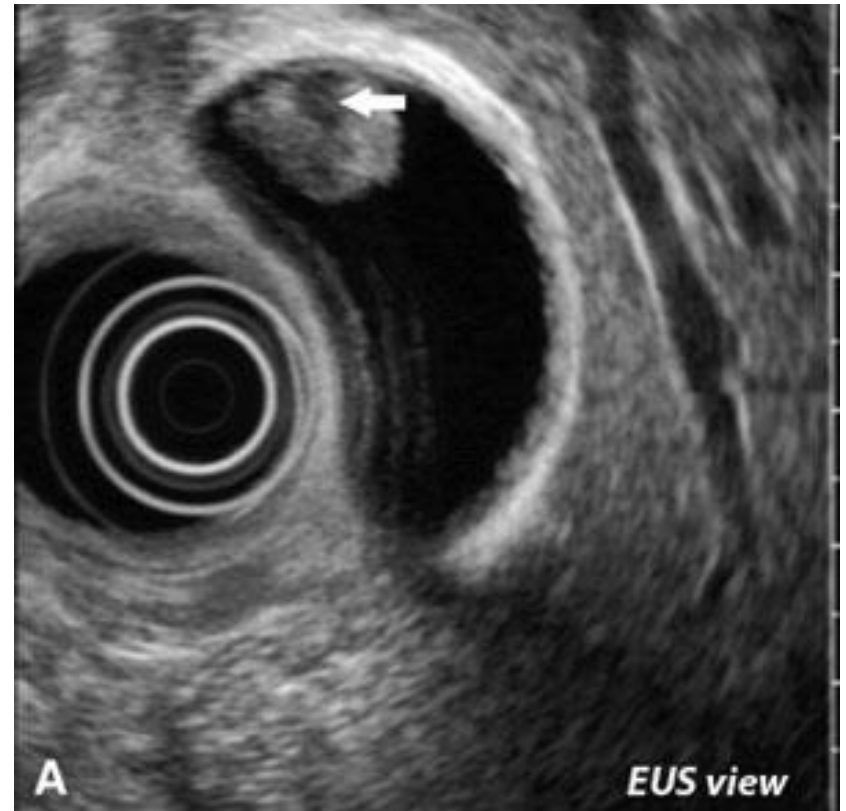- Typically polyps are incidentally found on upper abdominal imaging, in patients with upper abdominal discomfort.
- In most instances polyps are thought to be asymptomatic
- Surgical management considered if symptomatic and no other cause found
- The differential for a gallbladder polyp is limited, and includes:
 - gallstone
 - usually mobile, but may be adherent
 - usually casts and acoustic shadow
 - biliary sludge

Gallbladder Polyps

- In most instances predicting histology based purely on imaging is not possible, with the possible exception of cholesterol
- As adenomas are considered pre-malignant, surgical management is warranted, and thus the important imaging distinction is between a cholesterol polyp and a solid (and thus most likely neoplastic lesion).
- Overall size is probably the most useful indicator of malignancy, with polyps over 10mm in diameter having a malignancy rate of 37-88%.

Gallbladder Polyps

- General features of gallbladder polyps are a non shadowing polypoid ingrowth into gallbladder lumen, which is usually immobile unless there is a relatively long pedunculated component.
- EUS is useful in further assessing polyps as it is able to generate higher resolution images



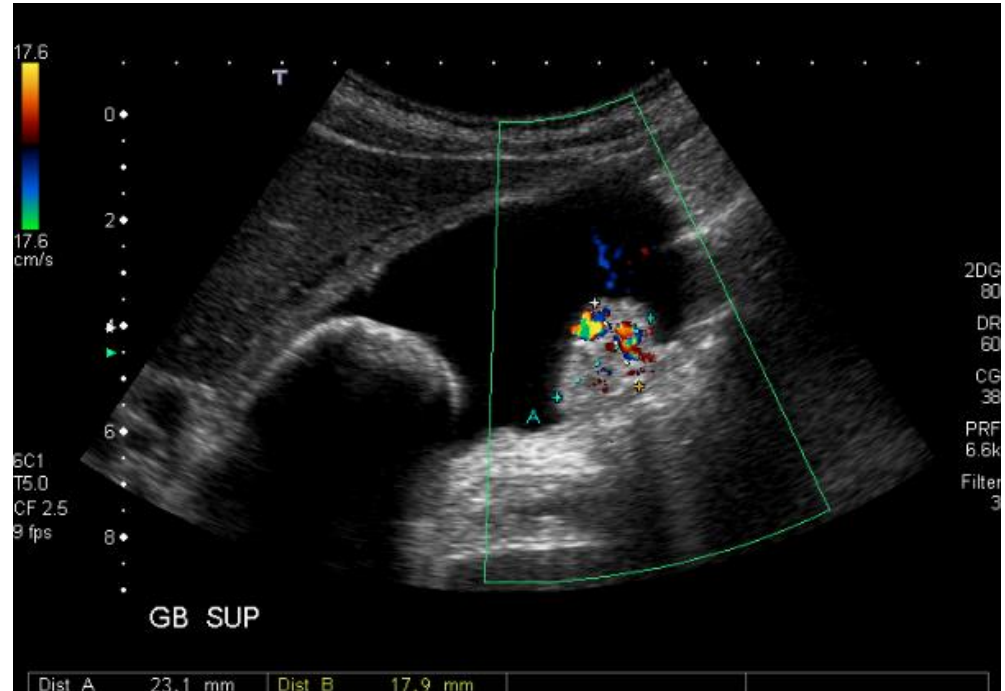
Gallbladder Polyps

Features of cholesterol polyp include:

- small size
- > 90% are less than 10 mm & most are less than 5 mm
- echogenicity varies with size
- small polyps are echogenic but non-shadowing
- larger cholesterol polyps tend to be hypoechoic
- small polyps are adherent to the wall and a smooth
- larger lesions tend to be pedunculated and granular in outline

Gallbladder Polyps

- Adenomas on the other hand tend to be larger, solitary, more often sessile with internal vascularity and of intermediate echogenicity.
- It is not possible to distinguish an adenoma from an adenocarcinoma



Gallbladder Polyps

- The risk of GB malignancy resulting from incidentally detected polyps is extremely low.
- Incidentally detected GB polyps measuring 6 mm or less may require no additional follow-up.
- Incidentally Detected Gallbladder Polyps: Is Follow-up Necessary?—Long-term Clinical and US Analysis of 346 Patients
January 2011 Radiology 258, 277-282

Gallbladder Polyp Management

- Any Polyp >9mm should be referred for consideration of Cholecystectomy.
- Incidental finding of a polyp <9mm in an asymptomatic patient should have a follow up scan in 1 year with 3 caveats.
 - If patient becomes symptomatic within the year they should be referred for consideration of Cholecystectomy, regardless of size of the polyp
 - If Polyp has stayed the same after 1 year can be discharged with advice see GP if becomes symptomatic. If the patient does develop RUQ symptoms they should be referred for consideration of Cholecystectomy, regardless of size of the polyp.
 - If small increase in size, annual follow up until either >9mm, symptomatic or stops growing.

The things we are good at

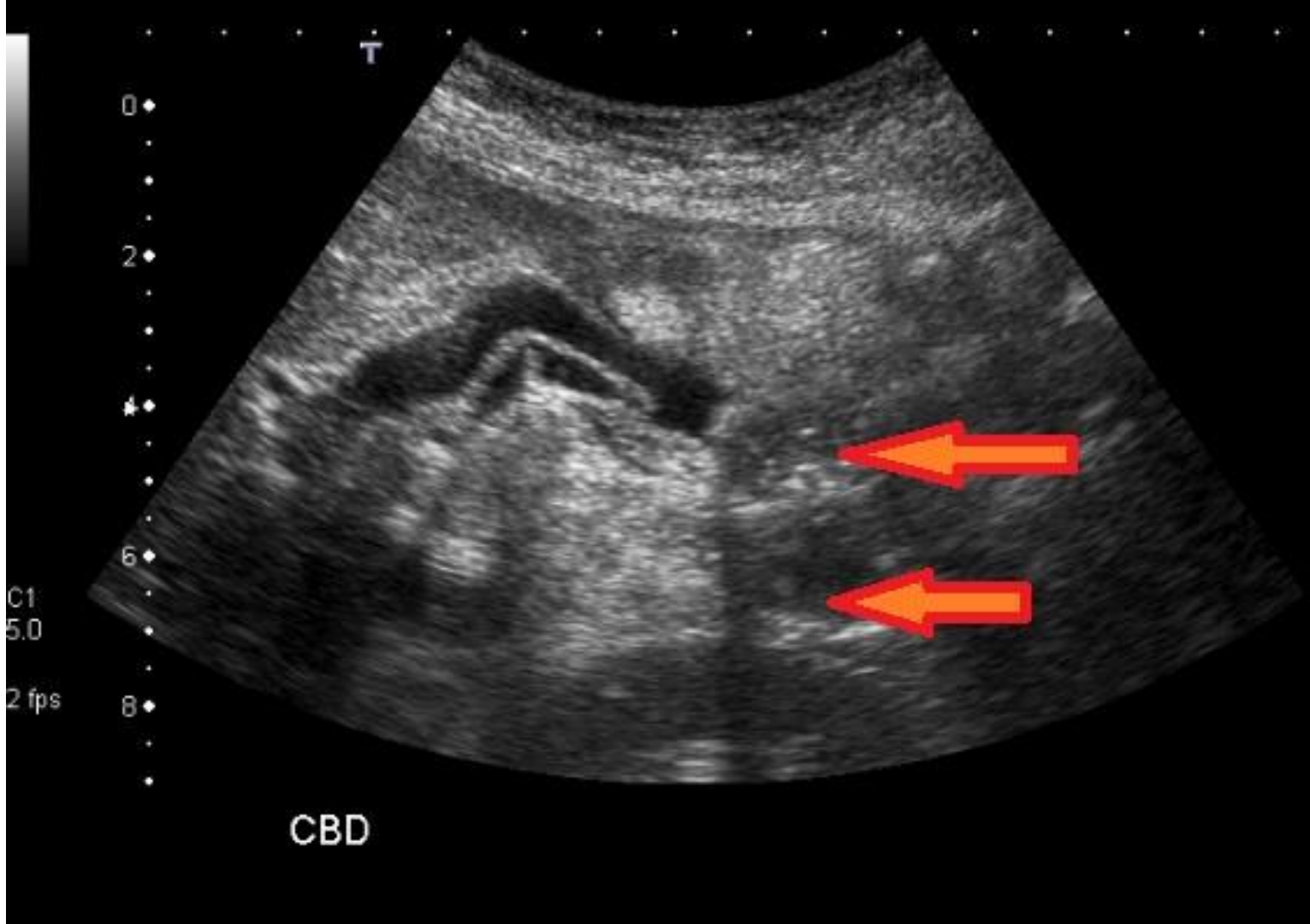


Gallstones

- 10-15% of people in the adult Western world develop gallstones.
- 1-4% of asymptomatic cases go on to develop symptoms annually.
- The most common presentations are biliary colic (56%) and acute cholecystitis (36%)

Gallstones

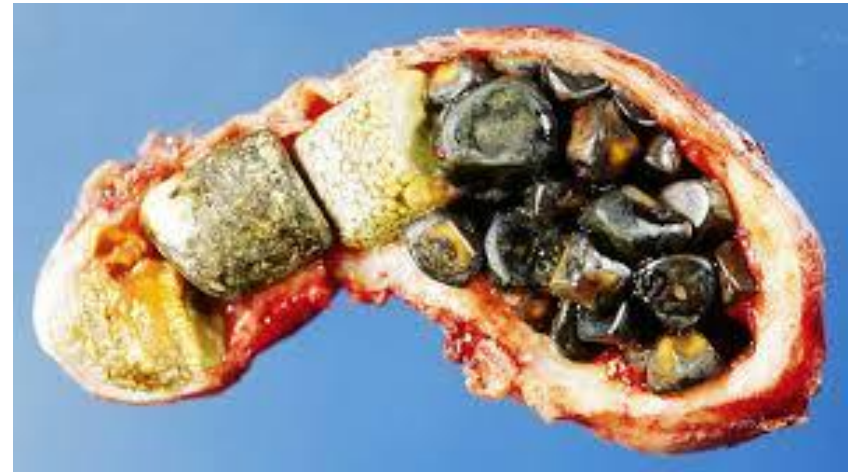- The adage 'fair, fat, fertile, female and forty' is only part of the story. Other risk factors include:
 - Increasing age.
 - Positive family history.
 - Sudden weight loss - eg, after obesity surgery.
 - Loss of bile salts - eg, ileal resection, terminal ileitis.
 - Diabetes - as part of the metabolic syndrome.
 - Oral contraception - particularly in young women



- CBD stones may occur in 3-14.7% of all patients for whom cholecystectomy is performed

Gallstones

- Bile contains cholesterol, bile pigments and phospholipids. If the concentrations of these vary, different kinds of stones may be formed.
- Cholesterol stones
- Black pigment stones
- Mixed stones.
- Brown pigment stones



Gallstones

- Black pigment stones are small, friable, irregular and radiolucent:
 - Risk factors include haemolysis and cirrhosis.
- Mixed stones are faceted and are comprised of calcium salts, pigment and cholesterol. 10% are radiopaque.
- Brown pigment stones (<5% in the UK) form as a result of stasis and infection within the biliary system,

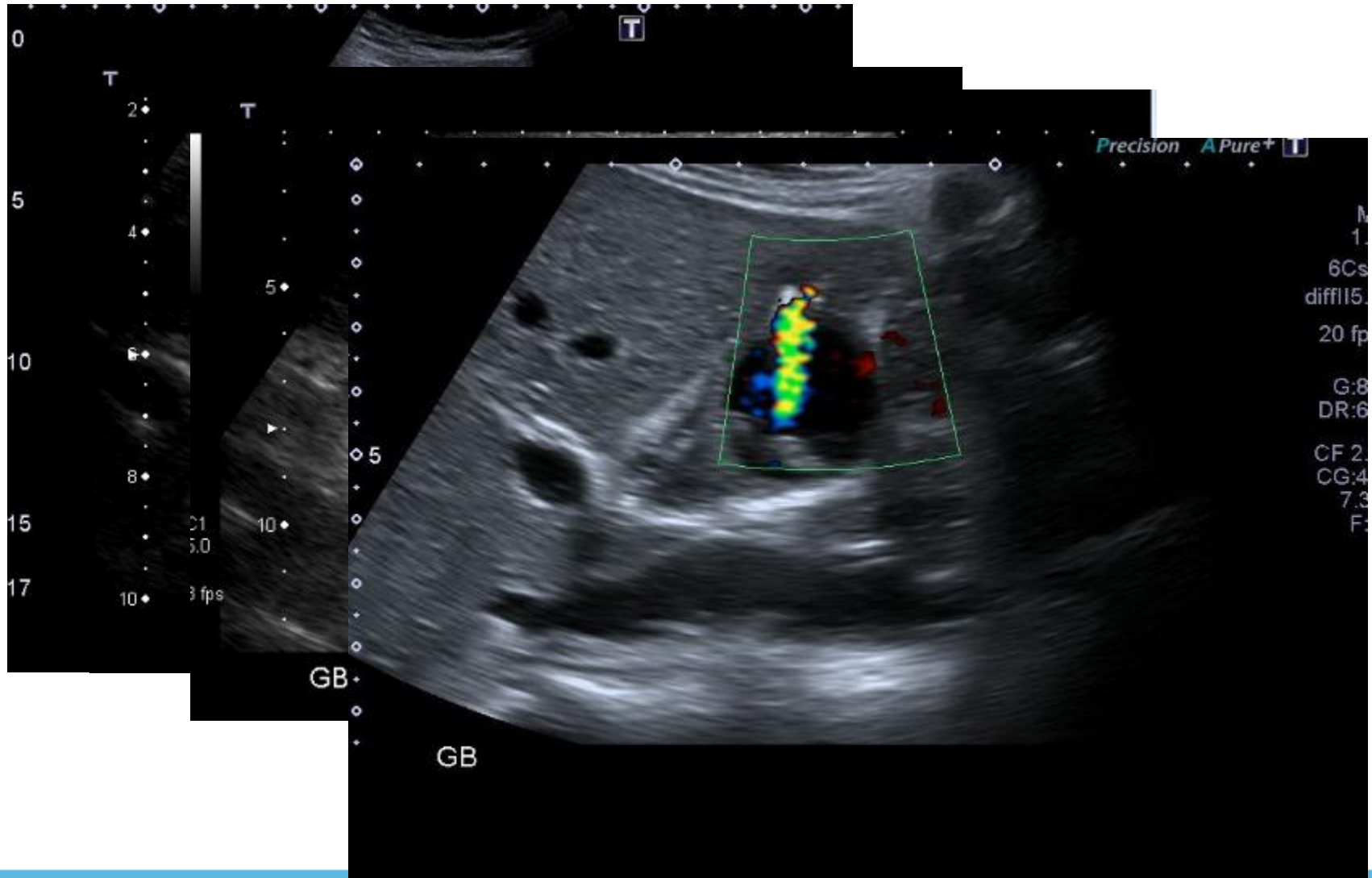
Gallstones – US features

- Ultrasound appearances are the same regardless of the composition of the stone.
- The large acoustic impedance between the stone and the surrounding bile makes them highly reflective.
- Strong acoustic shadow.

*** Pitfall Alert***

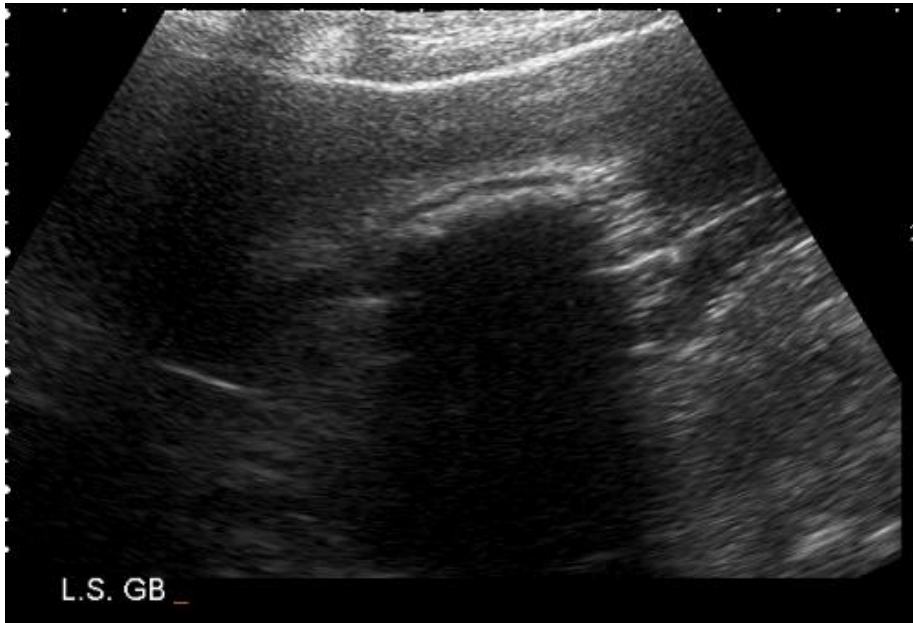
- Stones of less than 5mm may not shadow, particularly with the use of compound imaging
- Moving the patient and observe movement.
- Colour Doppler can occasionally aid diagnosis as it may produce a “twinkle” artefact in the stone.

Gallstones – US features

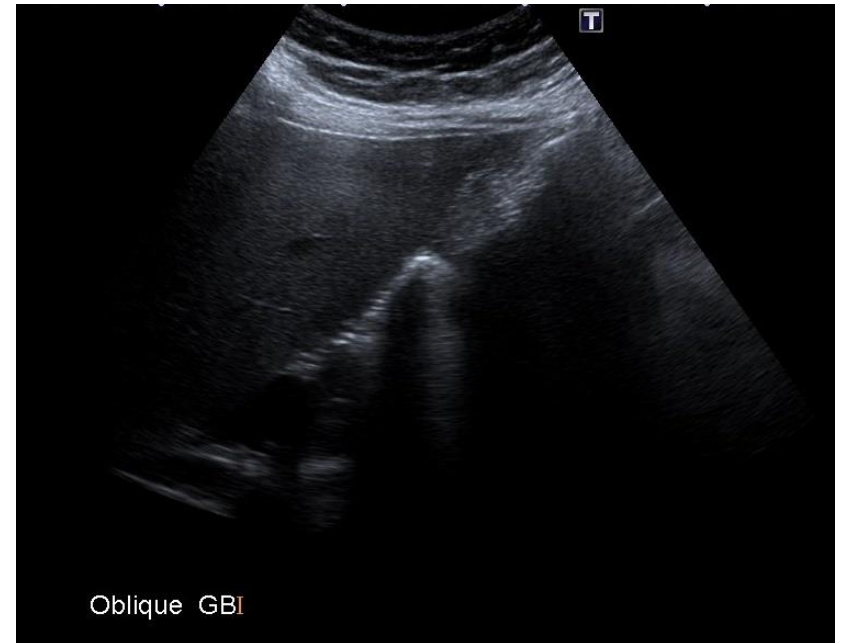


Gallstones – US features

Gallstones?



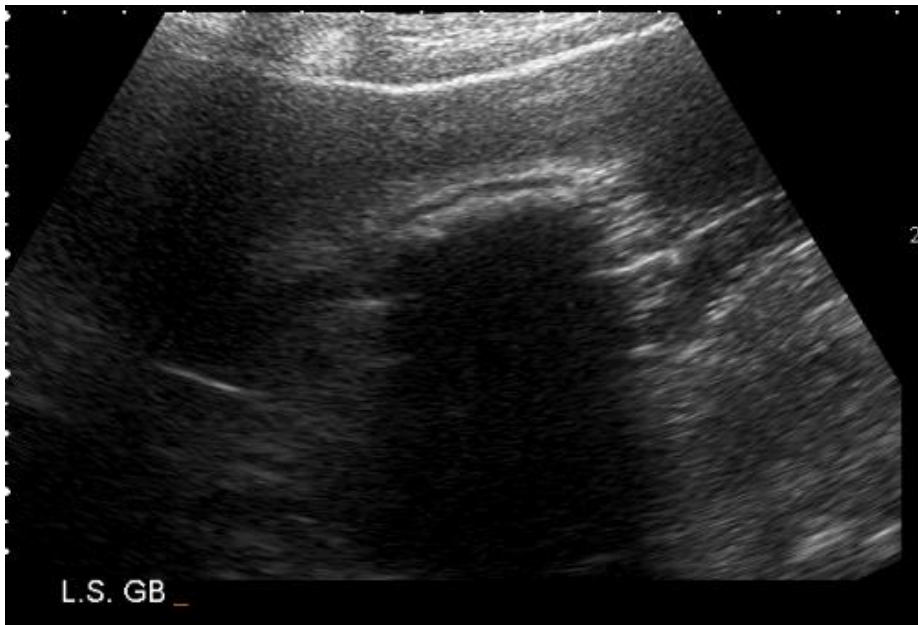Gallstones?



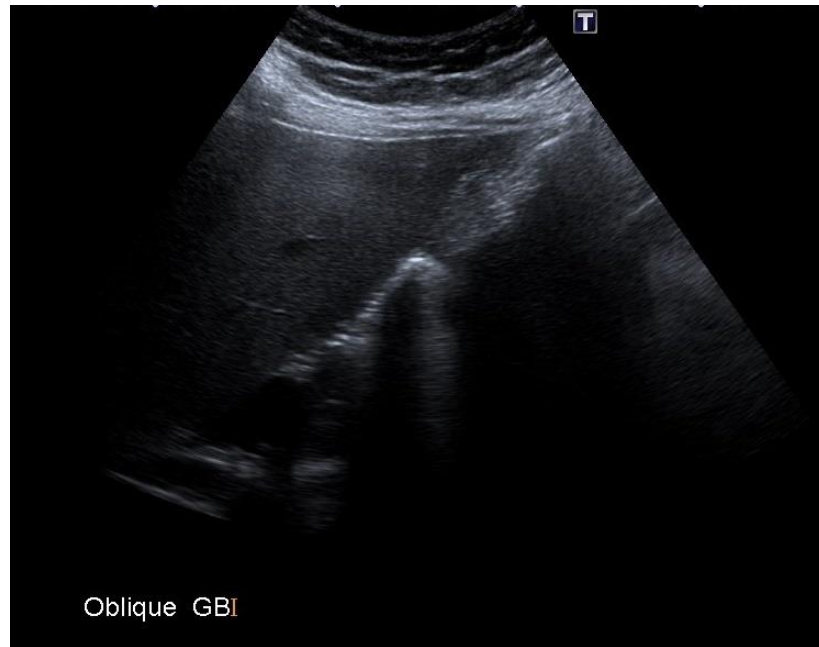
Gallstones ?

Pitfall Alert

YES ✓



No X – Gas filled
duodenum



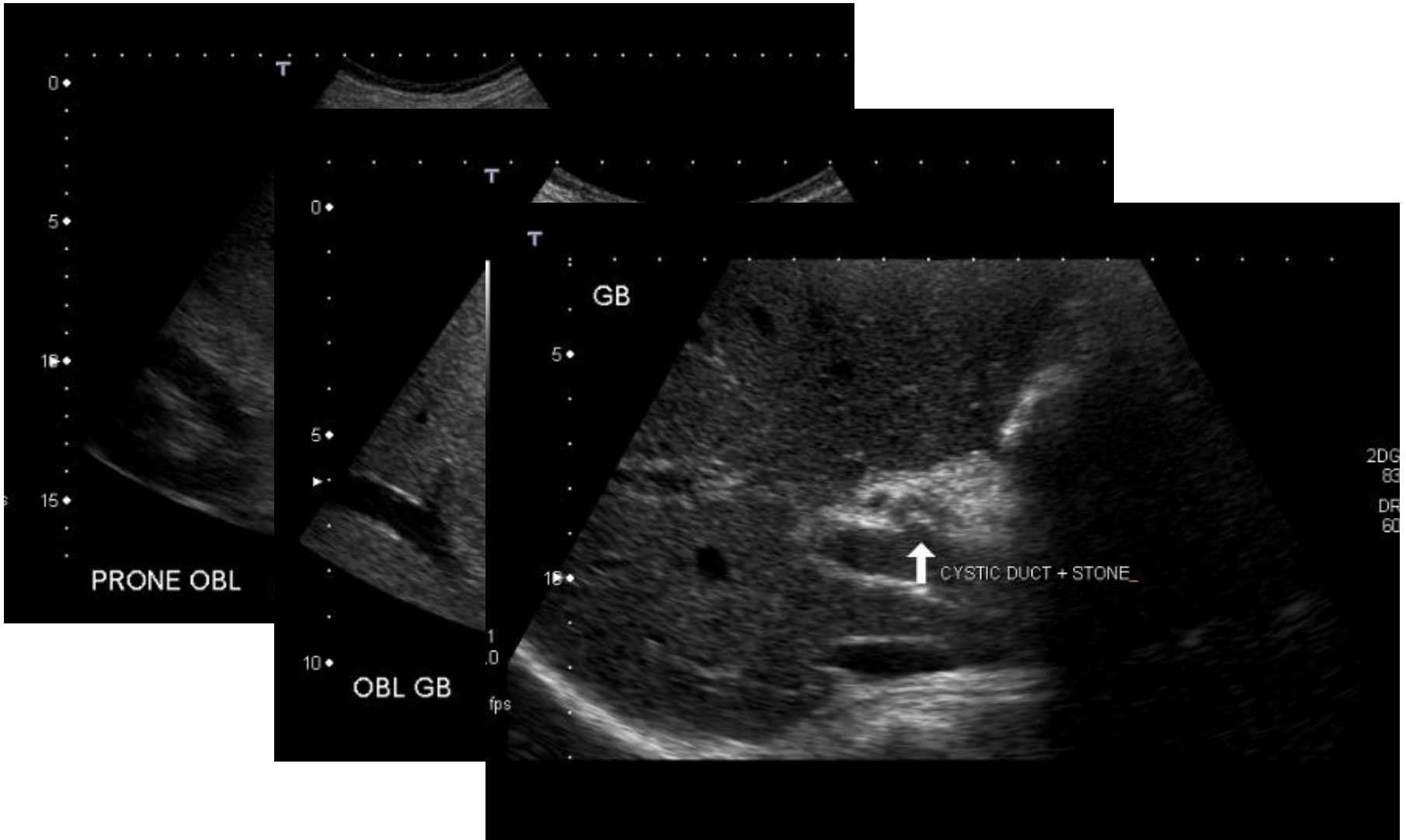
Gallstones - Presentation

- Up to 70% of patients with gallstones are asymptomatic at the time of diagnosis.
- Gallstones may cause acute or chronic cholecystitis, biliary colic, pancreatitis or obstructive jaundice.
- Biliary colic is the most common presentation,
- The second most common presentation is acute cholecystitis,

Biliary colic

- Caused by a gallstone impacting in the cystic duct or the ampulla of Vater.
- The pain starts suddenly in the epigastrium (RUQ) and may radiate around to the back in the interscapular region.
- Pain persists from 15 minutes up to 24 hours, subsiding spontaneously or with analgesics.
- Nausea or vomiting often accompanies the pain,
- Occurs as a result of distension of the gallbladder due to an obstruction or to the passage of a stone through the cystic duct

Gallstones - Colic



Gallstones – Investigations

- US is 90-95% sensitive
 - Immobile stones misinterpreted as polyps; very small ones may be missed or fail to throw a helpful acoustic shadow.
- US can also assess CBD liver and hepatic bile ducts;
 - but it can only identify with certainty about half of any stones in the CBD.
- If US negative but there is a high level of suspicion, repeat after an interval;
 - May pick up stones which were previously missed.

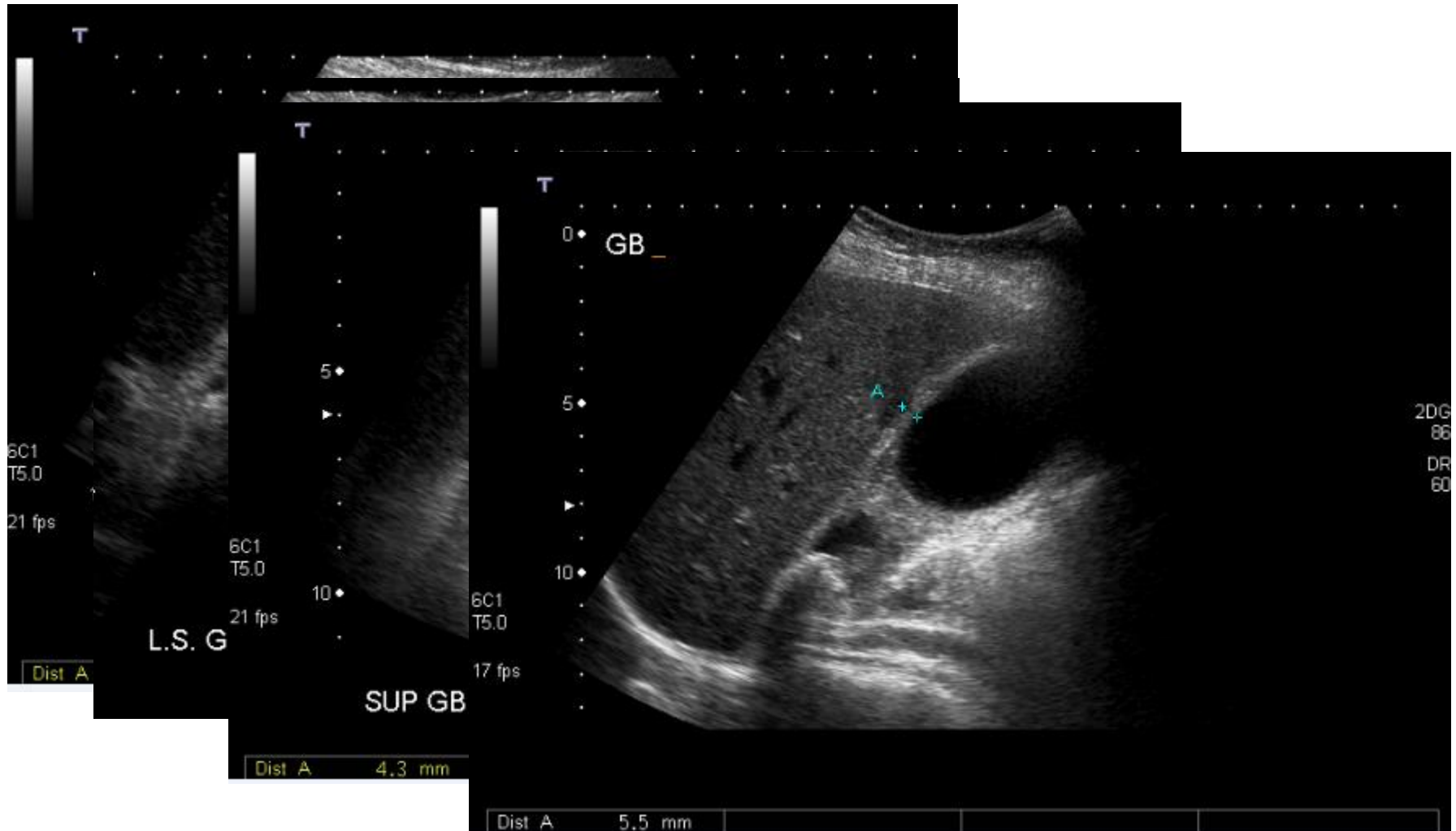
Causes of Cholecystitis

- Gallstones or biliary sludge (95% of patients).
- Trauma or acute biliary illness (5% acalculus disease).
- Female gender.
- Increasing age.
- Obesity.
- Rapid weight loss.
- Pregnancy.
- Crohn's disease.
- Hyperlipidaemia

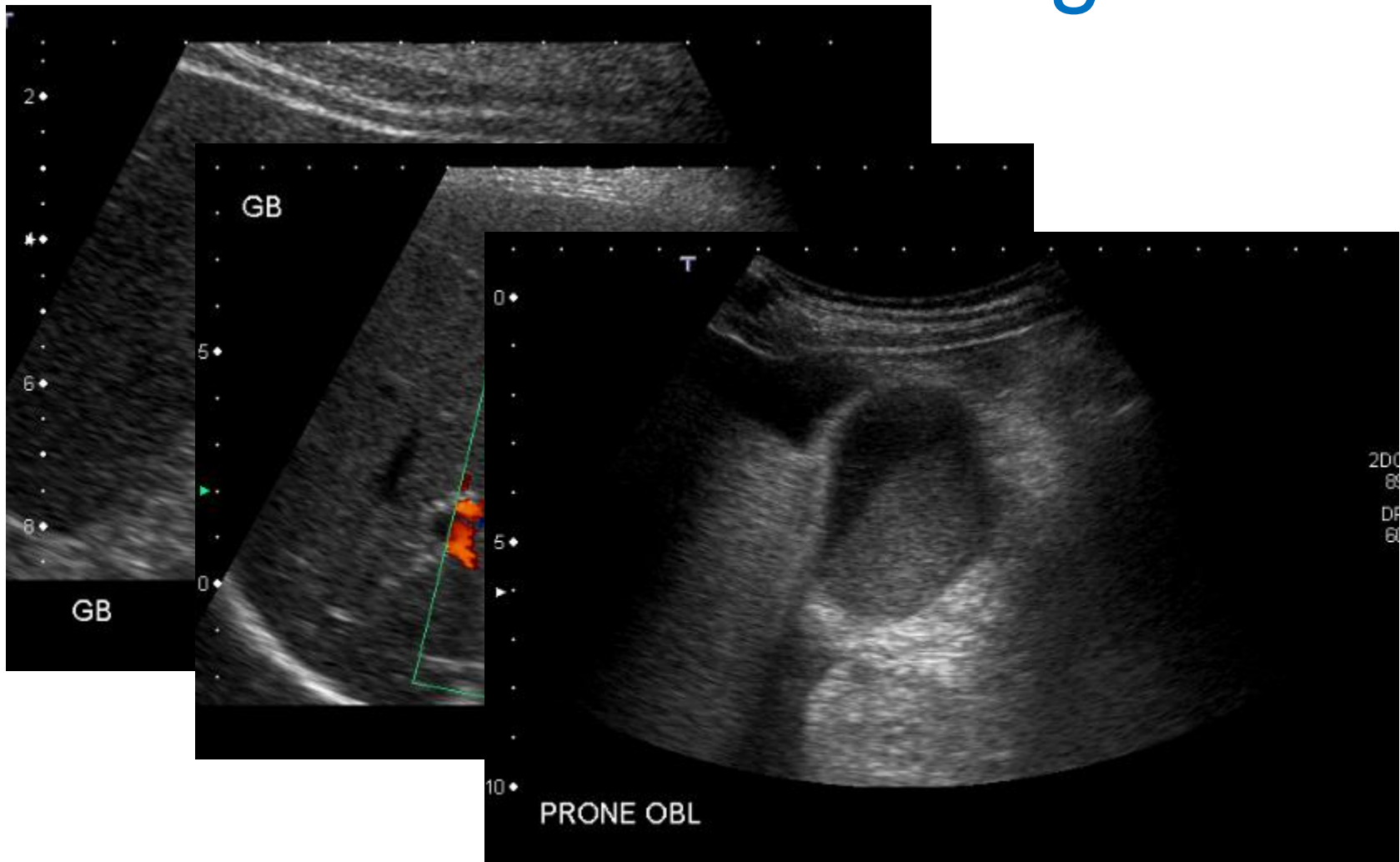
Cholecystitis Investigations

- FBC - the WCC is likely to be raised.
- Liver enzymes are often mildly abnormal.
- Ultrasound findings for cholecystitis:
 - Include a thickened GB wall (greater than 3 mm) and may also include pericholecystic fluid or air in the GB or the GB wall.
 - If the GB wall is thickened but there are no gallstones present then the diagnosis could still be acalculous cholecystitis

Cholecystitis

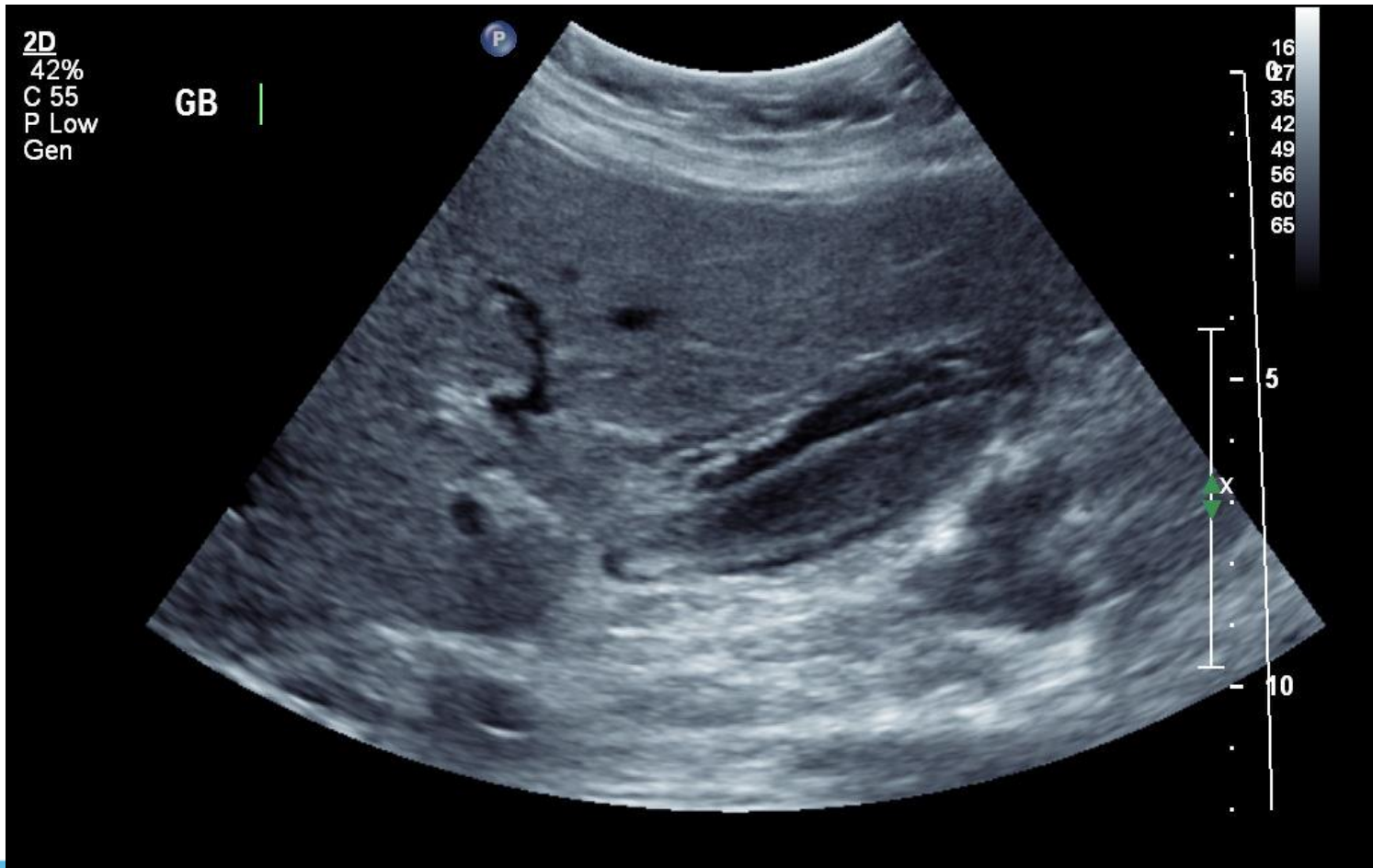


Additional Findings



Pitfall Alert

Mural oedema, but not cholecystitis



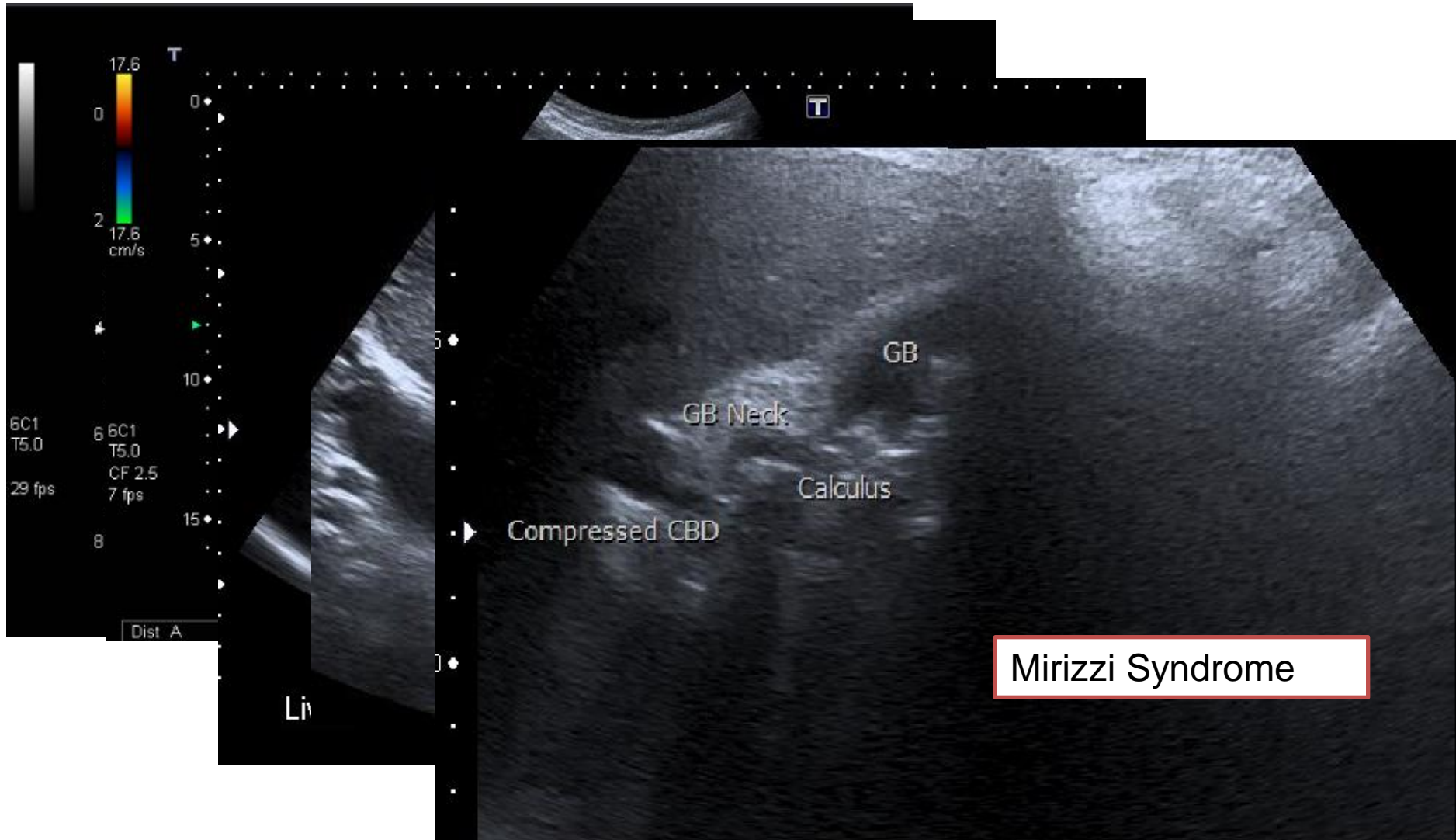
Causes of GB wall oedema

- Physiological
 - post prandial
- Inflammatory
- Adjacent disease
- Non-inflammatory
 - adenomyomatosis, cancer, leukaemia, mets
- Generalised oedema
 - Ascites, organ failure, portal hypertension
- Varices

Complications of Gallstones

1. Obstructive jaundice
2. Cholangitis
3. Severe Perforated Cholecystitis
4. Pancreatitis
5. Gallstone ileus
6. Chronic Cholecystitis

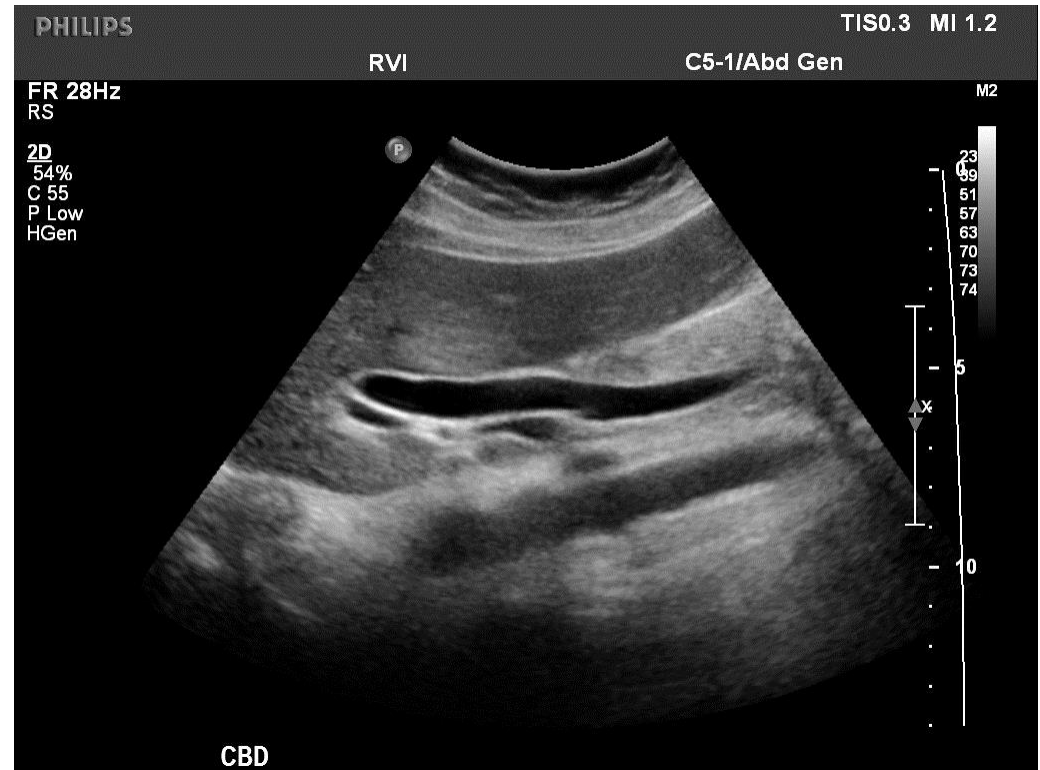1: Obstructive Jaundice



Pitfall Alert

Measuring the duct

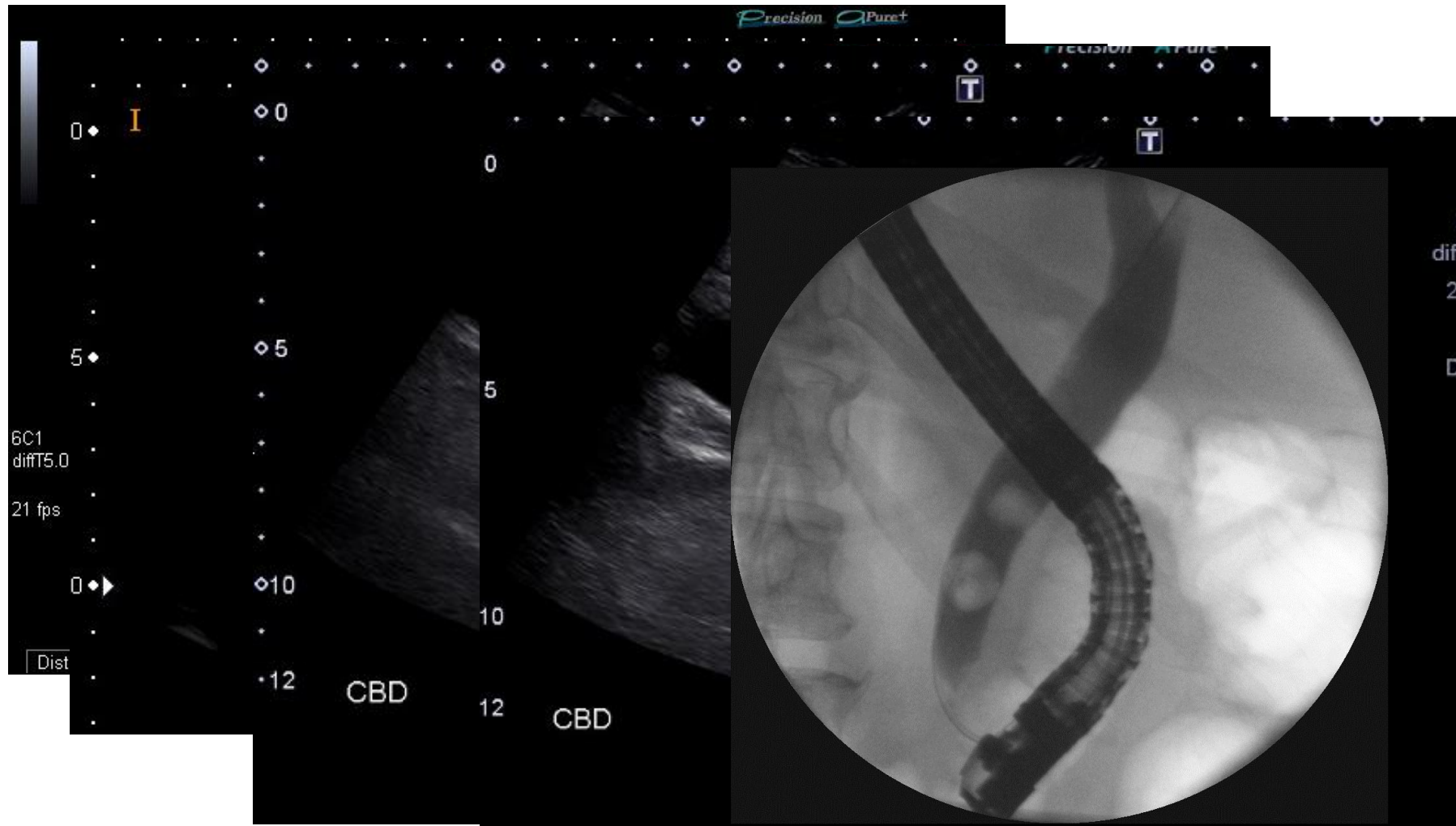
- What is normal?
- Does size matter?
- Enlarges with age, bile duct disease (?cholecystectomy)
- Should taper to pancreatic head
- Symptomatic vs Incidental



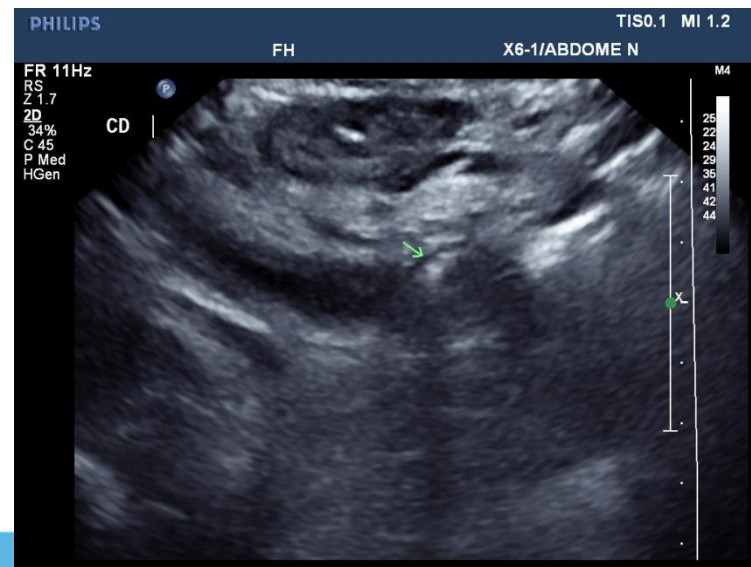
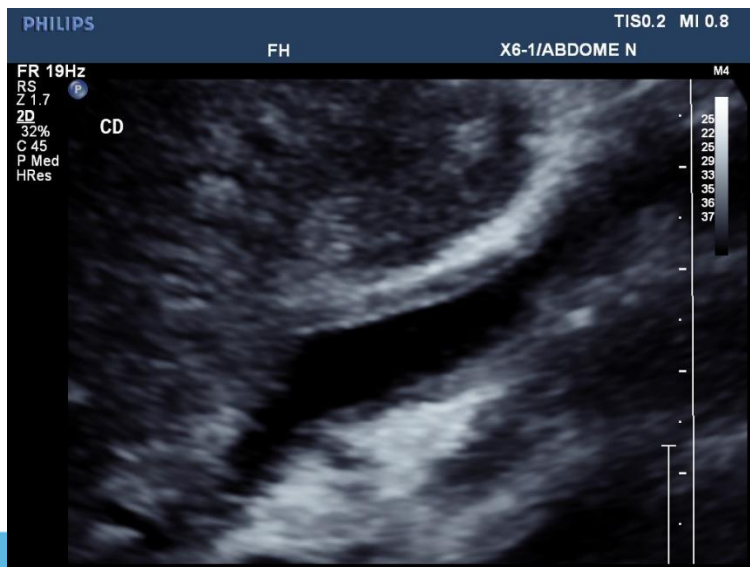
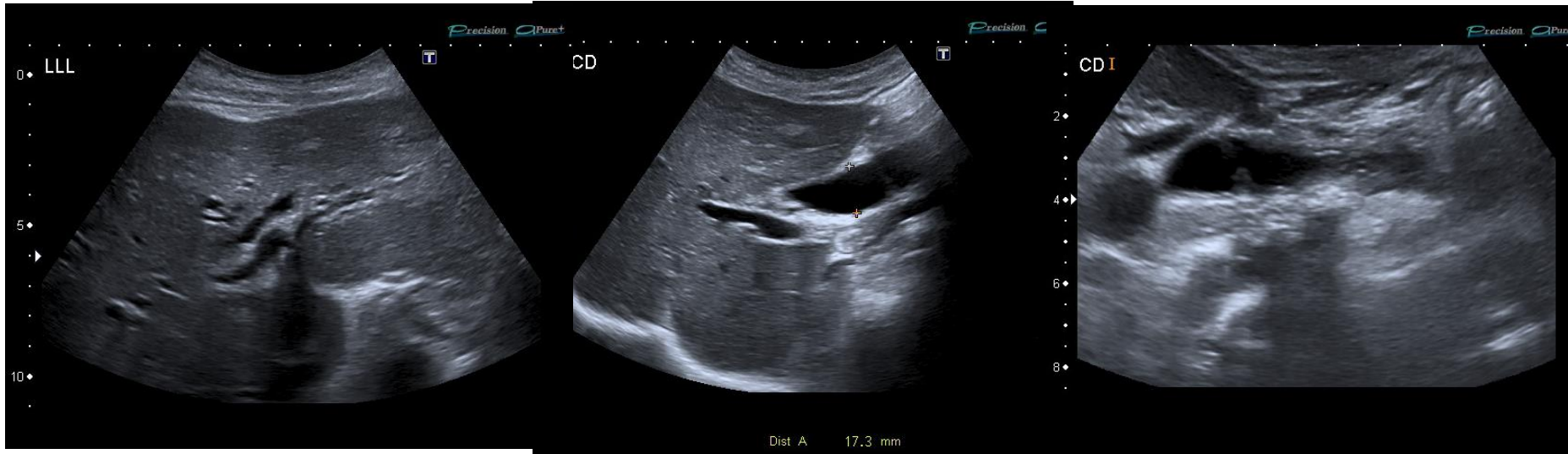
Why do we care about a big duct?

- Because it might represent obstruction
- Because of the possible causes...
 - Cancer
 - Stones
 - Inflammation/Stricture
- Because of the possible consequences
 - Cholangitis
 - Obstructive jaundice

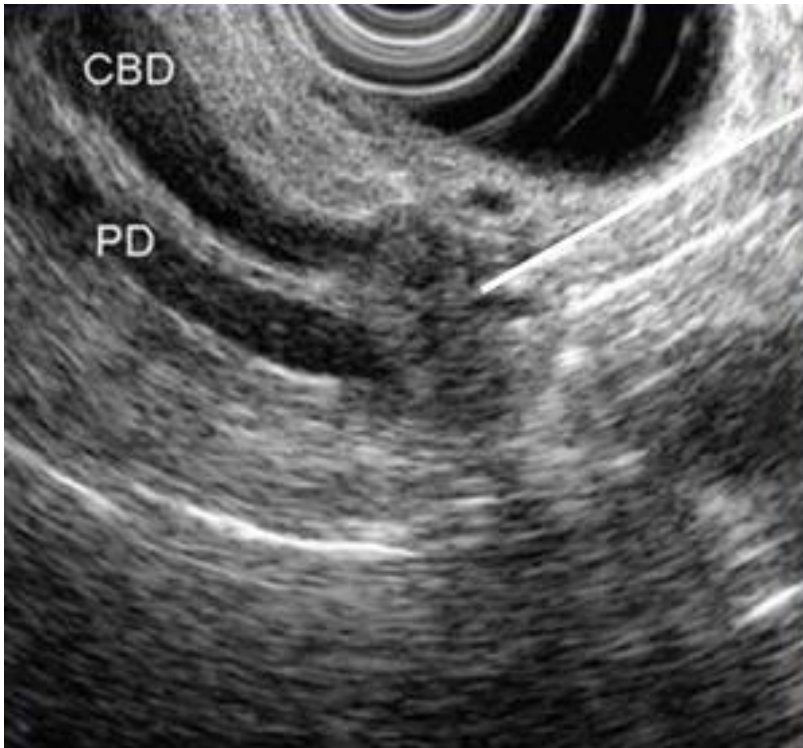
So if you see a big bile duct...



So if you see a big bile duct...



Endoscopic US



- Staging malignancy of hollow organs
- Chronic pancreatitis
- Pancreatic mass evaluation

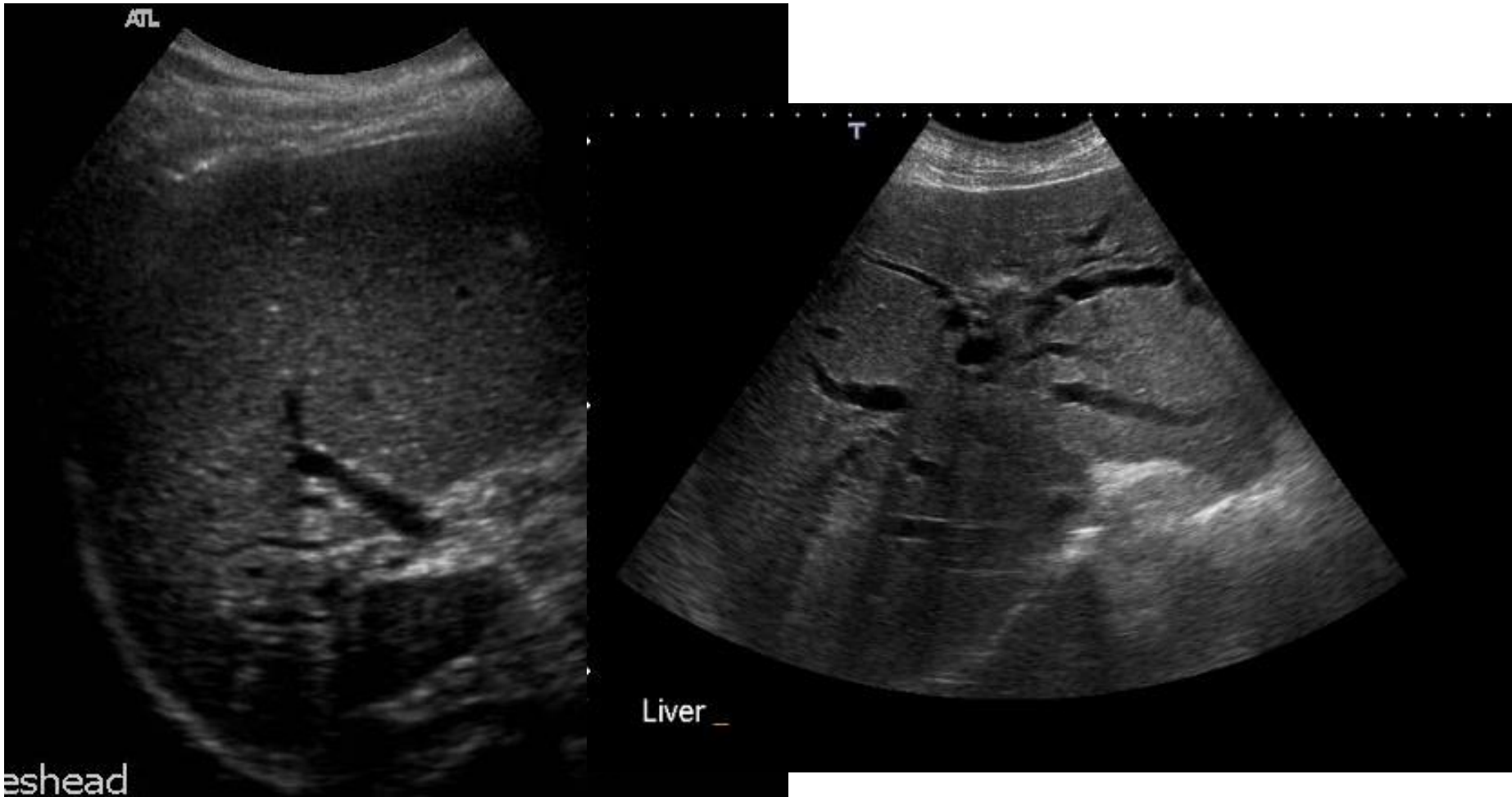What about the incidental big duct?

- Overall clinical picture
- Overall radiological picture
 - Intrahepatic ductal dilatation?
 - Good views of pancreas?
- Old imaging – any cross-sectional modality

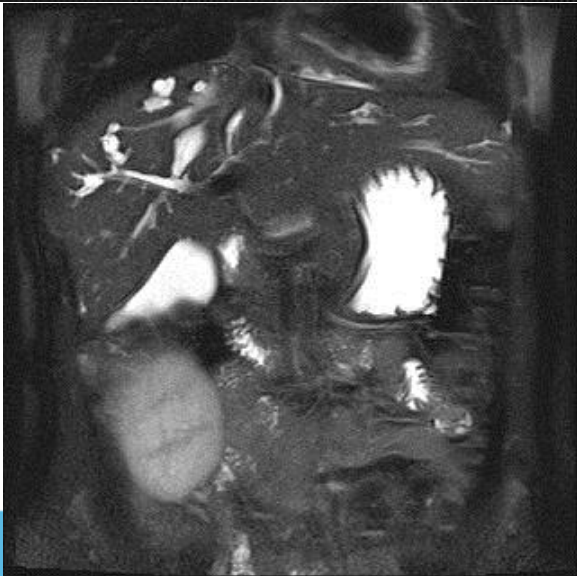
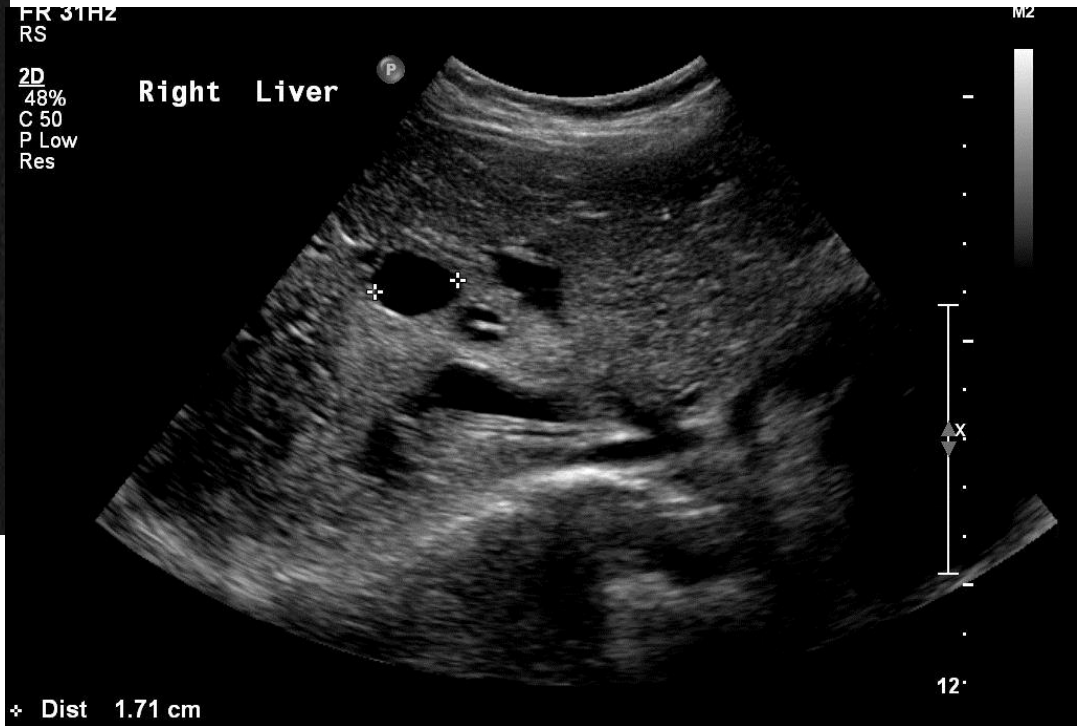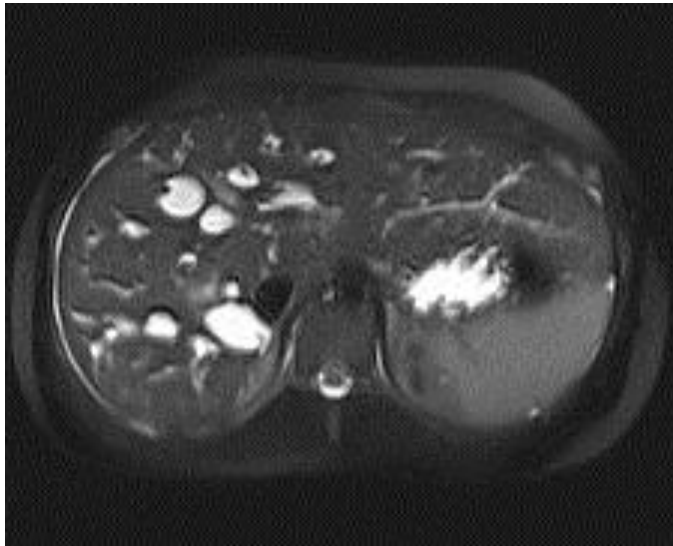
Intrahepatic Ducts

- Complex 3D shape
- Subjective
- Confounders
 - Arterial hypertrophy in cirrhotics
 - Saccular dilatation

Segmental Intrahepatic Biliary Dilatation



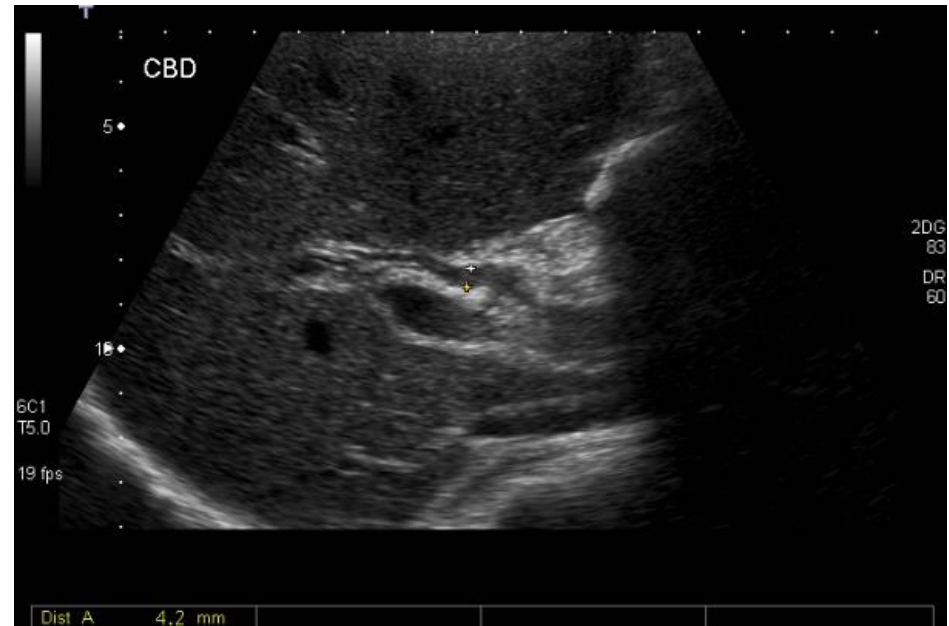Liver Cysts v Duct dilatation



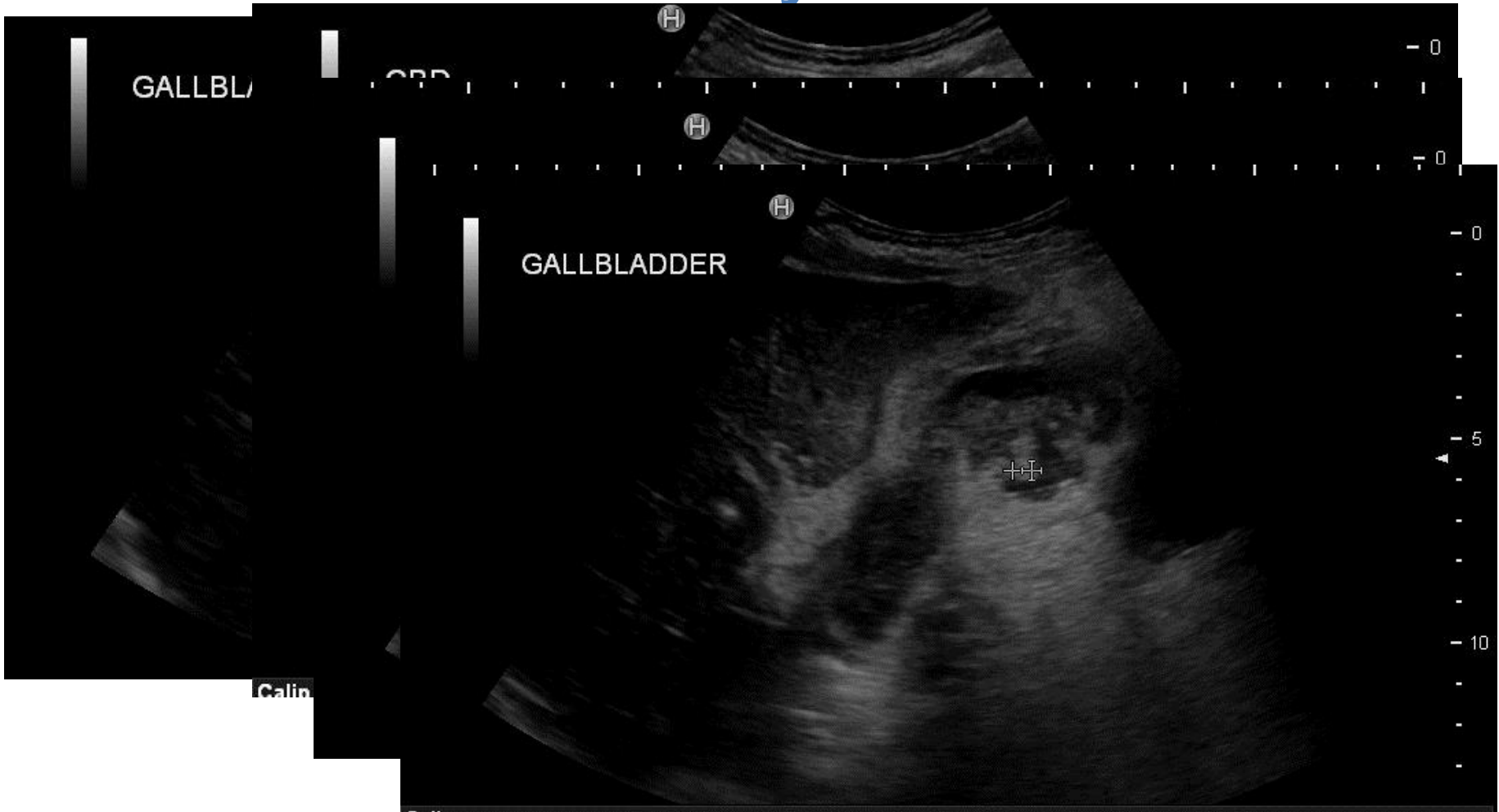
Central dot sign in Caroli's Disease
(dilatation or ectasia of the bile
ducts)

2: Ascending Cholangitis

- Charcot's triad:
Infected CBD leading to jaundice and high swinging fevers with rigors and chills
- Retrograde infection up the CBD as a result of acute cholecystitis or ERCP



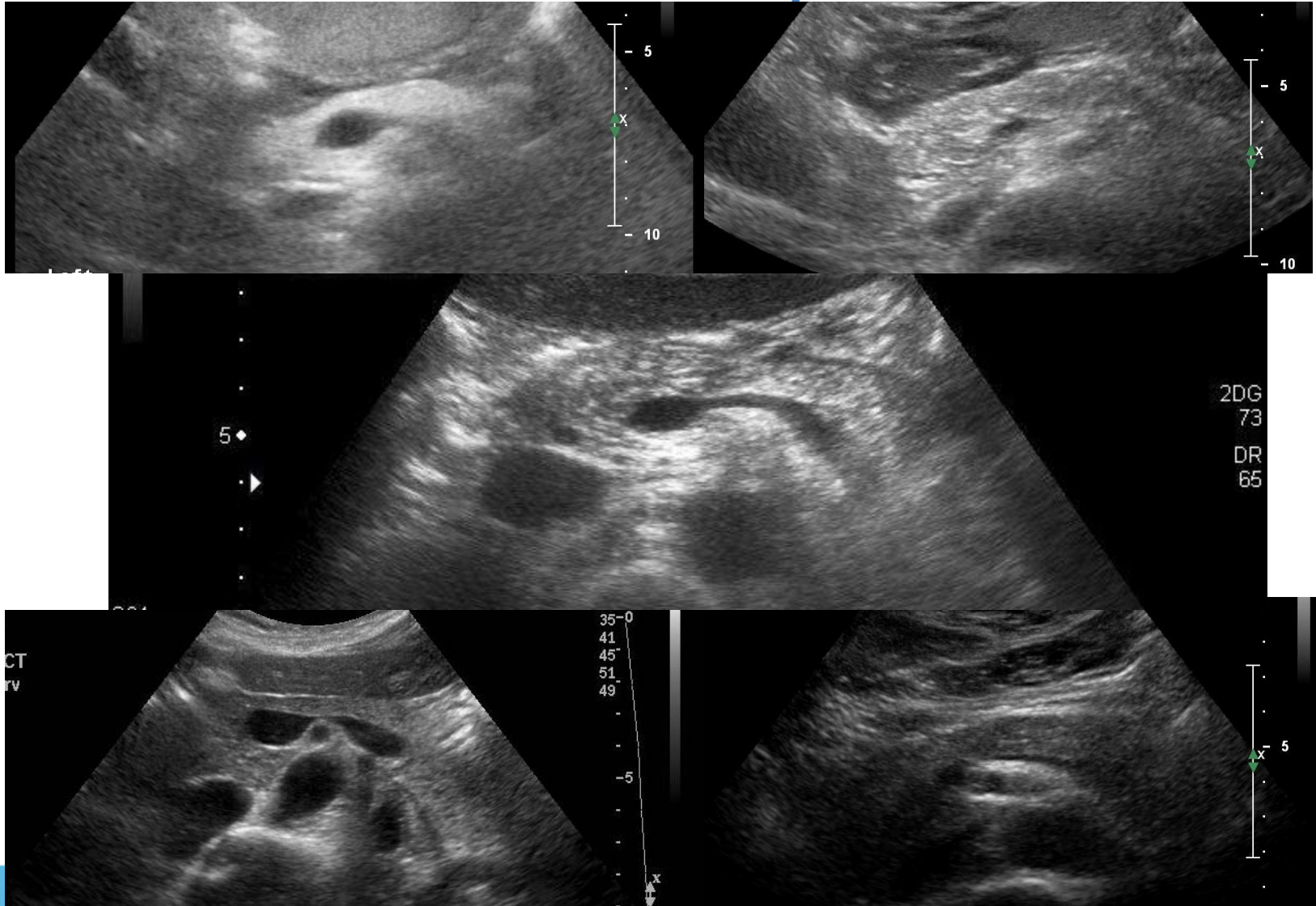
3: Severe, Perforated Cholecystitis



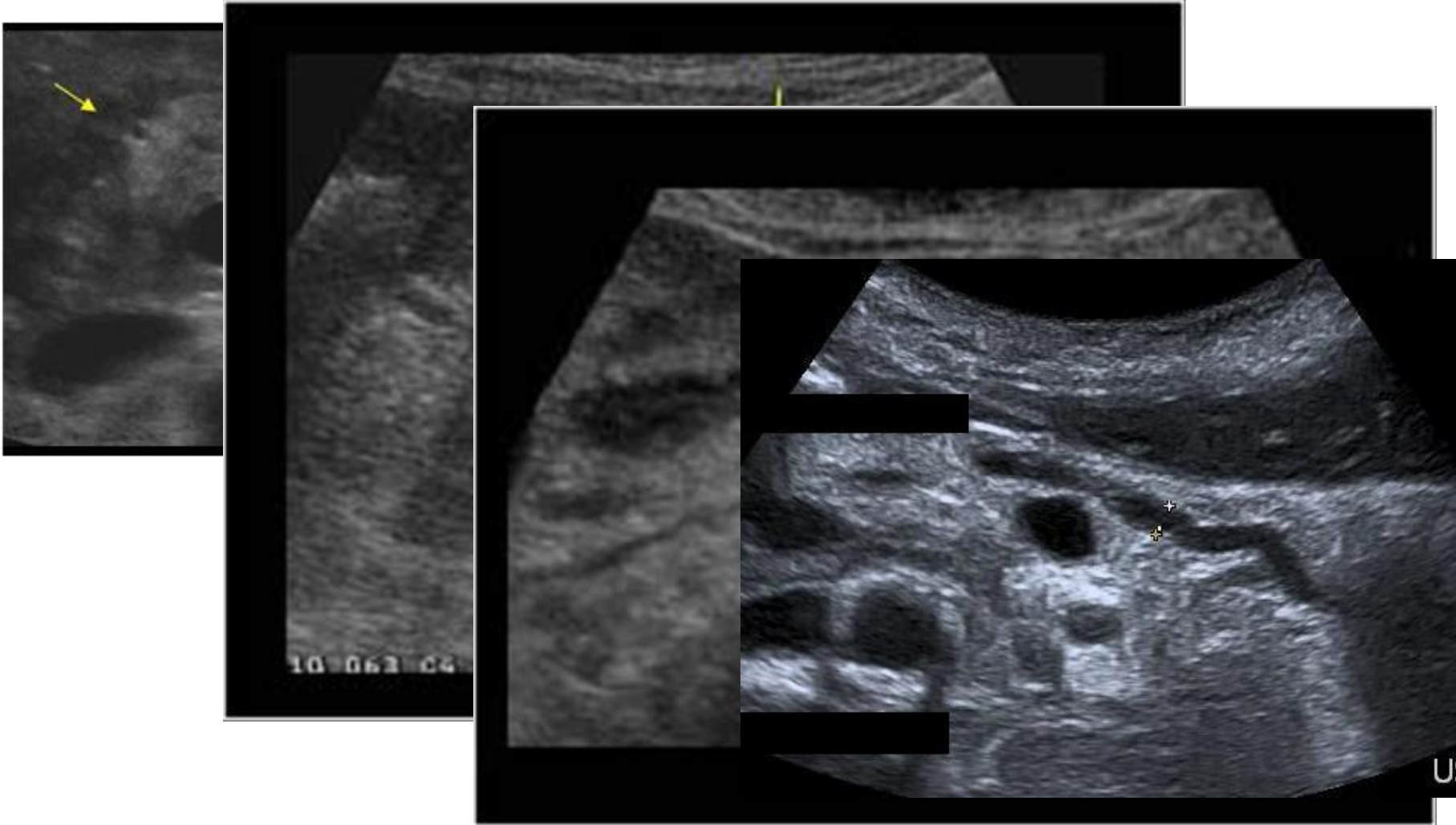
4: Pancreatitis

- Gallbladder disease and excess alcohol consumption account for most cases and typically cause periductal necrosis.
- Gallstones cause pancreatitis by blocking the bile duct, causing back pressure in the main pancreatic duct

Normal Pancreas – 50 Shades of Grey



Pancreatitis



5: Gallstone ileus

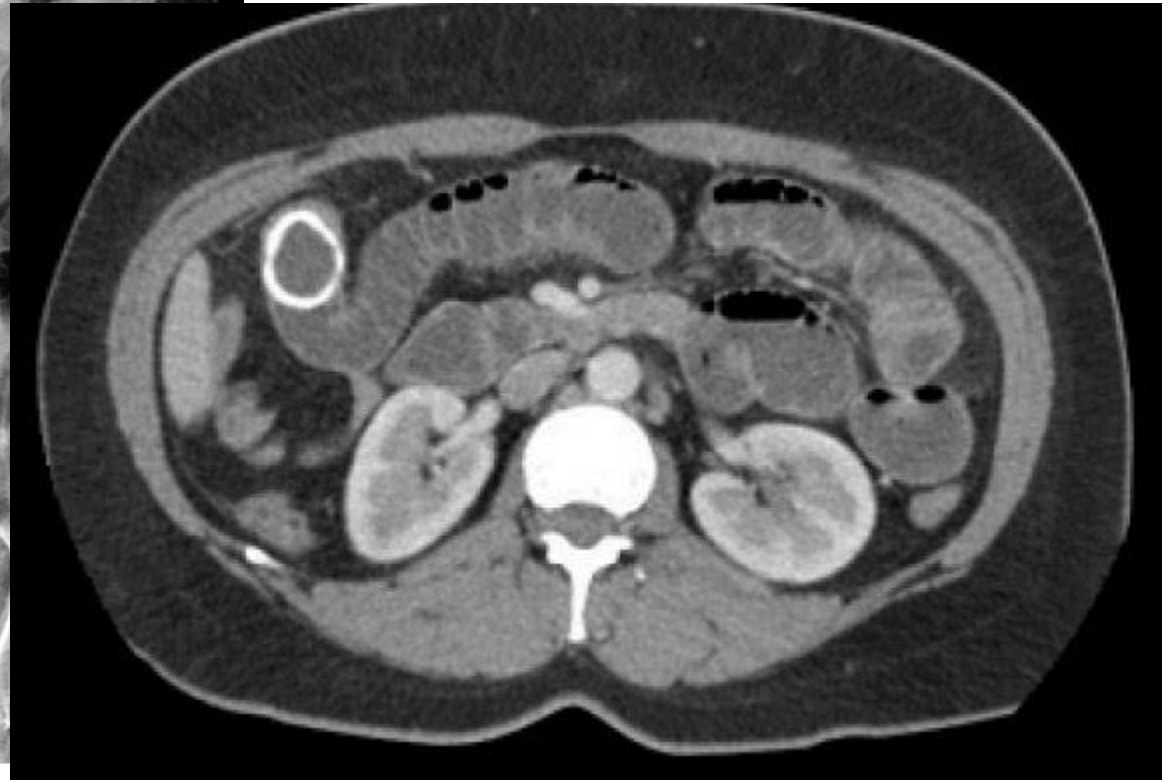
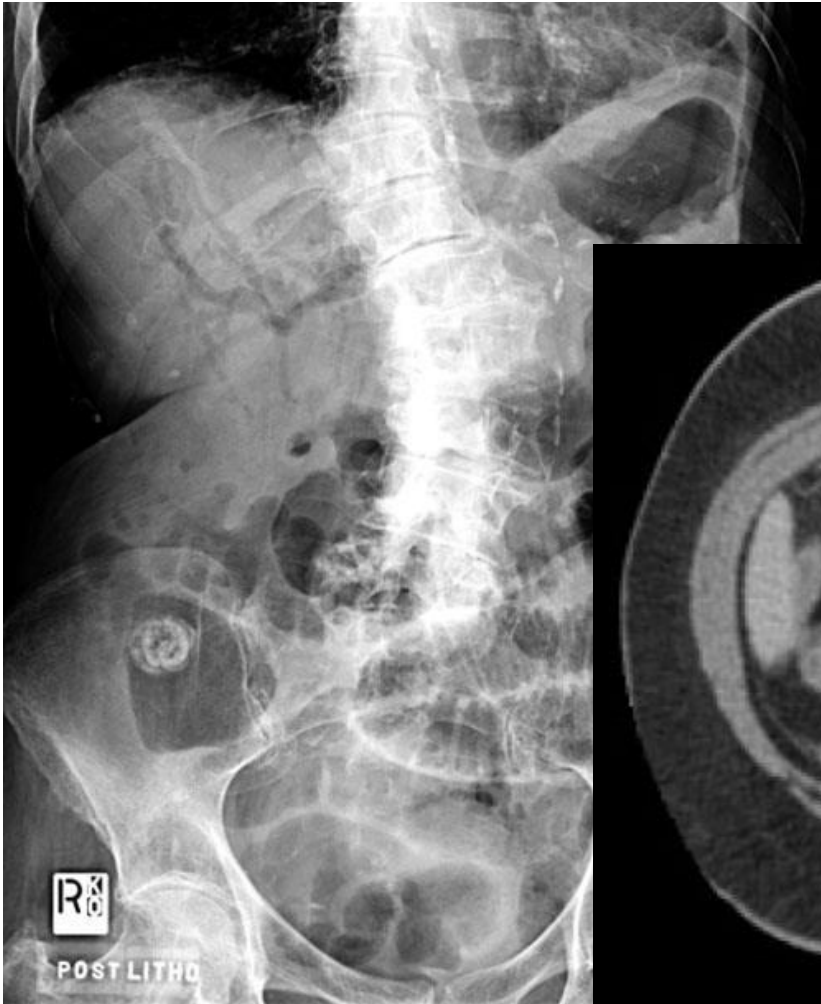
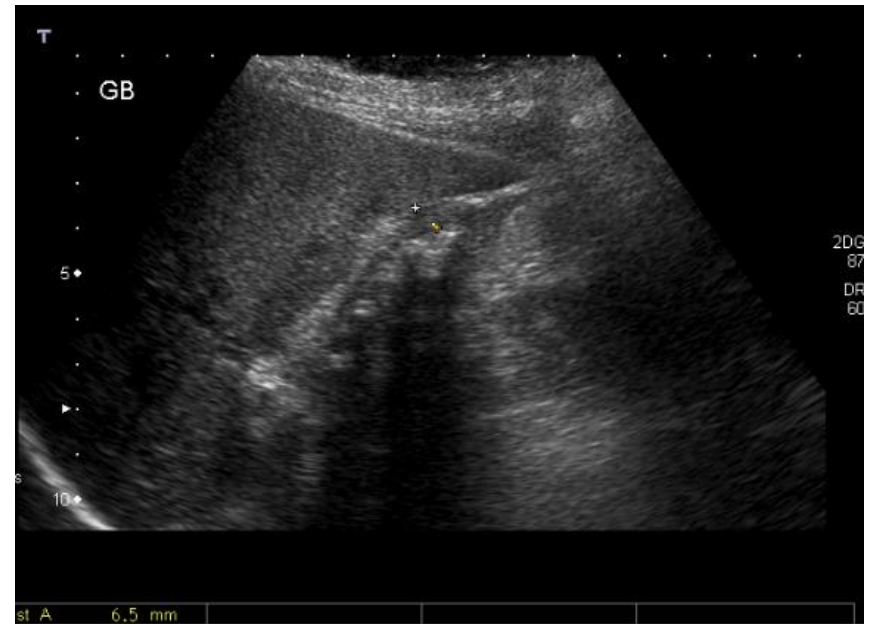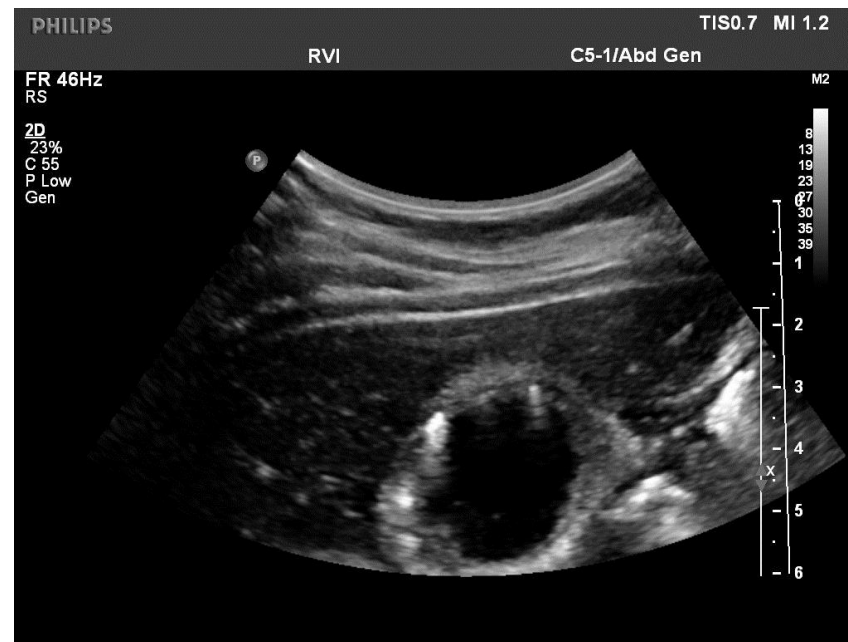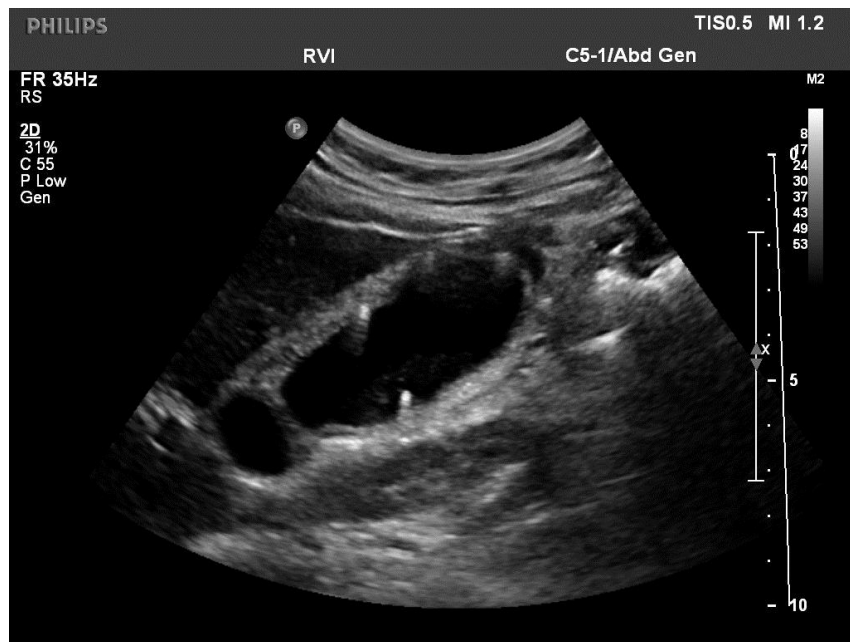Figure) Gallstone ileus pre-lithotripsy

6: Chronic Cholecystitis

- GB Walls irregularly thickened
- Hyperechoic
- Fibrosed
- Complicated by episodes of acute on chronic cholecystitis

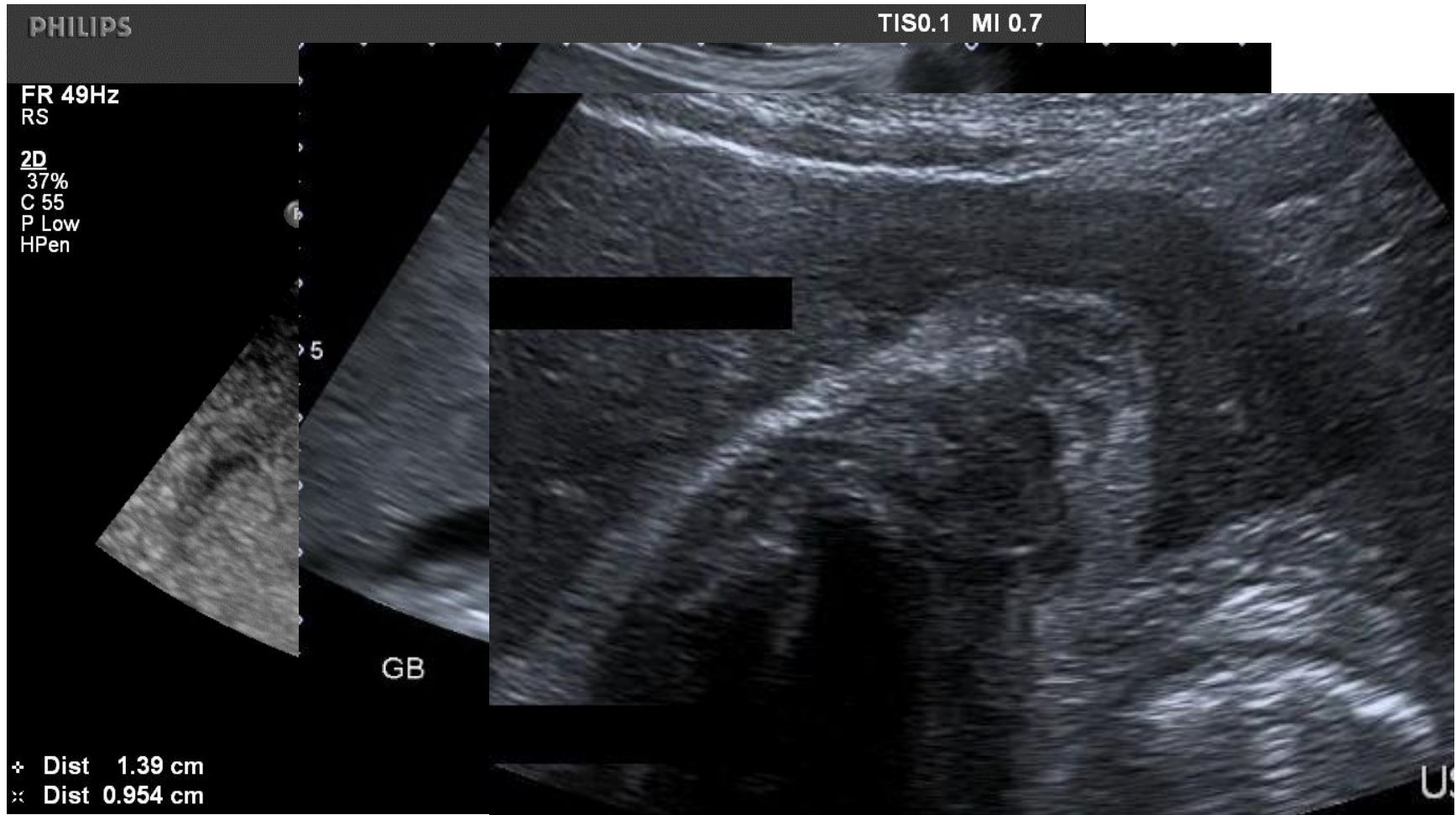


6: Adenomyomatosis



- Benign condition associated with stone disease and strictures
- Wall thickening, solid nodules often at the fundus, shadowing from Rokitanski-Achoff sinuses
- Surgeons tend to take out symptomatic gallbladders

6: Focal Adenomyomatosis



What are you going to report?

- **Clinical history: Admitted RUQ pain, jaundice and puritis. Mr ***** would like an US to look at CBD. Bil 148, ALP 521 and ALT 201.**

- **US ABDO**

The liver appears normal in size and shape with a homogenous echo pattern. No focal lesions identified. Normal hepatopetal flow shown in the portal vein. Pneumobilia again noted.

Cholecystectomy noted. The common duct is dilated measuring 17mm and intrahepatic duct dilation is present around the porta. There appear to be some filling defects in the CBD.

The right kidney appears normal. Left parapelvic cyst again seen. The pancreas was obscured by overlying bowel. No free fluid.

- **Patient went on to have CT then MRCP...**

Learning Points

- Clinical History
 - Acute, spasmodic, WCC
- Previous history
 - Previous cholecystectomy?
- Gallstones present – now what?
 - Wall thickness, oedema, pain
- Big ducts
 - Why? Intraductal Stones
- Pancreas
 - Secondary Signs

Biliary Tree Ultrasound in a Nutshell

- **Fantastic**
 - Common duct
 - Gallbladder and stone disease
 - Pancreatic Cancers (!)
- **Tricky**
 - Intrahepatic ductal pathology
 - Differentiating cancer from inflammation
 - Handling the incidentally dilated common duct
- **Think beyond the gallstone**