

# Role of Nonsurgical Chin Augmentation in Full Face Rejuvenation: A Review and Our Experience

MONIQUE J. VANAMAN WILSON, MD,\* ISABELA T. JONES, MD,† KIMBERLY BUTTERWICK, MD,‡  
AND SABRINA G. FABI, MD, FAAD, FAACS‡§

---

**BACKGROUND** The chin is a critical component to the perception of facial attractiveness. Dermal fillers offer a nonsurgical, temporary method of correcting mild to moderate chin retrusion and resorption. Thus far, discussion of this procedure has been largely limited to the plastic surgery and otolaryngology literature.

**OBJECTIVE** To review pertinent aspects of anatomy, patient evaluation, injection technique, concomitant therapies, and complications in chin augmentation using injectable fillers.

**METHODS** A brief review of the literature surrounding chin augmentation using injectable fillers, as well as the authors' experience in this area, is provided.

**RESULTS** Chin augmentation using injectable fillers can be performed effectively and safely with adequate background knowledge of the regional anatomy and appropriate patient selection. The authors discuss both injection techniques in the published literature and their own approach. Potential complications and concomitant therapies are also reviewed.

**CONCLUSION** As chin augmentation is increasingly recognized as an essential component to complete facial aesthetic rejuvenation, dermatologic surgeons should be familiar with how to safely and effectively perform augmentation with injectable fillers to achieve an optimal cosmetic outcome.

*The authors have indicated no significant interest with commercial supporters.*

---

The chin is a critical element to facial proportion and, thus, to the perception of attractiveness. The aging face shows a significant decrease in matrix nanocrystallites, osteons, and osteocytes throughout the entire skull, including the mandible, by age 35 years.<sup>1-4</sup> Loss of mandibular height and length leads to an obtuse mandibular angle, chin retrusion, and an exaggerated prejowl sulcus.<sup>5</sup> Despite geographic and gender differences in chin morphology, chin appearance has been linked with not only attractiveness but also the perception of youthfulness.<sup>6-8</sup> Thus, a complete facial rejuvenation approach should include chin augmentation for those with retrusion and correction in those that present for facial rejuvenation.<sup>8,9</sup>

Options for chin augmentation include surgical genioplasty, alloplastic implants, autologous fat transfer, and injection of dermal fillers. The American Society of Plastic Surgery reports that 16,668 surgical chin augmentations were performed in 2016, a decline of 4% compared with 2015 and 38% compared with 2000.<sup>10</sup> The reasons for the decline in surgical mentoplasty are unclear, but it is likely partially due to the increasing popularity of minimally invasive treatment options. Determining the best procedure for a patient requires careful consideration of a patient's anatomy, as well as the risks and benefits of each treatment. Dermal fillers offer a nonsurgical, nonpermanent method of correction of chin retrusion in the appropriate patient.

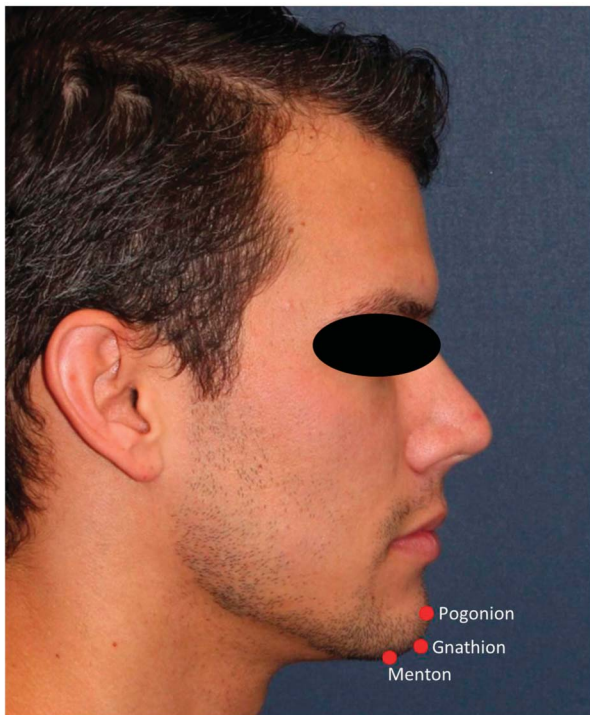
\*California Skin Institute, Sunnyvale, California; †McLean Dermatology and Skincare Center, McLean, Virginia; ‡Cosmetic Laser Dermatology, San Diego, California; §Department of Dermatology, University of California, San Diego, California

© 2018 by the American Society for Dermatologic Surgery, Inc. Published by Wolters Kluwer Health, Inc. All rights reserved.  
ISSN: 1076-0512 • Dermatol Surg 2018;00:1-9 • DOI: 10.1097/DSS.0000000000001461

**Anatomical Considerations**

The chin can be described using surface landmarks. The pogonion is the most anteriorly projected point on the chin, whereas the menton is the most inferiorly projecting. The gnathion is the midpoint between the pogonion and menton (Figure 1).

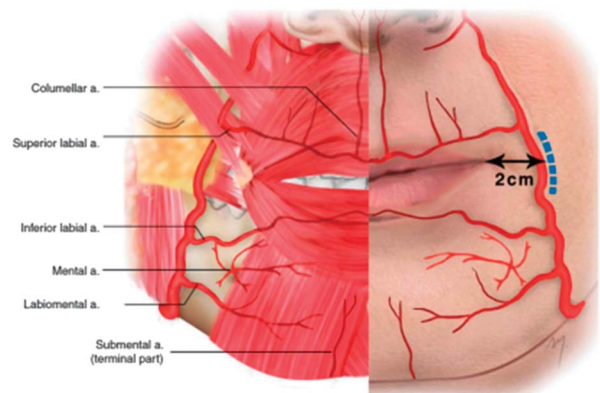
The chin exists as a well-defined compartment bounded by the mentolabial groove superiorly, the labio-mandibular grooves laterally, and the submental ligaments inferiorly.<sup>11</sup> This chin compartment is distinctly demarcated from the jowl and submental compartments. The skin in this area is thick, measuring 2,000 to 2,5000 μm in adults.<sup>12</sup> Deep to this is dense subcutaneous fat that is firmly attached to both the skin and the underlying musculature. From superficial to deep, the muscles of the chin are the depressor anguli oris (DAO), depressor labii inferioris (DLI), and paired mentalis centrally. The fibers of the DAO and DLI are interlaced with those of the platysma. Deep to the chin musculature is the mandible, which serves as the bony support for the area.



**Figure 1.** The pogonion is the most anteriorly projected point on the chin. The menton is the most inferiorly projecting point. The gnathion is the midpoint between the pogonion and menton.

The arteries of the chin and lower lip are highly anastomotic and are variable in pattern and location (Figure 2). The mental arteries are terminal branches of the inferior alveolar arteries which are themselves branches of the maxillary artery. The mental arteries serve as the primary blood supply to the chin, and exit the mental foramina on either side of the lateral chin at the second bicuspid, or approximately the mid-pupillary line. Further blood supply is derived from the inferior labial artery and labiomentary artery. The labiomentary artery may branch off the facial artery or the inferior labial artery, pass between the DLI and orbicularis oris muscles, eventually coursing superficially to be submucosal in the lower lip.<sup>13</sup> Similarly, after branching from the facial artery, the inferior labial artery runs deep to the DAO, coursing to the submucosal plane along the vermilion border of the lower lip.<sup>14</sup> The submental artery is the largest of the cervical branches of the facial artery and arises as the facial artery exits the submandibular gland. The submental artery then runs anteriorly over the mylohyoid, just below the body of the mandible, and then crosses over the mandible near the mandibular symphysis. This artery gives rise to the vertical labiomentary artery, which has both superficial and deep branches.

The inferior alveolar nerve travels through the mandible to exit as the mental nerve through the mental



**Figure 2.** Illustration of the arterial supply to the chin with the DAO removed. (Reprinted with permission from Springer: Vasiliou K. Thomaidis, MD, DDS, PhD. Cutaneous Flaps in Head and Neck Reconstruction: From Anatomy to Surgery, Lips and Chin. 2014; p. 265). DAO, depressor anguli oris.

foramen and provides sensory innervation to the chin and lower lip.<sup>15</sup>

## Evaluation

Many patients with chin retrusion are not aware that they have the condition. In fact, it is common for patients seeking rhinoplasty to have overlooked chin retrusion, as a small chin in patients with an appropriately sized nose can give the relative impression that the nose is large.<sup>16</sup> Similarly, many patients presenting for midface augmentation secondary to zygomatic and maxillary resorption do not recognize that the entire skull, including the mandible, resorbs to a degree as a function of age. When rejuvenating the midface, focus and attention needs to be given to the lower face, as well, to maintain aesthetic proportions. Counseling patients about the importance of facial proportions in aesthetics can call attention to previously overlooked chin retrusion and set realistic expectations of treatment.

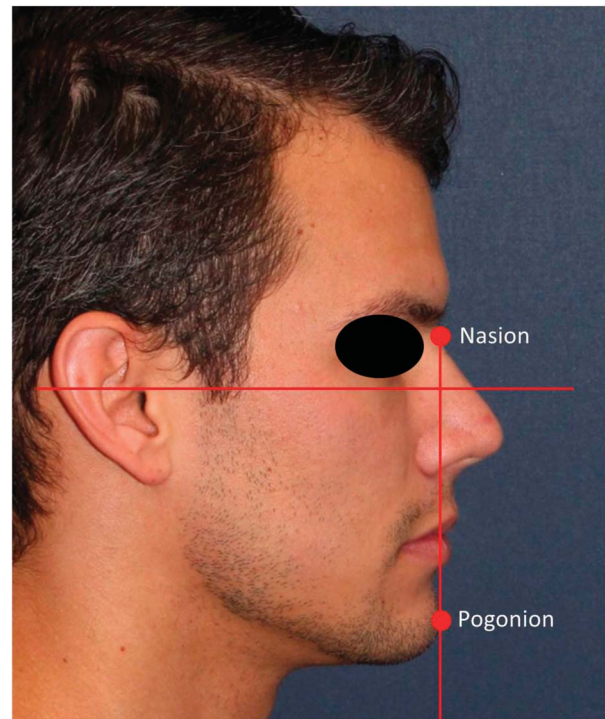
Careful aesthetic evaluation of the patient is necessary to determine whether chin augmentation with fillers is appropriate. Patients should be examined both at rest and with animation. Photographs should be taken in the anteroposterior, oblique, and lateral positions. Video recordings of the patient in animation are also helpful in assessment and post-treatment follow-up to ensure a natural-appearing result.

A simple validated scale exists to grade chin projection, but it only accounts for anterior projection in the sagittal plane. The contour, vertical height, and transverse width of the chin must also be considered, in addition to other aspects of the lower face such as morphology of the labiomental sulcus and volume of the lateral chin (i.e., prejowl sulcus).<sup>17-19</sup> The nose, lips, and teeth should also be considered because they are integral in creating an aesthetically harmonious appearance.

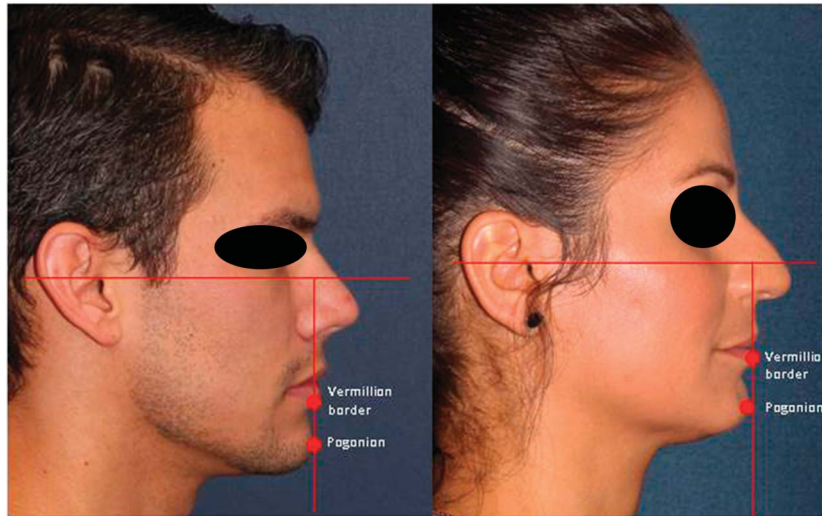
There are many guidelines regarding the ideal chin projection in the sagittal plane. The Gonzalez-Ulloa line is a vertical line that extends down from the nasion perpendicular to the Frankfurt plane, which is a line extending from the inferior orbital rim to the superior

margin of the external auditory meatus (Figure 3). An ideal chin is thought to meet, or fall just short of, this line and should not project beyond it.<sup>20,21</sup> Another easy and reproducible clinical method of evaluation is the Silver method, which requires a vertical line perpendicular to the Frankfurt plane from the vermilion border of the lower lip (Figure 4). An ideal male chin will meet this line at the pogonion, whereas the female chin should fall just short of this line.<sup>16,22</sup> Perhaps the simplest guideline many clinicians use is that the chin should project approximately as far as the lower lip in men, whereas the lower lip should project 1 to 2 mm beyond the chin in women.

Vertical chin height should also be considered in relation to the entire face. As a general rule, the upper third (extending from the hairline to the nasion), middle third (from nasion to subnasale), and bottom third (subnasale to the menton) of the face should be equal in height. An alternative method of analyzing chin height is to consider that the distance from the subnasale to the stomion superius (inferior margin of the vermilion of the upper lip) should ideally be one-



**Figure 3.** The Gonzalez-Ulloa line consists of a vertical line extending down from the nasion perpendicular to the Frankfurt plane. An ideal chin is thought to meet, or fall just short of, this line.



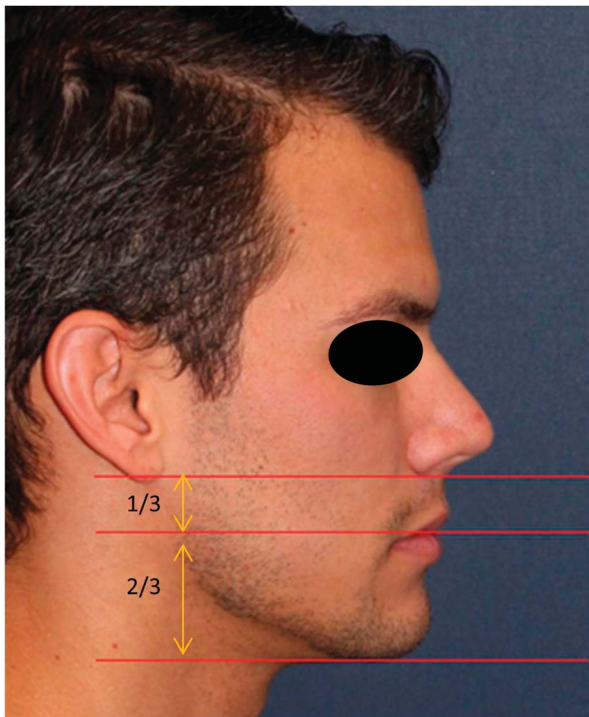
**Figure 4.** The Silver method uses a vertical line perpendicular to the Frankfurt line from the vermilion border of the lower lip. An ideal chin will meet, or fall just short of, this line at the pogonian.

third of the distance from the subnasale to the menton (Figure 5).<sup>22</sup>

Ideal transverse width of the chin is largely dependent on sex and ethnicity. An approximate guideline is that the chin should span the distance between the medial

canthi in female patients, whereas it should extend to the oral commissures in males.

Of course, these idealized proportions should only be used as a guideline for analysis as patient preferences, sex, ethnicity, and overall facial anatomy can influence the goal of aesthetic treatment. It has been suggested that chin retrusion up to 4 mm is clinically unnoticeable and likely does not warrant surgical intervention.<sup>7</sup> Mild to moderate retrusion may be more amenable to correction with dermal fillers, whereas more significant retrusion (greater than 10 mm) should be considered for surgical intervention.



**Figure 5.** When analyzing chin height, the distance from the subnasale to the inferior margin of the vermilion of the upper lip should ideally be one-third of the distance from the subnasale to the menton.

Alloplastic implants are best for those patients who have adequate vertical chin height but need more projection because implants can only produce significant changes in anterior projection.<sup>12</sup> Surgical genioplasty is a larger procedure that can correct both vertical and anterior deficiencies. Both of these surgical approaches involve extensive dissection and are thus subject to potential complications such as implant rejection or migration, scarring, infection, bone resorption, and mental nerve injury.<sup>22,23</sup> When compared with injection of dermal fillers, surgical approaches confer higher risk of significant complications and result in a permanent alteration of the chin, which may not look natural or appropriate as aging and mandibular bony resorption continue over the years.

By contrast, injectable fillers offer a nonsurgical, temporary alternative that requires no incisions. Fillers allow for correction of anterior, vertical, and transverse deficiencies, as well as treatment of adjacent structures such as lips, marionettes, and prejowl sulci.

### Technique

Fillers used for chin injection include hyaluronic acid (HA), autologous fat, calcium hydroxylapatite (CaHA), and poly-L-lactic acid (PLLA). The specific choice of filler depends on the patient's anatomy, injector preference, and cost as there are no data directly comparing these approaches for chin augmentation.

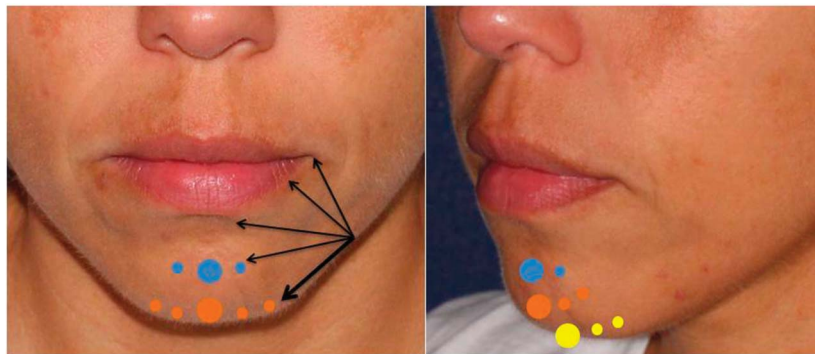
An analysis of patients who underwent autologous fat grafting for the chin by Wang and colleagues<sup>23</sup> found that this was an effective method of producing sustained improvement in anterior projection to a maximum of 3 to 5 mm. However, the ability of fat to produce an improvement in vertical height was limited when assessed by injectors and patient satisfaction. In this study, the authors injected autologous fat through blunt cannula in a multilayered fashion both submuscularly and subcutaneously. Injections were first performed to increase the anterior dimension of the chin. Then the vertical dimension was addressed, if necessary, by locating the menton and moving it inferiorly using the multilayered technique. The authors then performed tapered injections toward the jawline on either side. Patients underwent up to 3 injections. The drawbacks of this approach, according to the authors, are the variability of fat graft survival

and the relative lack of improvement in the vertical dimension of the chin.

Rho and colleagues<sup>24</sup> have described consensus recommendations regarding the technique for augmenting the chin with high-viscosity HA or CaHA in Asian patients. The authors recommend using 1 to 3 mL injected through needle or cannula into the supra-periosteal and subdermal planes. Needle injections are performed as vertical depots at the gnathion and slightly superolateral to the gnathion on either side. Augmentation using cannula is performed using a fanning technique through an entry site at the gnathion. The authors note that while anterior projection of the pogonion and menton is more easily achieved using needles, cannulas may reduce the risk of bruising.

In an 18-month, open label study of rejuvenation using an HA filler (Emervel Volume; Galderma SA, Lausanne, Switzerland) in subjects with facial volume loss, 15% required chin injection with a mean injection volume of  $1.1 \pm 0.9$  mL.<sup>25</sup> At 18 months, 98.3% of all study subjects were satisfied or very satisfied with their results.

Similarly, the authors (S.G.F. and K.B.) have found the use of high-viscosity HA and CaHA dermal fillers (Restylane Lyft; Galderma SA, Lausanne, Switzerland; Juvederm Voluma XC, Allergan, Inc., Parsippany-Troy Hills, NJ; Radiesse (+), Merz North America, Inc., Raleigh, NC) to be effective in improving the anterior, transverse, and vertical dimensions of the chin. The authors typically inject no



**Figure 6.** Authors' injection strategy for fillers in the chin, where larger dots indicate larger depots and black arrows indicate cannula fanning technique.

more than 1 to 2 mL of filler in a single injection session. If augmentation of the gnathion is needed, 0.1 to 0.2 mL of a high viscosity HA filler is injected as a depot (entering the chin in a direction i.e. 45° to the mental crease) through a needle placed supraperiosteally in the midline. Then, 2 to 3 smaller supraperiosteal depots are placed lateral to the midline injection on both sides to taper and round out the chin, respecting the transverse width proportions mentioned above (Figure 6).

The pogonion is then assessed, and if anterior projection is needed, 0.1 to 0.2 mL of a high-viscosity HA filler is injected as a horizontal supraperiosteal depot in the midline through needle, with 1 smaller volume injection performed lateral to this on both sides (Figure 7).

Vertical height is then assessed relative to the upper, middle, and lower thirds of the face. If augmentation is needed, 0.025 to 0.1 mL of a high-viscosity HA filler is injected supraperiosteally in the midline as a vertical depot through needle, with 2 to 3 smaller supraperiosteal depots injected lateral to the midline depot on both sides to taper and round out the chin, creating a smooth transition from the gnathion.

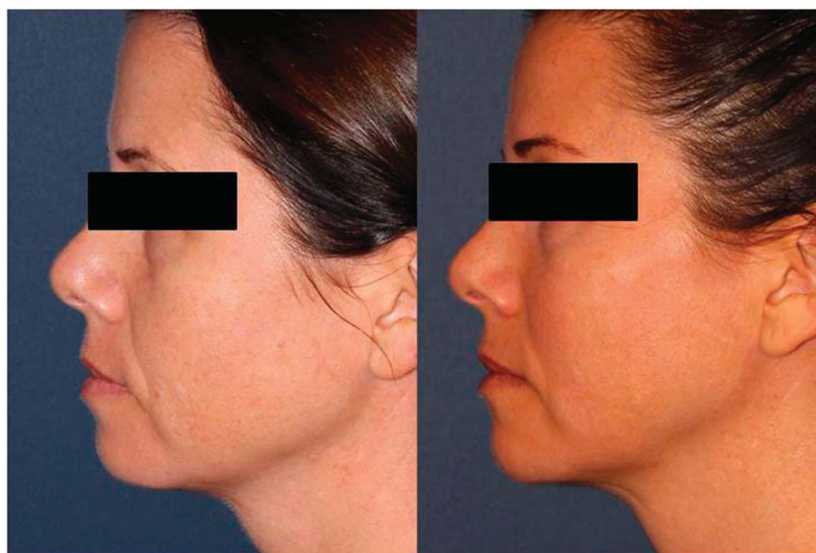A blunt-tipped 22 to 25 G, 1.5-inch cannula is then used to taper the projection that has been created to surrounding landmarks. A prejowl sulcus is softened by entering from the most lateral aspect of the sulcus and

placing a linear thread of filler deep to the DLI and DAO along the mandible to soften the sulcus. The cannula is then advanced to the pogonion and product is placed supraperiosteally using a fanning technique, moving deep to the DLI and DAO superolaterally to soften the transition between the pogonion and the mentolabial groove, as well as the labiomandibular grooves laterally. At times, a 28 G, 3/4 inch or 25 G, 1-inch needle is used instead of a cannula to perform a retrograde fanning technique. The authors prefer HA fillers when injecting with needles because of their reversibility in the event of an intra-arterial injection. HA and CaHA fillers are both used when injecting with a blunt-tipped cannula.

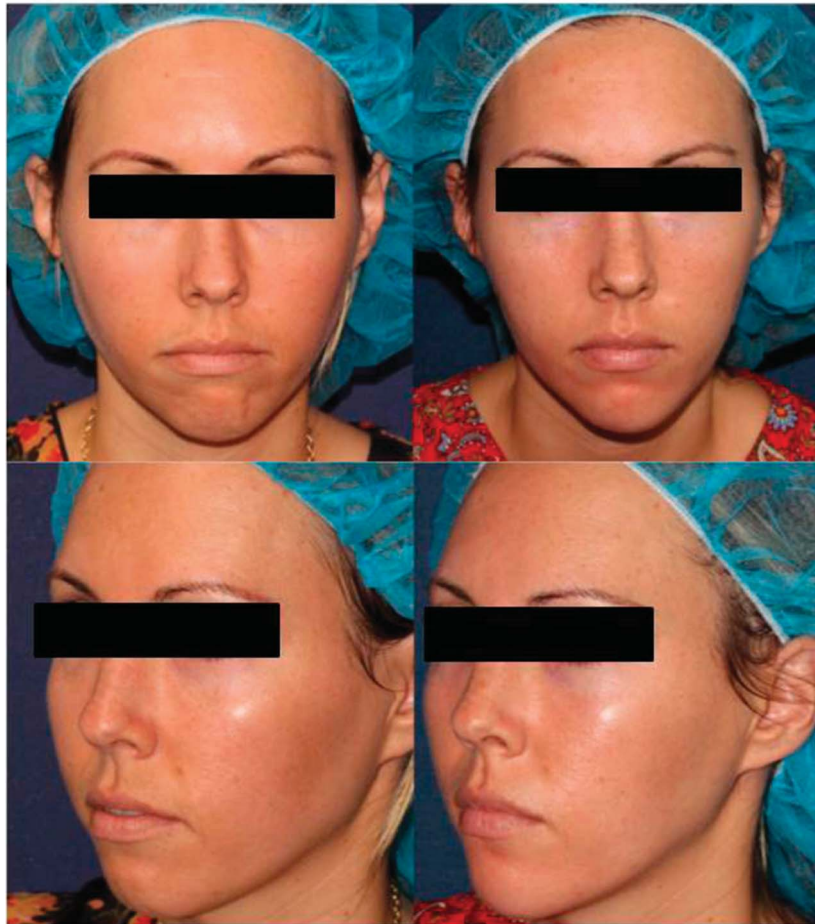### Complications

Chin augmentation with injectable fillers is subject to many of the same potential complications that can arise with use of fillers anywhere on the face. Swelling, bruising, delayed nodules, granuloma, and infection are possible and should be treated as they are in other locations of filler injection. As the skin on the chin is quite thick, contour irregularity with supraperiosteal injection is often not of particular concern. However, superficial injection of fillers may produce irregularity, especially with mentalis contraction and animation.<sup>24</sup>

Vascular compromise is quite rare but has been reported. Yuan and colleagues<sup>26</sup> described vascular



**Figure 7.** Thirty-eight-year-old woman with chin retrusion before (left-sided) and after injection (right-sided) of 0.8 mL of HA filler to the chin. HA, hyaluronic acid.



**Figure 8.** Thirty-one-year-old woman with chin retrusion before (left-sided) and after injection (right-sided) of 1 mL of HA filler to the chin, 4 U of onabotulinumtoxinA to the mentalis, and 36 U of onabotulinumtoxinA to the masseters. HA, hyaluronic acid.

compromise after injecting 0.1 mL of PLLA in the right lateral chin characterized by an immediate sensation of warmth extending to the lower lip and central chin numbness. The patient subsequently developed erosions on the mucosal lower lip, but ultimately healed without scarring. The authors suspected mental artery occlusion, but because of the anatomic variability and anastomoses in chin arterial circulation, it is unclear if the insult was to the mental artery, inferior labial artery, or labiomental artery. Suspected ischemic complications of chin filler injection should be addressed with hyaluronidase if appropriate, warm compresses, massage, and possibly topical nitroglycerin, although this remains controversial.<sup>27</sup>

### Concomitant Therapy

It is important not to consider the chin in isolation, but rather as just 1 part of the mandible that resorbs as

a function of age. For some patients, chin augmentation alone will not produce the aesthetic result they seek; in these cases, one should consider using concomitant therapies that address some of the most common issues in the lower face.

Volume loss of the posterolateral and angle of the mandible can be addressed by using HA, autologous fat, CaHA, and PLLA. A supraperiosteal injection at the inferoposterior angle of the mandible to accentuate the length of the jawline can be performed with either HA or CaHA, being mindful to not add width to the lower face in a woman that may already have a wide lower face. To masculinize and broaden the face in a man, HA or CaHA can be used subdermally over the masseter, being cautious not to inject into the parotid gland, potentially causing a sialocele. HA, autologous fat, CaHA, and PLLA can also be used along the length of the mandible, in the subcutaneous plane with

a blunt-tipped cannula, anterior to the masseter to create more prominent jawline. When using HA fillers or autologous fat for chin augmentation, the same products can also be used to treat adjacent and related areas such as the lips, oral commissures, marionettes, and mental crease.

It is especially important to keep the chin in mind when evaluating patients seeking lip augmentation as maintaining balance between the lips and the frame surrounding them, which includes the chin, is critical to facial harmony. For example, in women, the upper lip should ideally project 1 to 2 mm beyond the lower lip, whereas the lower lip should project 1 to 2 mm beyond the chin.<sup>28</sup>

Skin laxity and fat accumulation of the neck, jawline, and submental areas can exaggerate the appearance of a small chin and significantly blunt the cervicomental angle. Laxity may be safely and effectively addressed by radiofrequency and microfocused ultrasound with visualization technologies.<sup>29–31</sup> In patients with adequate skin thickness, minimally invasive subdermal suspension sutures can also be used. Fat in this area can be treated with liposuction or a series of deoxycholic acid injections or cryolipolysis.<sup>32</sup> Submental liposuction with tumescent anesthesia is a more invasive, but definitive and quicker, means of achieving results and can be especially effective when performed in combination with autologous fat enhancement of the chin.<sup>33</sup>

Platysmal bands, masseters, the mentalis, and DAO can be treated with neuromodulators to compliment an augmented chin.<sup>34</sup> A hyperdynamic mentalis muscle is common in this patient population and contributes to the appearance of retrusion by pulling the mentalis superiorly and deep. Zhou and colleagues<sup>35</sup> described improvement in chin projection among Asian patients after injecting 4 U of onabotulinumtoxinA into the belly of the mentalis muscle, at least 1 cm inferior to the lower lip.

Similarly, a recent study demonstrated that injection of 12 to 15 U of onabotulinumtoxinA into the mentalis lowered the vertical position of the pogonion in 10 of 11 patients, resulting in inferior displacement of the

soft tissue mass of the chin and a more rounded appearance. All 11 patients reported improvement in the aesthetic appearance of their chin.<sup>36</sup> Concomitant injection of neuromodulators into a hyperdynamic mentalis muscle may also prolong the filler's longevity (Figure 8).<sup>37,38</sup>

## Summary

Chin augmentation is increasingly recognized as an essential component to complete facial aesthetic rejuvenation. Dermatologic surgeons should be familiar with how to safely and effectively perform chin augmentation with injectable fillers, often in conjunction with concomitant therapies, to achieve an optimal cosmetic outcome in patients with mild to moderate chin retrusion.

## References

1. Shaw RB Jr, Katzel EB, Koltz PF, Kahn DM, et al. Aging of the mandible and its aesthetic implications. *Plast Reconstr Surg* 2010;125:332–42.
2. Zaitsev NV, Lebediantsev VV, Shul'ga IA. The gender and age-specific differences in the structure of the styloid processes of the temporal bone. *Vestn Otorinolaringol* 2014;5:23–5.
3. Mendelson B, Wong CH. Changes in the facial skeleton with aging: implications and clinical applications in facial rejuvenation. *Aesth Plast Surg* 2012;36:753–60.
4. Coleman SR, Grover R. The anatomy of the aging face: volume loss and changes in 3-dimensional topography. *Aesthet Surg J* 2006;26:S4–9.
5. Pessa JE, Slice DE, Hanz KR, Broadbent TH Jr, et al. Aging and the shape of the mandible. *Plast Reconstr Surg* 2008;121:196–200.
6. Thayer ZM, Dobson SD. Geographic variation in chin shape challenges the universal facial attractiveness hypothesis. *PLoS One* 2013;8:e60681.
7. Naini FB, Donaldson AN, McDonald F, Cobourne MT. Assessing the influence of chin prominence on perceived attractiveness in the orthognathic patient, clinician and layperson. *Int J Oral Maxillofac Surg* 2012;41:839–46.
8. Bae JM, Lee DW. Three-dimensional remodeling of young Asian women's faces using 20-mg/mL smooth, highly cohesive, viscous hyaluronic acid fillers: a retrospective study of 320 patients. *Dermatol Surg* 2013;39:1370–5.
9. Raspaldo H. Volumizing effect of a new hyaluronic acid sub-dermal facial filler: a retrospective analysis based on 102 cases. *J Cosmet Laser Ther* 2008;10:134–42.
10. American Society of Plastic Surgery. Available from: <https://d2wrczt3b6wjm.cloudfront.net/News/Statistics/2016/2016-plastic-surgery-statistics-report.pdf>. Accessed April 24, 2017.
11. Pils U, Anderhuber F. The chin and adjacent fat compartments. *Dermatol Surg* 2010;36:214–8.
12. Sykes JM, Fitzgerald R. Choosing the best procedure to augment the chin: is anything better than an implant? *Facial Plast Surg* 2016;32:507–12.
13. Lee SH, Lee HJ, Kim YS, Kim HJ, et al. What is the difference between the inferior labial artery and the horizontal labiomental artery? *Surg Radiol Anat* 2015;37:947–53.



14. Kawai K, Imanishi N, Nakajima H, Aiso S, et al. Arterial anatomy of the lower lip. *Scand J Plast Reconstr Surg Hand Surg* 2004;38:135–9.
15. Nelson DW, Gingrass RP. Anatomy of the mandibular branches of the facial nerve. *Plast Reconstr Surg* 1979;64:479–82.
16. Sykes JM, Suárez GA. Chin advancement, augmentation, and reduction as adjuncts to rhinoplasty. *Clin Plast Surg* 2016;43:295–306.
17. Sykes JM, Carruthers A, Hardas B, Murphy DK, et al. Development and validation of a photonic scale for assessment of chin retrusion. *Dermatol Surg* 2016;42(Suppl 1):S211–18.
18. Fattahi T. The prejowl sulcus: an important consideration in lower face rejuvenation. *J Oral Maxillofac Surg* 2008;66:355–8.
19. Romo T, Yalamanchili H, Sclafani AP. Chin and prejowl augmentation in the management of the aging jawline. *Facial Plast Surg* 2005;21:38–46.
20. Gross EJ, Hamilton MM, Ackermann K, Perkins SW. Mersilene mesh chin augmentation. A 14-year experience. *Arch Facial Plast Surg* 1999;1:183–9.
21. Gonzalez-Ulloa M. Quantitative principles in cosmetic surgery of the face (profile plasty). *Plast Reconstr Surg* 1962;29:186–98.
22. Silver W, Athre R, DeJoseph LM. Mandibular augmentation. In: Thomas JR, editor. *Advanced Therapy in Facial Plastic and Reconstructive Surgery*. Shelton, CT: People's Medical Publishing House- USA; 2010; pp. 503–511.
23. Wang Q, Guo X, Wang J. Autogenous fat grafting for chin augmentation: a preliminarily clinical study of cosmetic outcome. *J Craniofac Surg* 2015;26:e625–7.
24. Rho NK, Chang YY, Chao YY, Furuyama N, et al. Consensus recommendations for optimal augmentation of the asian face with hyaluronic acid and calcium hydroxylapatite fillers. *Plast Reconstr Surg* 2015;136:940–56.
25. Talarico S, Meski AP, Buratini L, Manela-Azulay M, et al. High patient satisfaction of a hyaluronic acid filler producing enduring full-facial volume restoration: an 18-month open multicenter study. *Dermatol Surg* 2015;41:1361–9.
26. Yuan JT, Chang TW, Yu SS, Arron ST. Mental artery occlusion from poly-L-lactic acid injection at the lateral chin. *Dermatol Surg* 2017;43:1402–5.
27. Hwang CJ, Morgan PV, Pimentel A, Sayre JW, et al. Rethinking the role of nitroglycerin ointment in ischemic vascular filler complications: an animal model with ICG imaging. *Ophthal Plast Reconstr Surg* 2016;32:118–22.
28. Swift A, Remington K. BeautiPHication™: a global approach to facial beauty. *Clin Plast Surg* 2011;38:347–77.
29. Fabi SG, Massaki AN, Goldman MP. Clinical efficacy and safety of monopolar radiofrequency device with comfort pulse technology for the treatment of facial and neck laxity in men. *Skinmed* 2016;14:181–5.
30. Dendle J, Wu D, Fabi S, Belo C, et al. A retrospective evaluation of subsurface monopolar radiofrequency for lifting of the face, neck and body. *Dermatol Surg* 2016;42:1261–5.
31. Fabi SG, Goldman MP. Retrospective evaluation of micro-focused ultrasound for lifting and tightening the face and neck. *Dermatol Surg* 2014;40:569–75.
32. Kilmer S, Burns J, Zelickson B. Safety and efficacy of cryolipolysis for non-invasive reduction of submental fat. *Lasers Surg Med* 2016;48:3–13.
33. Butterwick KJ. Enhancement of the results of neck liposuction with the FAMI technique. *J Drugs Dermatol* 2003;2:487–93.
34. Almeida T. The facial Platysma and its underappreciated role in lower face dynamics and contour. *Dermatol Surg* 2017;43:1402–9.
35. Zhou R, Pan B, Wang C, Wang D. Mandibular rim trilogy with botulinum toxin injection: reduction, projection, and lift. *Facial Plast Surg* 2017;33:102–8.
36. Hsu AK, Frankel AS. Modification of chin projection and aesthetics with onabotulinumtoxinA injection. *JAMA Facial Plast Surg* 2017;19:522–7.
37. Coleman KR, Carruthers J. Combination therapy with BOTOX and fillers: the new rejuvenation paradigm. *Dermatol Ther* 2006;19:177–88.
38. Dayan SH, Ellis DA, Moran ML. Facial fillers: discussion and debate. *Facial Plast Surg Clin North Am* 2012;20:245–64.

---

Address correspondence and reprint requests to: Monique J. Vanaman Wilson, MD, California Skin Institute, 603 S, Knickerbocker Drive, Sunnyvale, CA 94087, or e-mail: moniquewilsonmd@gmail.com