

# GASTRIC CARCINOMA AND THE MUCOSAL RELIEF TECHNIC

FREDERIC E. TEMPLETON, M.D.

It is the purpose of this article to outline briefly some of the newer concepts in the roentgenologic examination of the gastrointestinal tract, and to illustrate their application in the diagnosis of gastric carcinoma. The roentgenologic images obtained by these newer technics differ considerably from those obtained by the older method; the amount of useful information gleaned by using the newer technical process depends upon the examiner's ability to apply that method and interpret the results.

In the early days of roentgenology the gastrointestinal tract was examined either by studying a series of films exposed with the patient in various positions or by fluoroscopic observations after filling the organ with an opaque mixture. Attempts to devise a procedure retaining the advantages, but eliminating the disadvantages, of each method led to the development of a special instrument, "the filming fluoroscope."

The filming fluoroscope, as its name implies, is an instrument designed not only for the fluoroscopic examination of a patient but also for the exposing of films under fluoroscopic control. The instrument is sometimes called the "spot fluoroscope," because in some of the commercial varieties the exposed portion of the film is small and circular. For nearly a quarter of a century Forssell, Ackerland, Berg, Chaoul, and numerous other European authors have been writing about the instrument, the special technics developed for its use, and the interpretation of the fluoroscopic and film images. Until recently, most American radiologists have looked upon films as relatively unimportant adjuncts to the fluoroscopy. This attitude changed rapidly, however, with the introduction of the first commercial American filming fluoroscope in 1934.

The newer method of examining the gastrointestinal tract differs from the old, not merely in the greatly increased emphasis on films but also in the details of fluoroscopy itself. Ideally, the aim might be to examine every square inch of the image cast by the mucosa of the alimentary tract on the fluoroscopic screen and to record on films every area observed. Actually, of course, limitations of time and expense, and above all the safety of the patient and examiner reduce the extent to which this ideal can be realized, and not infrequently the body build of

the patient curtails the completeness of the examination regardless of the amount of radiation that the examiner is willing to tolerate.

Frequently, films provide objective confirmation of lesions suspected that were not observed at all during fluoroscopy. The desire to obtain good films spurs the examiner to a more careful and a more complete fluoroscopic examination. On the other hand, vague but repeated fluoroscopic evidence may lead to persistent filming that eventually is rewarded by the demonstration of a small, but nonetheless important, lesion.

Certain terms are best defined at the outset. When the patient ingests a small amount of contrast medium, such as a mixture of equal volumes of water and barium sulfate, and when this contrast material is spread in a thin layer over the mucosa of the organ being examined, one sees on the fluoroscopic screen a mucosal pattern in which the ridges, folds, nodules, and other elevations are bright and the barium caught in the interfold spaces is dark. On films the pattern is reversed, the elevations being black and the interfold spaces white. In both cases since the appearance is somewhat similar to a bas-relief in which the elevations stand out against the background of interfold spaces, the technic of obtaining such fluoroscopic images or films is termed the "relief technic."

Sometimes the mucosal pattern is demonstrated to better advantage by employing what is known as the "compression technic." More barium is administered, balsa-wood blocks, rubber bags, or pads of gauze and cotton are inserted between fluoroscopic screen and patient; a self-locking mechanism on the screen is brought into play; and the screen is pressed against the abdomen of the patient until the desired degree of compression is obtained. Finally, the older method, the so-called "filled organ technic," is employed. As its name implies, this is merely the examination of the organ after it has been completely filled with contrast medium.

By combining the old method and the new, diagnostic criteria become more precise. As the images obtained more nearly approximate those seen at gross pathologic examination, the roentgenologist begins to think in pathologic terms, and such words as "niche," "filling defect," and "incisura" give way to "ulcer crater," "polypoid mass encroaching on the lumen," and "scar tissue contraction."

### **Identification of Gastric Carcinoma**

In discussing the gross pathology of gastric carcinomata, seen by using the relief and compression technics, the classification of Borrmann,

## GASTRIC CARCINOMA

as modified by Konjetzny is chosen. Descriptions are limited to the "average" appearance. The merging of one type with another frequently makes it difficult to classify accurately a given lesion. The classification consists of four large groups.

1. Localized polypoid tumors
2. Localized ulcerating carcinomata
3. Ulcerating carcinomata with invasion of the surrounding tissues (transition type)
4. Diffuse infiltrating form
  - (a) Fibrosing
  - (b) Polypoid

The **rare, localized, polypoid** tumor seen at roentgenologic examination is usually broad-based, sometimes pedunculated. It protrudes into the lumen as a rough plateau, or ball-like, nodular mass with a smooth or uneven surface resulting from warty granulations, ulcerations, and fissures arising from disintegration of tissue (Fig. 1A). If the ulceration is marked and involves most of the tumor, a dishlike excavation with high margins results. In this state it has the characteristics of

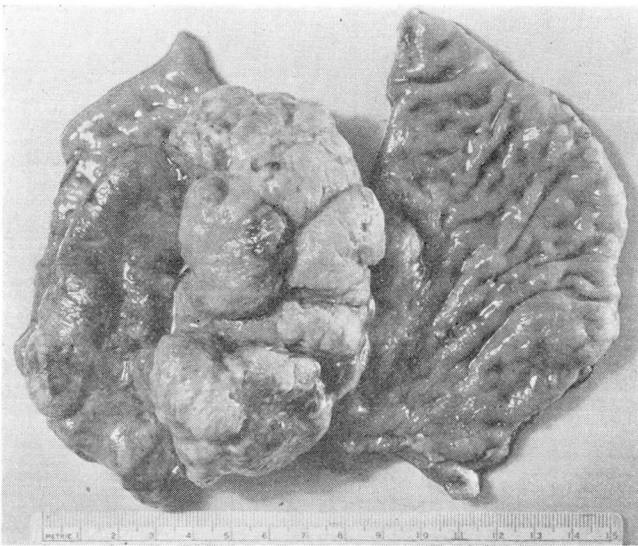


FIGURE 1. **Polypoid carcinoma.** (a) Gross specimen. Deep fissures and ulcerations separate the polypoid elevations.

the localized, ulcerating type. The hook shape of the stomach is often preserved, and the appearance of the defect depends upon whether it is seen in the frontal or profile projection. In the frontal projection the defect may be large enough to fill, or even expand, the lumen (Fig. 1B). The surrounding mucosa is pliable, and the rugae appear normal or "cut off" sharply at the tumor margin. Although this "cut off" of folds is theoretically sound in establishing the malignant nature of the lesion, the sign may be misleading. Too much compression over the lesion may

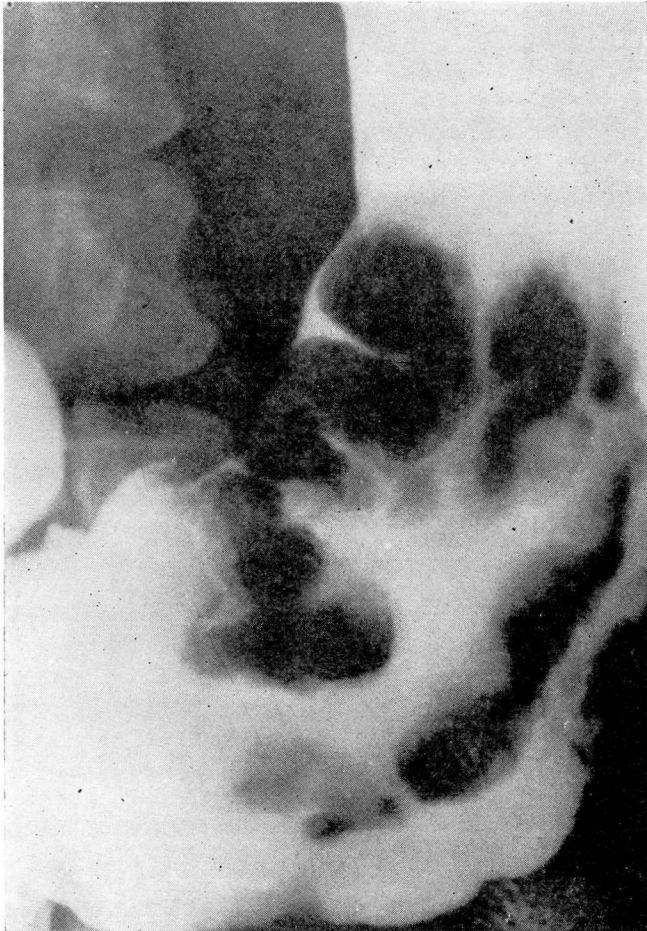


FIGURE 1. **Polypoid carcinoma.** (b) A large polypoid carcinoma fills the lumen of the midportion of the stomach. Angular dense shadows, representing barium puddled in ulcerations and fissures, outline the polypoid elevations.

## GASTRIC CARCINOMA

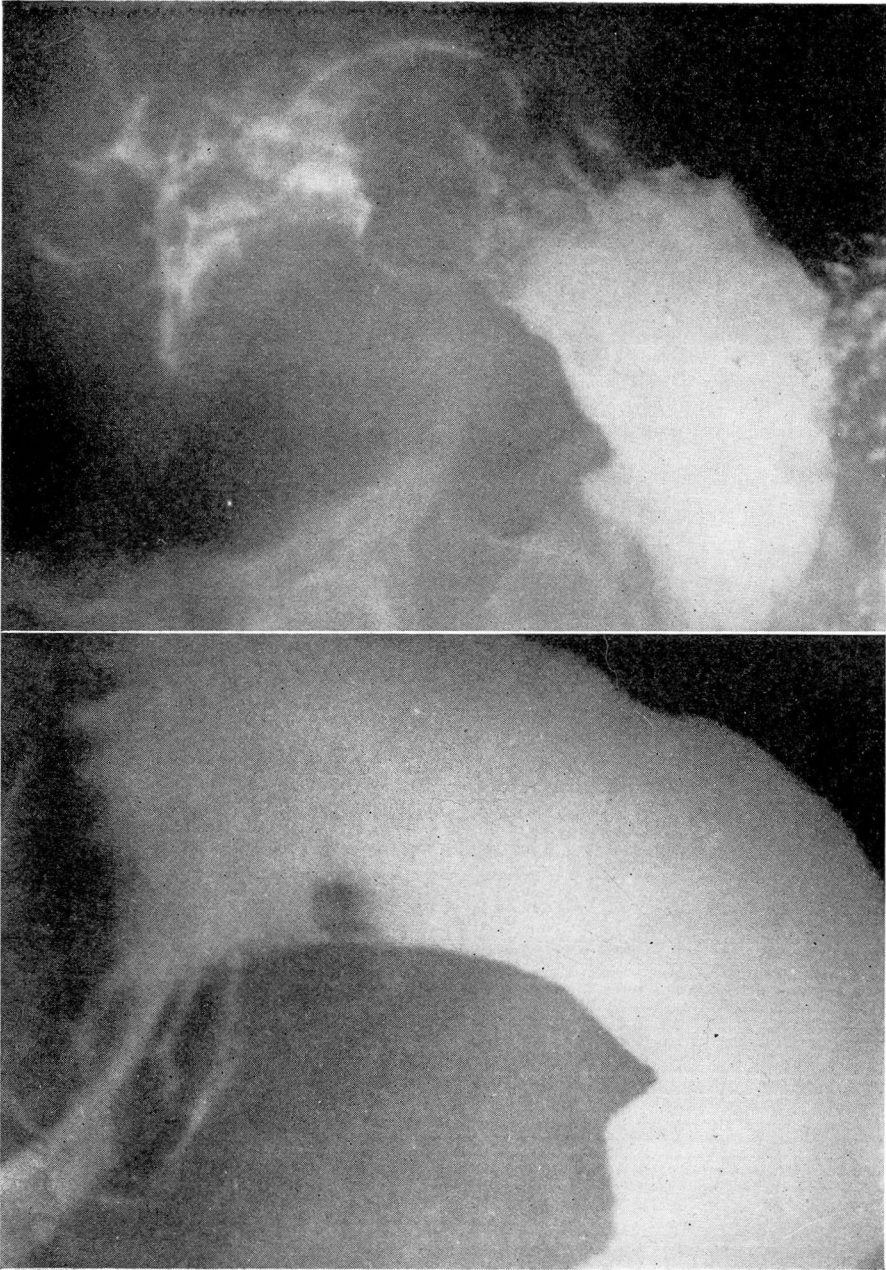


FIGURE 2  
A  
A large polypoid lesion invading the pancreas was found high on the posterior wall at operation. (a) In the filled stomach a small polypoid defect appears near the lesser curvature. Most of the tumor is covered with barium. (b) With relief films the entire tumor is outlined. Some of the folds on the anterior wall are superimposed on the shadow of the tumor.

completely obliterate all of the folds. This is particularly true in the antrum if too much barium is used. Folds on the opposite wall may also be obliterated by pressing against the tumor mass which produces a false appearance of "cutting off" of folds. If too little pressure is used, the rugal pattern of the opposite wall may be preserved, in which case folds seem to run through the tumor (Fig. 2). In the profile views barium flowing around a tumor located on a curvature may produce an hour-glass-like deformity of the stomach.

The **circumscribed ulcerating** carcinoma is common. Carmen described three different appearances produced by approximating the walls of the stomach: (1) A crater on the vertical portion of the lesser curvature produces a crescentic or meniscus-like shadow, the convexity of the crescent toward the gastric wall and the concavity toward the

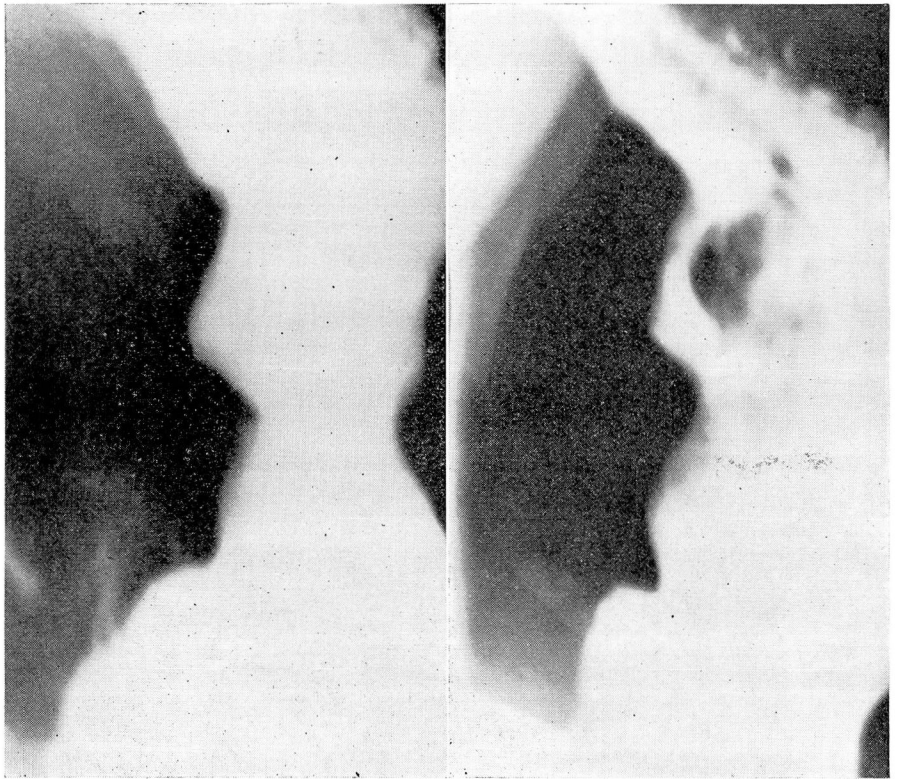


FIGURE 3. **Ulcerating carcinoma.** (a) A crater filled with barium protrudes from the lesser curvature of the body. (b) With compression excess barium has been displaced. The base of the crater is outlined by a meniscus-like shadow whose concavity is directed toward the gastric lumen.

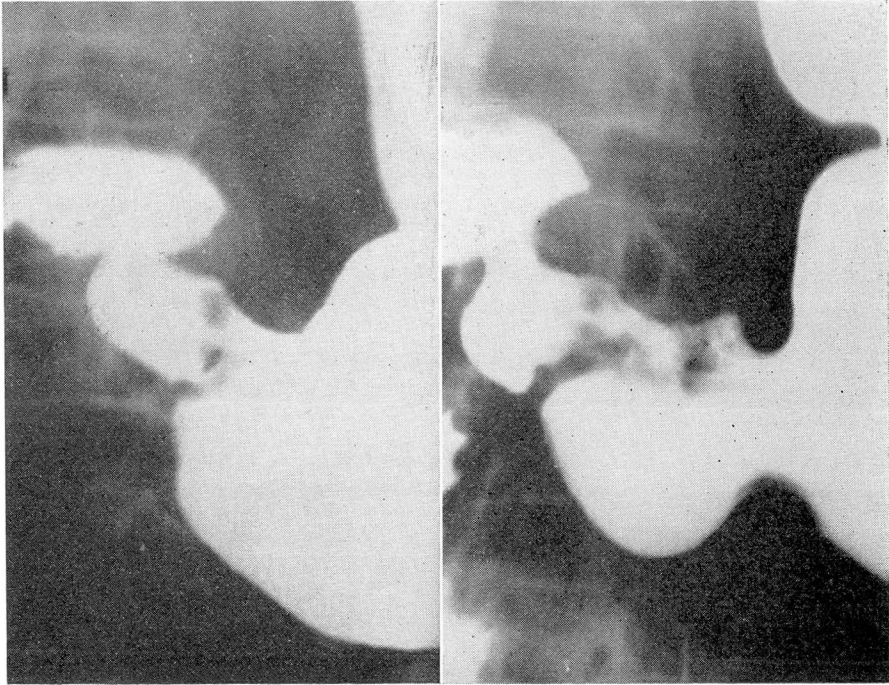
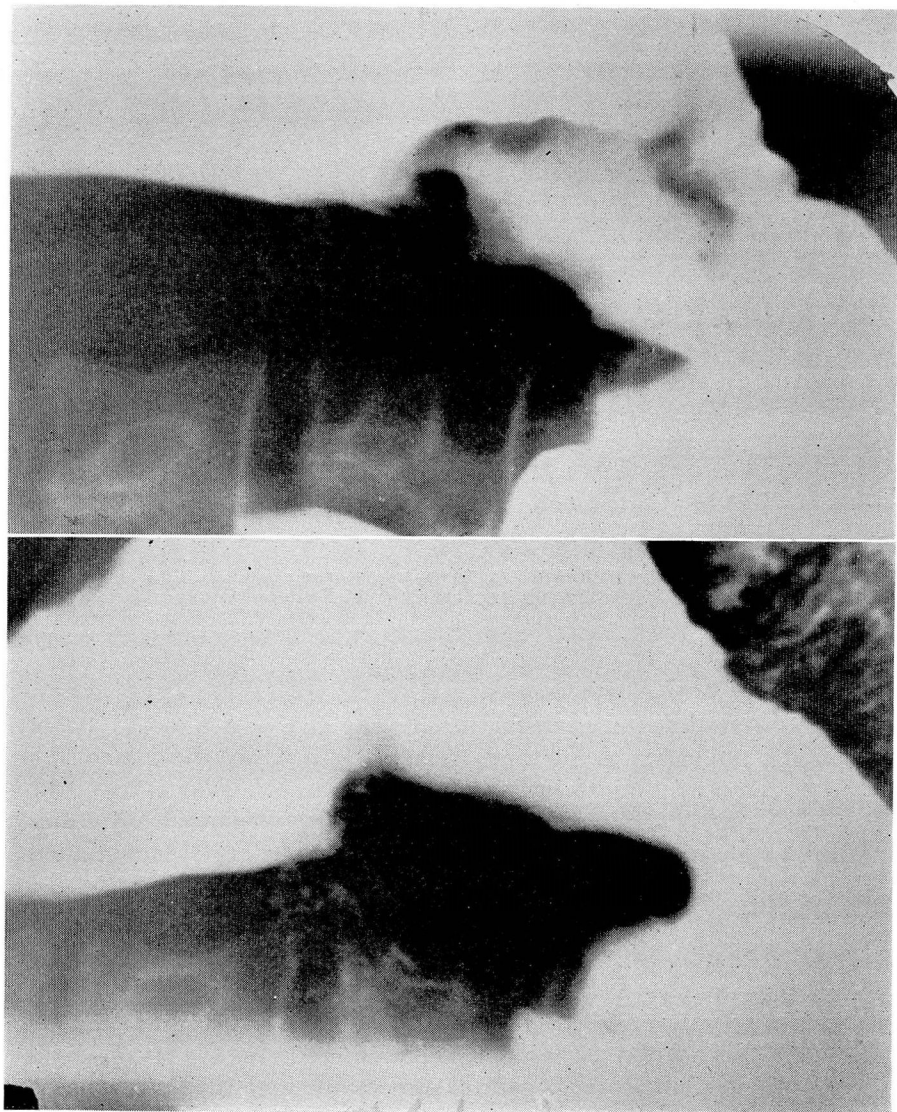


FIGURE 4. **Ulcerating carcinoma.** (a) With the stomach filled with barium, a section of the lesser curvature of the antrum is concave. (b) With compression the concave margin of the lesser curvature proves to be the base of the crater. The crater is set-off from the rest of the barium in the stomach by an irregular halo which represents the rolled-up margin about the crater.

lumen. (2) A saddle ulcer distal to the angle of a fishhook type of stomach also appears as a meniscus, but in this instance the base of the ulcer follows the bending line of the curvature, and the concavity of the meniscus is toward the gastric wall. (3) An ulcer distant from either curvature on the posterior wall appears as a circular crater surrounded by a halo and in oblique or profile views does not protrude beyond the contours of the stomach.

A carcinomatous ulcer with an appearance as described by Carmen in the first group is rare (Fig. 3). A lesion similar in appearance to that described in the second group on the vertical portion and at the angle of the lesser curvature is occasionally encountered (Fig. 4). If one wall of the ulcer is seen in a true tangential projection along the lesser curvature of a barium-filled stomach, an elongated depression results (Gutmann). The upper and lower margins of the lesion are sharp. Occasionally, the normal mucosa "mushrooms" over the rolled-up margin,



**FIGURE 5**  
**A**      **B**  
**Ulcerating carcinoma. (a)** The elongated depression with its sharp superior margin represents one wall of



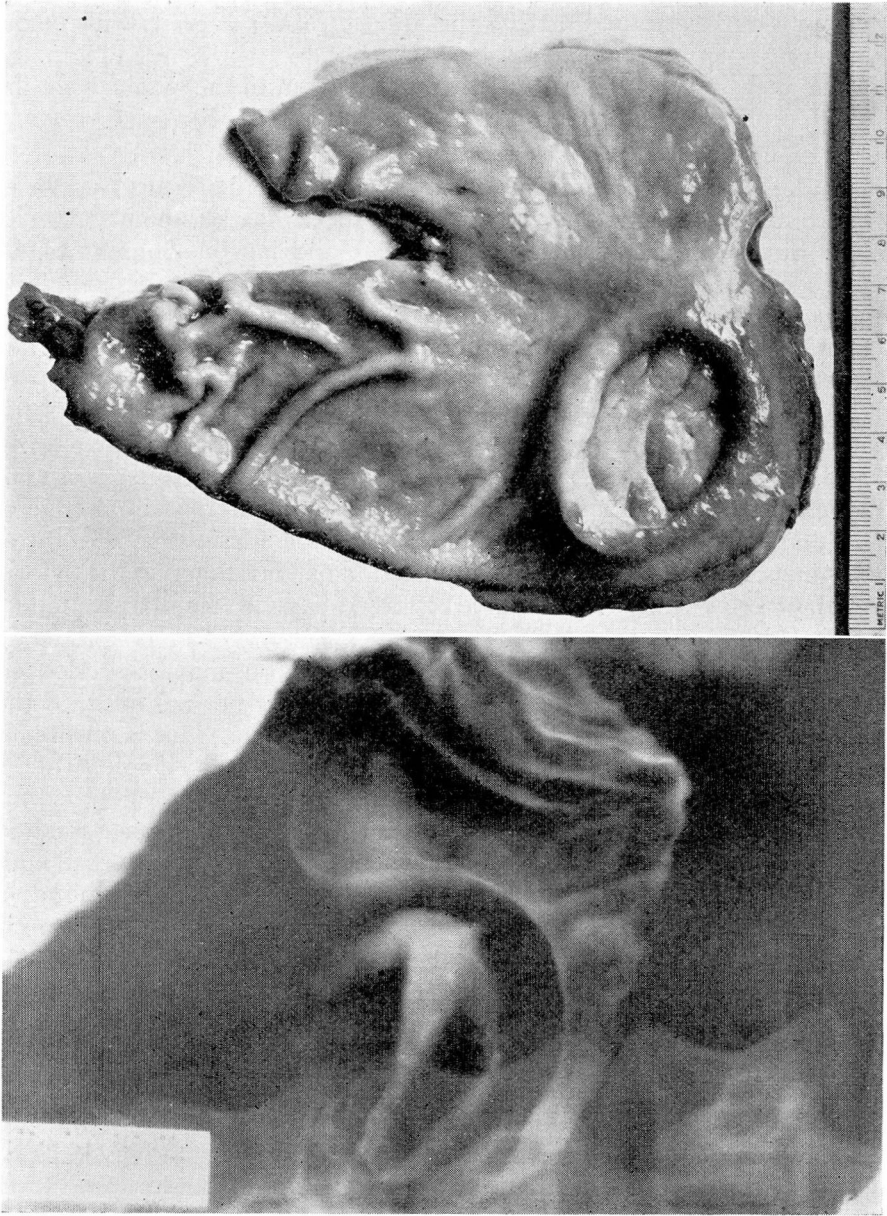


FIGURE 6  
A  
B  
**Ulcerating carcinoma.** (a) A large crater, with polypoid masses in the base outlined by barium, is surrounded by a high rolled margin. (b) Gross specimen.

giving the appearance of a small crater, and the actual tumor is overlooked. This can happen either at fluoroscopy or during the making of a film if the examination is done on a filled stomach without the use of compression. By approximating the anterior and posterior walls of the stomach by pressure, the barium in the crater which lies within the gastric margin is set off from the mass of barium in the stomach by the rolled, often irregular, margin of the ulceration (Fig. 5).

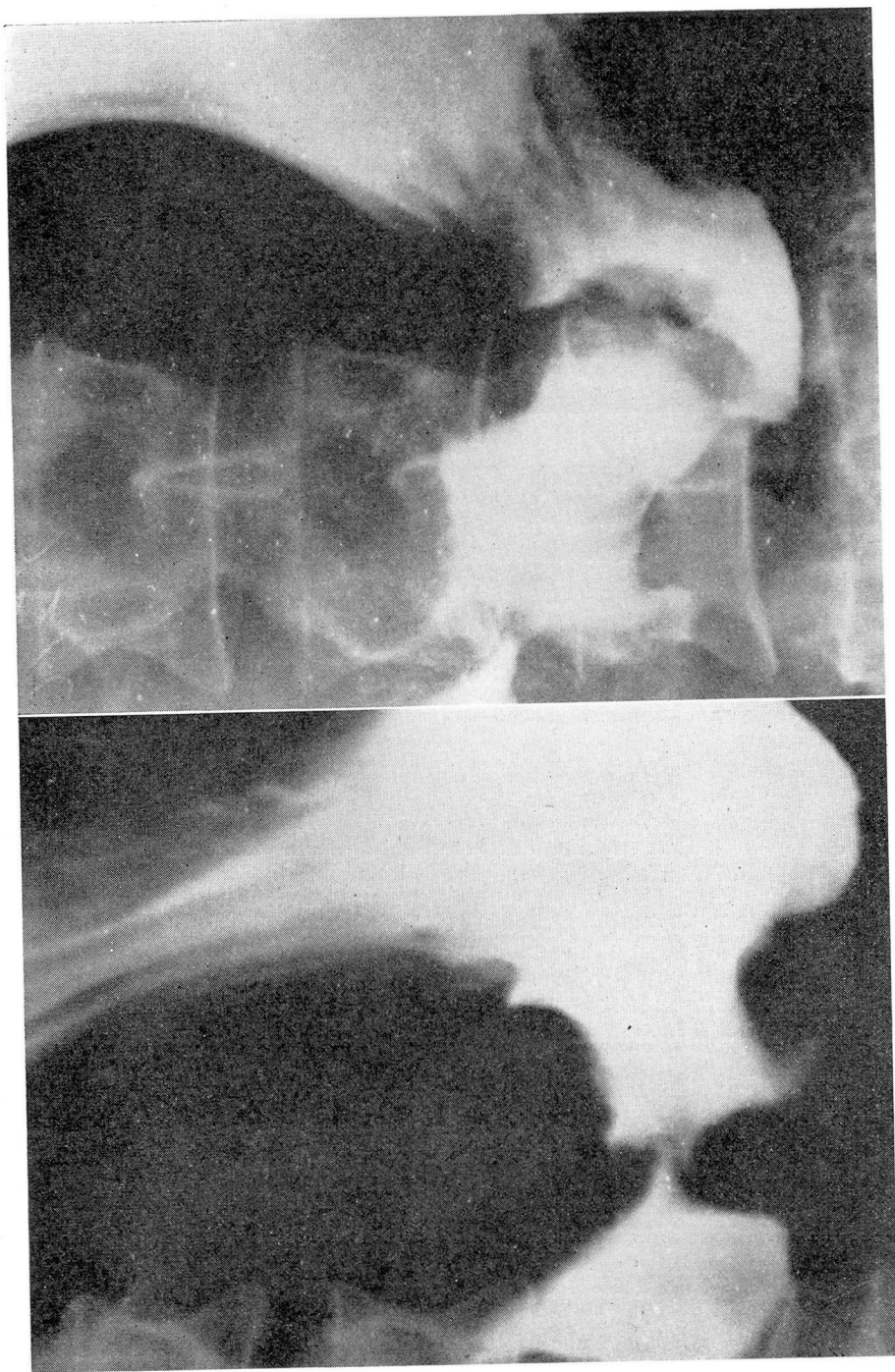
The ulcerating carcinoma described by Carmen in the third group is similar to that of the second group except that the crater is seen in the frontal projection. The margin of this ulcer may be smooth and circular but is frequently angular, irregular, and jagged. Sometimes, by severe compression, prominent polypoid elevations can be identified in the base (Fig. 6). As in the case of craters seen in profile, irregularity of the margin is caused by the polypoid nature of the elevated wall. The appearance of the rugae surrounding the lesion and on the opposite wall is similar to that encountered in the localized polypoid types.

In the pylorus the ulcerating tumor may spread in a ringlike form, causing stenosis (Klein). In the filled stomach this results in a stiff, ragged, narrowed lumen. If compression is used, the proximal edge of the sharply defined, rolled-up margin can be identified. The distal margin can seldom be outlined, as the lesion extends down to the pyloric canal, or sufficient barium cannot be forced beyond this margin to outline it (Fig. 7).

Berg pointed out that small tumors in the pylorus may be overlooked if the rolled margin has the same direction as the normal folds, as the margin may be easily confused with benign swelling. This is possible if one depends upon the results of the examination after a single swallow of barium, but is not so likely if compression is used on the filled stomach. Compression causes the crater to fill, whereas the former method may not. The failure of a crater to fill when too little barium is used with the hope of obtaining better relief views must always be kept in mind.

If the ulcer erodes beyond the level of the gastric wall, a pocket is produced which protrudes beyond the line of the curvature. The gastric wall falls sharply away from the ulcer margin, giving evidence of sharp demarcation which is a factor used in differentiating these lesions from the next type.

The **infiltrating carcinomatous ulcer of transition type** is, according to Berg, the carcinoma most frequently confused with benign ulcer, especially in the early stages, as it has a definite crater and may be associated with radiating folds. It may appear similar to the localized form except that part or all of the elevated margin is not so high, and consequently the adjacent gastric wall does not fall sharply away. This grad-

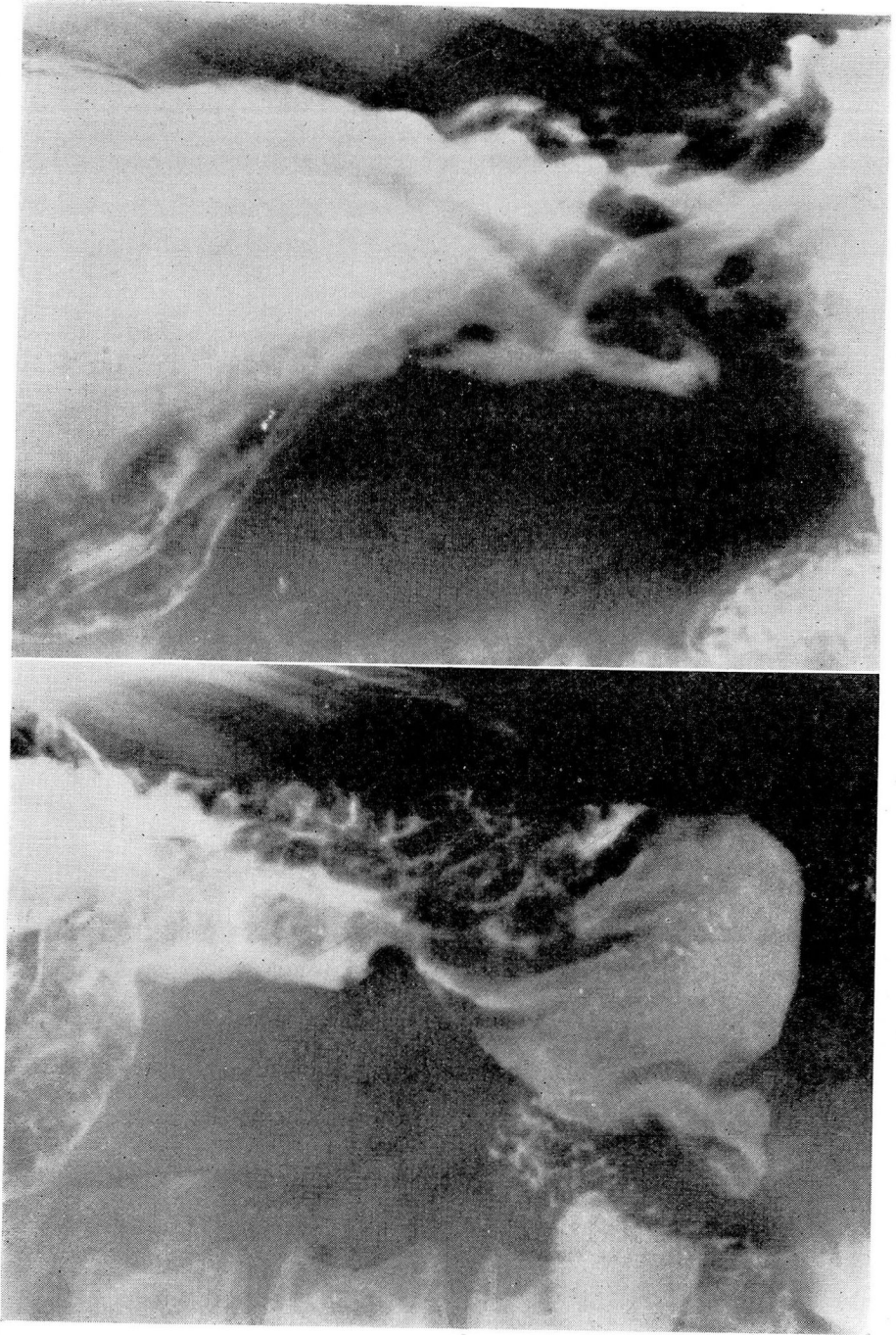


B

FIGURE 7

A

**Ringlike carcinomatous ulcer of the antrum.** (a) The ragged contours of the antrum were produced by neoplastic infiltration. (b) With compression normal rugae stop abruptly at the proximal rolled-up margin of the ragged crater encircling the antrum.



**FIGURE 8**  
**A** Flat, ulcerating, infiltrating carcinoma of the lesser curvature, proved to be inoperable: (a) The lower margin of the long, shallow ulcer set-off by a wide polymoid ulcer is shown. (b) The lower margin of the long, shallow ulcer.

ual merging of the infiltrated wall with the surrounding structures is evidence of infiltration beyond the confines of ulceration. If the lesion is situated along, or close to, the lesser curvature, which it frequently is, evidence of infiltration is usually seen first along the oral portion of the tumor. The surrounding mucosa may be involved by neoplasm or hyperplastic gastritis of a degree severe enough to produce roentgenographic changes. The folds are broad, stiff, and prominent, or the normal pattern is replaced with small, warty, mucosal thickening to nodular, polypoid growths of different sizes. The actual extent of the malignant changes cannot be estimated, and the gastritis cannot be differentiated from carcinoma, either at gastroscopic or at roentgenologic examination (Schindler). This appearance may be confused with that of the diffuse infiltrating carcinomata, particularly of the polypoid type (Fig. 8).

The **infiltrating carcinoma**, particularly the localized, non-ulcerating, fibrosing type, offers the greatest diagnostic difficulty in that it may easily escape detection (Eisler). If the mucosa is not fixed and the tumor is soft, it may be impossible to identify the lesion. The pattern of the folds may not be appreciably changed, and peristalsis may pass through the lesion, as reported by Kirklín, a phenomenon I have also observed.

If a small portion of one curvature is fixed, the only evidences of infiltration may be a slight straightening of the curvature (Cole), protrusion of the normal mucosa over the proximal edge of the lesion giving the appearance of a small crater, and the "peristaltic jump" of Fränkel. In this latter sign the peristaltic wave progresses in an uninterrupted manner along the uninvolved curvature opposite the tumor, but ceases at the proximal edge of the tumor only to reappear at the distal edge (Fig. 9).

If the infiltration is advanced, the pattern of the normal folds is obliterated, or is replaced by stiff irregular folds with narrow interspaces.\* The line of demarcation is not sharp, the normal folds gradually losing their identity in the abnormal patterns.

\*Loss of fold pattern in the antrum may be physiologic as well as pathologic. After a small swallow of barium various types of fold patterns appear in the antrum. If the stomach is filled with barium and compressed, no folds may be seen; if the patient is placed supine after taking the barium, the air which gravitates to the antrum and results in a "double contrast view" may distend the antrum sufficiently to obliterate folds. This observation is in keeping with the findings of the gastroscopist, who rarely sees antral folds. The smooth mucosal pattern does not necessarily indicate the presence of atrophic gastritis, which is easily differentiated from neoplasm by the presence of the folds in the collapsed antrum as seen after a single swallow of barium, by its distensibility by air in the stomach, and by pliability to external manipulation and passage of peristaltic waves.

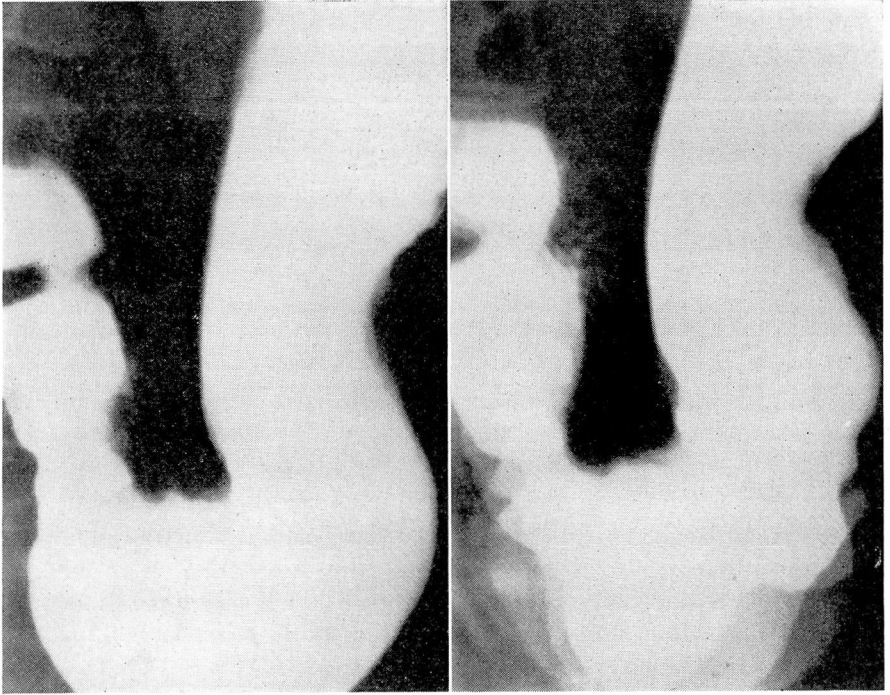


FIGURE 9. **Small infiltrating carcinoma.** (a) In the filled stomach the lesser curvature of the antrum is irregular. (b) Polygram. This view was made by giving  $\frac{1}{3}$  the normal exposure three times at intervals of 2 seconds. The progressive peristaltic waves can be identified along the greater curvature and the lesser curvature of the body. The infiltrated portion indicated in (a) is not affected by peristalsis.

If both curvatures are involved, they are abnormally smooth and straight.

In the far advanced case in which the entire stomach is involved, the diagnosis is more easily made by filling the stomach completely. The small, stiffened, foldless lumen with its pipelike passage of barium is characteristic (Fig. 10).

The polypoid type appears similar to the fibrosing type except that the nodular ulcerated mucosa results in various translucent rounded areas of various sizes (Fig. 11). The involved region is stiff, so that the pattern cannot be changed by variations in pressure during palpation. There is no sharp demarcation between the normal and the abnormal

## GASTRIC CARCINOMA

pattern. This type rarely involves the entire stomach and cannot always be differentiated from the fibrosing type by the roentgenologic observation if ulceration is pronounced.

Both types, if confined mainly to the antrum, result in a tubelike, or funnel-shaped, canal from contraction of the fibrous tissue. This may either cause obstruction or hold the pylorus open, allowing rapid emptying. If the lesion is confined to the center of the stomach, an hour-glass-like deformity may result. This is particularly true of the fibrosing type.

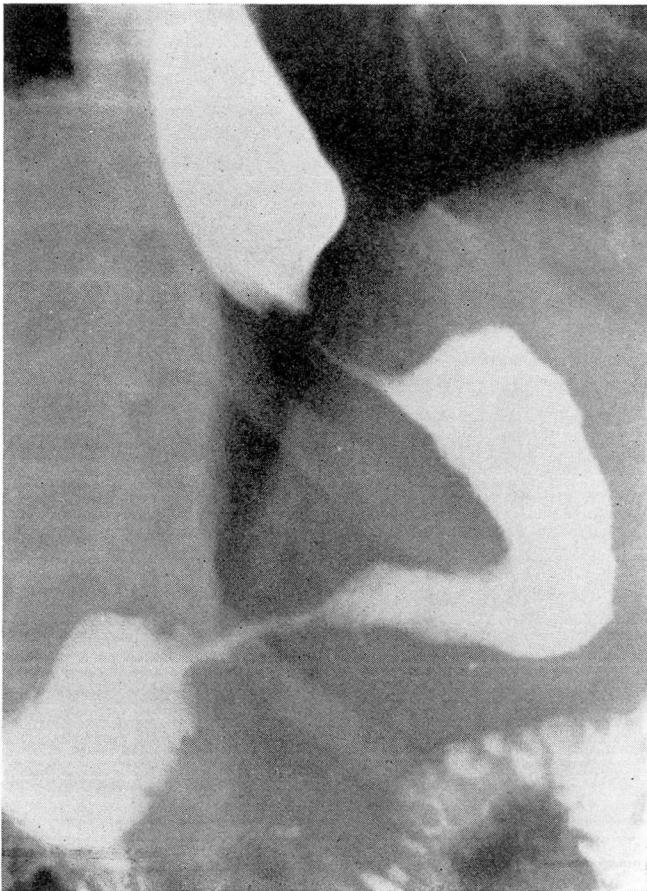

FIGURE 10. A diffuse, infiltrating, fibrosing carcinoma has involved the entire stomach and lower end of the esophagus.

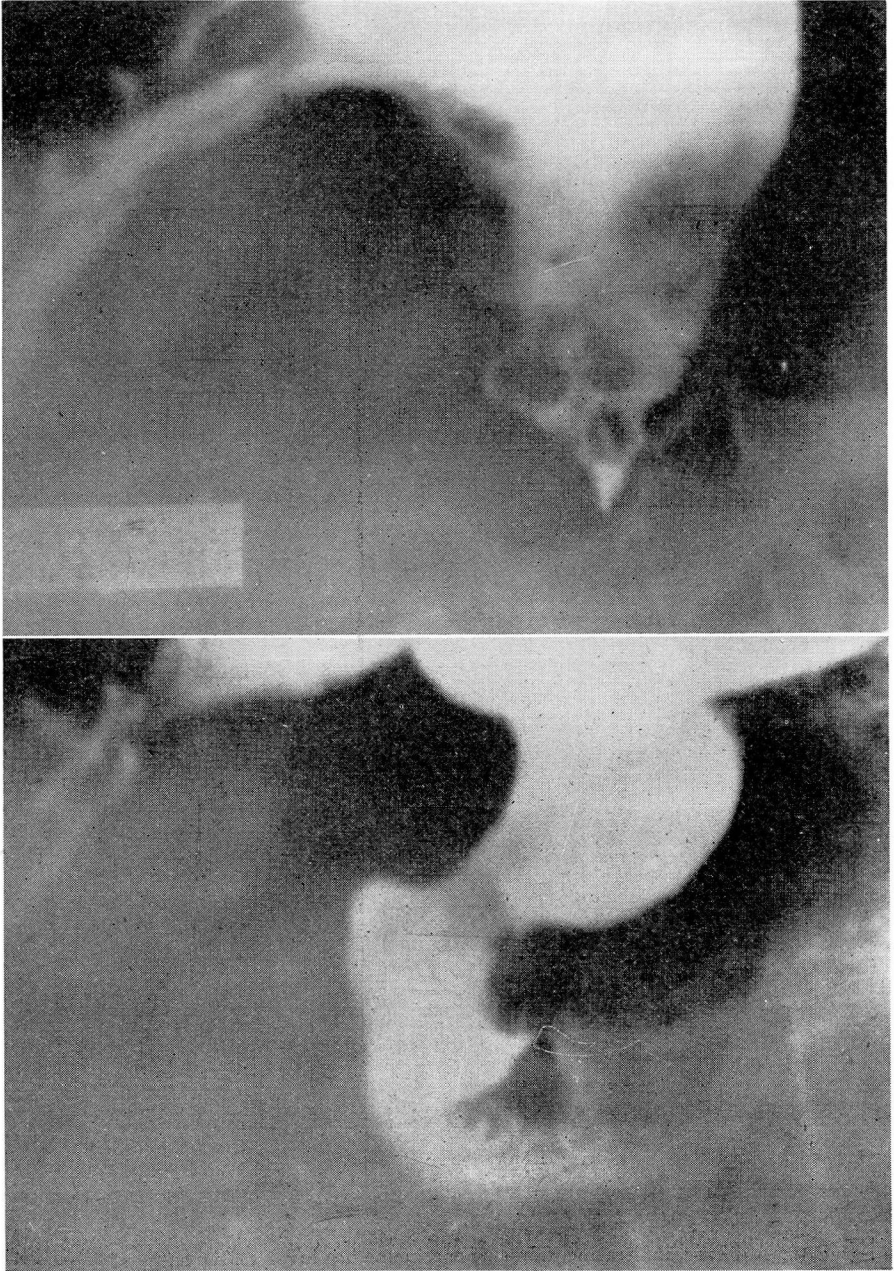


FIGURE 11  
A Small, infiltrating, polypoid carcinoma of the antrum. (a) Filled stomach. (b) After



## GASTRIC CARCINOMA

An infiltrating lesion in the fundus is particularly difficult to identify as the rib margin interferes with adequate palpation. Polypoid masses cause the stream to split into two or more components as it enters the stomach. The relief methods give valuable aid, as overdistension of the fundus with barium covers up a lesion involving either the posterior or anterior wall (Kirklin). One must beware of placing too much emphasis on the increase in distance between the fundus and diaphragm as a diagnostic sign provided that the dome of the fundus fills out smoothly and appears pliable to changes in the position of the diaphragm or transmitted pulsation from the heart. In the partially distended fundus folds running over the dome, seen on the axial projection, give a more or less regular serration similar to that seen along the greater curvature. Frequently, the observation of carcinomatous masses against the gastric air bubble may be facilitated by partially filling the stomach with barium with the patient supine. By turning him to a prone or upright position, the bulk of the barium falls away, sometimes leaving a film of barium on the surface, sharply outlining the lesion against the air. Such patterns may be more pronounced if the distention is not too great. Greater distention may roll the lesion around to either the anterior or the posterior wall so that the shadows are less pronounced or lost when seen in the anteroposterior projection. Here again the examiner must beware, for at times a normal, slightly distended fundus, insufficiently coated with barium, may give irregular shadows not unlike carcinomatous masses. In all cases careful examination of the lower end of the esophagus is necessary to determine the presence or absence of infiltration as these lesions frequently involve this region.

### Differential Diagnosis of Gastric Carcinoma

In some localized polypoid types of carcinomata, the appearance leaves little doubt as to the malignant nature, but in other types differentiation from a benign lesion is at best only a guess. If the lesion fulfils the criteria described earlier, especially if the lobulations, fissures, and ulcerations are found, it is surely malignant. If the surface is smooth, if there is no infiltration of the neighboring mucosa, or if folds encircle the tumor to enclose it, it is usually benign. In such a case, however, it is not possible to determine the absence or presence of malignant cells in the polyp if the mucosa is not involved. Fortunately, polypi and localized polypoid carcinomata are rare, so that this problem of differentiation does not occur frequently.

Palmer, in discussing ulcerating gastric lesions, concluded that (1) the existence of carcinomatous degeneration in benign ulcer remains to

be proved conclusively; (2) peptic ulceration of carcinoma may produce a lesion grossly indistinguishable from benign ulcer; and (3) although there is no pathognomonic sign to indicate the benign nature of the lesion, the total evidence available from careful roentgenologic, gastroscopic, and clinical studies permits differentiation of benign and malignant gastric ulcer with a high degree of accuracy.

There are, however, certain types of ulcerating lesions which leave very little doubt as to their benign or malignant nature when first seen at roentgenologic examination. The protruding ulcer, whose crater margin is rounded and regular and sharply undermined, and which is set off from pliable normal-appearing mucosa, either with or without a few radiating folds, by a smooth rolled-up margin, is usually benign. The ulcer fulfilling the criteria of Carmen by presenting the meniscus-like complex is surely malignant. If the ulcer simulates the appearance of the infiltrating, transition type of ulcer or is large, differentiation between a benign and malignant lesion may not be made from roentgenologic evidence alone. The hypertrophic changes in the gastritis, which sometimes simulates a benign ulcer, may appear similar to the neoplastic infiltration about this form of carcinomatous ulcer. In these cases a period of medical management may be instituted, since the rapid diminution in size and eventual disappearance of a crater as seen at either gastroscopic or roentgenologic examination is an important factor in establishing the benign nature of an ulcer.

In evaluating this evidence, the ulcer must not only disappear but must leave soft, pliable mucosa, through which peristalsis passes at the former site of the crater. The crater of an ulcerating malignancy occurring in a stomach producing free acid will fill in with neoplastic tissue. The crater disappears but the infiltration remains. The stiffness which this infiltration produces can be detected (Fig. 12). Bloomfield has justified the delay in diagnosis by pointing out that the incidence in error in the clinical differentiation is not greater than the mortality rate from a sub-total gastrectomy.

Some infiltrating carcinomata may not be differentiated from the rare forms of hyperplastic gastritis, either at gastroscopy or roentgen examination. Templeton and Schindler point out that the passage of deep peristaltic waves through the stomach is helpful in differentiating certain forms of gastritis from carcinoma. Also, they presented a case of polypoid gastritis in which multiple polyp-like lesions were scattered throughout the antrum. Following the lead of Berg, they stated that this finding is apparently the only sure sign of gastritis. In view of Konjetzny's work suggesting that these forms of gastritis may become carcinomatous,

## GASTRIC CARCINOMA

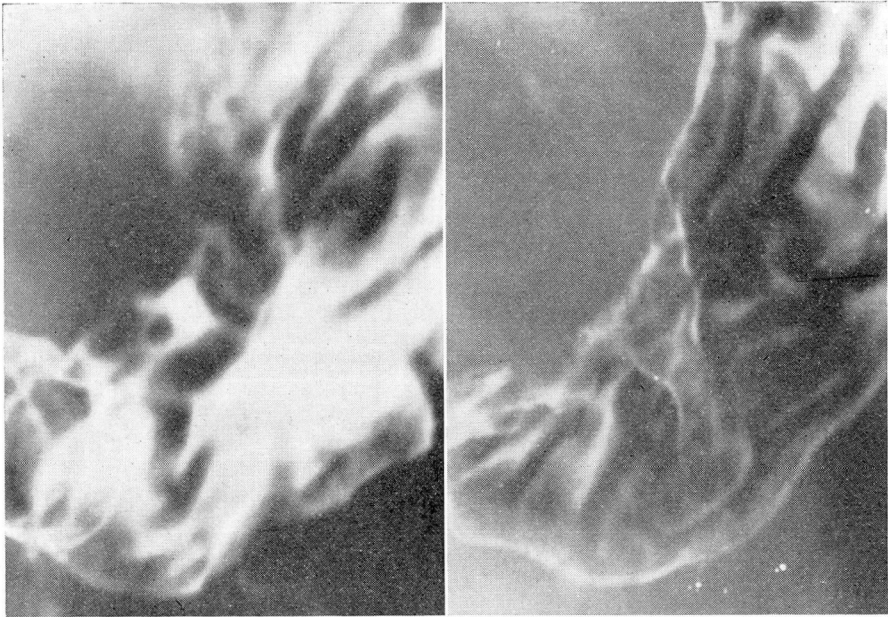


FIGURE 12. Carcinomatous ulcer disappearing under medical management. (a) An irregular crater having poorly defined margins is present along the lesser curvature of the antrum. Free acid was present in the gastric juice. (b) On medical management the crater disappeared but an area of infiltration remained. The stiffened area was difficult to identify at fluoroscopy, but peristalsis failed to pass through the region. (See Fig. 9)

it now seems reasonable to suppose that the criteria are not absolute. Berg has also stated that if a stiffly infiltrated stomach with large rugae is accompanied by a demonstrable crater or stiff polypoid folds in the duodenum, the gastric lesion is inflammatory.

### SUMMARY

1. The advantages of using the filming-fluoroscope (spot machine) in gastrointestinal diagnosis are briefly discussed.
2. The use of the filming-fluoroscope and the interpretation of the images obtained by it in gastric carcinoma including some of the problems of differential diagnosis of gastric carcinoma are outlined.

REFERENCES

1. Akerlund, A.: Roentgen study of duodenum. *Hygiea* 81:449 (May) 1919.
2. Akerlund, A.: Later experiences concerning niche diagnosis in cases of duodenal ulcer. *Acta radiol.* 8:538-546, 1927.
3. Akerlund, A.: Present-day criteria of x-ray diagnosis of duodenal ulcer. *Am. J. Surg.* 11:233 (Feb.); 504 (Mar.) 1931.
4. Berg, H. H.: Röntgenuntersuchungen am Innenrelief des Verdauungskanal. (Leipzig: G. Thieme, 1930).
5. Bloomsfield, A. L.: Diagnosis of early cancerous changes in peptic ulcer. *J.A.M.A.* 104:1197-1201 (April 6) 1935.
6. Carman, R. D.: New roentgen-ray sign of ulcerating gastric cancer. *J.A.M.A.* 77:990, 1921.
7. Chaoul, H.: Das Schleimhautrelief des Magens im Röntgenbilde. *Deutsche Ztschr. f. Chir.* 214:351-386, 1929.
8. Cole, L. G.: Gastric cancer: correlation of roentgenological and pathological findings. *Am. J. Surg.* 31:206-224, 1936.
9. Eisler, F.: Zur röntgenologischen Frühdiagnose des Magenkrebses. *Fortschr. a. d. Geb. d. Röntgenstrahlen.* 54:289-296, 1936.
10. Fränkel, A.: Cross-bar symptom, direct roentgen symptom of gastric ulcer without niche. *Arch. f. Verdauungskr.* 37:408-421, 1926.
11. Forssell, G.: Über die Beziehung der Roentgenbilder des menschlichen Magens zu seinem anatomischen Bau. *Beiträge zur Anatomie und Physiologie des Magens.* XII, (Hamburg: L. Gräfe & Silem, 1913).
12. Forssell, G.: Normale und Pathologische Reliefbilder der Schleimhaut. Ein Überblick über Autoplastik des Digestionkanals. *Verhandl. d. Gesellsch. f. Verdauungs. u. Stoffwechselkr.* 7 Tagung. 1927, 199-219. (G. Thieme, 1928)
13. Gutmann, R. A.: Un cas "d'image encastree" dans un cancer de l'estomac a son extreme debut. *Bull. et mem. Soc. de radiol. med. de France* 25:194-196, 1937.
14. Kanjetzny, G. E.: Der Magenkrebs. F. Enke Suttgart, 1938.
15. Kirklin, R. B.: Radiology of the gastro-intestinal tract. *Lancet* 2:1162-1163, 1934.
16. Kirklin, R. B.: Roentgenologic diagnosis of cancer of cardia. *Am. J. Roentgenol.* 41:873-880 (June) 1939.
17. Klein, S. H.: Origin of carcinoma in chronic gastric ulcer. *Arch. Surg.* 37:155-174 (July) 1938.
18. Palmer, W. L.: Benign and malignant gastric ulcers: their relation and clinical differentiation. *Ann. Int. Med.* 13:317-338, 1939.
19. Templeton, F. E., and Schindler, R.: Roentgenologic and gastroscopic studies in chronic gastritis and peptic ulcer. *Am. J. Roentgenol.* 41:354-76 (March) 1939.
20. Schindler, R.: Gastritis simulating tumor formation. *Am. J. Digest. Dis.* 6:523-529 (Oct.) 1939.