

NEOPLASMS OF THE SMALL INTESTINE

J. C. ROOT, M.D.
Department of Roentgenology

Neoplasms of the small intestine constitute only a small percentage of the tumors found throughout the gastrointestinal tract, but they are discovered frequently enough to make the clinician "small bowel conscious". Certainly this type of lesion should always be considered when a patient is seen with obscure intestinal symptoms or with bleeding from the bowel of undetermined origin. Ewing¹ states that carcinoma of the small intestine is comparatively rare, forming about 3 per cent of all intestinal cancers. Tumors of this type constitute the majority of the small intestine neoplasms. The next most common type is that of the sarcoma group. Sarcoma may occur in any portion of the small intestine but is seen more often in the ileum. A third type of neoplasm to be considered is the carcinoid or argentaffin tumor which is also seen with greater frequency in the ileum than in the proximal portion of the small intestine. These tumors are usually small intramural growths and seldom give rise to clinical symptoms. They are seldom discovered by roentgen examination and are more apt to be seen at autopsy or as an incidental finding at operation.

Many tumors of the small intestine are not definitely diagnosed before operation because a special roentgen examination of the intestine has not been made. Instead, and with some logic, the diagnosis is made by an exclusion process following a negative roentgen examination of the stomach and colon. Considering the rarity of tumors of the small intestine, it is readily understood why they may not be considered when the patient is first seen, and how they may be overlooked in the routine roentgen examination of the gastrointestinal tract. This is particularly true with small tumors or those outside of the bowel lumen, and diligent search must be made by careful roentgen examination which is not only time consuming but may also be somewhat tedious.

The symptoms will vary greatly, depending upon such factors as type of tumor, size of the mass, degree of encroachment on the lumen and its location. During the early stage of growth and even after the tumor has reached considerable size, the subjective symptoms may be so slight or obscure that they are apt to be disregarded by both the patient and the clinician.

The most common symptoms of malignant tumors of the small intestine are those due to mechanical obstruction and to intestinal bleeding. The former is more often seen in the carcinoma group since

these tumors arise in the mucosa and are primarily of the intraluminal type. Obstruction may be produced by constriction of the lumen from the classical "napkin ring" type of growth or by encroachment upon the lumen of the bowel by a projecting mass. The early symptoms are those of obstruction and may consist only of vague, colicky pains or a subjective feeling of peristaltic unrest. Frequently nausea may be the chief symptom. As growth progresses, however, obstruction increases with constipation, nausea and vomiting, signs of abdominal distention, and visible peristaltic movements. Where, however, the carcinoma has arisen from a pedunculated adenoma, the onset may be sudden and severe due to an intussusception and the resulting obstruction.

The small intestinal tumors occurring outside the lumen are mostly of the sarcoma type. They may not give rise to early symptoms since there may be little or no encroachment upon the lumen of the bowel until they have reached considerable size. With the enlargement, they may either project into the lumen and produce obstruction, or the obstruction may result from pressure of the large mass outside the lumen. With this type of tumor a palpable mass may be present in the abdomen with only mild subjective symptoms suggesting an obstructing lesion.

Intestinal bleeding is frequently found to be due to a malignant tumor although it may not appear until the growth is of considerable size. The bleeding may be manifested as occult blood or hypochromic anemia, but massive hemorrhage with tarry stool or even bright red blood is not uncommon. Again, the type and location of the growth are important factors in causing bleeding. The carcinoma group, because of early mucosal involvement, will give rise to bleeding early. The group arising outside the lumen, on the other hand, may be present for a considerable time before the mucosa is invaded and ulceration produced.

The age of patients with neoplasm of the small intestine is a suggestive but not an entirely dependable factor in diagnosis, although the carcinoma group more commonly occurs in the fourth and fifth decades of life. In the sarcoma group the incidence is higher in the fourth decade although it may occur from infancy to an advanced age.

The roentgen examination is the most important procedure for diagnosis of lesions of the small intestinal tract and any one, or a combination, of three technics may be employed. These consist of barium by mouth with interval examination, the so-called "small intestinal enema" with duodenal intubation, and the barium enema into the colon. Examination in the last procedure depends upon sufficient barium mixture passing through the ileocecal valve for visualization of the distal portion of the ileum. Of these procedures, the first named is of more value for lesions in the proximal and mid-portions, and the last for

visualization of lesions in the distal or terminal portion of the ileum. We have employed the intubation technic but a few times since we have found it difficult to obtain satisfactory visualization. Due to the extent of the bowel which is filled with the barium solution at one time, there is considerable overlapping of the various loops of intestine with resulting confusion of shadows.

The usual procedure at Cleveland Clinic when a lesion of the small intestine is suspected is to examine the patient by the oral route first and follow this with the barium enema. Although the examination may follow the same pattern, no routine can be established since this will depend upon time of passage of the barium solution through the small intestine and the conditions which may be demonstrated. In all cases, however, we use only a small amount of the barium solution, as a rule not over 2 ounces of a thin suspension. This is an important point since it is desirable to obtain adequate visualization and avoid overlapping of the intestinal loops which will occur if a large amount of the barium mixture is given to the patient. The patient drinks the solution in small sips during the initial fluoroscopic examination so that the proper amount may be determined. At this time careful examination of the duodenum and proximal jejunum is made and spot films exposed if any abnormal changes are noted. Following the initial fluoroscopic examination, survey films are made with the patient in the most appropriate position for demonstration of any changes noted. The study is then continued at intervals, which will vary from minutes to hours, depending upon the rapidity with which the barium solution passes through the intestine and upon the discovery of any lesion that may be demonstrated. For this reason every examination of the small intestine is an individual problem and no routine method or procedure may be established.

Both fluoroscopy and films are employed; the former is of importance for manipulation and separation of the various loops, the latter for record and detailed visualization. The column of barium is followed at least until the head of the meal has reached the cecum and all parts of the small intestine have been adequately visualized. In some patients a marked hypermotility may be present and the barium will reach the colon in an hour or less. In others there may be obstruction or hypomotility and a period of hours may be required for complete examination. In a great many cases, some of which may be normal, there may be some delay or slowing in the motility when the meal has reached mid-portion of the bowel. If there is no residual barium in the stomach at this time the patient may eat a light meal which will again stimulate intestinal activity and speed the passage of the barium column. In

every case we include a six-hour film, regardless of others that have been made, since this forms the basis of our judgment of the over-all motility. It can be readily understood that the complete examination requires considerable time and attention but there are no short-cuts if one is to arrive at the correct diagnosis.

The barium enema examination is employed if a lesion has not been demonstrated by the preceding method. Generally it will permit more satisfactory visualization of the distal and terminal portion of the ileum by reflux of the barium through the ileocecal valve. In the interval study method it may be difficult to obtain satisfactory visualization of the terminal ileum due to overlapping and inability to separate the partially filled coils. This difficulty is overcome to a considerable degree by the distention of the lumen with the barium solution at the time of the fluoroscopic examination. The distention tends to straighten the intestinal coils. This effect, combined with manipulation of the gloved hand, will give satisfactory visualization of a considerable length of the distal ileum.

At times the barium suspension in the colon may obscure the ileum and in these instances the patient should have additional fluoroscopic

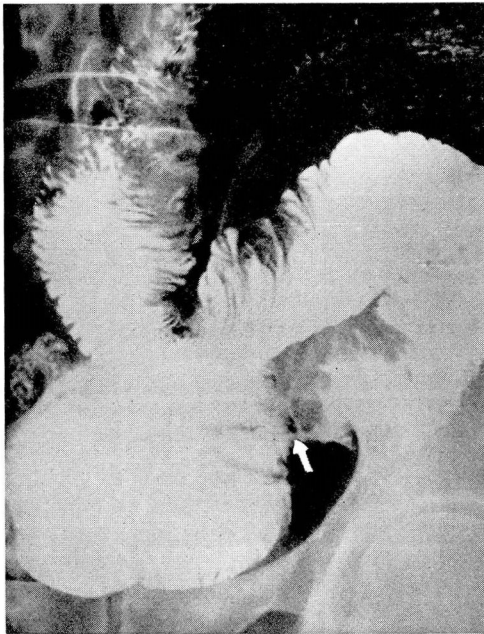

FIG. 1. Adenocarcinoma of ileum. Annular constricting deformity producing partial obstruction. Dilatation of intestine proximal to the lesion.

examination and roentgenograms after expulsion of the enema. Generally, too, the patient is more relaxed after expelling the solution and it is possible to make a more thorough search for the suspected lesion.

The roentgen criteria for diagnosis of neoplasms of the small intestine are much the same as for the other portions of the gastrointestinal tract. The most prominent change will be a localized deformity of the shadow which may manifest itself as a filling defect, an annular constriction, or an infiltrative defect in the wall of the bowel. Although lesions other than neoplasm may simulate some of these changes, filling defects due to tumor are generally sharply demarcated at both the proximal and distal margins and involve a short segment. Other changes associated with neoplasm are alteration or obliteration of the mucosal pattern at the site of the lesion, obstruction, and ulceration.

Obstruction may develop slowly over a period of time and will show an increasing degree of dilatation of the bowel proximal to the site of the lesion. In the early stage of obstruction such as that produced by a constricting neoplasm (fig. 1), the dilatation may not be marked and may be demonstrated for only a relatively short distance proximal to

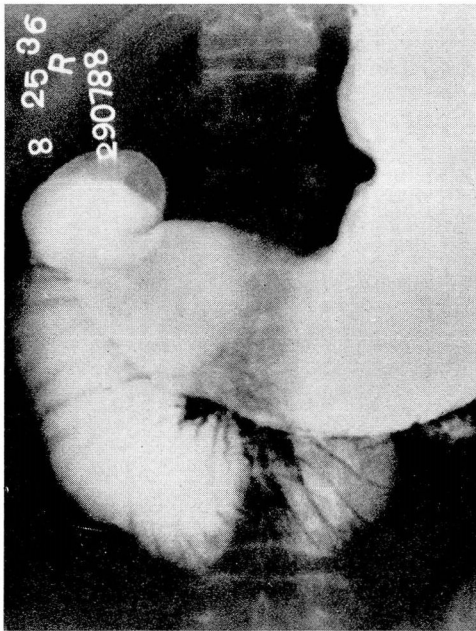


FIG. 2. Adenocarcinoma of jejunum causing obstruction. There is marked dilatation of the duodenum with loss of morphologic characteristics of the tumor.

the tumor. As the obstruction and resulting dilatation increase, however, it may reach such a degree that the morphologic features of the lesion cannot be demonstrated by the roentgen examination (fig. 2). The characteristic appearance of intestinal obstruction with marked dilatation, "stepladder" pattern, and multiple fluid levels is usually absent unless there be sudden onset such as that produced by intussusception of a polypoid tumor. This is due chiefly to the fact that the small intestine has the inherent ability to compensate for a gradual reduction in the diameter of the lumen.

Mucosal pattern change may be one of the earliest manifestations produced by neoplasms of the gastrointestinal tract. In the carcinoma group, arising from the mucosa, this will be the first demonstrable change in the roentgen examination. With the intramural type of tumor and the one arising outside the lumen, the mucosal pattern change is produced by pressure or stretching of the folds and may not be marked at any stage. These changes are best demonstrated during the fluoroscopic examination and must be carefully looked for throughout the length of the small intestine. As the growth of the tumor progresses and

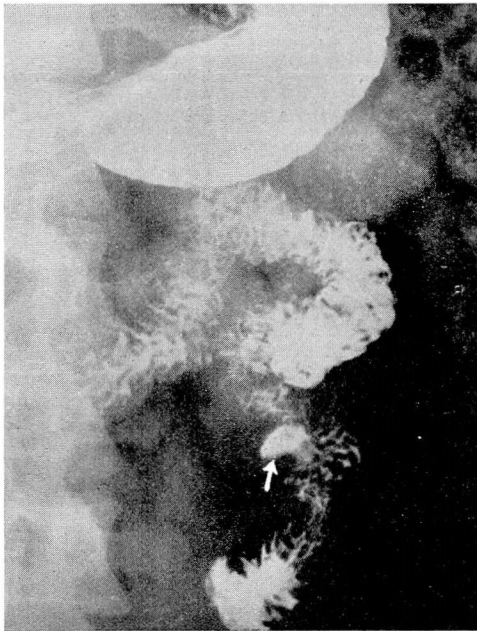


FIG. 3. Leiomyosarcoma of the jejunum. Tumor intramural in origin but growth did not project into the lumen. Ulcer crater and slight ulceration of mucosal pattern are only roentgenogenic sign of this tumor; measurement 6 x 4 x 3 cm.

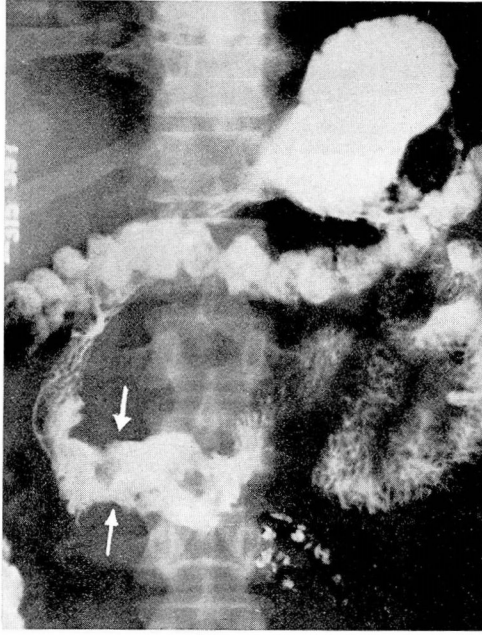


FIG. 4. Lymphosarcoma of duodenum. Infiltration of wall of intestine producing marked irregularity with a little dilatation. Absence of mucosal pattern due to invasion by neoplasm. Segment involved longer than with carcinoma.

its size increases the pattern may be completely obliterated even though the mucosa has not been invaded by the lesion. With invasion of the mucosa, ulceration will be present (fig. 3), and this may be the only evidence of a neoplasm which has developed external to the lumen of the bowel. In the case which was recently reported by Collins,² the mass of the tumor was external to the lumen and no evidence of obstruction was present. Apart from the ulceration there was only slight alteration in the pattern of the mucosa and the lesion could easily have been overlooked had it not been for visualization of the crater.

The filling defects of neoplasm show morphologic characteristics which place them in one of three groups; the infiltrative defect, the annular or constricting defect, and the polypoid mass. The infiltrative defect is more common in lesions which are intramural in origin, of which lymphosarcoma (fig. 4) is an example. These tumors may show involvement of a rather long segment of intestine when they are first discovered and may even resemble inflammatory changes in the roentgenogram. Ulceration may or may not be present, as in many cases the mucosa may not be destroyed even though the infiltration be extensive.

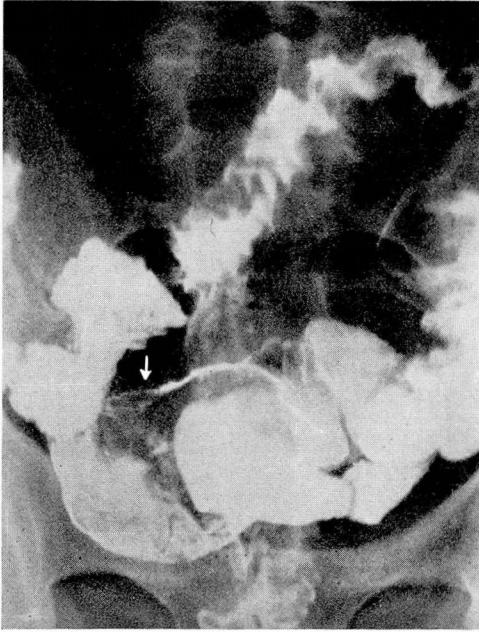


FIG. 5. Spindle cell sarcoma of ileum. On examination of colon neoplasm visualized by reflux barium through ileocecal valve. Tumor almost entirely outside of the bowel but produced polypoid filling defect by pressure on the lumen.

Rigidity of the intestinal wall is apparent during the roentgen examination and this feature is especially prominent during the fluoroscopic examination. It is during this phase of the examination that the lack of peristaltic movement through the involved segment is most striking. The lumen may show narrowing as well as infiltration but this is not always true in neoplastic disease. The annular defect is highly suggestive of carcinoma, particularly so if the appearance is that of a "napkin ring" deformity with involvement of a short segment. These appearances must be differentiated from inflammatory changes. In the latter condition the involved segment is usually longer and the margins of the process are not so sharply defined. Also with inflammatory lesions there may be surrounding adhesions which are demonstrable at the time of fluoroscopic examination by fixation of the bowel. With involvement of a short segment in inflammatory disease or a longer segment in the case of neoplasm, it may be impossible to make a definite diagnosis before operation.

Polypoid filling defects are, as a rule, well-defined negative shadows within the lumen of the bowel and are most often due to tumor of

mucosal origin. Tumors of intramural origin may simulate this appearance if they project into the lumen of the bowel in the course of their development (fig. 5). Benign tumors most frequently present a polypoid appearance and with no other changes present it may be possible to differentiate them from malignant tumors.

Conclusion

Malignant tumors of the small intestine, although not common, should be considered in patients having obscure gastrointestinal symptoms or intestinal bleeding from undetermined origin. These tumors show the same morphologic characteristics as they do elsewhere in the gastrointestinal tract, and a high percentage may be diagnosed by special roentgen examination.

References

1. Ewing, James: *Neoplastic Diseases*. 4th ed. (Philadelphia: W. B. Saunders Co., 1941).
2. Collins, E. N., and Spencer, F.: Massive hemorrhage (melena) due to leiomyosarcoma of jejunum. *Cleveland Clin. Quart.* **14**:1-6 (Jan.) 1947.