

EOSINOPHILIC GRANULOMA

Report of a Case with Both Osseous and Cutaneous Lesions

JAMES I. KENDRICK, M.D., and J. B. WOODRUFF, JR., M.D.

Department of Orthopedics

EOSINOPHILIC granuloma of bone was first recognized as a clinical entity during the past decade.^{1,2,3} It is a destructive type of lesion involving usually the interior of the flat bones but occasionally the long bones. Not until a recent publication by Curtis and Cawley⁴ have cutaneous manifestations been attributed to this condition, nor has the relationship between the osseous and skin lesions been established,⁵ although such a relationship has been suggested.⁶

The case which we are reporting is of special interest because of the patient's age and the manifestation of both osseous and cutaneous lesions.

Case Report

A white baby girl, aged 12 weeks, was first seen at the Cleveland Clinic on March 4, 1946. The parents related that ten days previously they had noted that the child was protecting her right arm. On inspection of the shoulder a swelling was noted in the region of the scapula. The past history revealed that at birth delivery had been spontaneous and the weight was 8.5 pounds. Shortly afterward a papular rash was noted in scattered areas over the child's body. She had gained steadily until the onset of pain in the right shoulder.

On physical examination it was observed that movement of the right shoulder caused some pain. In the infraspinous portion of the scapula a fusiform thickening was palpated, which was smooth, slightly tender, and moved freely with the scapula. Over the chest, back, and buttocks there was a slightly scaly rash (fig. 1). These lesions were dull red in color and simulated an impetiginous eruption.

The laboratory examinations revealed a mild degree of secondary anemia. There was an elevation in the leukocyte count to 17,800, with the differential count showing 56 per cent polymorphonuclear cells, 34 per cent lymphocytes, 2 per cent eosinophils, and 8 per cent monocytes. The blood cholesterol level was within normal limits. The Wassermann and Kahn tests were negative.

Roentgenologic Examination. Roentgenograms were made of all the bones. The roentgenograms of the scapula (fig. 2a) showed expansion of the bone below the spine and evidence of osteolysis, but the cortex was not invaded. The left fifth rib contained a similar lesion, and the eleventh dorsal vertebra showed some narrowing and several small areas of osteolysis.

Pathologic Examination. A biopsy of the scapula, recommended at the time of examination, was done elsewhere and the tissue obtained was forwarded to us for examination.

The formalin-fixed specimens were prepared with hematoxylin and eosin stain. A section from a cutaneous lesion (fig. 3a) was also studied and revealed a localized area in the upper corium comprised of a dense, compact infiltration of lymphocytes, large mononuclear cells, and frequent eosinophils in small patches involving the superficial portion of the skin and extending downward to surround a hair follicle and several sweat glands. Over the entire extent of the lesion the epidermis was absent, being resumed with normal configuration at the immediate margin of the lesion.

Sections from a cancellous portion of the scapula (fig. 3b) revealed patches of callus

EOSINOPHILIC GRANULOMA

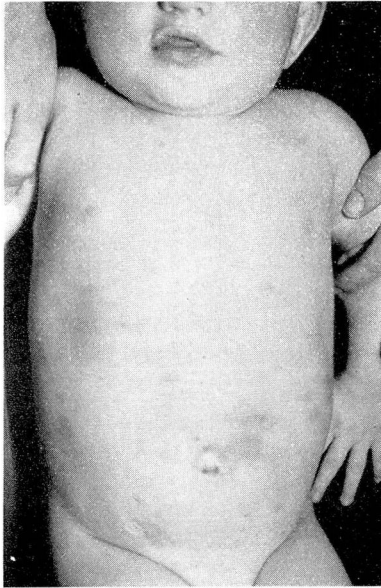


FIG. 1. Cutaneous lesions of the chest and abdomen.

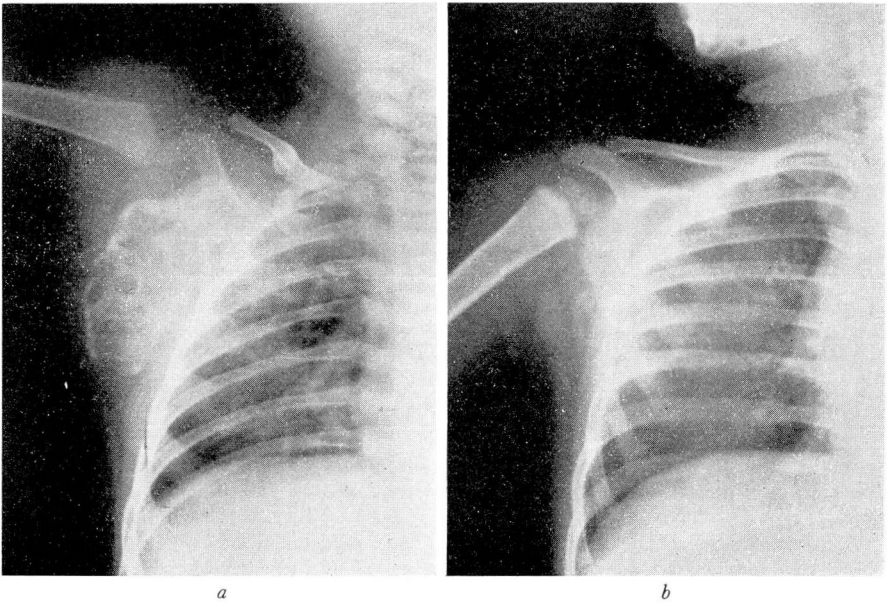


FIG. 2. (a) Initial appearance of scapular lesion. (b) Scapular lesion sixteen months after treatment.

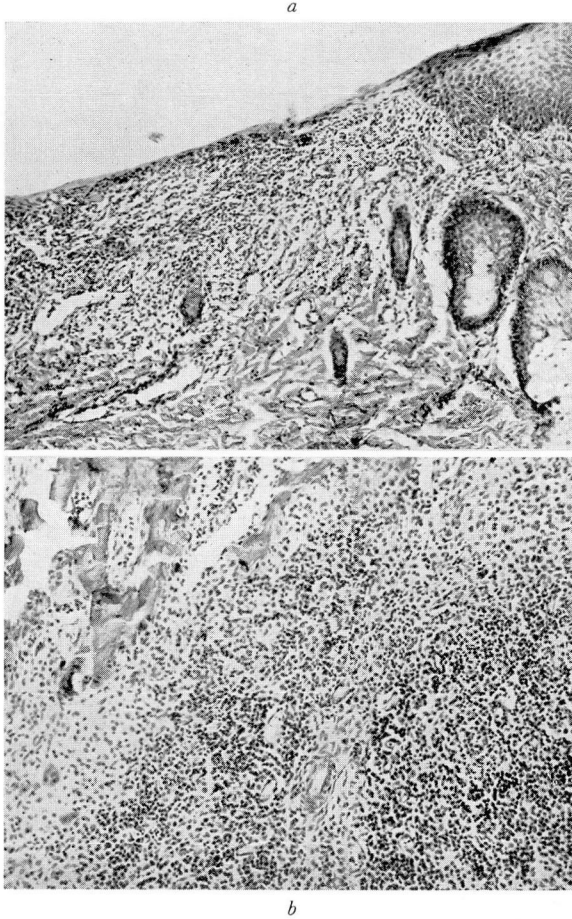


FIG. 3. Lymphocytic infiltration of upper corium, patches of histiocytes, scattered eosinophils. Epidermis thinned or absent over lesion (x50). (b) Large foci of eosinophils, zones of histiocytes including one giant cell in bone (x50).

contiguous to cellular granulation tissue composed of many histiocytic cells, masses of eosinophils, and occasional patches of lymphocytes. Many small multinucleated giant cells of the osteoclastic type were present in the cellular tissue adjoining the bone and also adjacent to the callus. The surrounding dense connective tissue was also infiltrated by patches of the above-mentioned cells. One small area of infarct type necrosis was noted.

Clinical Course. Radiation therapy was instituted on April 23, 1946, and was given in divided exposures over a period of three days. A total of 200 r was given to the scapula and eleventh dorsal vertebra and 150 r to the rib.

An examination of the patient on May 27, five weeks after the radiation therapy, revealed considerable improvement in the cutaneous lesions and clinical improvement in use of the arm but no reduction in size of the scapula.

A roentgenologic examination made on August 20, four months after the radiation therapy, revealed marked improvement, and the child had no discomfort in her arm.

EOSINOPHILIC GRANULOMA

The child was last seen on August 19, 1947. Her development had been normal and at that time she was in excellent health. The skin lesions were healed with small areas of scarring. There was a scar over the lower portion of the scapula where the biopsy had been made, but there was no evidence of abnormality in the contour of the scapula or of dysfunction in the arm. A roentgenogram (fig. 2b) made at that time showed that the osseous lesions had completely healed and the bones had assumed their normal texture and contour.

Summary

The case of eosinophilic granuloma of the bone discussed is believed to represent the youngest patient reported in the literature. The patient exhibited skin lesions which are probably cutaneous manifestations of this disease.

References

1. Lichtenstein, L., and Jaffe, H. L.: Eosinophilic granuloma of bone, with report of case. *Am. J. Path.* **16**:595-604 (Sept.) 1940.
2. Otani, S., and Ehrlich, J. C.: Solitary granuloma of bone simulating primary neoplasm. *Am. J. Path.* **16**:479-490 (July) 1940.
3. Green, W. T., and Farber, S.: "Eosinophilic or solitary granuloma" of bone. *J. Bone and Joint Surg.* **24**:499-526 (July) 1942.
4. Curtis, A. C., and Cawley, E. P.: Eosinophilic granuloma of bone with cutaneous manifestations; report of case. *Arch. Derm. and Syph.* **55**:810-818 (June) 1947.
5. Weidman, F. D.: "Eosinophilic granulomas" of skin. *Arch. Derm. and Syph.* **55**:155-175 (Feb.) 1947.
6. Lever, W. F.: Eosinophilic granuloma of skin; its relationship to erythema elevatum diutinum and eosinophilic granuloma of bone; report of case. *Arch. Derm. and Syph.* **55**:194-211 (Feb.) 1947.