

# CHONDROMA OF THE LARYNX

## *Report of a Case*

PAUL M. MOORE, JR., M.D.

Department of Otolaryngology

THE rarity of chondromata of the larynx is attested by the relatively small number of cases which have been reported. The first comprehensive survey of the world's literature was made by Irwin Moore<sup>1</sup> in 1925. He collected 53 cases which he considered true cartilaginous tumors. The most recent survey (1944) was made by McCall, Dupertuis, and Gardiner,<sup>2</sup> who collected an additional 30 cases since Moore's report. They have summarized each case and have added 2 of their own, making a total of 85 cases. A case reported by Rosedale<sup>3</sup> and the one herewith reported bring the total to 87 cases.

The most frequent site of development of chondroma of the larynx is the endolaryngeal surface of the posterior plate of the cricoid cartilage. The next is the thyroid cartilage, then the epiglottis and the arytenoid cartilage. In Rosedale's case the chondroma arose from the cricoid cartilage, while in ours the tumor had its origin in the left ala of the thyroid cartilage.

Hoarseness and dyspnea are the commonest symptoms, and cough or dysphagia may develop. There may be an external deformity in the neck when the chondroma arises from the thyroid cartilage. The symptoms are caused by obstruction of the airway and interference with the function of the larynx, and they depend upon the location and size of the tumor. Since these tumors usually grow slowly the symptoms increase so gradually that the chondroma may be very large before the patient seeks relief.

The chondroma is usually smooth, rounded, hard, non-compressible, and is covered by a normal or thinned mucous membrane in which the blood-vessels are often prominent. It is firmly attached to the cartilaginous box of the larynx.

The only treatment for this condition is surgical removal of the tumor, the method depending upon its size and location. Direct laryngoscopy and endolaryngeal removal is successful when the tumor is small and accessible, but as the chondroma becomes larger more extensive procedures are required. When it is attached to the cricoid cartilage, laryngofissure with complete removal of the growth is the method of choice. If it arises from the thyroid cartilage it may be removed by an external approach and submucous resection or morcellation without incising or removing any of the laryngeal mucosa. It is necessary to remove every fragment of the tumor with a fairly wide margin of the thyroid cartilage around its attachment in order to avoid recurrence. This method was employed by New<sup>4</sup> in a case reported in 1918, Waggett<sup>5</sup> in 1921 and again in 1925,<sup>6</sup> Neilson<sup>7</sup> in 1929, Figi<sup>8</sup> in 1932, Holinger and Matzkin<sup>9</sup> in 1942, and in the case reported in this paper. In Waggett's case there was

a recurrence in three years, and a more extensive removal with laryngeal mucosa was performed. In Figi's patient the chondroma recurred six years later, at which time a laryngectomy was advised and refused. All of the procedures mentioned leave a normally functioning larynx. A total laryngectomy is required when the chondroma has attained such size that its removal entails a sacrifice of a sufficient amount of the framework of the larynx to result in a collapse and stenosis. Laryngectomy has been done in 14 of the reported cases, including the 2 by McCall *et al.* and the 1 by Rosedale.

### Case Report

A white man, aged 60, came to the Cleveland Clinic on March 1, 1939. He stated that he had enjoyed excellent health until two years ago. At this time he noted a small growth in the left side of the neck just lateral to the Adam's apple. This had gradually increased in size. A slowly progressive hoarseness had developed and was constantly present, having become especially pronounced during the past two months. He had had a chronic non-productive cough and some dyspnea for the past three months. The dyspnea had increased so that some was present even while he was at rest. There had been no pain in the neck and no dysphagia or odynphagia. There had been no loss of weight or appetite.

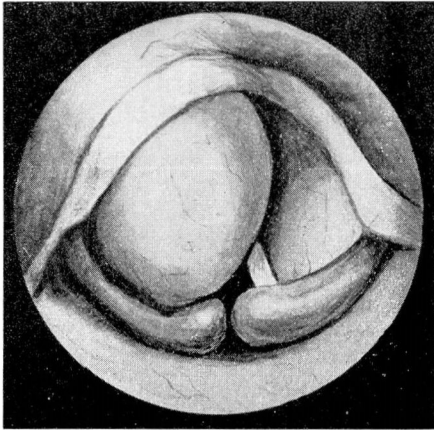


FIG. 1. View of larynx through laryngoscope.

The general physical examination revealed a muscular well developed man with a blood pressure of 165 systolic, 90 diastolic. There were no abnormal observations other than the tumor in the neck, which was the size of a large olive and was firmly attached to the left ala of the thyroid cartilage. It was of hard consistency and was not tender to palpation. The mass moved with the larynx during the act of swallowing and of speaking. The skin was freely movable over the tumor and appeared normal. There was no palpable cervical adenopathy.

The sinuses were clear to transillumination. The nasal passages showed no abnormalities. There were only a few lower teeth remaining, and these showed signs of oral neglect. The tonsils were of moderate size. The ears contained some moist debris.

Mirror laryngoscopy revealed a marked distortion of the larynx. There was a large, smooth, rounded tumor mass above the glottis and in the region of the left aryepiglottic fold. This mass was so large that neither vocal cord could be visualized. The opening into the larynx was displaced to the right and the airway appeared restricted. The mucous membrane overlying the tumor mass was smooth and normal in appearance. On direct laryngoscopy (fig. 1)

the tumor was found to be hard and firmly attached to the laryngeal box. It could not be compressed or displaced to obtain a view of the cords. No biopsy was taken from the interior of the larynx.

Roentgenologic examination of the chest was negative. A lateral roentgenogram of the larynx (fig. 2) showed a large tumor with calcified walls.

A tentative diagnosis of chondroma of the larynx arising from the left ala of the thyroid cartilage was made.

The patient was admitted to the hospital on March 6, 1939, and the teeth were cleaned and the gums treated prophylactically in the Department of Dentistry. On March 7 a tracheotomy and surgical removal of the chondroma was performed. The tracheotomy was done because of the patient's dyspnea and the possibility that the surgical removal might temporarily increase the obstruction. Nembutal, morphine, and atropine were administered as pre-operative analgesia. Two per cent pontocaine was applied to the oropharynx, pyriform sinuses, epiglottis, and larynx. One-half per cent novocain was injected regionally into the neck. An orderly low tracheotomy was performed first. A second incision was then made horizontally over the tumor mass in the left side of the neck. This incision was about  $2\frac{1}{2}$  inches

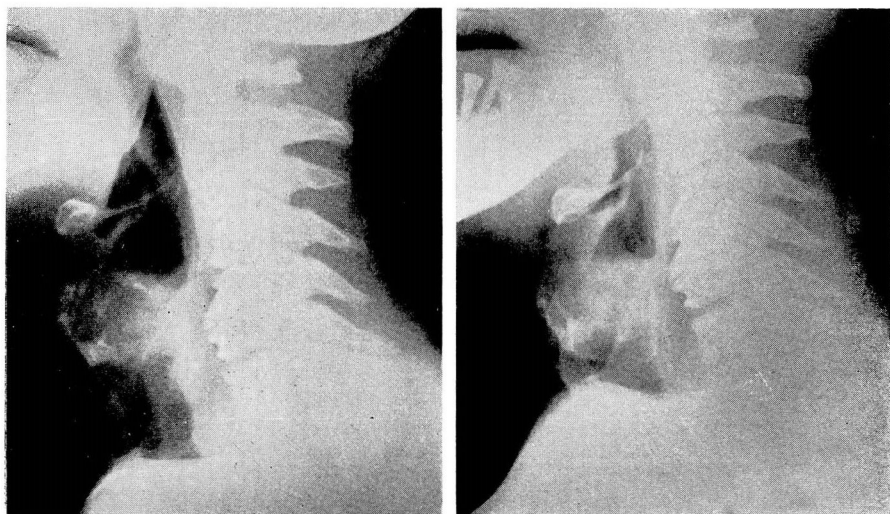


FIG. 2. Lateral roentgenograms of neck showing tumor mass in larynx.

long and extended to within  $\frac{1}{2}$  inch of the midline. The soft tissues were separated down to the tumor and the thyroid cartilage. A window was cut through the thyroid cartilage around the periphery of the external portion of the chondroma. The internal portion of the mass was removed by morcellation, using a large mastoid curette. This procedure was continued until every visible vestige of tumor had been removed from the mucous membrane of the interior of the larynx. The mucous membrane was not torn or incised. A small vaseline drain was inserted into the cavity, and the incisions were closed with buried catgut sutures in the fascia and muscle and with clips in the skin.

The tissue was examined by Dr. Allen Graham. The fragmented tumor mass weighed 20 Gm., and all of the pieces had similar gross characteristics suggestive of cartilaginous tissue with relatively no ossified tissue or gross bone. The microscopic examination showed well differentiated hyaline cartilage with no definite bone present and no histologic evidence of malignant disease.

The postoperative course was uneventful. A cork was placed in the tracheotomy tube on the third postoperative day, and the tube was removed on the sixth postoperative day.

The patient was discharged from the hospital on the eighth postoperative day. On March 27, 1939, the operative wounds were entirely healed, and he was told to return in one month for observation.

He returned on August 24, 1943, complaining that for the past six months he had experienced trouble breathing when he walked rapidly and climbed stairs. He had noticed an external lump in the neck for the past year. Examination showed a recurrence of the chondroma of the larynx, causing some external deformity over the left wing of the thyroid cartilage. Laryngoscopy revealed a larger internal mass displacing the left side of the larynx across the midline and narrowing the glottis to a small chink. The left cord appeared fixed. Lateral roentgenograms of the neck again showed a large tumor mass involving the larynx, estimated to be about 4 cm. in diameter. The advisability of doing a total laryngectomy was discussed with the patient and his family, but since he was now 64 years old and the previous operation had given him four and one-half years of comfort, it was decided to remove the tumor again by morcellation. He was admitted to the hospital on September 8, 1943. On September 9 a tracheotomy was again performed and the chondroma removed by morcellation under local anesthesia combined with sodium pentothal. Almost all of the left wing of the thyroid cartilage was removed at this time. On the sixth postoperative day the tracheotomy tube was closed with a cork, and the tube itself was removed on the eighth postoperative day. He was discharged on the tenth postoperative day. He returned faithfully until the tracheotomy wound was completely healed but did not come in for follow-up observation.

On August 24, 1946, he returned with a third recurrence of the chondroma. This time it was only a small, hard, freely movable mass attached to the skin at the level of the thyroid cartilage on the left side of the neck. There was no encroachment on the interior of the larynx. The vocal cords were normal in appearance and in movement, and the voice was of excellent quality. Since this recurrent mass was small, not attached to the larynx, and just beneath the skin, he was not admitted to the hospital. The mass including the skin to which it was attached was removed by dissection under local anesthesia, and he was allowed to return home.

The specimen consisted of tissue from the left cervical region. On gross examination there was an elliptical portion of skin 3.2 x 1.2 cm. with hair stubble and several clamp marks incident to the surgical procedure. Beneath the skin was an ovoid mass 2 x 1.8 x 1.6 cm., the external surface of which was nodular. It was firm and semi-elastic, pale gray, and semi-translucent. A small amount of fatty tissue was attached to the surface.

It cut with resistance and presented a cystic center 1.5 cm. in greatest diameter, filled with a thick, mucoid, colorless liquid. The wall was 0.3 cm. in thickness, white, homogeneous, hard, and scraped with a grating sensation. It had the appearance of cartilage.

Upon microscopic examination the nodule was comprised of hyaline cartilage with nuclei irregularly clumped but fairly well lacunated. There was some variation in nuclear size, but no mitoses were found. There was an irregular bluish staining zone free from nuclei in the center. A thin zone of fibrous tissue surrounded the nodule, growing in the corium and apparently not in the subcutaneous layer.

### Summary

A chondroma of the larynx in a man 60 years old is reported. This rose from the left ala of the thyroid cartilage, presenting a large obstructing mass within the laryngeal box and a smaller external extension into the neck. The tumor was removed in 1939 by morcellation, using an external approach. A portion of the thyroid cartilage was removed from around the point of attachment. The interior of the larynx was not entered. The patient returned with a recurrence four and one-half years later, at which time the tumor was almost as large as the original one and was again causing signs of laryngeal obstruction. The same method of removal was used, but, in addition, the left ala of the thyroid cartilage was removed. There was a third recurrence three years later, but the mass was quite small and was attached to the skin but not to the

larynx. Malignant changes did not develop in this growth. During the seven years that the patient was under observation and treatment he had had normal function of the larynx except for relatively short periods before and after operation. The first recurrence may have been the result of removing too small an amount of thyroid cartilage from around the attachment of the chondroma.

#### References

1. Moore, I.: Cartilaginous tumours of larynx. *J. Laryngol. and Otol.* **40**:9-14 (Jan.), 81-109 (Feb.), 145-164 (March) 1925.
2. McCall, J. W., Dupertuis, S. M., and Gardiner, F. S.: Chondroma of larynx; review of literature and report of 2 cases. *Laryngoscope* **54**:1-17 (Jan.) 1944.
3. Rosedale, R. S.: Laryngeal chondroma. *Arch. Otolaryng.* **45**:543-549 (May) 1947.
4. New, G. B.: Cartilaginous tumors of larynx. *Laryngoscope* **28**:367 (May) 1918.
5. Waggett, E. B.: Chondroma of cricoid. *J. Laryngol. and Otol.* **36**:338 (July) 1921.
6. Idem: Chondroma of cricoid cartilage of larynx. *J. Laryngol. and Otol.* **40**:27 (Jan.) 1925.
7. Neilson, D. F. A.: Chondroma of thyroid cartilage. *J. Laryng. and Otol.* **44**:127-130 (Feb.) 1929.
8. Figi, F. A.: Chondroma of larynx; report of 6 cases. *Ann. Otol. Rhin. and Laryng.* **41**: 369-386 (June) 1932.
9. Holinger, P. H., and Matzkin, L. L.: Chondroma of larynx. *Arch. Otolaryng.* **35**:640-645 (April) 1942.