

THE USE OF TANTALUM TUBES IN FRONTAL SINUS SURGERY

HAROLD E. HARRIS, M.D.

Department of Otolaryngology

OPERATIONS on the frontal sinus at times produce unsatisfactory results. Analysis of the causes of failure is helpful, but improved technics are still needed.

Among the causes of failure of the radical frontal operation are:

- (1) Incomplete removal of the floor of the frontal sinus which may result in a partitioning and formation of pockets in the remaining portion of the sinus cavity.
- (2) Incomplete ethmoidectomy leaving the orbital ethmoid cell extension undisturbed.
- (3) Removal of the frontal process of the superior maxilla, allowing collapse of the nasofrontal passage from pressure of the orbital soft tissues.

Even when careful technic is observed and complete removal of the floor of the frontal sinus and the ethmoid cells is accomplished as in the Lynch operation for ethmoid and frontal chronic sinusitis, 20 per cent of the operations result in failure because of adhesions and closure of the nasofrontal duct.

Several precautions should be taken to prevent closure of the nasofrontal passage. An opening is usually made through the nose into the frontal sinus. It should be large enough to ensure subsequent drainage of the sinus when healing has occurred. At the time of operation the communication appears unnecessarily large, but the processes of healing render it incredibly small.

The tendency to closure may be prevented by leaving the frontal process of the maxilla undisturbed, thus preventing the orbital periosteum from moving mesially. Patency of the opening is best assured by the use of tantalum tubes. These tubes are inert in the tissues and do not interfere with epithelization. The tube is placed in the newly created nasofrontal communication with the upper end in the frontal sinus and the lower end protruding from the nostril. The presence of the tube prevents granulation tissue from covering surfaces denuded of epithelium and from bridging and obstructing the nasofrontal passage. If contact of the granulation tissue on opposite sides can be prevented, complete epithelization of the surfaces will occur. Tantalum tubes are light in weight, cause no discomfort, and provide free exit for secretions from the frontal sinus. Since there is no reaction in tissue surrounding the tantalum tube, such as edema of the mucous membrane and formation of granulation tissue, secretions do not become "sealed off" but continue to drain through and around the tube.

Welded tantalum tubes* 5 mm., 7½ mm., and 10 mm. in diameter are used to accommodate the space between the frontal process of the maxilla,

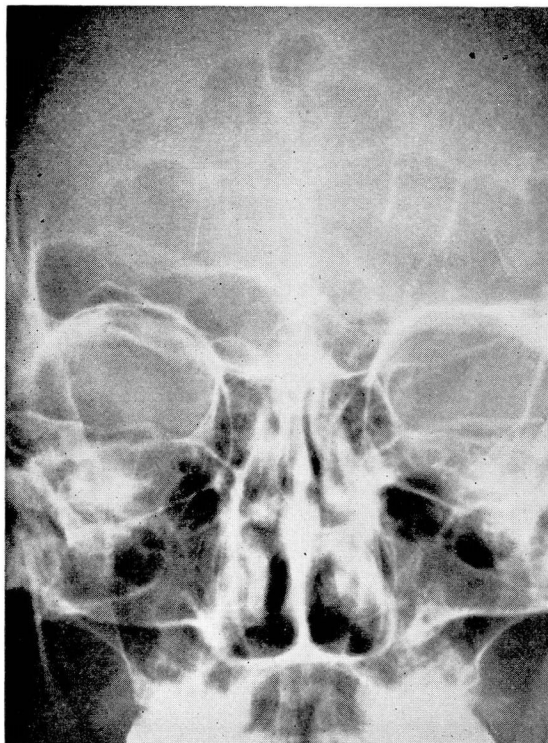*The tantalum tubes were supplied by the Ethicon Division of Johnson & Johnson.

the interfrontal septum, and the spine of the frontal bone. The 10 mm. tube is used when the frontal spine has been removed at a previous operation or when its removal has been necessary because of infected bone or to expose the anterior ethmoid region. Occasionally, the frontal spine has disappeared due to erosion caused by pressure of a mucocele.

The tantalum is fixed in position by a No. 28 tantalum wire, which is introduced through a small hole 1 mm. from the end of the tube. The two ends of the wire are drawn out through the skin incision and anchored to the forehead by adhesive tape or by a wire suture.

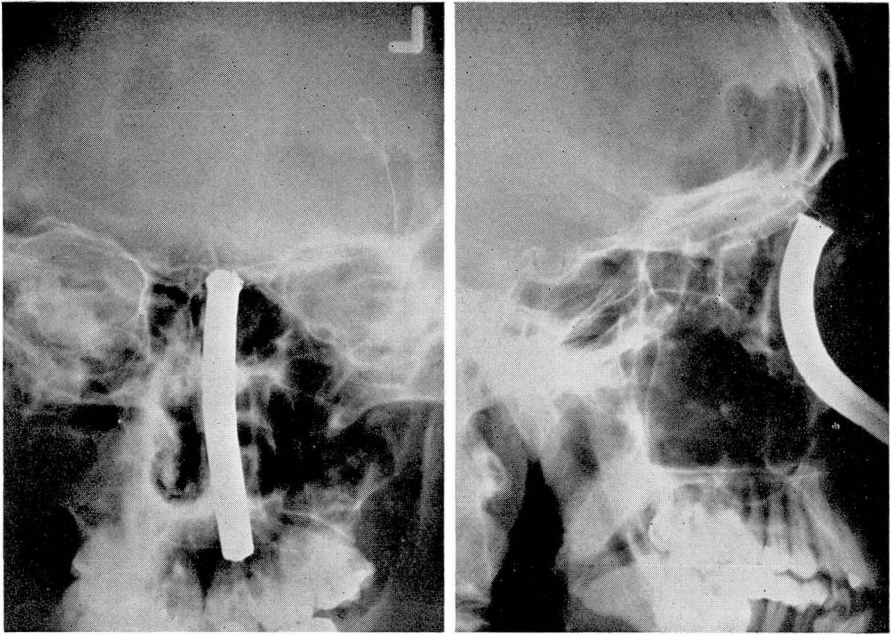
Following operation the tube is cleaned by means of inserting a small curved metal suction tube or a small sterile rubber catheter connected to a suction machine. The tantalum tube remains in position from four to six weeks, depending upon conditions of the nasofrontal passage. At the end of this time epithelization is completed and a well healed nasofrontal communication has resulted.

In 1945 Goodale¹ reported his experience with sheets of tantalum foil to prevent the surface of the orbital periosteum from coming into contact with



a.

FIG. 1. Case 1. (a) Preoperative roentgenogram reveals bilateral large orbital ethmoid extensions with cloudiness of frontal sinuses.



b.

FIG. 1. Case 1. (b) Postoperative anteroposterior and lateral films of the frontal and ethmoid sinuses reveal tantalum tube anchored with tantalum wire in nasofrontal passage.

the medial wall of the nasofrontal passage. He found that when the tantalum foil was used the nasofrontal passage remained open.

Case Reports

Case 1. A man, aged 42, entered the Cleveland Clinic on July 25, 1947, with the complaint of "frontal sinus trouble" present since 1922. He had undergone three operations upon the frontal sinus by the external approach, the first in 1928 and the last in 1940. He had suffered from intermittent frontal headaches and recurrent swelling above the left eye. In 1946 a fistula had developed in the mid-supraorbital region.

Preoperative roentgenograms revealed bilateral, large, orbital, ethmoid cells with cloudiness of both frontal sinuses.

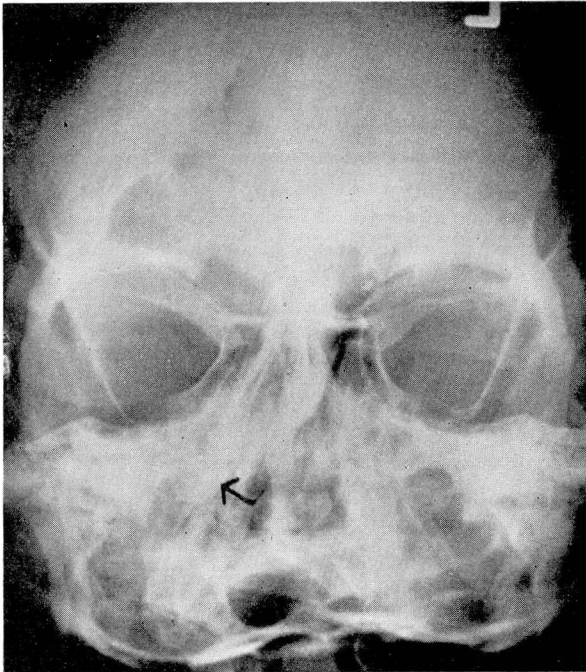
A radical left external frontal operation was performed, removing the entire floor of this sinus, all of the lining membrane, a portion of the anterior wall which showed dehiscence and evidence of localized osteomyelitis, and all of the left ethmoid, including the large orbital ethmoid cells, which contained pus and thickened mucous membrane. The right frontal sinus was entered through the interfrontal septum, and only mild thickening of the lining mucous membrane was encountered. No further procedure was carried out on the right frontal sinus. A curved tantalum tube $7\frac{1}{2}$ mm. in diameter was placed in the left nasal cavity through the newly created nasofrontal opening, with the upper end resting on the floor of the frontal sinus. The lower end of the tube protruded 4 mm. from the external naris. A tantalum wire was inserted through a small hole near the upper margin of the tube, was brought out through the external incision, and was anchored to the skin of the forehead with adhesive tape. The wire was taut to prevent the tantalum tube from sliding out of position.

The tube was removed during the fifth postoperative week. The external fistula has remained healed, the new frontal opening is large and patent, and the patient is entirely free of symptoms (fig. 1).

Case 2. A man, aged 35, was admitted to the Cleveland Clinic on February 1, 1945, complaining of a discharging fistula over the left eye and diplopia following a left external frontal operation in February, 1943. Nine years previously he had had severe pain over the left eye, lasting for one month. This was followed by a bilateral purulent nasal discharge which had continued until present admission. He had received intense sulfa and penicillin therapy without significant improvement.

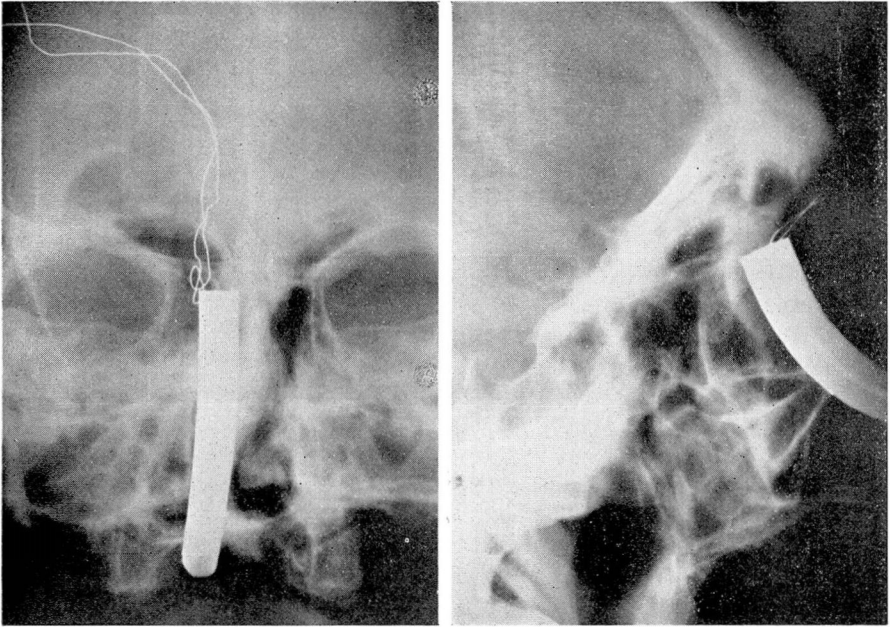
Preoperative roentgenograms revealed cloudiness of all the paranasal sinuses. On February 5, 1945, a bilateral intranasal antrotomy was carried out to eliminate the maxillary sinus infection. This was followed by a left external frontal operation (Lynch procedure). The orbital ethmoid extensions were removed and found to be filled with thickened mucous membrane and pus. The supraorbital fistula extended through a dehiscence in the floor of the frontal sinus, which, with all of the lining membrane, was completely removed. A tantalum tube was placed in the nose, with the upper end resting in the frontal sinus according to the method described in case 1. The patient made a prompt and complete recovery and has remained symptom-free. The nasofrontal passage now appears well epithelized and is free of granulations and surrounding edema.

Case 3. A man, aged 32, was admitted to the Cleveland Clinic with the complaint of intermittent swelling above the right eye of two years' duration. Trauma to the right frontal region in 1934 had been followed by frontal headaches, purulent anterior and posterior



a.

FIG. 2. Case 3. (a) Preoperative roentgenogram reveals cloudiness of right frontal sinus with absence of part of bony floor and anterior wall. Right ethmoid area is clouded by mucocele which protrudes into nasal cavity. Arrow points to nasal border of mucocele.



b.

FIG. 2. Case 3. (b) Postoperative roentgenograms show tantalum tube anchored *in situ*.

nasal discharge, and nasal obstruction on the right side. One year after the injury the patient had had a bilateral external frontal operation. In 1938 bilateral Caldwell-Luc operations and a second right external frontal operation had been performed.

Physical examination on admission revealed diplopia and edema of the right upper eyelid with closure of the palpebral fissure. Roentgenologic examination demonstrated a mucocoele of the right frontal sinus with partial absence of the bony floor and anterior wall. At operation the usual Lynch procedure was carried out, with removal of the mucocoele and mucous membrane lining the sinus cavity. A large tantalum tube was placed in the frontal sinus through the right side of the nose, as described in case 1, and anchored in the usual manner. The patient was discharged from the hospital with the tube in place. Upon follow-up examination eight weeks later the tube was removed and all swelling had disappeared. The patient has remained free of symptoms (fig. 2).

Summary

In spite of careful technic in surgery of the frontal sinus, postoperative closure of the nasofrontal passage may give rise to failure. A method involving the use of tantalum tubes will maintain a permanent communication between the frontal sinus and the nasal cavity and thus decrease the number of unfavorable results from this type of surgical procedure.

Reference

1. Goodale, R. L.: Use of tantalum in radical frontal sinus surgery. *Ann. Otol., Rhin. and Laryng.* 54:757-762 (Dec.) 1945.