

REIMPLANTATION OF THE URETER INTO THE BLADDER

J. G. WARDEN, M.D., and C. C. HIGGINS, M.D.

Department of Urology

THE operation of reimplantation of the ureter into the bladder has undergone a stormy course of criticism before being accepted as a sound surgical procedure. It may not have been frequently advocated, primarily because there was no satisfactory method of evaluating the status of the upper urinary tract and the end results without subjecting the patient to retrograde pyelography which might be unsatisfactory. However, with the advent of intravenous urography, a simple yet relatively innocuous procedure may be used to evaluate with accuracy those cases that can be submitted to this type of operation. Because of the increased number of cases amen-

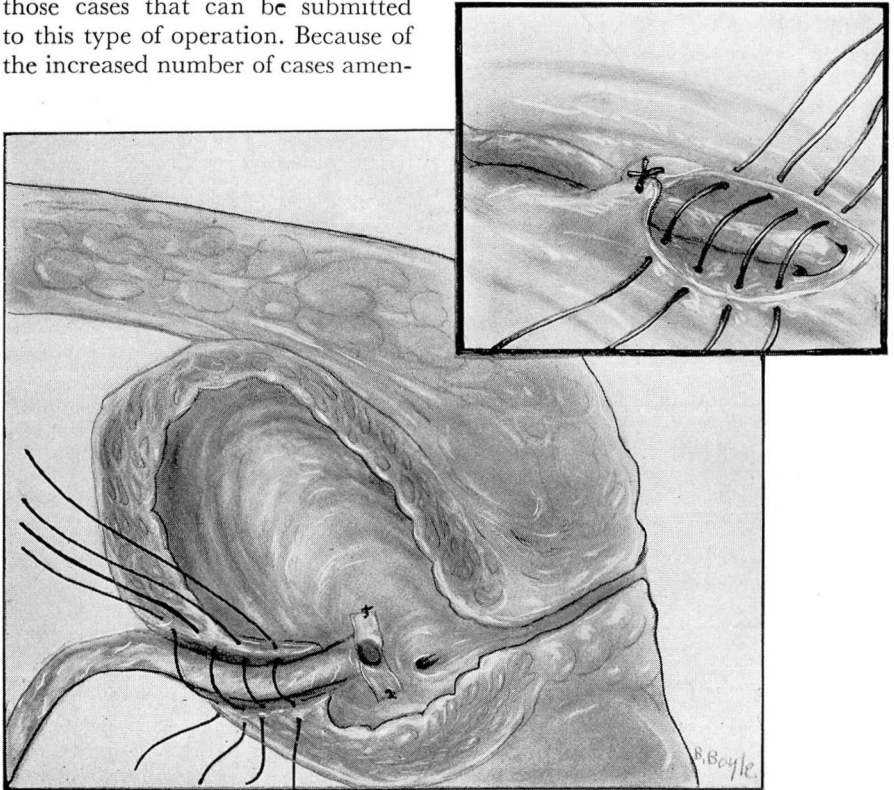


FIG. 1. Parasagittal section showing ureter in trough with sutures in place. Catheter not shown. Inset shows ureter from lateral view with sutures in place.

able for this type of surgical procedure observed recently by one of us (C. C. H.) at the Cleveland Clinic, a review of the results seems indicated.

Indications

Gynecological surgery has frequently been followed by complications necessitating reimplantation of the ureter. In recent years the increased use of combined abdominoperineal resection of the colon has also brought numerous cases to the urologist for which this surgical procedure was indicated.

A summary of indications for implantation is as follows:

1. Traumatic injuries to the lower ureter, e.g.
 - a. Complicating hysterectomy.
 - b. Complicating abdominoperineal resections.
 - c. Complicating manipulation of ureteral stones.
 - d. Complicating ureterolithotomy.
 - e. Complicating ruptured bladder.
 - f. Gunshot wounds.

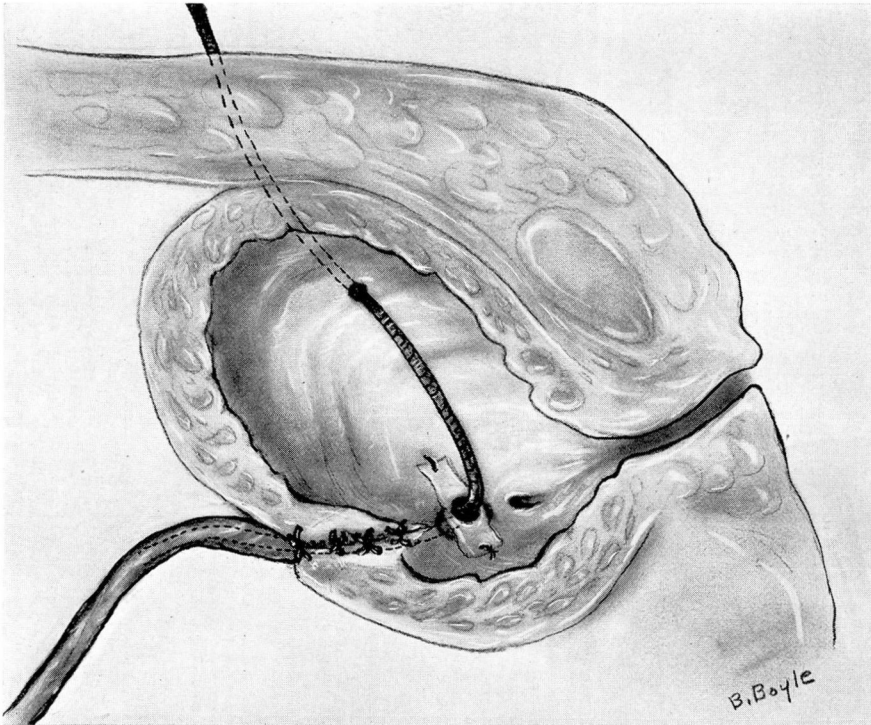


FIG. 2. Parasagittal section showing suture line closed. Ureteral catheter in place.

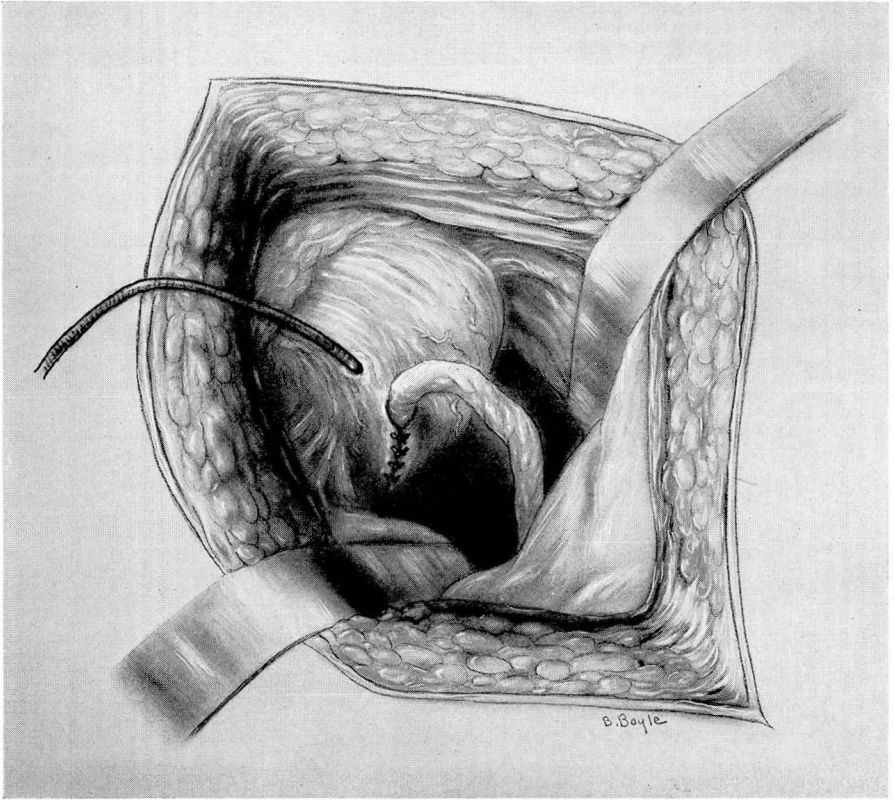


FIG. 3. Diagram demonstrating left reimplanted ureter with indwelling ureteral catheter through bladder wall.

2. Embryologic malformation of the lower ureter
 - a. Ectopic ureter.
 - b. Congenital ureteral valves.
 - c. Stricture of the ureter.
 - d. Certain ureteroceles.
 - e. Ureteral diverticula.
3. Neoplastic involvement of the lower ureter
 - a. Bladder neoplasms in close proximity to the ureteral orifice.
 - b. Benign ureteral tumors.
4. Inflammatory involvement of the lower ureter
 - a. Coexisting with ureteral stones.
 - b. Associated with pelvic inflammatory disease.
5. Miscellaneous factors involving the lower ureter
 - a. Bladder diverticulum involving a ureteral orifice.

Before deciding to employ ureteral implantation, a urologic investigation is of paramount importance. A complete history and physical examination may reveal associated pathologic entities such as disseminated carcinomatosis, low cardiac reserve, or advanced arteriosclerosis thereby making such a procedure hazardous. Cystoscopic examination is important in detecting a suitable site for implantation in the bladder. An attempted retrograde pyelography should be performed because of the valuable information to be gained by this study. At the time this is done specimens of urine may be collected for culture so that preoperative and postoperative chemotherapy will be specific in case of bacterial invasion. But by far the most important procedure for evaluation of the urinary status is the intravenous urogram. By this method it can be ascertained whether the renal and ureteral damage is serious enough to contraindicate reimplantation. The location of the ureteral stricture, the presence of ureteral anomalies, and the distance of the normal ureter from the bladder wall can all be determined by urographic study.

Further aids in evaluation of the urinary status consist of the injection of methylene blue into the bladder and intravenous injection of indigo carmine. By these two methods it can be determined whether a constant urinary fistula originates from the ureter or from the bladder.

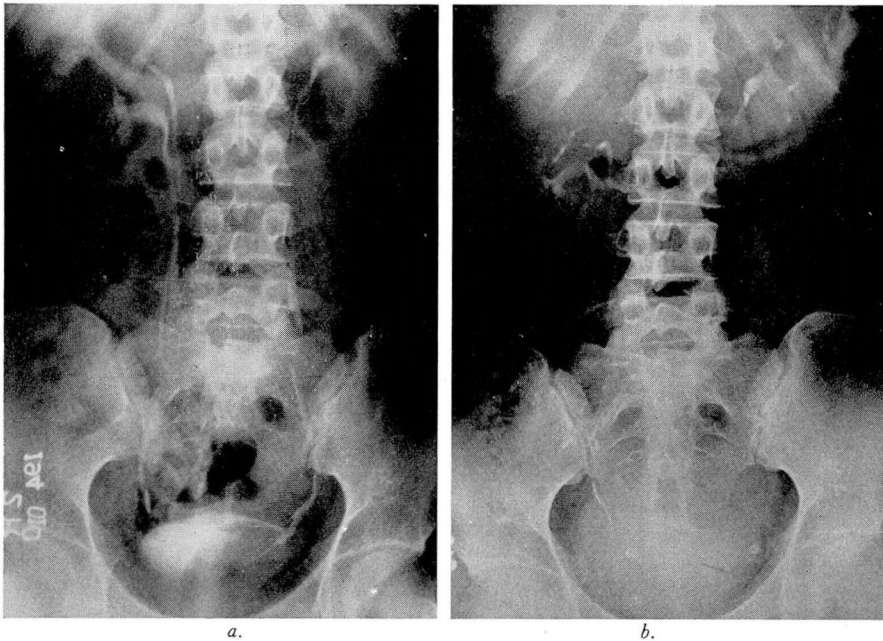


FIG. 4. (a) Preoperative film. Intravenous urogram showing severe bladder defect produced by bladder neoplasm. (b) Postoperative urogram showing normal urinary tract after left ureteral reimplantation.

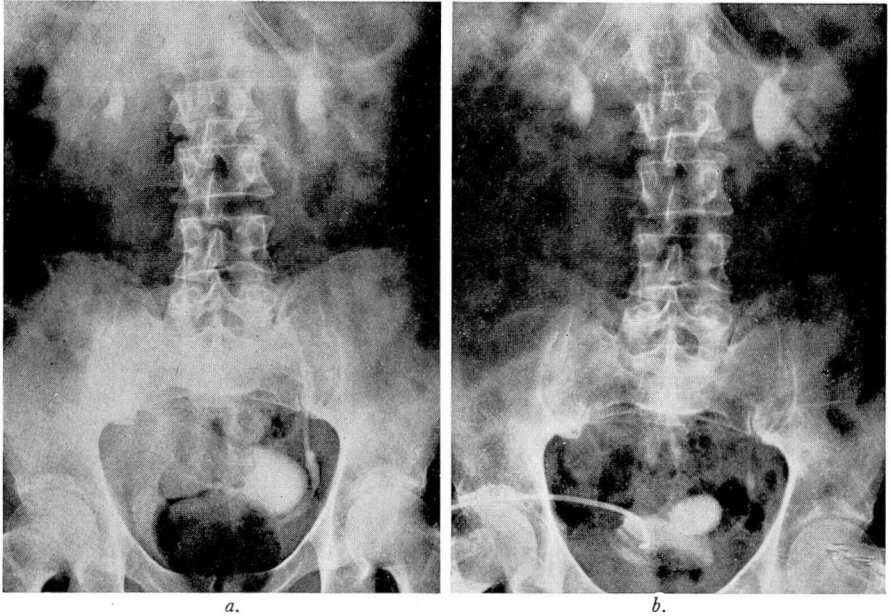


FIG. 5. (a) Preoperative urogram showing dilation of lower left ureter by obstructing bladder neoplasm. Coexisting diverticulum. (b) Postoperative urogram showing normal urinary tract after reimplantation of left ureter and excision bladder tumor. Note cystostomy tube and bladder diverticulum.

Procedure

Although no single operative procedure is applicable to all cases, a method not unlike the Coffey I method of ureterointestinal transplantation has been used in this group.

The abdominal wall is entered through a muscle splitting pararectus incision. The peritoneum is dissected medially from the lateral abdominal wall and the ureter is isolated. The latter is freed from surrounding tissues, great care being utilized to preserve its blood supply. The ureter is freed distally as far as is practicable and is then clamped and the distal end ligated. The proximal end of the ureter is then cut on the oblique and a No. 6 ureteral catheter inserted into the renal pelvis and anchored to the ureter (figs. 1, 2, 3).

The bladder is dissected free from the surrounding tissue. On the lateral side of the bladder, as near the previous ureteral orifice as possible, Allis clamps are applied and a trough incision is made down to the mucosa. The trough is further prepared by peeling the muscle layer from the mucosa for a distance of 1 cm. At the inferior end of the trough a stab incision is made through the mucosa and the ureteral catheter and ureter are pulled through for a distance of 1 inch into the lumen of the bladder. At this point the ureteral stump end is anchored by the use of 000 chromic catgut sutures through the mucosa, submucosal and muscular layers of the bladder. Several 00 chromic sutures are

placed through the ureteral adventitia and bladder mucosa for further support of the anastomosis.

Extreme care is exercised so to avoid placing undue tension on the suture line by a taut ureter.

The ureteral catheter is brought through a minute stab wound through the lateral bladder wall and out through the incision. A Penrose drain is placed down to the ureterovesical junction, and the abdominal wall closed with stainless steel sutures. A No. 22 balloon indwelling catheter is placed through the urethra into the bladder.

The following brief resume of case histories demonstrates the results obtained by using the above technic.

Case Reports

Case 1. A 20 year old white woman entered Cleveland Clinic on February 2, 1937 complaining of pain in the lower abdomen. The pain was dull in character, and aggravated by walking. For the past six months she had had nocturia two to three times but no hematuria or other urinary symptoms.

Physical examination did not disclose any serious abnormalities. There was some suprapubic tenderness to palpation over the abdomen.

Intravenous urogram was reported as normal, with the exception of a filling defect involving the left lateral wall of the bladder.

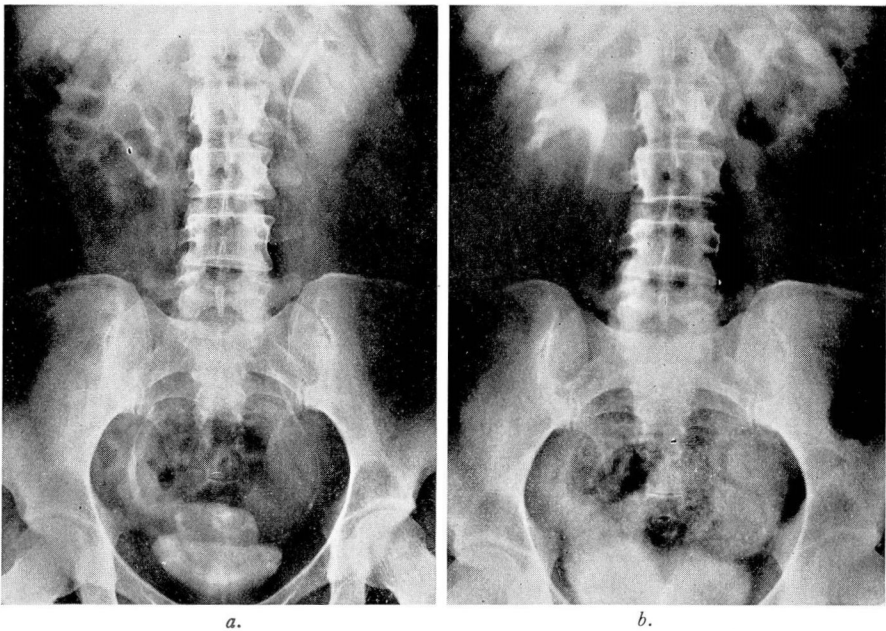


FIG. 6. (a) Preoperative urogram showing right ureter draining into vagina. (b) Postoperative film after right ureteral reimplantation. Normal upper urinary tract.

Cystoscopy revealed what was thought to be a large extravescical tumor, filling two-thirds of the bladder, and involving the left ureteral orifice. Because of the massive intravesical intrusion, suprapubic exploration was performed. After exposing the bladder wall a solid tumor was found involving the muscle walls, extending from the left ureteral orifice to nearly the vesical orifice. By means of sharp dissection a partial cystectomy was performed and the ureter then implanted into the bladder wall. The postoperative course was without complications and the indwelling ureteral catheter was removed on the seventeenth day. The pathologic diagnosis was lymphosarcoma of the bladder.

A recent urogram, eleven years after operation, shows an essentially normal urinary tract (fig. 4). Repeated cystoscopic examinations have revealed no recurrence of neoplasm.

Case 2. A 65 year old white man entered the Cleveland Clinic on April 14, 1947 with a history of hematuria of two weeks' duration, accompanied by obstructive vesical neck symptoms.

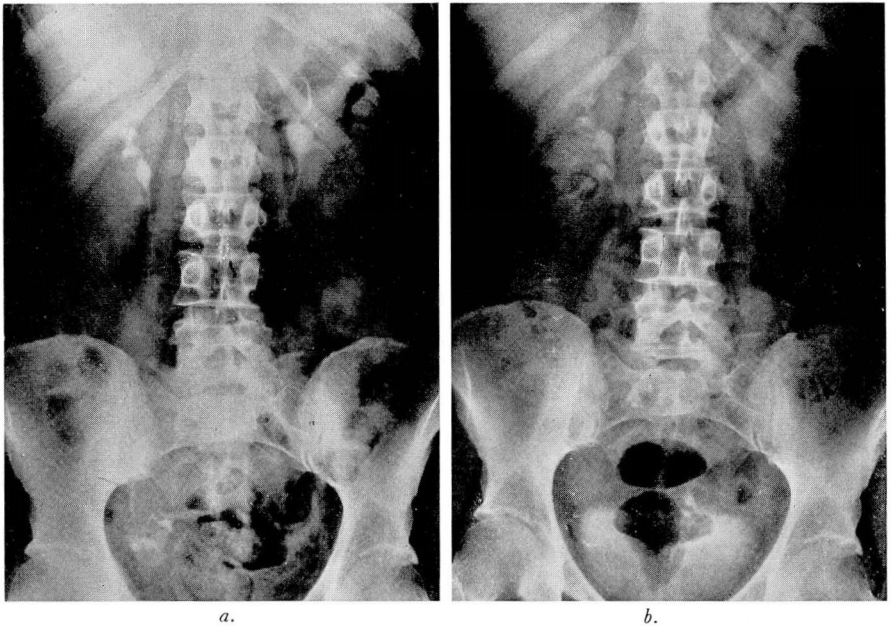


FIG. 7. (a) Preoperative urogram showing no dye in bladder. (b) Postoperative urogram after bilateral ureteral implantation showing normal upper urinary tract.

Physical examination revealed a well developed patient with no gross abnormalities. Cystoscopy disclosed a papillary, egg sized neoplasm immediately adjacent to the left ureteral orifice.

The intravenous urogram revealed normal kidney function, and the lower left ureter was dilated. The cystogram showed coarse trabeculation with several large diverticula. There was 450 cc. of residual urine.

Diagnosis was carcinoma of the bladder and hypertrophy of the prostate.

On April 24, 1947 a suprapubic excision of the bladder tumor and adjacent muscular wall was performed. The ureter was reimplemented into the bladder using the previously described procedure. A cystostomy tube was left in place, the ureteral catheter removed on the seventeenth postoperative day, and the patient was discharged from the hospital. The pathologic diagnosis was papillary transitional cell carcinoma of the bladder grade II.

The patient was readmitted to the hospital two months later and a transurethral resection of the prostate was performed.

Since operation the bladder has been examined every three months for neoplasm recurrences and at the same time ureteral dilations have been performed. There has been no recurrence and the upper urinary roentgenograms are normal (fig. 5).

Case 3. A 37 year old white woman was admitted to the Cleveland Clinic in 1947 with a history of continuous urinary drainage through the vagina following a complete abdominal hysterectomy performed six months previously. A repair operation had been instituted elsewhere two months prior to her admittance but this had been unsuccessful. General physical examination revealed no gross abnormalities.

Intravenous urogram showed enlargement of the right renal pelvis with tortuosity of the right ureter. The remainder of the urinary tract was normal.

Cystoscopic examination revealed a normal bladder with no evidence of fistula. A right ureteral catheterization disclosed an impassable obstruction approximately 3 cm. up the ureter. Methylene blue injected into the bladder did not appear on a vaginal pack but indigo carmine administered intravenously appeared on a vaginal pack in four minutes in excellent concentration. The left ureter was catheterized without difficulty.

Diagnosis was ureterovaginal fistula.

On February 4, 1948 through a suprapubic approach the right ureter was excised and reimplanted into the bladder by the method described.

Postoperative course was without complications and the indwelling ureteral catheter was removed on the fourteenth postoperative day, the urethral catheter was removed on the sixteenth day and the patient discharged on the seventh postoperative day.

At monthly intervals ureteral dilations have been performed until a normal urogram was obtained on the fifth postoperative month (fig. 6).

Case 4. A 51 year old white woman was admitted to the Cleveland Clinic on June 4, 1948 with a history of having had a hysterectomy performed elsewhere ten days previously for fibroids of the uterus. Immediately after operation total urinary incontinence was observed, and the patient had no desire to void.

Physical examination revealed a moderately obese white woman, with no gross abnormalities.

Cystoscopy did not show bladder fistula, but an attempt to catheterize the ureters met bilateral obstructions at approximately 2 cm. up the ureters. Methylene blue injected into the bladder did not appear in the vagina. However, intravenous injection of indigo carmine appeared in three minutes in the vagina in good concentration.

Intravenous urogram showed a normal upper urinary tract but both ureters revealed dilation in the lower thirds.

Vaginal examination disclosed excoriation of the mucosa and urinary seepage into the dome of the vagina.

Diagnosis was bilateral ureterovaginal fistula.

On June 12, 1948 the right ureter was implanted into the bladder and the indwelling ureteral catheter was removed on the thirteenth postoperative day. One month later a left ureteral implantation was performed and the indwelling ureteral catheter was removed on the sixteenth postoperative day. The patient was discharged from the hospital with excellent urinary control.

An intravenous urogram taken three and one-half months later shows essentially a normal urinary tract (fig. 7).

Summary

Reimplantation of the ureter into the bladder is a sound surgical procedure with which excellent results can be obtained. However, certain fundamental principles must be followed if failures are to be avoided.

A preliminary physical examination and thorough urologic investigation, including intravenous urogram, cystoscopy, and retrograde study is essential.

The particular operative method is probably immaterial provided adequate blood supply to the ureter is retained; the principle utilized, and a cuff of ureter is allowed to project into the bladder, without tension, for approximately 1 inch. The site of implantation is preferably near the original ureteral orifice and the importance of adequate splinting of the new ureterovesical junction with an indwelling ureteral catheter for a period of two weeks cannot be overemphasized. Complete relaxation of the bladder by use of a urethral catheter favors healing of the ureterovesical junction by further immobilization. Finally, drainage of the perivesical space with a Penrose drain to prevent collections of blood and tissue fluid at the anastomosis site is desirable.