

IDIOPATHIC STEATORRHEA

Report of Thirty Cases

CHARLES H. BROWN, M.D.

Department of Gastroenterology

IDIOPATHIC steatorrhea or sprue is a condition in which many of the nutritional principles, complications and therapeutic characteristics are equally applicable to other disorders producing malnutrition and steatorrhea.

Sprue or idiopathic steatorrhea may be defined as a chronic deficiency disease with a definite tendency to remission and relapse, characterized by glossitis, stomatitis, anorexia, gastrointestinal symptoms, by the passage of large frothy, foul-smelling stools, by great muscular wasting, nervous symptoms, decalcification, and in adults by a macrocytic hyperchromic anemia.

The etiology of steatorrhea or fatty stool may be classified as follows:

1. Lack of secretions
 - a. Lack of bile (calculi, carcinoma, etc.)
 - b. Lack of pancreatic secretions (calculi, chronic pancreatitis, neoplasm, cystic fibrosis)
2. "Secondary" sprue
 - a. Postgastrectomy
 - b. Gastrocolic and jejunocolic fistulae
 - c. Mesenteric lymph node disease (tuberculous, neoplasm)
 - d. Lymphatic obstruction
 - e. Intestinal lipodystrophy (Whipple's disease)
 - f. Regional enteritis
 - g. Sequelae of protozoan and bacillary dysenteries
 - h. Amyloidosis of small intestine
3. "Primary" sprue
 - a. Tropical sprue
 - b. Non-tropical sprue
 - c. Coeliac disease

The recent war stimulated medical interest in these diseases. One writer¹ observed more than 1000 cases of sprue in a prison camp. Also the introduction of folic acid and the work by Spies and his associates² aroused attention concerning sprue and allied conditions.

The **etiology** of sprue is still not understood. It was originally thought to be due to intestinal parasites, particularly the *Monilia* group of organisms; however, it is generally agreed that the finding of parasites in the stool is merely coincidental in these patients.

In sprue there is some change in the mucous membrane of the small bowel that results in impaired absorption of fat. There may be a defect in the phosphorylation of carbohydrates and fats; the latter are normally split in sprue

patients by the digestive juices but not absorbed. This lack of absorption results in the entire clinical picture:

1. Increased fat in the stool causes diarrhea.
2. Lack of absorption of the intrinsic factor causes macrocytic anemia.
3. Lack of absorption of calcium causes osteoporosis, dwarfism, skeletal changes and tetany.
4. Lack of absorption of vitamin D acts synergistically with the lack of calcium and causes similar changes.
5. Lack of absorption of vitamin A causes some of the skin changes and occasionally lens opacities.
6. Lack of vitamin K absorption may cause a hemorrhagic picture.
7. Lack of absorption of vitamin B components causes glossitis and stomatitis.

The primary defect in sprue—impaired fat absorption—is not corrected by specific therapy (folic acid or liver extract). Vitamin A tolerance curves remain flat despite treatment,³ indicating that the primary defect is still present.

Pathologically, little is found. Many workers have failed to discover significant changes in the intestines when an autopsy was performed immediately. The intestines may be thin and atrophic; the fat deposits of the body are depleted and there is generalized atrophy of all internal organs. Castle⁴ has shown that the liver in sprue patients lacks the erythrocyte maturing factor. Spies² has described distinct shortening and blunting of the villi, accompanied by an increase in the number of plasma cells in the tunica propria in about one half of autopsied sprue patients. Bone marrow changes are not distinguishable from those accompanying pernicious anemia.

The **clinical picture** of sprue is often confusing. The onset is usually insidious with a history of a previous debilitating illness such as malaria or dysentery or with a poor nutritional history. Gastrointestinal symptoms of anorexia, flatulence, epigastric fullness appear. The dyspepsia, anorexia, and abdominal discomfort increase until the patient becomes a chronic dyspeptic, further limiting his dietary intake. The tongue and mouth become sore, with aphthae developing and with the tongue assuming a bald beefy red appearance. The patient passes semi-solid or fluid stools that are frequently foul smelling, or occasionally one large stool a day. In addition he loses considerable weight. Ashford⁵ stated that, "Sprue literally dissects its victim." The skin develops a dirty brownish yellow color with patchy pigmentation of the forehead and malar eminences. Unlike Addison's disease there is no pigmentation of the mucous membrane. Edema, due to the low dietary protein intake, may develop; this was common in the sprue seen in prison camps in the recent war. There may be a central nervous system irritability with vague aches and pains, paresthesias of the hands and feet. Subacute combined degeneration occurs rarely.

Complications of sprue may be the primary complaint of the patient, particularly in northern climates. There may be lens opacities due to vitamin A deficiency, a bleeding tendency because of lack of vitamin K, tetany due to a

low serum calcium, osteoporosis in adults and dwarfism and rickets attributable to lack of absorption of vitamin D and a negative calcium balance. Backache caused by osteoporosis or bleeding may hasten a consultation.

In the past ten years, 30 cases of sprue have been observed at the Cleveland Clinic. The complaints of these patients are listed in Table 1.

TABLE 1.
Symptoms in Sprue Patients at the Cleveland Clinic

Symptom	No. of Cases (30)
Diarrhea	27
Loss of over 20 pounds	21
Sore tongue	12
Flatulence	11
Edema	8
Osteoporosis (symptoms from)	6
Tetany	5
Anorexia	5
Hemorrhage	3
Pernicious anemia	1

The duration of symptoms in our cases was less than one year in 8 cases, one to five years in 16 cases and over five years in 6 cases.

In our experience many patients presented themselves with symptoms of complications of sprue, rather than with the usual cardinal symptoms of the condition. Frequently it is only by direct questioning that the history of diarrhea or a sore tongue may be elicited.

One patient complained of "pernicious anemia." However, free hydrochloric acid was present on gastric analysis. Laboratory studies and small bowel roentgenograms confirmed the diagnosis of sprue.

Tetany was the primary complaint in 2 cases. On further questioning it developed that both patients had diarrhea. One of them was admitted to the hospital and a serum calcium of 6.8 mg. per 100 ml. was found. Under treatment the calcium increased, tetany disappeared, he gained weight and the diarrhea stopped. About six months later treatment was discontinued. The diarrhea returned, the patient lost weight, and shortly thereafter was readmitted to the hospital because of tetany. Once again he responded promptly to the treatment.

Two other patients were observed primarily because of a bleeding tendency. One patient, previously reported by Collins and Hoffmann,⁶ had hematuria and hemoptysis. The second patient had subcutaneous hemorrhages. Both responded quickly to the treatment of the underlying sprue.

Two other patients complained of edema caused by low serum proteins associated with sprue.

Another patient complained of pain in the back. Roentgenograms of the back revealed severe osteoporosis and collapse of three vertebrae. Seven years

previously he had had a gastro-enterostomy, subsequently developing a diarrhea that had never been troublesome. Gastrointestinal x-ray examination revealed a gastrocolic fistula. This is an example of "secondary" sprue. Three other such cases due to an inadvertent gastro-ileostomy have been reported by Brown, Colvert and Brush.⁷

Consequently it is evident that many sprue patients do not have the classical picture of sprue but complain of complications of this disorder. This may be because, with the lower incidence of the disease in this climate as compared to the tropics, we are less aware of its possible existence until a complication of the condition arises. Consequently, sprue should be considered in any patient with steatorrhea, loss of weight, unexplained edema, macrocytic anemia, tetany or osteoporosis.

The **laboratory examinations** in a patient suspected of having sprue are frequently helpful. On gastric analysis 40 per cent are shown to have achlorhydria, while others disclose hypochlorhydria. Gastroscoically 40 per cent show an atrophic gastritis. In children the blood picture is usually that of a hypochromia anemia, while in the fully developed adult case the blood picture is that of a hyperchromic, macrocytic anemia. There is more than 30 per cent fat in the stool, the fat being largely split (77 per cent). A rough estimation of the split fat in the stool can be obtained by staining with sudan 3. There is a flat oral glucose tolerance curve. In 65 cases of sprue at Duke reported by Hanes⁸ only 5 showed a rise of more than 40 mg. per 100 ml. after 1.5 Gm. of glucose per kilo body weight had been given orally. Serum cholesterol and serum proteins may remain low. Both serum calcium and serum phosphorus are low, differentiating the condition from hypoparathyroidism. Vitamin A tolerance curves are flat.

The laboratory observations in our cases are presented in Table 2.

Roentgen-ray examination of the bones of a patient with sprue may show osteoporosis in adults and rickets and deformities in children. The colon may be large and atonic. Frequently x-ray examination of the small bowel is practically diagnostic. With sprue there is obliteration of the herringbone markings due to the vulvulae conniventes, moulage formation or smoothing of the contours of the lumen, dilatation of the small bowel, clumping of barium, and hypomotility. Rarely will other conditions such as pylorospasm and pyloric lesions (Glass⁹) cause a similar bowel picture. Typical roentgenograms are presented in figures 1a and b.

The **diagnosis** of sprue is based on the history, physical, laboratory, and roentgen-ray examinations. A history of steatorrhea, diarrhea, loss of weight, gastro-intestinal symptoms of flatulence, epigastric fullness, and anorexia is suggestive. On physical examination there may be glossitis, stomatitis, pigmentation and emaciation. Laboratory examinations reveal a flat oral glucose tolerance curve, low serum calcium and phosphorus, a macrocytic anemia in adults, a hypochromic anemia in children, and a high split fat in the stool. Roentgenograms of the small bowel may show dilatation and hypomotility.

TABLE 2

Laboratory Observations in 30 Cases of Sprue

Observations	No. of Cases
Anemia	24
Macrocytic	18
Stool—increased fatty acid crystals	29
Serum calcium—below 9 mg./100 ml.	18
Not done	5
Serum phosphorus—below 3 mg./100 ml.	11
Not done	14
Ewald—normal	11
Hypochlorhydria	12
Hyperchlorhydria	2
Not done	5
Serum proteins—below 6 Gm./100 ml.	14
Not done	13
Oral glucose tolerance—flat	9
Normal	2
Not done	19
Prothrombin—low	3
Gastroscopic—normal	2
Atrophic gastritis	1

In the **differential diagnosis**, other causes of steatorrhea are differentiated from sprue by the presence of meat fibers or high unsplit fat and increased nitrogen in the stool, a normal oral glucose tolerance curve, normal serum calcium, and normal small bowel motility studies. Further investigation will often reveal pancreatic disease with a lack of pancreatic enzymes, a gastrocolic or gastroileal fistula as the cause of the steatorrhea.

Pernicious anemia can be differentiated from sprue by the flat glucose tolerance test, the frequent presence of hydrochloric acid on gastric analysis, increased split fat in the stool, and the small bowel changes that are associated with sprue rather than pernicious anemia.

Addison's disease may be differentiated by the pigmentation of the mucous membrane, non-existent in sprue, by the normal glucose tolerance curve and by the study of the stool.

Other causes of diarrhea must of course be distinguished from sprue, and this can be done by the laboratory observations of a macrocytic anemia, high split fat in the stool, and by the typical x-ray findings in patients with sprue.

In **treatment** the diet must be fluid at first, high in protein and carbohydrate. Frequent small feedings should be given. The diet should be increased until the patient is receiving 150 Gm. of protein and 300 Gm. of carbohydrate a day. The fat content of the diet should be kept low and increased as tolerated. Two cubic centimeters of liver extract parenterally should be prescribed every

day. Spies² has shown that it makes little difference whether refined or crude liver extract is given to these patients.

Folic acid has been proved to be specific at least for the anemia of sprue.² Frequently the diarrhea and other symptoms disappear when the patient is given folic acid as the only therapeutic measure,² although this is not recommended. Initially, the patient should get from 10 to 20 mg. of folic acid orally each day. As a maintenance dose, he should receive 2.5 to 5.0 mg. daily.

Two cubic centimeters of vitamin B complex given daily, parenterally, is helpful in treating these patients. Later, oral doses of vitamin B complex may be prescribed, either in the form of Brewer's yeast or in high potency capsules.

Because of the negative calcium balance, these patients should receive extra calcium. This may be given in the form of calcium lactate, 15 gr. three times a day.

Vitamins A and D should be prescribed because of the impaired absorption of fat substances, preferably one c.c. daily of viosterol or halibut oil. Vitamin K may be used if there is any decrease in the prothrombin time.

Mecholyl was used successfully in one patient in an effort to increase the tone of the small intestine and cause better absorption.

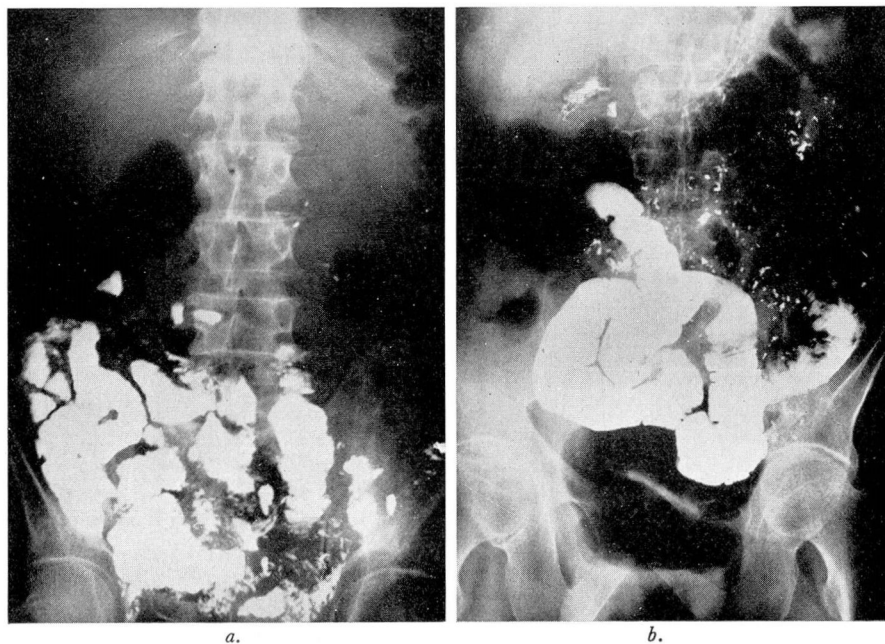


FIG. 1 (a) Small intestinal x-ray in patient with sprue showing dilatation, moulage, and segmentation. (b) Small intestinal x-ray in patient with sprue showing dilatation and moulage of the intestinal wall.

If, on the described program, the patient is still unable to gain because of impaired fat absorption, Tween 80 or polyoxyethylene sorbitan monooleate may be used in a dose of 1.5 Gm. before each meal. This drug is an emulsifying agent and breaks the fat into smaller globules probably by lowering the surface tension. Jones et al.³ have described its use in cases of sprue of both the primary and secondary types.

What are the **effects of treatment?** In the usual case of sprue the symptoms promptly disappear, the oral glucose tolerance and the blood count quickly become normal. There may be a fairly rapid gain of weight. Although clinically the patient may improve, the flat vitamin A tolerance curve persists. This indicates that the basic difficulty—fat absorption in the small intestine—is not corrected by treatment with folic acid or liver extract.

In our group of cases improvement was rapid in all but 4. One patient received testosterone to improve nitrogen metabolism, and responded promptly to this addition to his therapeutic program. Two others, originally diagnosed as sprue patients, were subsequently found to have tuberculosis which proved fatal. Their original conditions were undoubtedly *tabes mesenterica*. This shows the importance of obtaining a chest roentgenogram in every patient with sprue. The fourth patient was reported to have died of cancer, the site of the growth not having been disclosed.

Because of the fact that irreversible damage may occur, it is important that patients be treated intensively with all of the measures outlined.

References

1. Stefanini, M.: Hypoproteinemia and edema in course of tropical sprue. *Gastroenterology* 11:50-55 (July) 1948.
2. Suarez, R., Spies, T. D., and Suarez, R. M., Jr.: Use of folic acid in sprue. *Ann. Int. Med.* 30:643-677 (May) 1947.
3. Jones, C. M., Culver, P. J., Drummey, G. D., and Ryan, A. E.: Modification of fat absorption in digestive tract by use of an emulsifying agent. *Ann. Int. Med.* 29:1-10 (July) 1948.
4. Castle, W. B., Rhoads, C. P., Lawson, H. A., and Payne, G. C.: Etiology and treatment of sprue. *Ann. Int. Med.* 56:627-699 (Oct.) 1935.
5. Ashford, B. K.: Observations on the conception that sprue is a mycosis superimposed upon a state of deficiency in essential food elements. *Am. J. Trop. Med.* 2:139-150. (March) 1922.
6. Collins, E. N., and Hoffman, A. D.: Hemoptysis and hematuria in sprue; importance of vitamin K metabolism. *Cleveland Clin. Quart.* 10:105-111 (Oct.) 1943.
7. Brown, C. H., Colvert, J. R., and Brush, B. E.: Gastro-ileostomy, rare surgical error: symptoms and x-ray findings. *Gastroenterology.* 8:71-81 (Jan.) 1947.
8. Hanes, F. M.: Sprue. *Oxford Medicine* 5: (part 2) 631-652, 1942. (New York: Oxford University Press).
9. Glass, W. H.: Non-vitaminic factors involved in production of "small intestinal deficiency pattern." *Gastroenterology.* 10:660-666 (Apr.) 1948.