

AMOEBIIC HEPATIC ABSCESS WITH BRONCHOHEPATIC FISTULA

Report of a Case

ARTHUR G. MICHELS, M.D., H. S. VAN ORDSTRAND, M.D., and
E. N. COLLINS, M.D.

Departments of Cardiorespiratory Disease and Gastroenterology

PLEURALPNEUMONIC involvement comprises the most frequent complication of amoebic hepatic abscess. The majority of the cases result from rupture or direct extension of the liver abscess through the diaphragm into the pleural cavity. The diagnosis of hepatic amebiasis and possible concomitant pulmonary complications depends primarily upon the awareness of the great possibility of liver involvement following amoebic colon infections. The following case report is an example in which, because of the high index of suspicion, the diagnosis of amebiasis was initially made. In this patient bronchohepatic fistula developed from an amoebic liver abscess and the patient dramatically recovered on a regimen of antiamoebic treatment and closed drainage.

Case Report

A 54-year-old man of Italian descent when first examined at the Cleveland Clinic was complaining of right chest pain and fever of two months' duration. For the previous thirty years, the patient had noticed occasional loose stools but had had no other symptoms until the onset of his acute illness. Two months before examination, he had noticed constant dull right-sided lateral neck and shoulder pain accompanied by fever; this pain was aggravated by inspiration, coughing, or straining at stool. He had felt fatigued and warm, perspired a great deal. He had lost 24 pounds since the onset of his acute illness and was profoundly weak. A few days after the initial chest pain, he began to have daily diarrhea with two to four watery stools which did not contain bright blood or mucus. For the four weeks previous to the initial examination, anorexia was severe and the patient suffered from recurrent insomnia, eructation, epigastric fullness, and slight dyspnea. At the time of hospital admission, he was having paroxysms of coughing with the expectoration of blood-stained sputum. A determination of the time of onset of this hemoptysis could not be accurately established.

The patient appeared acutely ill. The temperature was 101.2 F., the pulse 100, and the respirations were 38 per minute. The blood pressure was 120 systolic, 70 diastolic. There was diminished respiratory excursion of the right chest with decreased resonance, tactile and vocal fremitus at the right lung base. Breath sounds in this area were diminished and there were frequent paroxysms of coughing with production of chocolate colored and blood-tinged sputum. The heart was essentially normal. The liver edge was barely palpable under the right costal border and was moderately tender. The left inguinal canal was dilated and filled with a large reducible hernia sac. Rectal and neurologic examinations disclosed no abnormalities.

The initial blood count was 4,100,000 red cells, hemoglobin of 10.5 Gm., and 16,450 white cells of which 90 per cent were neutrophils. The blood Wassermann and Kahn tests were negative and the urinalysis was normal. Total protein was 6.6 Gm. per 100 cc. with a reversal of the normal albumin globulin ratio: 2.8 Gm. albumin to 3.8 Gm. of globulin. Thymol turbidity was 1.6 units and cephalin flocculation test was equivocal. Bromsulfalein

test showed 24 per cent retention in thirty minutes. Icteric index was 4.0. Examination of the chocolate colored sputum was negative for tubercle bacilli, spirochetes, fungi, and amoebae. Sputum culture revealed non-hemolytic streptococci and *N. catarrhalis*. On five successive warm stool examinations occult blood test was positive several times but no amoeba were ever found.

The proctosigmoidoscopic examination revealed multiple discreet, punched out ulcers 3 to 5 mm. in diameter in the rectosigmoid colon at a distance of 10 to 15 cm. from the anal sphincter. Smears from the bases of the ulcer beds showed many amoebae which were suggestive in appearance of *Endamoeba histolytica* and in the warmed preparation, the motile vegetative forms of *Endamoeba histolytica* were positively identified.

Initial roentgen studies of the chest (fig. 1) demonstrated a large, smoothly outlined triangular mass in the right lower lung field. Films two days later showed a pleural effusion obscuring the lower two-thirds of the right lung (fig. 2). Stereoscopic films of the liver demonstrated immobilization of the right diaphragm. A diffuse inflammatory process of the entire colon with the most pronounced changes in the cecum and ascending colon was shown by barium enema (fig. 3).

On the second day in the hospital, a bronchoscopy was done. A considerable amount of thick brown mucus was found to be coming from the right middle and lower lobe bronchi with no evidence of bronchial obstruction or neoplasm. The two smears made from bronchial secretions were negative for tumor cells. On the following day, a thoracentesis was done in the sixth anterior interspace in the anterior axillary line with a total of 1800 cc. of chocolate colored or anchovy sauce fluid aspirated. Laboratory examination of this fluid was negative for tubercle bacilli, fungi, spirochetes, and amoeba. The specific gravity was 1.027 and the white cell count 62,000; all cells found were neutrophils.

Upon hospital admission, the patient was placed on intramuscular penicillin, 50,000 units every three hours until the diagnosis was established of intestinal amebiasis with hepatic abscess and pleural-pulmonary involvement. Following one day's treatment with penicillin, the patient's temperature fell to 100 F., and a few hours after specific antiamoebic treatment was begun, the patient became afebrile and remained so during the remainder of his hospital stay. The antiamoebic therapy used was as follows: The intramuscular injection of emetine

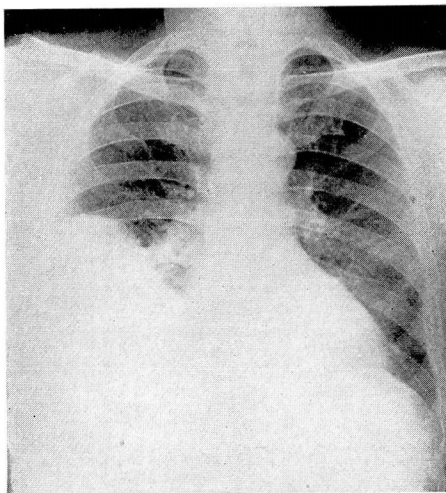


FIG. 1. Initial chest film showing large smoothly outlined triangular mass in right lower lung field.

hydrochloride 0.065 Gm. (1 grain), daily for six days and at the same time, one 0.25 Gm. carbarsonc capsule given orally twice daily until twenty capsules had been used, followed by oral administration of diodoquin tablets 0.21 Gm., three tablets being given three times daily until a total of one hundred tablets were used.

The patient's response to antiamebic therapy was immediate and his general condition improved with the gradual return of appetite, disappearance of chest pain and productive cough, cessation of diarrhea, and gradual clearing of the right chest as judged by chest films and physical findings. An additional 800 cc. of chocolate milk fluid was removed on the eighth hospital day by thoracentesis. During the first four days following hospital admission, the recurrent cough gradually became less productive of brown colored sputum indicating the closure of the bronchohepatic fistula. By the seventh hospital day, the patient's occasional dry cough was non-productive. Electrocardiogram remained normal after completion of the six-day course of emetine hydrochloride and there was no clinical evidence of peripheral neuritis. White cell count was 11,000 at this time. A week after initiation of specific treatment, there were fewer rectosigmoid ulcers found on proctosigmoidoscopic examination

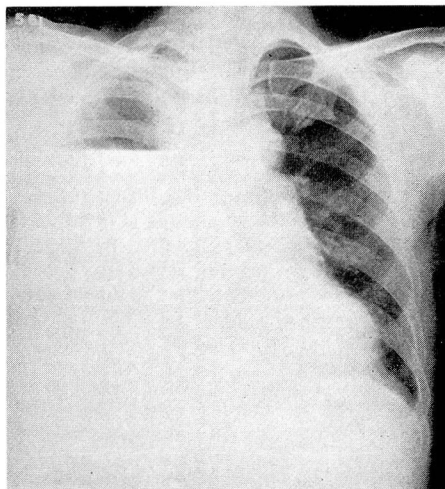


FIG. 2. Chest film taken two days after initial examination demonstrating a pleural effusion obscuring the lower two-thirds of right lung.

and these lesions showed evidence of healing. At the time of hospital discharge on the eighteenth hospital day, the liver was not palpable and there was no tenderness over the right upper quadrant.

Examination three months later showed the patient had gained 27 pounds and was symptom free. Roentgen studies disclosed no active pleural disease or free fluid. Residual right base pleural scarring was moderate.

Discussion

Amoebic hepatic abscesses comprise the large percentage of liver abscesses. In 287 patients with liver abscess, Oschner¹ found 63 per cent were amoebic in origin, and the remaining 37 per cent non-amoebic. Payne² reported liver abscesses in almost 3 per cent of 1000 cases of intestinal amebiasis. The diagnosis is not always easy to make as neither symptomatology or liver function

studies are pathognomonic but are merely suggestive of amoebic liver disease. Excessive indulgence in alcohol is believed to be the most important predisposing influence in favoring the development of amoebic hepatitis and liver abscess.

Amoebic hepatitis is the result of invasion of the liver by the amoebae through one of three possible routes: 1. by direct extension through the bowel wall, peritoneal cavity, and the capsule of the liver; 2. by lymphatic route, and 3. through the portal vein. The amoebic liver abscess contents have a characteristic appearance in non-infected cases. In the early stages, the abscess material is viscid, glary and semi-transparent; later, the contents become less viscid and with the mixture of blood, assume a yellow-red or chocolate brown color. This material has been given many terms and commonly is described

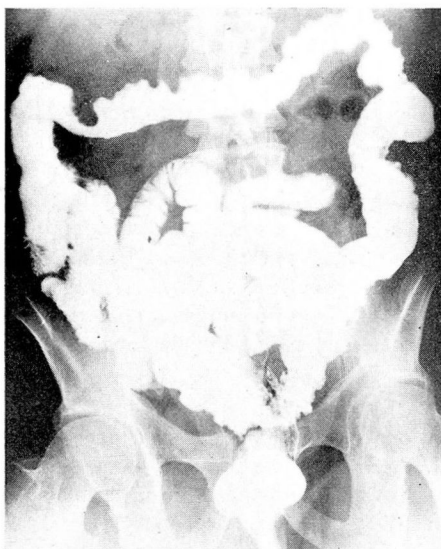


FIG. 3. Barium enema demonstrating the diffuse inflammatory process of entire colon.

as anchovy sauce or chocolate milk material. The formation of a well defined wall of connective tissue demarcates the abscess cavity and amoebae can be found throughout the peripheral abscess wall and frequently can be observed invading the surrounding liver parenchyma. Calcification of amoebic hepatic abscess is rare.

The amoebic hepatic abscesses are characteristically single and occur in the right lobe near the dome of the liver or near the inferior surface next to the hepatic flexure of the colon. The predominance of right liver involvement is closely related to the high incidence of amebiasis in the cecum and ascending colon. Venous drainage of the right colon is chiefly into the right lobe of the liver and is cited as cause for the great frequency of right-sided liver abscesses reported variously as 55 to 97 per cent. Multiple abscesses are present in less than 50 per cent.

Pleuralpulmonary complications of amoebic liver abscess occur in approximately 15 per cent. In a study of 2490 cases of amoebic hepatic abscess, Ochsner³ found pleural complications occurring in 7.5 per cent and the pulmonary complications such as empyema and broncho-pleural fistula in 8.3 per cent for a combined incidence of pleuralpulmonary complications of 15.8 per cent.

Pleuropulmonary amebiasis occasionally is due to systemic invasion but is usually a direct extension of amoebic abscess such as in the case reported here. It is extremely doubtful whether primary infection of the lung occurs without antecedent bowel infection. Transphrenic immigration of amoebae to the lung via lymphatics has been mentioned as a possibility but is rare. A rupture of a liver abscess into the lung parenchyma may produce a bronchial fistula (30 per cent) such as occurred in this reported case, or pulmonary abscess (34 per cent) may follow.

In pleuropneumonic amebiasis, the clinical manifestations vary with extent and mode of infection. Pain is the most common single complaint, usually sharp, stabbing in the right lower chest or liver region frequently radiating to the shoulder; dyspnea may be present when the abscess is large; cough usually is unproductive but when large quantities of purulent material and chocolate sauce material appears in the sputum this is pathognomonic of hepatobronchial fistula. Other rather common manifestations are fever, anorexia, malaise, weakness, and weight loss. Jaundice is rare. Chest findings are characteristic of pleural effusion and roentgenographic examination may disclose a triangular shadow in both anterior-posterior lateral roentgenograms with its base toward the liver and apex extending toward the hilum of the lung (fig. 1).

The treatment of amoebic hepatic abscess and consequently its pleuropneumonic complications is entirely surgical whether conservative or radical therapy is employed. Early recognition of hepatitis and prevention of abscess formation or progression to pleuropneumonic involvement will result in a greatly reduced mortality. Emetine hydrochloride is specific for amoebic hepatic disease and usually is administered intramuscularly daily in 1 gr. (0.065 Gm.) doses for a total of 6 to 10 gr. Following the completion or during the course of emetine, the intestinal amebiasis should be treated with a suitable amebicidal drug such as carbarsone, diodoquin, etc., as outlined by Collins.⁴ Failure to treat the intestinal infection adequately probably accounts for many recurrent abscesses.

Closed drainage by aspiration is the procedure of choice when evacuation of a liver abscess becomes necessary. Aspiration must always be preceded by preliminary administration of emetine hydrochloride for two to four days. Every attempt must be made to maintain sterility as secondary infection of the abscess results in a much higher mortality. Open drainage employed in 80 cases incurred a 22.1 per cent mortality in contrast to 3.6 per cent mortality in 83 cases treated by closed drainage in Ochsner's series.¹ Bockus,⁵ however, does not favor aspirating liver abscesses for diagnosis because of the danger of soiling the peritoneum, pleura, or lung.

A suspected amoebic hepatic abscess should not be subjected to exploratory aspiration without cognizance of the possible dangers of 1. hemorrhage, and 2. extension of the infection. Pre-aspiration emetine therapy largely avoids these complications and the aspiration procedure should be carried out preferably in an operating room to assure absolute aseptic technic.

If open drainage becomes unavoidable when the amoebic abscess is secondarily infected, then two general types of surgical approaches are used: 1. trans-thoracic, and 2. transabdominal with either procedure completely avoiding contamination of the two virgin surfaces, pleural and peritoneal, by means of extraserous approach. The most popular method is that of Beck's two stage procedure.⁶ The first stage consists of suturing the costophrenic pleural reflection and packing the wound with an irritative substance to stimulate the formation of adhesions. The second stage consists of later incising through to the abscess so the drainage is confined in the previously formed fistula.

Other complications of amoebic hepatic abscess are rupture into the peritoneal cavity (6 per cent), pericardial cavity perforation (2 per cent), and an even rarer complication of cerebral abscess which is almost invariably fatal.

The prognosis in pleuropulmonic amoebic involvement is poorest in the cases in which the hepatic abscess ruptures into the pleural cavity without subsequent adequate drainage, and best in those in which a bronchohepatic fistula develops with minimal pulmonary reaction. Incomplete evacuation of the liver abscess through the bronchus may result in empyema, a complication with 77.7 per cent mortality in the collected cases of Ochsner.¹ Liver abscess with extension into the lung incurs a 43 per cent mortality whereas in bronchohepatic fistula where drainage is usually adequate, the mortality of 10 per cent is much more favorable.

Summary

The most frequent complication of amoebic hepatic abscess is pleuropneumonic involvement. The diagnosis of this complication depends primarily on a high index of suspicion in patients with unexplained symptoms referable to the right side of the chest and diaphragm. A case of amoebic hepatic abscess with bronchohepatic fistula has been described in which there was rapid improvement with antiamoebic therapy and closed drainage.

References

1. Ochsner, A., and DeBakey, M.: Amoebic hepatitis and hepatic abscess; analysis of 181 cases with review of literature. *Surgery* 13:460 (March) and 612 (April), 1943.
2. Payne, A. M.: Amoebic dysentery in Eastern India. *Lancet* 1:206-209 (Feb. 17) 1945.
3. Ochsner, A., and DeBakey, M.: Pleuropulmonary complications of amebiasis; analysis of 153 collected and 15 personal cases. *J. Thorac. Surg.* 5:225-258 (Feb.) 1936.
4. Collins, E. N., and Bynum, F. L.: Amebiasis and indeterminate ulcerative colitis; combined therapy as applied to veterans from overseas. *M. Clin. North America* p. 408-418 (March) 1948.
5. Bockus, H. L. et al: *Gastro-enterology*, vol. 2 (Philadelphia: W. B. Saunders Company, 1944) p. 630-634.
6. Beck, C.: On diagnosis and treatment of abscess of lung. *New York M. J. and M. Rec.* 66:287, 1897.