

TRANSLUMBAR AORTOGRAPHY

EUGENE F. POUTASSE, M.D. and WILLIAM J. ENGEL, M.D.

Department of Urology

and

JOSEPH C. ROOT, M.D.

Department of Roentgenology

SATISFACTORY visualization of arterial circulation by roentgen examination is a comparatively recent accomplishment. This is true of translumbar aortography, although it was described by Dos Santos before the Surgical Society of Paris in 1929.¹ This diagnostic procedure did not meet with immediate acceptance, however, and almost a quarter of a century elapsed before it became recognized as a valuable diagnostic aid. Improvements in contrast media and technic have contributed to making arteriography a safe and simple examination.^{2,3}

The original application of aortography was chiefly in the field of urology to differentiate between various types of renal lesions.⁴⁻⁸ Useful information concerning potential renal function can be obtained from a roentgenographic study of renal blood supply.

In recent years, aortography has been found to be of equal or even greater value in the diagnosis of vascular pathology involving the abdominal aorta and its immediate branches.^{9,10} Suspected conditions such as aneurysm and complete or partial occlusion may now be confirmed or excluded by this means.

The technic of translumbar aortography has been adequately described in the literature. We have used the simple technic of syringe injection employed by Smith et al.³ The choice of the opaque media, whether it be sodium iodide, neo-iopax or diodrast is largely the preference of the physician making the injection. We have found no appreciable difference in results between 75 per cent neo-iopax and 70 per cent diodrast. Sodium iodide, 80 per cent, will give a contrast shadow somewhat more dense than the other media and may be preferable with a large patient; however, it is more irritating. One point in the technic should be stressed, the importance of making a preliminary film after insertion of the needle and the injection of 10 cc. of 35 per cent diodrast, particularly when there is doubt whether the needle is in the aorta. This insures the proper positioning of the needle and will prevent injection of the concentrated solution into one of the smaller vessels. The preliminary film is immediately processed and viewed and, if the needle tip is in satisfactory position within the lumen of the aorta, the injection of the concentrated solution follows without delay. We believe that thrombosis of one of the smaller arteries may be prevented by means of this preliminary injection. Aortography may be accomplished with or without anesthesia; only morphine premedication and novocain may be necessary in many instances.

Translumbar aortography has been performed approximately one hundred times at the Cleveland Clinic in the past 2 years without serious complication. A few instances of extramural or intramural injection of the aorta have occurred. The dye is absorbed within a few minutes and the only consequence has been mild back pain for one day. The superior mesenteric and splenic artery have been injected accidentally without incident.

The needle is usually inserted into the aorta at the level of the interspace between D 12 and L 1 vertebra. This insures filling of the aorta and all its major branches (fig. 1). For special purposes the needle can be inserted at a lower level to avoid dispersion of the dye into the celiac axis. The renal arteries come off at right angles to the aorta usually at the level of the second lumbar vertebra, the left being slightly higher than the right. Before reaching the hilum of the kidney, the renal artery divides into lesser branches which spread out in a fan-like arrangement, extending almost to the periphery of the renal outline.

Anomalous renal arteries may arise separately from the aorta or the proximal portion of the renal artery (figs. 2 and 3). These vessels must be studied carefully to determine that their branches end within the renal shadow. They may cross the ureter in such a way that hydronephrosis is produced. Aortography provides a means of visualizing these aberrant arteries and demonstrates how much of the kidney is supplied by them.

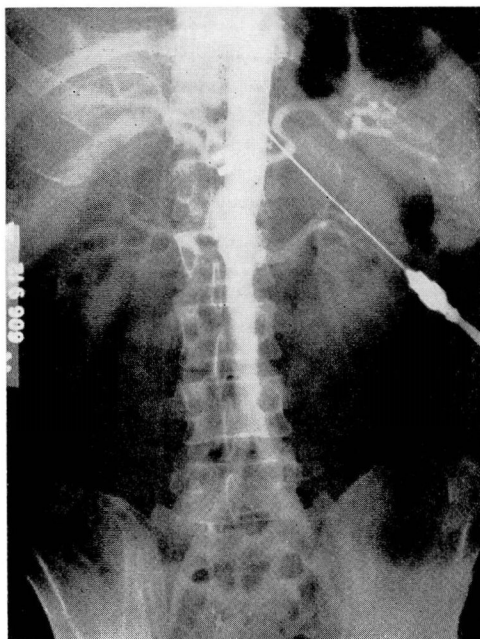


FIG. 1. Normal aortogram. The celiac axis is the first major branch of the abdominal aorta, dividing into the splenic artery, the left gastric and the hepatic artery. The renal arteries arise from the aorta at the level of the second lumbar vertebra.

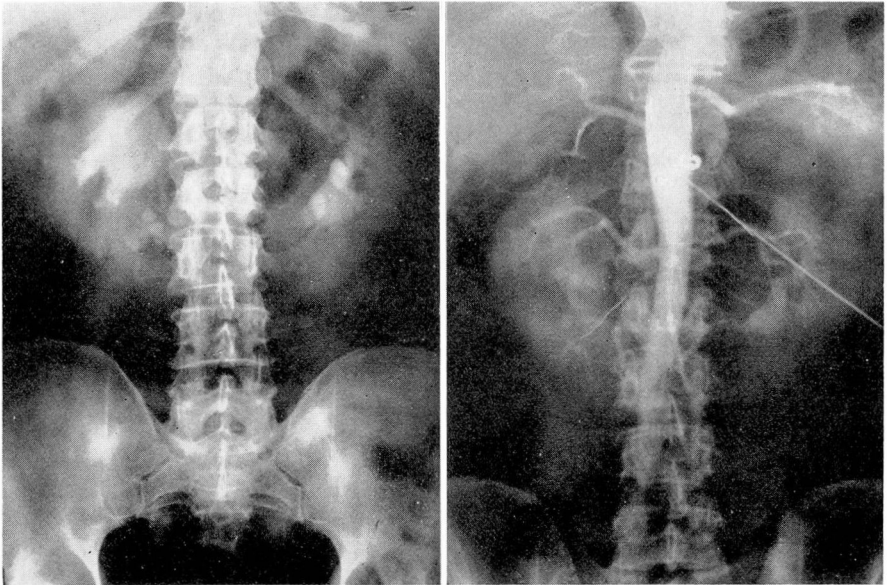


FIG. 2. (a) Intravenous urogram demonstrating a horseshoe kidney with hydronephrosis of right half and multiple calculi in the lower calyces. (b) Two large renal arteries supply the right half of the horseshoe kidney; two large and two smaller arteries supply the left half.

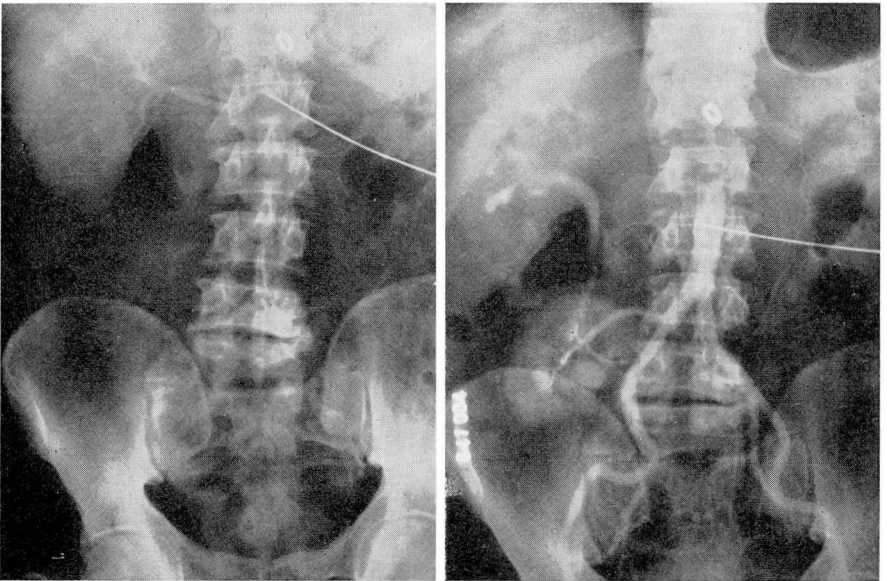


FIG. 3. Crossed renal ectopia. (a) The right kidney lies in its normal position and is supplied by two renal arteries. There is no evidence of a left kidney in its normal location. (b) The second kidney lies on right side of abdomen, deriving its blood supply from right common iliac artery. The opaque medium from first injection is being excreted by both kidneys.

Important information of practical surgical value to the urologist concerning congenital anomalies of the kidneys is supplied by aortography. Horseshoe kidneys have an exceedingly variable blood supply; instances of a solitary renal artery supplying both halves have been observed. The arterial supply of a horseshoe kidney in which two or more renal arteries supplied each half is shown in figure 2. Ectopic kidneys may derive their blood supply from the aorta or the iliac vessels. Figure 3 demonstrates an unusual vascular pattern found when both kidneys are on one side. The first aortogram (fig. 3a) depicts a normal right kidney in its normal position but supplied by two renal arteries. After reinsertion of the needle in the midlumbar aorta, the aortogram was repeated (fig. 3b). The second kidney was found to lie on the right side of the pelvis, supplied by a single renal artery arising from the right common iliac artery. The ureter from the upper kidney can be seen crossing the lower kidney. This condition is known as crossed renal ectopia.

Cysts and malignant tumors of the kidney usually are difficult or impossible to differentiate on pyelographic findings alone. They both cause enlargement and irregularity of the renal outline, and although there often are changes on the pyelogram suggestive of either a cyst or tumor, they may produce an identical deformity of the pelvocalyceal system. Occasionally a cyst or tumor can be present in a kidney without deformity of the renal pelvis or calyces. Under these circumstances, pyelography is of little value. Without exploration or direct needle puncture of the lesion, the two often cannot be distinguished. Aortography has proved useful under such conditions.

A kidney with a cyst has an avascular area corresponding to the pyelographic deformity and enlarged renal outline. There is displacement of the renal parenchyma and intrarenal vessels around the periphery of the cyst. These points are illustrated in figure 4. The pyelogram showed a large, soft tissue mass at the lower pole of the right kidney, with a deformity of the pelvocalyceal system characteristic of either a cyst or tumor. The aortogram (fig. 4a) indicated the area to be avascular, establishing the diagnosis of renal cyst. Attempted aspiration proved unsuccessful because the cyst was multilocular (fig. 4b).

A renal tumor shows increased vascularity with an abnormal reticulated pattern of arterial supply in the region of the pelvocalyceal deformity, known as "pooling" of the opaque media. Some vessels adjacent to the mass may be displaced around it. A small tumor may alter only a portion of the renal blood supply, whereas a large tumor has multiple abnormal vessels and rich vascularity. In figure 5 are shown the roentgenograms of a renal tumor where aortography established the diagnosis preoperatively. The urogram showed a soft tissue mass arising from the upper pole of the left kidney without calyceal deformity. Differentiation between cyst or tumor could not be made. In the aortogram (fig. 5a) a large artery can be seen extending to the center of the mass from which many smaller vessels radiate, indicating that the mass is a tumor (fig. 5b).

A benign adenoma of the renal parenchyma does not show this increased

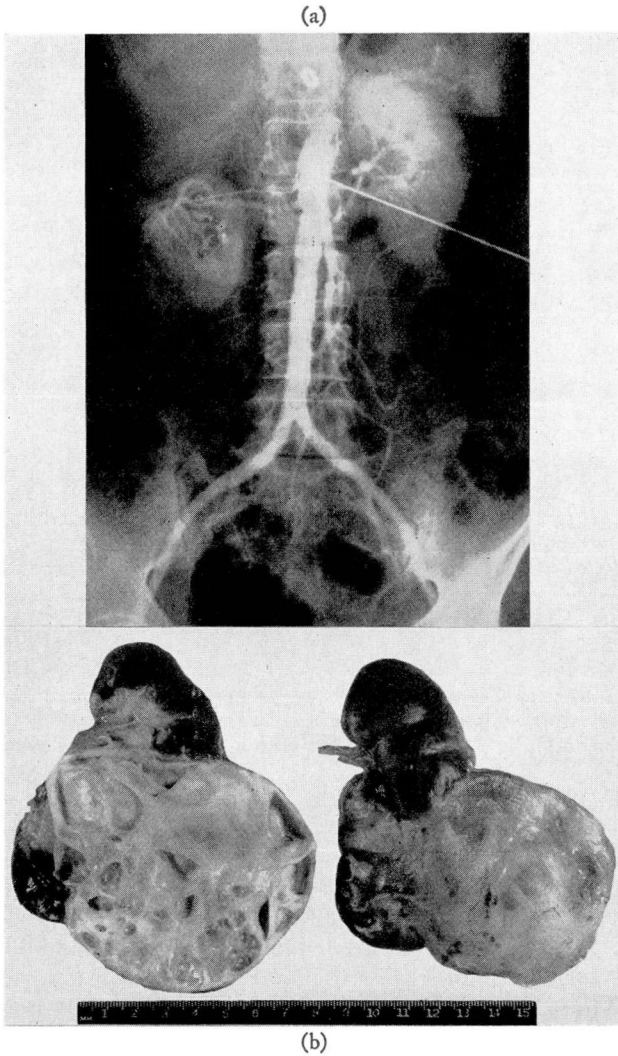


FIG. 4. Renal cyst. (a) Note the abnormal outline of the right kidney with absence of vascularity of the soft tissue mass arising from its midportion. (b) Large multiloculated cyst arising from the midportion of the kidney.

vascularity. Neither do papillary or squamous cell carcinomas of the renal pelvis reveal any characteristic disturbances of the vascular pattern.

Chronic pyelonephritis may cause considerable morphologic change in the kidney. The excretory urogram will show decrease in renal function as well as calyctasis and reduction in renal size. Figure 6 illustrates the renal vascular changes in a patient who had a long history of infection of the left kidney. This

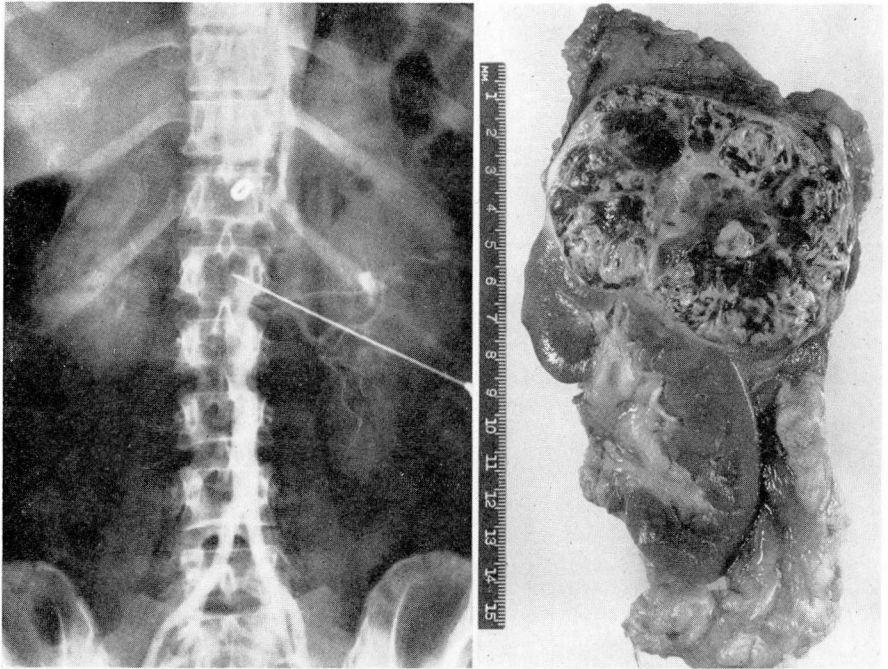


FIG. 5. Renal tumor. (a) The aortogram shows the left kidney displaced downwards by a mass arising from its upper pole. The presence of large vessels and "pooling" of the opaque medium established the diagnosis of renal tumor. (b) Renal cell carcinoma.

kidney was smaller than the opposite one and showed calyctasis on retrograde pyelography. The right renal artery measured 6 mm. in diameter, the left only 3 mm. There was a corresponding reduction in the vascular supply of the entire kidney suggestive of an old inflammatory process. The kidney was removed and showed chronic pyelonephritis.

Ordinarily when a poorly or nonfunctioning kidney is found on urography, a retrograde pyelogram establishes the etiology of the disturbance. When the ureter cannot be catheterized, or the dye fails to get past the ureteropelvic junction, aortography becomes especially useful. A careful study of the vascular pattern within the renal outline furnishes important information concerning the diagnosis and the amount of potentially good renal parenchyma present. Hydronephrosis causes the subdivisions of the renal artery to lengthen and become narrow with decrease in the vascularity of the renal parenchyma. A kidney which is a mere shell due to massive hydronephrosis will show only a few small caliber vessels stretched over the entire mass.

The diagnosis of congenital hypoplasia of one kidney may be difficult to establish by conventional means, particularly when the kidney in question fails to excrete sufficient dye to outline the pelvocalyceal system and the ureter is inaccessible to catheterization. In congenital hypoplasia the aortogram will show only a small renal artery and relative avascularity of the kidney.

Chronic renal infection with or without obstruction, will produce pyelographic changes resembling those of congenital hypoplasia. Such atrophy of the kidney can be further assessed by aortography. In the instance shown in figure 7, atrophy followed an old surgical injury of the left ureter. The kidney had virtually no function on urography and the left ureter could not be catheterized. Only a small renal artery is visible in the left renal area (fig. 7a), the kidney apparently undergoing atrophy from infection and obstruction (fig. 7b).

Retroperitoneal tumors are usually diagnosed by the finding of a ballotable mass on physical examination which causes displacement of the abdominal organs and the kidney or ureter. When complete gastrointestinal and urinary tract investigations fail to disclose the origin of a palpable abdominal mass, aortography becomes exceedingly useful. Careful study of the vascular supply of such tumors will reveal their etiology and aid in surgical intervention.

A large right adrenal carcinoma which caused downward displacement of the right kidney is shown in figure 8. The origin of the adrenal artery and the tumor's rich vascularity is well demonstrated. Aortography has not proved helpful in our experience in attempting to locate small adrenal tumors or to demonstrate adrenal hyperplasia.

The aortogram of a patient who had a left upper quadrant mass is shown in figure 9a. Complete gastrointestinal roentgenograms failed to disclose the

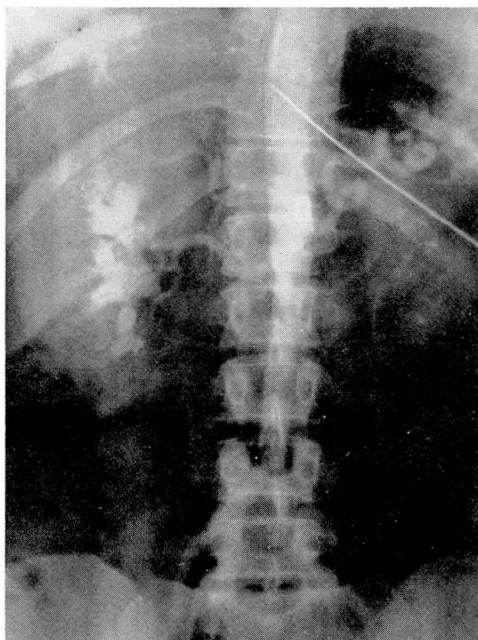


FIG. 6. Combined excretory urogram and aortogram in patient with chronic pyelonephritis of left kidney. Note the difference in size of the two kidneys, the small caliber of the left renal artery and the decreased function of the left kidney.

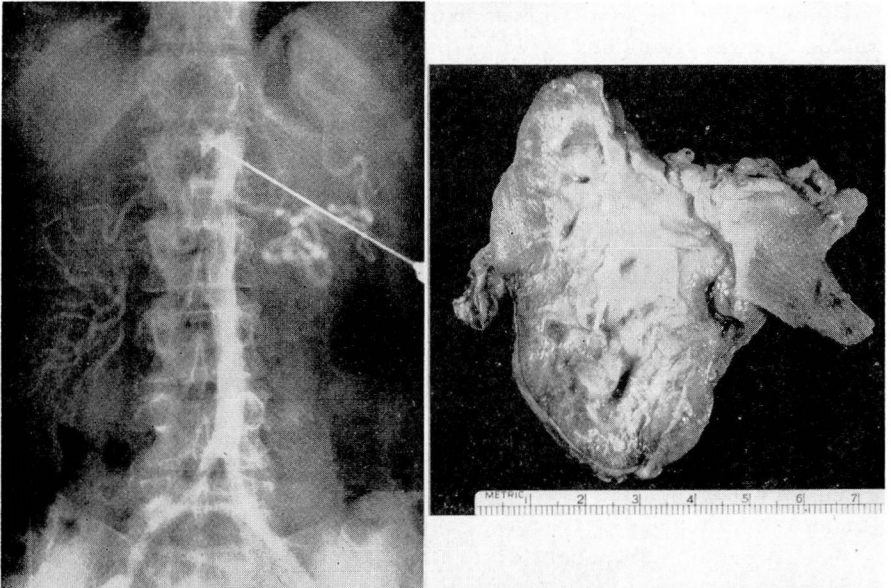


FIG. 7. Atrophy of the left kidney. (a) Note the large right kidney with normal vascularity. Small left renal artery lies below the coiled splenic artery. (b) Small, scarred left kidney.

origin of the mass and it was considered to be spleen, enlarged kidney or a retroperitoneal tumor. Visualization by urography of the left kidney was unsatisfactory and the ureter could not be catheterized for a retrograde pyelogram. An unusually large splenic artery whose branches extended over the entire mass is demonstrated; the kidney is depressed but its blood supply is normal. Hodgkin's sarcoma of the spleen was found at operation, the spleen weighing 1570 Gm. (fig. 9b).

Aortography has shown that occlusive disease of the aorta is more common than previously suspected.^{9,10} The aorta may be constricted with only a narrow passageway for blood flow or blocked completely (fig. 10a). The constriction is caused by encroachment of atherosclerotic plaques on the lumen of the aorta. When the plaques ulcerate thrombosis may occur, giving rise to complete thrombotic occlusion of the aorta. The level of occlusion may be anywhere in the lumbar aorta below the renal and superior mesenteric arteries. We have not had an opportunity to observe constriction or occlusion of the aorta above this level except in one boy with severe hypertension due to coarctation of the abdominal aorta commencing just below the origin of the celiac axis.

Patients who have claudication of the low back, hip, and upper leg with an absent or weak femoral pulse in the affected extremity, may be shown to have constriction or occlusion of the corresponding common iliac artery by aortography (fig. 10b). The level of occlusion may be at or close to the bifurcation

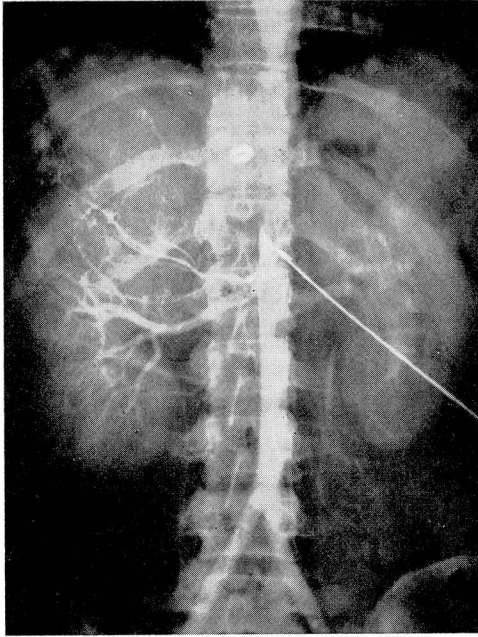


FIG. 8. Carcinoma of right adrenal gland. The right adrenal artery is enlarged, supplying a large mass which displaces the right kidney. Pulmonary metastases are present.

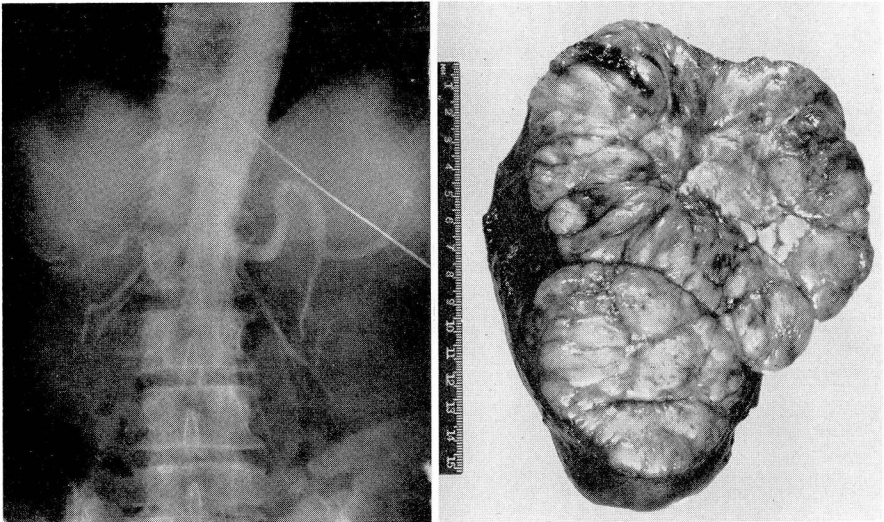


FIG. 9. (a) The left kidney is displaced down to the iliac crest by an enlarged spleen. (b) Hodgkin's sarcoma of the spleen.

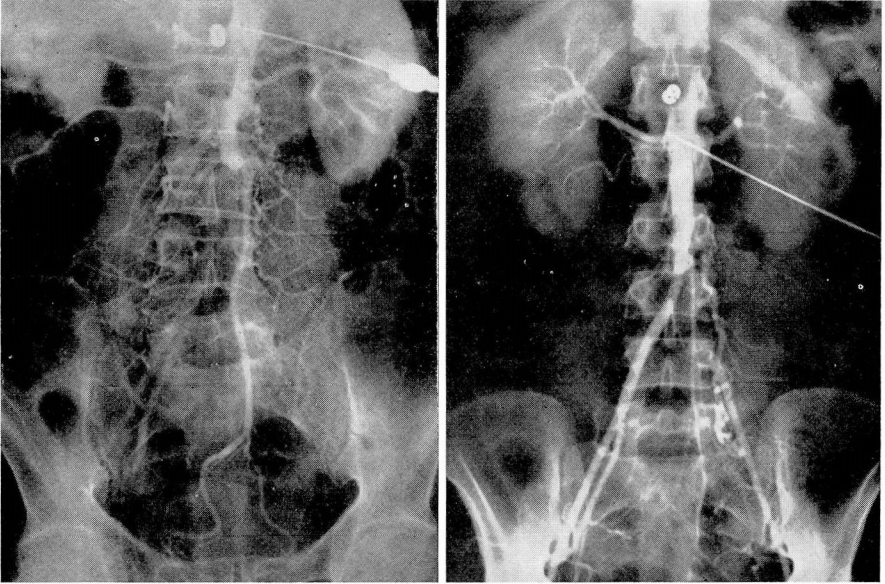


FIG. 10. (a) Occlusion of the abdominal aorta just below the superior mesenteric artery. Anastomotic vessels entering the common iliacs are shown. (b) Occlusion of left common iliac artery. Anastomotic vessels between the aorta and the distal iliac artery are shown.

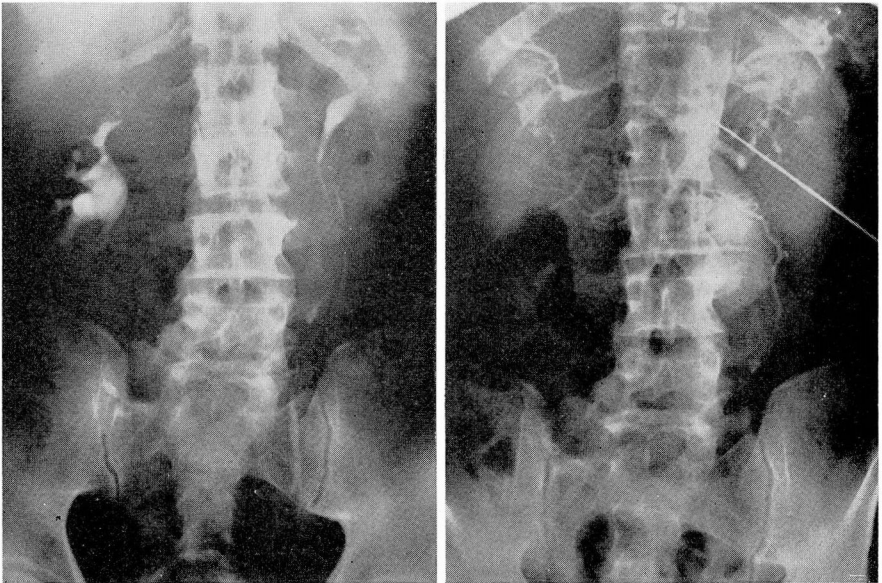


FIG. 11. (a) The left ureter is displaced around a mass. (b) Aortogram demonstrating aneurysmal dilatation of the abdominal aorta.

of the aorta. Anastomotic arteries from the aorta filling the distal portion of the internal and external iliac arteries often are demonstrated.

Aneurysms of the lower thoracic or abdominal aorta, as well as the iliac or femoral arteries, can be visualized by injecting the aorta above the lesion (figs. 11a and b). Direct puncture of the aneurysmal sac has been performed although this is better avoided. The presence as well as exact location of an arterial embolism can be demonstrated by aortography.

Many important and unusual diseases of the aorta and its major branches were seen formerly only at autopsy. Their practical demonstration in patients with vascular disease can now be accomplished by several methods,^{2,10,11} each with its own advantages. In our experience, translumbar aortography has proved a reliable and simple means of visualizing the aorta and its major branches.

Summary

Translumbar aortography is a safe, practical and valuable diagnostic aid to the urologist, supplementing intravenous urography and retrograde pyelography in evaluating renal disease. Under certain circumstances which have been described, the demonstration of the blood supply of various organs may be the only way of establishing the diagnosis. Various diseases of the aorta and its major branches can be accurately visualized by translumbar aortography. It is possible that wider applications of this useful procedure will be developed.

References

1. Dos Santos, R., Lamas, A. C. and Caldas, J.: Arteriographie des membres et de l'aorte abdominale. Paris, Masson et Cie, 1931.
2. Farinas, P. L.: New technic for arteriographic examination of abdominal aorta and its branches. *Am. J. Roentgenol.* **46**:641 (Nov.) 1941.
3. Smith, P. G., Rush, T. W. and Evans, A. T.: Technique of translumbar arteriography. *J.A.M.A.* **148**:255 (Jan. 26) 1952.
4. Nelson, O. A.: Arteriography in renal and abdominal conditions. *J. Urol.* **53**:521 (April) 1945.
5. Doss, A. K.: Translumbar aortography; its diagnostic value in urology. *J. Urol.* **55**:594 (June) 1946.
6. Melick, W. F., and Vitt, A. E.: Present status of aortography. *J. Urol.* **60**:321 (Aug.) 1948.
7. Smith, P. G., Rush, T. W. and Evans, A. T.: Interpretation of translumbar arteriograms. *J. Urol.* **66**:145 (July) 1951.
8. Hamm, F. C. and Harlin, H. C.: Translumbar arteriography in urology. *Brooklyn Hosp. J.* **10**:3, 1952.
9. Elliot, R. V. and Peck, M. E.: Thrombotic occlusion of aorta as demonstrated by translumbar aortograms. *J.A.M.A.* **148**:426 (Feb. 9) 1952.
10. Leriche, R., Beaconsfield, B. and Boely, C.: Aortography, its interpretation and value; report of 200 cases. *Surg., Gynec. and Obst.* **94**:83 (Jan.) 1952.
11. Peirce, E. C.: Percutaneous arterial catheterization in dogs with special reference to aortography. *Ann. Surg.* **135**:544 (April) 1951.