

# MUCOEPIDERMOID CARCINOMA OF SALIVARY GLAND ORIGIN

GEORGE F. STEVENSON, M.D.\* and JOHN B. HAZARD, M.D.

Department of Pathology

**M**UCOEPIDERMOID CARCINOMA, a distinctive neoplasm of salivary gland origin, had received comparatively little consideration in the medical literature until recent years. It is the purpose of this report to review the features of this neoplasm as previously described and to present 12 additional cases.

The first authentic instance of mucoepidermoid carcinoma was reported by Schilling<sup>1</sup> in 1921; the tumor arose in the parotid gland. However, there is some possibility that cases mentioned earlier by Volkmann<sup>2</sup> and Lecene<sup>3</sup> are examples of this tumor. In 1940, in addition to presenting eight cases of mucoepidermoid carcinoma, Skorpil<sup>4</sup> reviewed the literature and found seven previously reported instances of the neoplasm. In this country, it was not until 1945 that Stewart, Foote and Becker<sup>5</sup> first described this tumor and recognized it as an entity. In their report they analyzed the data derived from a study of 45 cases of this salivary gland neoplasm, for which they suggested the name mucoepidermoid tumor. In 1948 Lindell<sup>6</sup> described 12 additional examples and presented a detailed analysis of the reported cases. In 1949 Godwin and Colvin<sup>7</sup> described two more instances, in 1950 Rawson, Howard, Royster and Horn<sup>8</sup> mentioned 12, and in 1951 Kirklin, McDonald, Harrington and New<sup>9</sup> included 19 in a report of parotid tumors in general. Pung<sup>10</sup> added one case in 1952, and in 1953 eight were described in a report by Bauer and Bauer<sup>11</sup> and eight more were mentioned by Slaughter, Southwick and Walter.<sup>12</sup> It will be noted that the majority of the case reports have been published during the past decade. In the present review 157 cases were found mentioned in various reports.

## INCIDENCE

Despite the rather recent recognition of this tumor, it is of sufficient incidence compared with the better known salivary gland neoplasms to be of considerable importance. The 45 cases reported by Stewart et al.<sup>5</sup> were encountered among approximately 700 salivary gland tumors, an incidence of slightly more than 5 per cent. In the series of 160 cases of salivary gland neoplasms described by Rawson et al.,<sup>8</sup> the incidence was 7.5 per cent. Nineteen of the 717 tumors reported by Kirklin et al.<sup>9</sup> were mucoepidermoid carcinoma, representing 2.6 per cent. Bauer and Bauer<sup>11</sup> reported eight cases among 143 salivary gland

---

\*Former Fellow in Department of Pathology, now at Northwestern University Medical School and St. Joseph's Hospital, Chicago, Illinois.

RELATIONSHIP BETWEEN AGE OF PATIENT  
AND SITE OF MUCOEPIDERMOID CAR-  
CINOMA  
( 50 CASES )

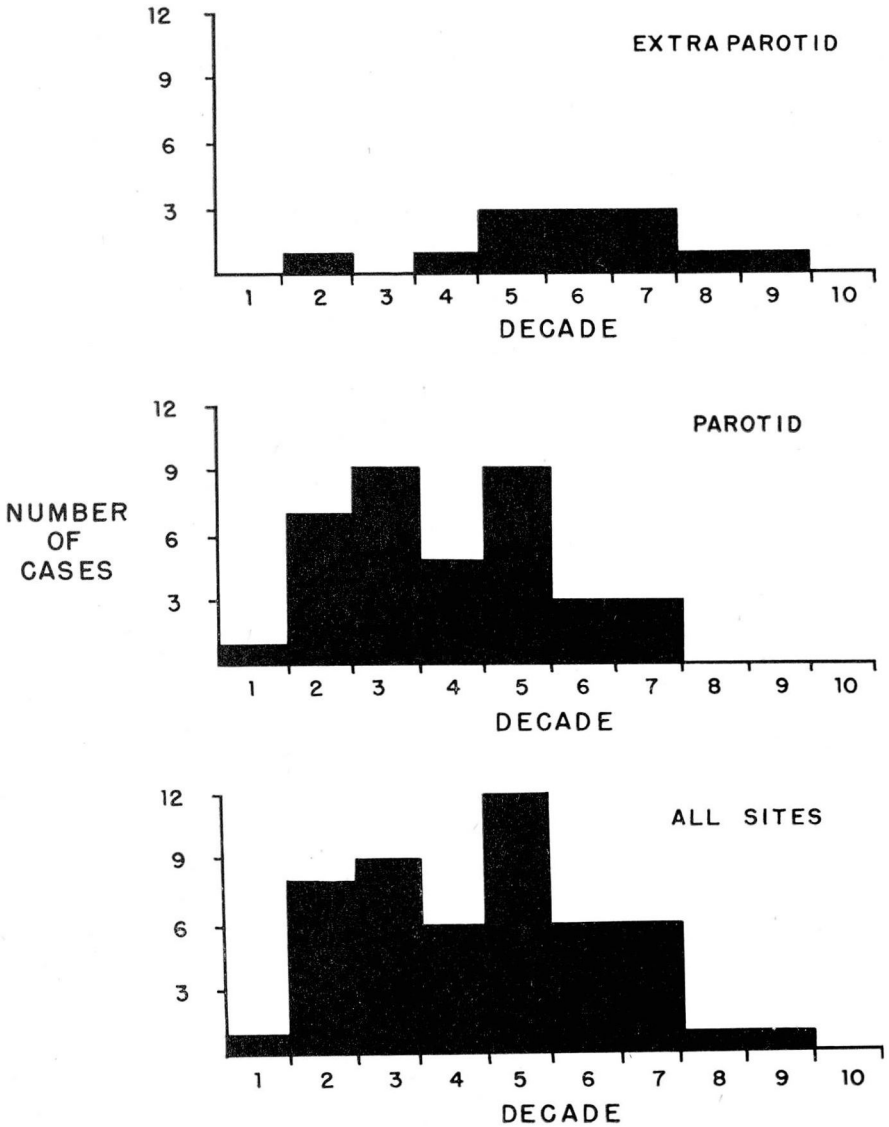


Fig. 1

tumors, 5.6 per cent. The ten cases of parotid origin in this report formed 5 per cent of tumors of this gland.

**Age.** Mucoepidermoid carcinoma of the salivary glands has been described in all age groups. It attains its highest incidence in the fifth decade when all sites are considered (fig. 1).

**Sex.** In 52 individual reports there were 35 women and 17 men, a ratio of approximately 2 to 1. Stewart et al. found an approximately equal sex distribution.

**SITE**

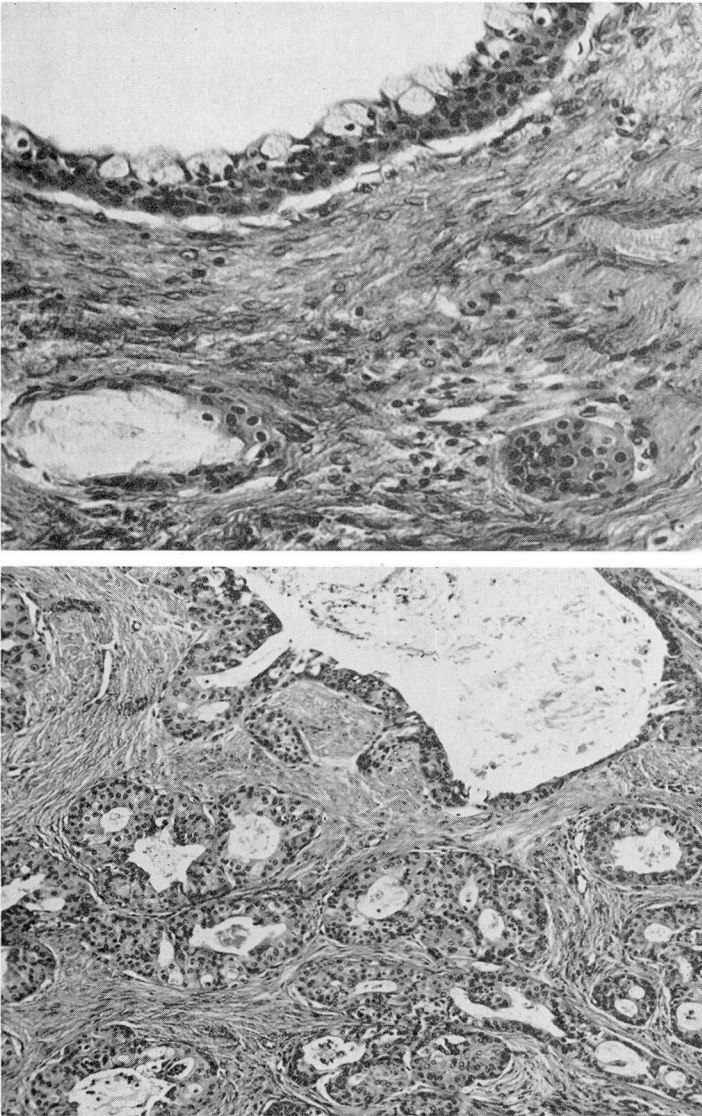
Mucoepidermoid carcinoma has been reported in all major salivary glands but in the majority of cases it has arisen in the parotid gland. The sites of origin of 157 cases including those of this report are summarized in Table 1. Of the minor salivary glands those of the tongue were involved most frequently, but neoplasms were found also in the lips, cheeks and palate. Owens<sup>13</sup> reviewed the cases of tumors of the minor salivary glands published in the 20 years prior to 1949 and found 14 mucoepidermoid tumors among the total of 1138 neoplasms. No record of the occurrence of this neoplasm in the lacrimal gland or other extra-salivary locations has been found.

Table 1

Sites of Origin of Mucoepidermoid Carcinoma		
Site		No. of Cases
Major salivary glands . . . . .		112
Parotid . . . . .	105	
Submaxillary . . . . .	6	
Sublingual . . . . .	1	
Minor salivary glands . . . . .		45
Total . . . . .		157

**PATHOLOGY**

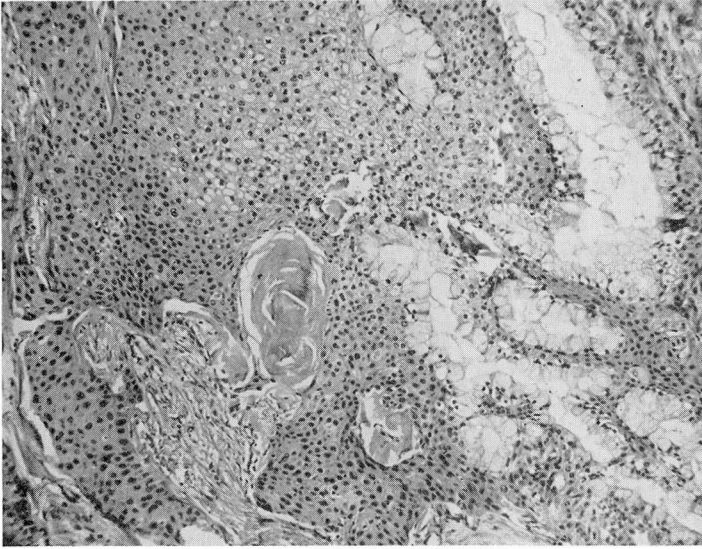
The neoplasm usually has a maximum diameter of 2 or 3 cm. but may range from a few mm. to 5 cm. The surface may appear rough and irregular or lobulated. Frequently, it lacks circumscription and fuses with adjacent structures. Encapsulation is recorded in a little more than 10 per cent of reported cases. The consistence varies from firm to hard depending on the amount of cyst formation. If cyst formation is marked, it may give the neoplasm a fluctuant character. At operation the first indication of the nature of the tumor may be the appearance of thick mucoid material when the tissue is incised. The tumor tissue is white or pale gray to tan, tough, and occasionally of cartilaginous consistence. It may be solid throughout, but in most instances is partly cystic.



(a)

(b)

Fig. 2. (Case 8) Mucoepidermoid carcinoma. (a) Small and large mucus-containing luminated structures formed by intermediate and basal cells and a few mucous cells. X 70. (b) Cyst lining formed by basal cells surmounted by goblet cells. X 200.



**Fig. 3.** (Case 7) Sheets of squamous cells with mucus-containing structures formed by goblet cells. X 70.

The microscopic appearance is distinctive. Typically, squamous and mucous cells are arranged in both cystic and solid formations and these cell types are intermingled with small cuboidal to polyhedral cells similar to those in the basal and intermediate positions in the parotid ducts (figs. 2 and 3). Also there may be polyhedral cells with abundant, pale, reticulated cytoplasm, suggestive of sebaceous gland cells. The mucous cells are often of goblet type (fig. 4) and usually line spaces of irregular size and contour. At times the spaces are partly or wholly devoid of lining epithelium and mucus lies in pools in the connective tissue stroma (fig. 5). In the more malignant forms of the tumor, the number of squamous and polyhedral cells is usually increased, arrangement is solid or cord-like, and the stroma is sparse. Commonly the neoplastic cells are well differentiated and show slight nuclear variability; mitoses are rare and tumor giant cells absent. In some tumors the epithelial cells have a pale-staining cytoplasm producing a hypernephroid appearance (fig. 6).

Generally, the epithelial elements are not limited by a capsule and invade the salivary gland tissue and neighboring structures, the latter to a limited extent. Distant metastases are uncommon, but regional and cervical node involvement is frequent.

### CLINICAL COURSE

The usual clinical course is one of slow progressive growth, local spread

and regional recurrence. The initial signs and symptoms are similar to those of the common mixed tumor of salivary glands. The first manifestation of the neoplasm is most often a painless swelling of firm rubbery or fluctuant consistence. The mass may be fixed initially or remain well defined and movable for an indefinite period. Other than the presence of a mass there are few subjective findings, although local pain, bloody saliva and facial weakness have been encountered occasionally. Typically, the neoplasm grows slowly and in some instances may remain the same size for prolonged periods. In 43 reported cases, 50 per cent of the patients had noted the presence of a mass for one year or less, about 25 per cent had noted it for more than three years, and slightly less than 10 per cent for 10 to 15 years. In the few instances that growth was rapid from the beginning there was more extensive involvement of the surrounding structures. Regardless of growth rate, invasion of adjacent structures is a common finding, and in neoplasms of the parotid gland involvement of the overlying skin may occur with ulceration and the formation of a salivary-cutaneous fistula. However, this was not a common feature in the cases of this series, occurring in only one instance where there had been operative interference with the tumor in the parotid. When the neoplasm arises in this gland, extensive involvement of the external ear may occur. The more malignant tumors also may invade the deep tissues and involve the bones of the jaw and mastoid region. In such cases cachexia is frequent.

With rare exceptions, recurrences following excision are at the site of the original neoplasm. Of 31 patients traced one year or longer, only seven were without recurrence. The majority of the 24 recurrences were within one year

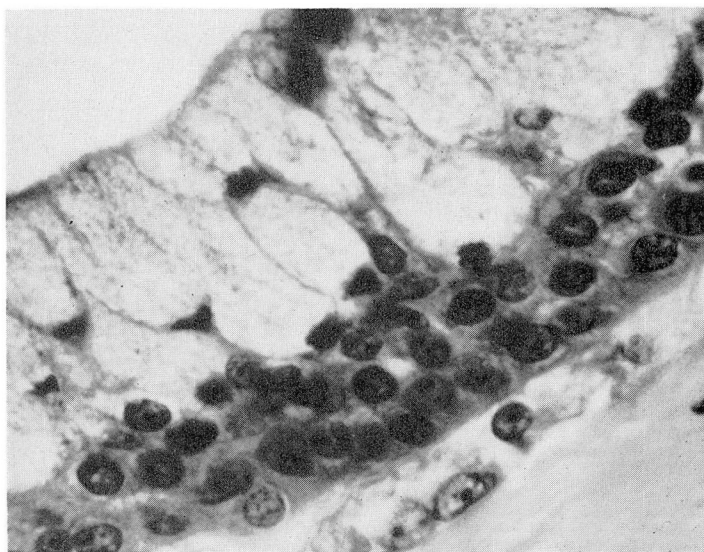
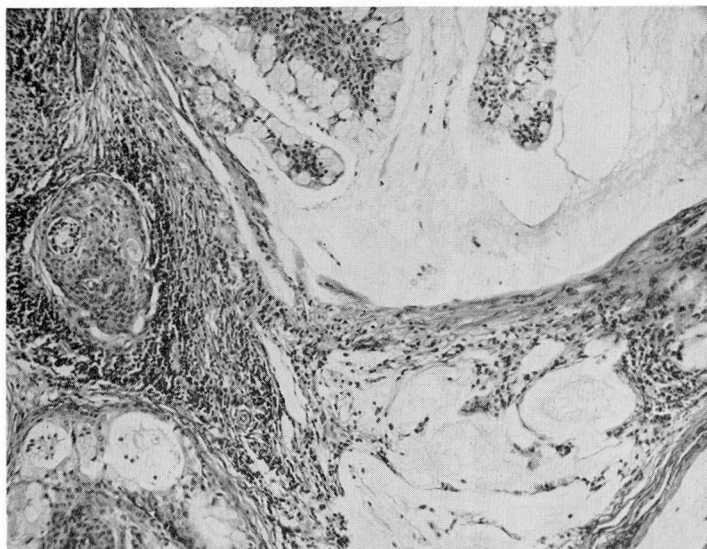
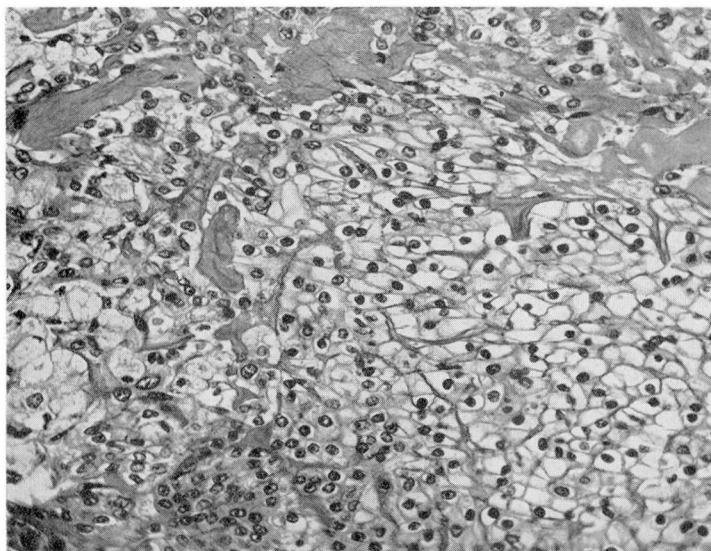


Fig. 4. (Case 2) A portion of wall of cystic structure with lining of goblet cells and basal cells. X 750.



**Fig. 5.** (Case 7) Pools of mucus in connective tissue stroma adjoining neoplastic islands of goblet and intermediate cells. X 70.



**Fig. 6** (Case 2) A portion of a neoplasm formed principally of large, pale, polyhedral cells of hypernephroid appearance; little stroma. X 200.

after operation but three were between seven and ten years. Stewart et al. reported two similar late recurrences. One of the four cases with recurrence in our own series of 12 showed reappearance of tumor in eight years after excision and radiation. Recurrence of the others ranged from 6 to 20 months.

Regional lymph node metastases were found in 10 of the 45 cases reported by Stewart et al.<sup>2</sup> and represent a common feature in the more rapidly growing neoplasms. Kirklin et al.<sup>9</sup> found metastasis to the regional nodes in 10.6 per cent. Three of the ten parotid tumors reported here revealed lymph node involvement and in a fourth, there was diffuse infiltration of the entire auriculo-parotid area.

Distant metastases were present in only 4 of the 45 cases in the series of Stewart et al.,<sup>5</sup> occurring in subcutaneous tissue, lungs, myocardium, liver and distant lymph nodes. McIntyre<sup>4</sup> reported a fatal case of mucoepidermoid carcinoma of the tongue, of only eight months' duration and at autopsy showing massive local extension, and metastases to the pericardium, myocardium, omentum and mesentery, liver and adrenal. In the majority of instances, however, the neoplasm does not lead to the death of the patient.

Kirklin et al. traced 18 of 19 patients and reported a three year survival of 94.4 per cent, a five year survival of 83.3 per cent, and no further deaths. In the series of 12 presented here only one patient has died.

## TREATMENT

Treatment consists of wide local excision. Allowance must be made for the fact that the gross margins are indistinct because of the common locally invasive nature of the tumor. Radiation therapy has been employed in a number of cases but its effectiveness cannot be evaluated with certainty. In our own series resection accompanied radiation in each instance where the latter was employed, making accurate evaluation of radiation therapy impossible. In one instance (case 9) radiation, 4800 r, was given without effect on the tumor, either in regard to size or histologic change as evidenced in the tissue removed two months later. However, after partial excision and interstitial radiation, the neoplasm clinically disappeared and has not been demonstrable for four years. In a second case (case 2), radiation given to a recurrence was stated as causing disappearance of the tumor, but there was recurrence in six months. In three other instances radiation did not prevent recurrence of the neoplasm.

## MALIGNANCY

From the foregoing descriptions it seems evident that this salivary gland tumor should be regarded as a malignant neoplasm. Kirklin et al.<sup>9</sup> were unable to find characteristics to separate them into benign and malignant groups and regarded them all as carcinoma. However, Rawson et al.<sup>8</sup> found that the tumors of a higher grade malignancy had a low stroma-epithelium ratio. Cyst formation



is less common in those with greater malignancy. This is true in the one fatal case of our series (case 2). In the majority of instances the squamous component of the neoplasm is similar to non-keratinizing squamous cell carcinoma, and in biopsy material may be mistaken for this. Clear cells may be readily confused with carcinoma of renal origin. The characteristics of local invasion and repeated rapid recurrences would seem to indicate that this neoplasm should be classified as carcinoma, though generally of low grade malignancy.

### Report of Cases

Ten of the 12 cases in this series arose in the parotid gland, one tumor arose in the hard palate and one in the base of the tongue. Certain features of the entire group are summarized in Table 2.

The combined occurrence of malignant mixed tumor and mucoepidermoid carcinoma was an unusual feature in case 5. Both elements were evident in parotid lymph nodes. The tumor on repeated recurrence, however, was purely mucoepidermoid.

A needle biopsy of the tumor of case 2 led at first to an erroneous diagnosis of squamous cell carcinoma. Limited biopsies of these neoplasms offer such a source of error since they may not include mucous elements and hence not be fully representative of the lesion. Clear cell areas may be confused with hypernephroma and, as might be expected, also might suggest sebaceous gland derivation.

The tumor in the one fatal case (case 2), though it was similar to the others in many regions, was in part poorly differentiated and showed nuclear variability, mitoses, irregular arrangement of epithelial elements, little stroma and a preponderance of the squamous and hypernephroid cell types (fig. 6).

### SUMMARY

Twelve cases of mucoepidermoid carcinoma have been summarized and include ten from the parotid, one from the base of the tongue and one from the hard palate.

The pathologic features of the neoplasm are distinctive. It appears grossly as an invasive or at times circumscribed, partly cystic, pale gray mass, and is distinguished microscopically by the presence of several types of cells, principal among which are squamous epithelial cells and mucin-containing cells.

The clinical course of mucoepidermoid carcinoma is characterized by the initial appearance of a tumor mass, usually painless, slow growth, local invasiveness and local recurrences following excision. Although distant metastases of this tumor are uncommon, both the clinical features and the pathologic characteristics indicate that it should be regarded as malignant.

TABLE 2  
Summary of Cases

Case No.	Race Sex	Age Years	Site	Initial Symptoms	Pathologic Aspects	Therapy and Clinical Course
1	W F	44	Parotid	Swelling. 6 mo., slight pain.	Infiltrating. Well differentiated	Excision, radiation (2000 r); recurrence 6 mo., excision and radiation (1092 mc. hr.). Living without recurrence 6 yrs.
2	N F	25	Parotid	Swelling, postauricular. Few months.	Infiltrating, auricular canal, mastoid zygoma, parotid area. Poorly differentiated, cellular for most part.	Excision, recurrence 1 yr.; radiation, "24 treatments," disappearance of tumor; recurrence 6 mo.; biopsy 1 yr., fistula formation; radical excision 1 yr.; recurrence, cervical metastases, death 6 mo.
3	W F	52	Hard palate	Tumor, 8 yrs.	Infiltrating. Well differentiated.	Biopsy, contact radiation (4000 r); excision, coagulation. Living, no recurrence 1 yr.
4	W F	28	Parotid	Mass below left ear, 3 yrs.	Circumscribed, infiltrating, well differentiated. Metastasis to parotid lymph node.	Partial excision, interstitial radiation (1300 mc. hr.); recurrence 20 mo.; excision, interstitial radiation (1300 mc. hr.). Living 15 yrs.
5	W M	35	Parotid	Swelling, below right ear. Duration un- stated.	Mucoepidermoid tumor in mixed lymph nodes. Recurrence as malignant mixed tumor and mucoepidermoid carcinoma, then as mucoepidermoid carcinoma only. Well differentiated.	Incision, "application of radium;" recurrence 8 yrs., excision; recurrence, excision, 4 yrs.; prompt recurrence, excision 6 yrs.; recurrence 1 yr., excision; recurrence 4 yrs., excision. Living 7 years with small nodule in scar.
6	W F	56	Parotid	Swelling right side of face, 3 yrs.	Poorly defined. Well differentiated.	Radiation (1950 r), excision. Last seen 2 mo. after operation.

Table 2 (cont'd)

Case No.	Race Sex	Age Years	Site	Initial Symptoms	Pathologic Aspects	Therapy and Clinical Course
7	W F	41	Parotid	Swelling anterior to left ear, 4 yrs.	Encapsulated, grossly; microscopic invasion including adjoining lymph node. Moderately differentiated.	Excision, radiation (3100 r). Living without recurrence 7 yrs.
8	W F	31	Parotid	Enlarging mass behind right ear, 4 mo.	Infiltrating. Moderately differentiated.	Excision, radiation (3900 r). Living without recurrence, 26 mo.
9	W M	23	Parotid	Lump anterior to right ear, 2½ mo.	Infiltrating. Moderately differentiated.	Radiation (4800 r); partial excision in 2 mo., interstitial radiation. Living 4 yrs., no apparent neoplasia.
10	W M	52	Parotid	Tumor anterior to left ear; fluctuating in size, 7 mo.	Grossly encapsulate, microscopic infiltration. Well differentiated.	Excision. Living 6 mo. no recurrence.
11	W F	32	Tongue	Cough; tumor found on physical examination	Infiltrating. Well differentiated basal and goblet cells.	Excision, cautery. Living 1 yr. no recurrence.
12	W F	62	Parotid	Lump at angle of left jaw, 3 yrs.	Infiltrating; mucous cysts, grossly.	Excision. Living 11 mo. no recurrence.

## References

1. Schilling, F.: Beitrag zur Kenntnis der Parotisgeschwülste, Ziegler Beiträge z. path. Anat. **68**:139-160, 1921.
2. Volkmann, R.: Ueber endotheliale Geschwülste, zugleich ein Beitrag zu den Speicheldrüsen und Gaumentumoren. Deutsch Zeitschr. f. Chir., **41**:1-180, 1895.
3. Lecene, P.: Adenomes et Kystes della Parotide. Rev. de Chir. **37**:1-17, 1908.
4. Skorpil, R.: Ueber das schleimbildende Epitheliom der Speicheldrüsen. Virchow's Arch. f. Path. Anat. u. Physiol. **305**:661-794, 1940.
5. Stewart, F. W., Foote, F. W., and Becker, W. F.: Muco-epidermoid tumors of salivary glands. Ann. Surg. **122**:820-844 (Nov.) 1945.
6. Linell, F.: Mucus-secreting and cystic epidermoid carcinomas of mucous-and salivary glands. Acta path. et microbiol. Scandinav. **25**:801-828, 1948.
7. Godwin, J. T. and Colvin, S. H., Jr.: Benign mucoepidermoid tumor. Arch. Path. **47**:512-515 (May) 1949.
8. Rawson, A. J., Howard, J. M., Royster, H. P. and Horn, R. C., Jr.: Tumors of salivary glands; clinicopathologic study of 160 cases. Cancer **3**:445-458 (May) 1950.
9. Kirklin, J. W., McDonald, J. R., Harrington, S. W. and New, G. B.: Parotid tumors; histopathology, clinical behavior, and end results. Surg., Gynec. & Obst. **92**:721-733 (June) 1951.
10. Pung, S.: Muco-epidermoid tumor of the parotid gland. Report of case. Am. J. Clin. Path. **22**:1153-1156 (Dec.) 1952.
11. Bauer, W. H. and Bauer, J. D.: Classification of glandular tumors of salivary glands; study of 143 cases. Arch. Path. **55**:328-346 (April) 1953.
12. Slaughter, D. P., Southwick, H. W., and Walter, L.: The fate of recurrent or persistent parotid tumors. Surg., Gynec. & Obst. **96**:535-540 (May) 1953.
13. Owens, H.: Minor salivary gland tumors in respiratory tract and ear; review of literature and report of 2 cases. Laryngoscope **59**:960-983 (Sept.) 1949.
14. McIntyre, H. W.: Mucoepidermoid carcinoma of the salivary gland. Report of a case with autopsy findings. Arch. Path. **56**:79-83 (July) 1953.