

MASSIVE LOBAR EMPHYSEMA IN INFANTS: DIAGNOSIS AND TREATMENT

Report of Three Cases

ROBERT D. MERCER, M.D.,

Department of Pediatrics

WILLIAM A. HAWK, M.D.,

Division of Pathology

and

GHAZAR DARAKJIAN, M.D.*

Department of Pediatrics

MASSIVE lobar emphysema in infants deserves more widespread recognition, because it requires emergency surgical treatment. The condition is readily diagnosed, and if untreated may prove fatal. Surgical removal of the involved lung tissue is lifesaving.

Diagnosis

The disease may be recognized clinically from the history, physical examination, and roentgenograms. In general the history is that of a baby who was normal at birth but in whom respiratory distress developed within the first few weeks of life. Often the respiratory distress is intermittent and is precipitated by feeding or by crying. It is characterized by dyspnea, wheezing, grunting, coughing, and cyanosis. As the disease progresses the dyspnea and cyanosis become profound and the infant may die of respiratory failure.

The physical findings are those of emphysema. The child breathes with difficulty with flaring of the ala nasi and retraction of the costal cartilages. Breathing is audibly difficult, and an expiratory wheeze is commonly heard. The breath sounds are diminished on the diseased side, sometimes having an amphoric quality. Crackling rales may be heard on both sides in addition to the expiratory wheeze.

Excitement, or the greater respiratory effort associated with feeding or crying may cause cyanosis. The portion of thorax over the involved side is more prominent than that over the uninvolved side. The excursion of the chest wall during respiration is limited. The percussion note is hyperresonant, although this fact may be difficult to demonstrate in the normally resonant infant's chest. Laryngeal stridor is not present. The heart is displaced to the side opposite the lesion, and the diaphragm is displaced downwards.

Roentgenograms show evidence of such severe emphysema that attention may erroneously be directed to the opposite side, and the diagnosis of atelectasis may

*Fellow in the Department of Pediatrics.

be made. Usually there is atelectasis of the lobes adjacent to the emphysematous lobe. Often in addition to the displacement of the mediastinal contents there is herniation of the involved lobe across the mediastinum.

The differential diagnosis includes congenital cystic disease of the lung, pneumatocele, spontaneous pneumothorax, localized emphysema, generalized obstructive emphysema, aspiration of a foreign body, hyaline membrane disease, diaphragmatic hernia or eventration, and cyanotic congenital heart disease. Accurate interpretation of the roentgenograms will serve to differentiate most of these diseases. It is important to note the persistence of pulmonary markings in massive lobar emphysema, which are not present in congenital cystic disease of the lung, in pneumatocele, or in pneumothorax. There has been much unnecessary confusion between congenital cystic disease and lobar emphysema. Localized emphysema such as may be seen in association with cystic fibrosis of the pancreas may be difficult to distinguish from lobar emphysema until the primary disease has been recognized. Aspiration of a foreign body is rare in infants so young; hyaline membrane disease is rare in infants so old. Both diseases may be ruled in or out by the history and roentgenograms. The latter also serve to establish the presence or absence of diaphragmatic hernia. Congenital heart disease may be difficult to differentiate since it often is seen in association with massive lobar emphysema. When uncertainty exists, the clinician's problem is to decide which disease is most threatening to the life of the patient.

Treatment

The treatment of massive lobar emphysema in infants is always the surgical removal of the involved pulmonary lobe. This seems to be readily accomplished by skilled surgeons, even in the most desperate circumstances. Relief of the symptoms promptly follows removal of the lobe.

Pathologic Study

The surgically resected pulmonary specimen was studied in each of the three cases. In two instances the tissue was dissected in the fresh state and representative blocks were fixed in modified Zenker's fluid.* One specimen was fixed by instilling 10 per cent formaldehyde into it via the main bronchus to the lobe; representative blocks were then taken after fixation was complete. All sections were stained with hematoxylin-eosin and methylene blue stain. The fibrous tissue component of the representative blocks was assessed by means of Masson's trichrome stain, and the elastic tissue component was assessed by means of Verhoeff's elastic-tissue stain. Representative blocks, usually two to a lobe, were routinely taken, one from the hilar region and one from the peripheral portion

*Mercuric chloride, 3.5 per cent; potassium dichromate, 2.5 per cent; glacial acetic acid, 3 per cent; in distilled water.

of the parenchyma. As control material, representative sections of necropsy specimens from infants of approximately the same age were compared with the sections for this study.

Report of Cases

Case 1. A three and one-half month old white male infant was first examined in September, 1954, because of "heart disease." The pregnancy and delivery had been normal, and the infant at six weeks of age was thought to be healthy when examined by his physician. When he was two months old, the parents noted episodes of heavy breathing after crying, but no cyanosis or coughing. On examination he was breathing rapidly with retraction of the sternal notch and lower rib margins. The respirations had an unusual stridulous quality not suggestive of laryngeal stridor. Scattered fine crackling rales could be heard at the end of inspiration, accompanied by some sibilant expiratory wheezes. The breath sounds were amphoric on the right side. The right side of the chest wall did not move with respirations. A grade 3 to grade 4 systolic bruit could be heard maximally over the left second to fourth interspaces. A systolic thrill could be palpated in this region. The pulmonic second sound was greatly accentuated. Fluoroscopy disclosed about 25 per cent over-all cardiac enlargement predominantly involving the right ventricular outflow tract. The mediastinum was displaced to the left and did not shift with respirations. The electrocardiogram revealed a sinus rhythm. The P waves were high and peaked in standard lead 2; they were notched in standard lead 1, and diphasic in leads from the right precordium. The R-R interval was 0.39 sec.; the Q-T interval, 0.27 sec. The precordial pattern revealed the presence of incomplete right bundle-branch block thought to be associated with right ventricular hypertrophy. Roentgenograms demonstrated evidence of an enlarged heart (*Figs. 1 and 2*). There was notable emphysema of the right middle lobe, with partial atelectasis of the right upper and right lower lobes.

Cardiac catheterization was performed by Dr. F. Mason Sones, Jr., of the Department of Pediatric Cardiology and Cardiac Laboratory, through the right superficial femoral vein. A high interventricular septal defect was demonstrated as well as a patent foramen ovale. Significantly high right ventricular pressure essentially equal to the femoral arterial systolic pressure was present. Pulmonary venous blood returning from the left upper pulmonary vein and that in the left atrium demonstrated gross arterial oxygen unsaturation with only 84 per cent of capacity.

A thoracotomy was performed by Dr. Laurence K. Groves of the Department of Thoracic Surgery. The right middle lobe of the lung was greatly enlarged, and it would not collapse when positive pressure was removed via the anesthesia circuit or by direct finger pressure. Patchy atelectasis was present, particularly in the superior segment of the lower lobe and the posterior segment of the upper lobe. The right middle lobe was removed without difficulty; it was noted that the bronchial stump leaked little air even with positive pressure maintained by the anesthetist. The postoperative course was uneventful and the respirations were greatly improved.

The resected right middle lobe was 8.0 cm. by 6.5 cm. by 2.0 cm., and weighed 30.0 gm. (*Fig. 3*). The general configuration was that of an overinflated or emphysematous

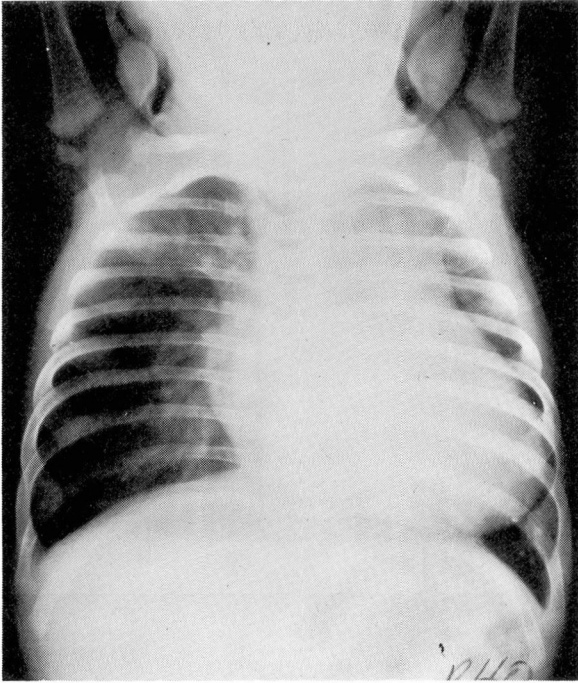


Fig. 1. Case. 1. Roentgenogram of the chest, demonstrating massive emphysema of right middle lobe with cardiac enlargement.

pulmonary lobe. Grossly the hilus of the lobe revealed no abnormality of the major bronchi or of the major pulmonary vessels.

Sections from the hilar area and from the periphery of the lobe showed dilatation of the tertiary bronchi and of the terminal bronchioles (*Fig. 4*). The cartilaginous, muscular, and epithelial components of the tertiary bronchi and the terminal bronchioles appeared to be within normal limits. The pulmonary parenchyma showed so widely dilated an alveolar pattern, that alveolar ducts, alveolar sacs, and alveoli could not be separately identified. Many of the alveolar walls were ruptured, thus forming irregular, polyhedral, partially septated spaces. The septae in general were thin, and no significant inflammatory infiltrate was observed. The intraalveolar hemorrhage was thought to have been surgically induced. Since it was known that the bronchial stump had not leaked air during the operation, it was presumed that an obstructive lesion in the bronchus of the right middle lobe had been left intact at the time of the operation. The child was followed for two years as an outpatient. At the first examination four months postoperatively, dyspnea was absent, but the parents stated dyspnea had remained for some time after the child was discharged from the hospital. He had had two respiratory infections, in the interval, which were not unusually severe. On further follow-up examinations he was noted to have had a great number of respiratory infections, and his general growth and development were subnormal. Cardiac surgery was advised

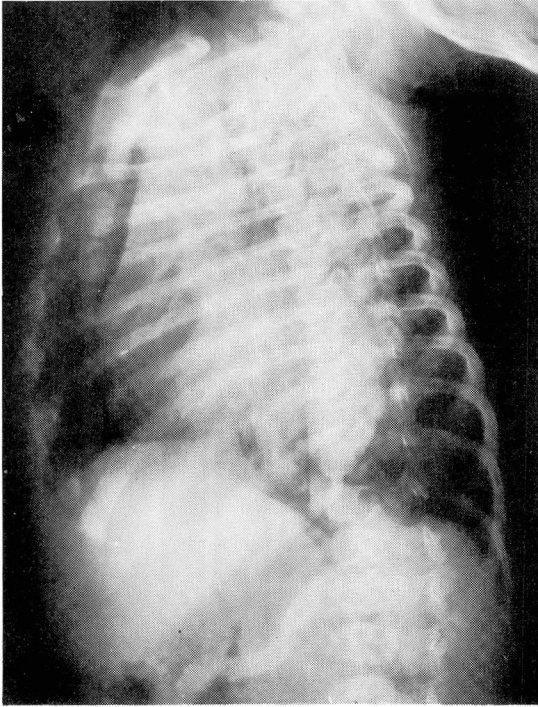


Fig. 2. Case 1. Oblique roentgenogram of the chest, demonstrating herniation of right middle lobe in the anterior mediastinum.

in 1956, but was refused by the parents. The patient has not been examined since that time.

Case 2. A three-week-old white male infant was first examined in November, 1959, because of cyanosis during crying. The pregnancy and delivery had been normal. The parents had noticed that the child was dusky when feeding, and breathed heavily. On physical examination the baby seemed critically ill. The lips, hands, and feet were cyanotic. The respirations were rapid and labored with retraction of the sternum. An expiratory wheeze could be heard. A systolic thrill was palpated over the precordium. The heart rate was 160, and a grade 4 systolic murmur was heard at the apex. The liver was slightly enlarged. Electrocardiograms showed evidence of a sinus tachycardia with a ventricular rate of 167. The P-R, Q-R-S, and Q-T intervals were normal. Large secondary R waves were present over the right side of the precordium in leads V1, V2, V3, and V3R, with reciprocal deep S-wave deflections over the left side of the precordium in V5 and V6. The tracing was read as showing incomplete right bundle-branch block, and right ventricular hypertrophy. Roentgenograms demonstrated evidence of severe emphysema of the right middle pulmonary lobe, with herniation of this lobe across the mediastinum (*Figs. 5 and 6*). The right upper lobe was atelectatic and the heart was displaced to the left.

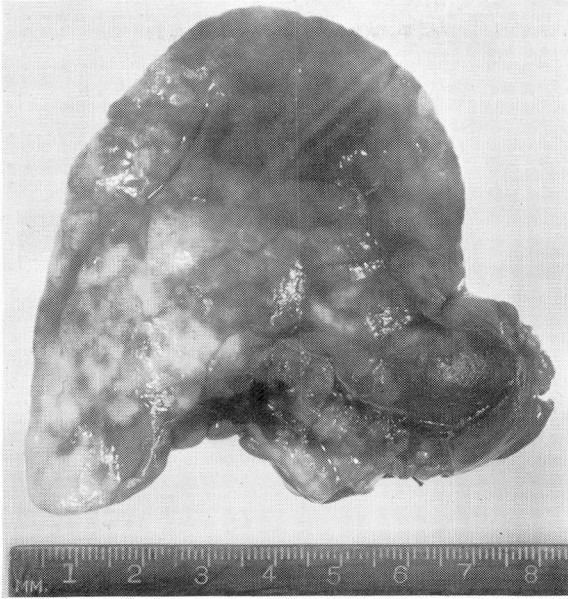


Fig. 3. Case 1. Resected right middle lobe.

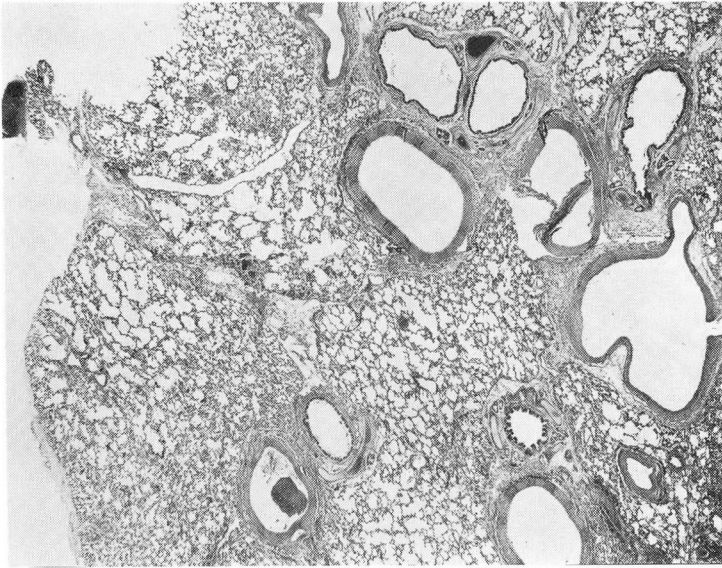


Fig. 4. Case 1. Photomicrograph of section showing widely dilated alveoli in pulmonary parenchyma; magnification X 10.

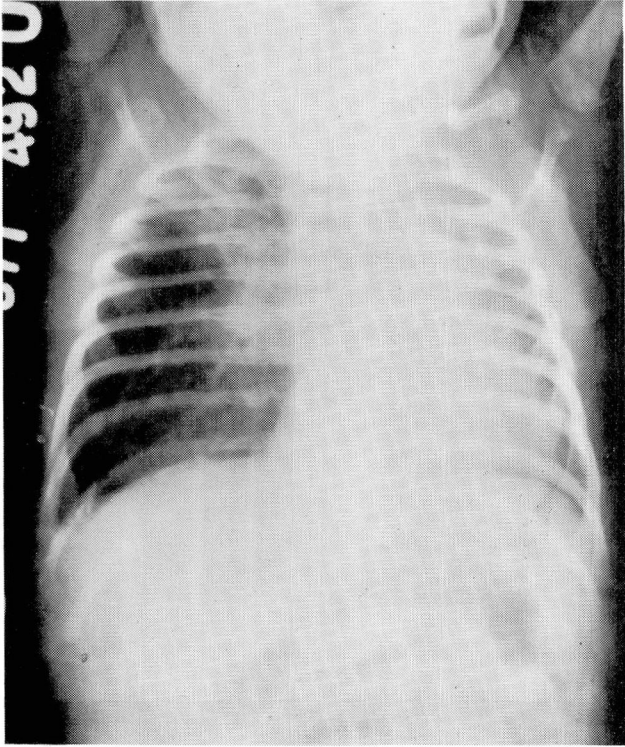


Fig. 5. Case 2. Roentgenogram of the chest, demonstrating massive emphysema of the right middle lobe, and the heart displaced to the left.

A thoracotomy was performed by Dr. Donald B. Effler of the Department of Thoracic Surgery. The greatly expanded right middle lobe could not be manually compressed, and the bronchus of the lobe appeared unusually small. The lobe was removed and the atelectatic upper and lower lobes were re-expanded. The infant tolerated the procedure well and the emergency situation was relieved.

The resected right middle lobe was immediately fixed by intrabronchial instillation with formalin solution. Dissection of the fixed specimen revealed bronchi of normal caliber and distribution. The major vessels appeared normal. Histologic sections of the tertiary bronchi and terminal bronchioles showed dilatation of these structures with moderate festooning of the ciliated epithelial lining. The bronchial cartilages and the smooth muscle of the tertiary bronchi appeared normal. The terminal bronchioles had the usual smooth muscles, but the cartilaginous plates were not observed in multiple sections. The pulmonary parenchyma contained irregularly enlarged alveolar spaces formed in part by the rupture of the alveolar septae. The distinction between alveolar ducts, alveolar sacs, and alveoli could not be made. There was no significant inflammatory reaction.

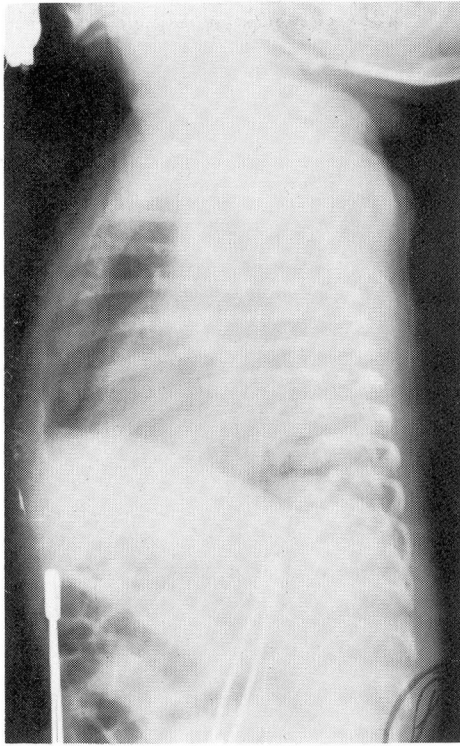


Fig. 6. Case 2. Lateral roentgenogram of the chest, demonstrating herniation of the right middle lobe in the anterior mediastinum.

At the age of two and one-half months the baby was readmitted for cardiac studies. The child had had no dyspnea, but still occasionally became cyanotic during crying. On examination the cardiac findings were essentially as previously observed. On fluoroscopy the heart appeared to be from 30 to 35 per cent enlarged. There was moderate enlargement of the right ventricular inflow and outflow tracts. The barium-filled esophagus was displaced far to the right.

Cardiac catheterization was performed in January, 1960, by Dr. Earl K. Shirey of the Department of Pediatric Cardiology and Cardiac Laboratory. Segmental hypoplasia of the right hilar pulmonary arteries could be demonstrated, and severe aneurysmal dilatation of the right main pulmonary artery. The left main pulmonary artery was normal in size, but there was hypoplasia of the distal radicals with extreme avascularity of the left upper lobe. A small interventricular septal defect was present. The status of the pulmonary valve was not ascertained as this valve could not be crossed with the catheter. The cardiac problem was considered inoperable and the child was discharged to his home in apparently good condition. Ten days later there was a sudden onset of severe cyanosis and shortness of breath after vomiting. The infant was admitted to another hospital where he died. The autopsy confirmed the findings of the cardiac catheteriza-

tion. Scattered small areas of emphysema and atelectasis were present in both lungs. No abnormality of the bronchi was described.

Case 3. A six-month-old white female infant was examined in August, 1960, because of difficulty in breathing. The pregnancy and delivery were reported to have been normal. She was said to have been well until two months of age when an upper respiratory infection developed and she suddenly became acutely ill with severe dyspnea. She was admitted to another hospital where a diagnosis of acute tracheobronchitis was made. She was treated with antibiotics, increased humidity and oxygen, and she seemed to recover. Subsequently she was hospitalized twice for similar respiratory difficulties. Roentgenograms were said to show evidence of lack of normal aeration over the right side. The left side was said to be well aerated. At the time of our initial examination the child was breathing with considerable difficulty. The chest was asymmetric, the left side being more prominent than the right side. Expiratory wheezes were prominent bilaterally. Breath sounds were decreased on the left side. Breathing was less difficult after the administration of Adrenalin, but the difference in breath sounds on the two sides persisted. Roentgenograms demonstrated evidence of a greatly increased radiolucency of the left lung field (*Fig. 7*). The heart and the mediastinum were displaced to the right.

Bronchoscopy under general anesthesia was performed by Dr. Donald B. Effler of the Department of Thoracic Surgery. The trachea was normal; the left main bronchus

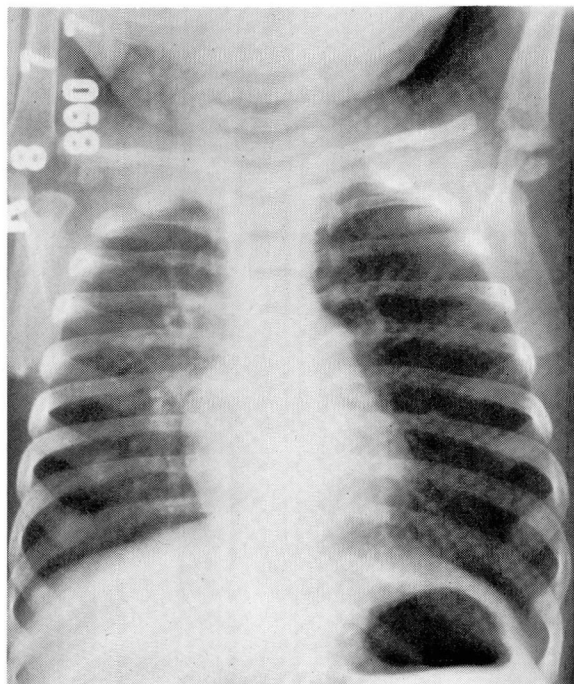


Fig. 7. Case 3. Roentgenogram of the chest, demonstrating massive emphysema of the left lung.

was erythematous with a pinhole caliber. On the next day the child's condition deteriorated rapidly, and an emergency thoracotomy was performed. The entire left lung was tremendously expanded, and it was impossible manually to compress it. When the left bronchus was transected it was observed that no air came through the bronchial stump, even under positive pressure exerted by the anesthetist. When the inflated lung was removed the child's condition promptly improved. Respirations continued to be wheezing and noisy but without dyspnea. She was discharged from the hospital 10 days after the operation.

The left lung was greatly distended but otherwise normal on gross inspection. Dissection of the bronchi and major vessels showed no abnormalities. Multiple histologic sections showed uniform distention of the tertiary bronchi and terminal bronchioles. The ciliated respiratory epithelium showed some festooning and infolding but it was less pronounced than that in the previous patient (case 2). Cartilage was present in the normal amount in the tertiary bronchi, but was not observed in the terminal bronchioles. The pulmonary parenchyma showed extremely enlarged and irregular air spaces formed sometimes by distended alveoli, and sometimes by rupture of alveolar septae (*Fig. 8*). No significant inflammatory infiltrate was present.

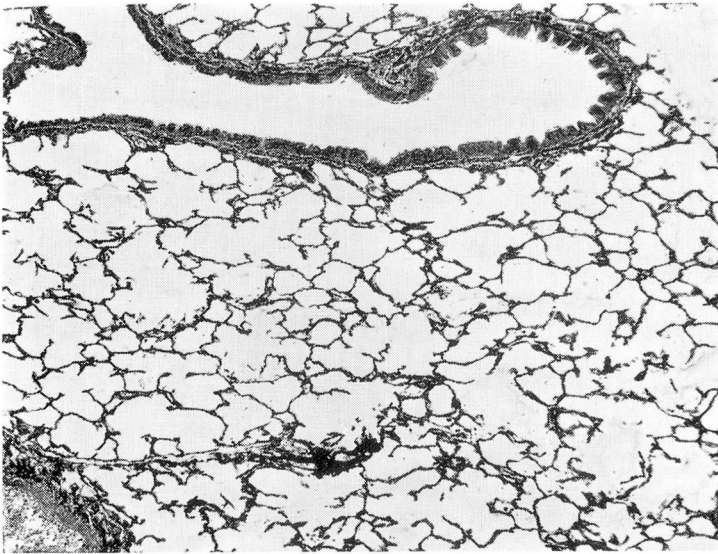


Fig. 8. Case 3. Photomicrograph of a section of the left lung, demonstrating extremely distended alveoli; magnification X 55.

Discussion

Forty-nine cases that to us represent examples of massive lobar emphysema are reported in the literature.¹⁻²⁷ This small number of cases does not accurately reflect the incidence of the disease, since at least nine additional cases were mentioned by those who discussed Sloan's¹ paper on the subject. In our opinion,

the first authentic case was reported by Nelson² in 1932. He referred to this as a case of congenital cystic disease of the lung, and the first to be reported in America; however, his description suggests that his patient had massive lobar emphysema. Gross and Lewis³ in 1945 performed the first successful operation for this disease in a patient who had previously been unsuccessfully operated upon because of a large mediastinal defect.

In general, massive lobar emphysema produces symptoms in early infancy. Most patients who did not have surgical treatment died.^{2,4-7} It is possible that some patients with massive lobar emphysema have survived to adult life.^{8,9} The early report of Wethered,¹⁰ in 1896-1897, concerning a 51-year-old man, and that of Royes,¹¹ in 1938, concerning a 28-year-old man, are in our opinion of doubtful authenticity.

Lobectomy or pneumonectomy is the treatment of choice. Two patients¹² are reported to have been treated by needle aspiration, and although neither diagnosis was proved histologically, the presumptive diagnosis of each seems to be correct. In both instances needle aspiration was followed by tension pneumothorax.

Massive lobar emphysema in infants is probably caused by several factors. It would seem that obstruction of the air passages is the basic etiologic factor, although such obstruction is not always apparent. Deficiency in bronchial cartilage causing collapse of the bronchus on expiration has been the single most common associated finding;^{2-6,8,13-15} stenosis of the bronchus leading to the involved lung has also been common.^{3,7,16} Other possible causes include mucosal folds,^{4,7,14,17} external compression of a bronchus by an abnormal blood vessel,^{4,5,7,14,18} and inflammation of the bronchus.^{4,19} Possibly a stenotic bronchus was left behind at the time of operation in some of the patients in whom there was no apparent cause for the disease.^{1,20} Congenital heart disease, exclusive of abnormalities of the great vessels, has been described in several cases,^{18,21} and was present in two of our three patients. Though relationship between the congenital heart disease and the massive lobar emphysema is not clear, it is important to decide which disease is most threatening to the life of the patient. Bolande, Schneider, and Boggs⁴ described an alveolar fibrosis, in some of their patients, associated with a thickening of the supporting stroma of the alveolar walls.

The three case reports presented here demonstrated essentially the same microscopic findings in the lungs: uniform dilatation of bronchi and bronchioles, and overdistention of alveoli with rupture of alveolar septae. No cause for the emphysema was evident on study of the resected tissue. In each case stenosis of the bronchus leading to the emphysematous area was described at the time of the operation. The possibility that hypoplasia of the bronchial or bronchiolar cartilages, or hypoplasia of elastic tissue could be responsible for the emphysematous process was entertained. In all three cases, however, these structures were comparable to normal tissues removed from infants of similar ages. In no case were there significant areas of interstitial or peribronchial inflammation or fibrosis.

Summary

Massive lobar emphysema is readily diagnosed from the pathognomonic physical and roentgenographic features of the disease. Three cases of massive lobar emphysema in infants are reported. These three cases each demonstrated the presence of stenosis of the bronchus leading to the emphysematous lobe involved. The various etiologic agents described in the literature as the cause of this disease are discussed; these include hypoplasia of bronchial cartilages; valves or folds of bronchial mucosa; alveolar fibrosis; and pressure on the bronchus from abnormal blood vessels. The possibility that a stenotic bronchus may have been left behind at the time of operation in so-called "idiopathic" cases is mentioned. The treatment of this disease is surgical removal of the involved lobe, and such surgical removal is lifesaving.

References

1. Sloan, H.: Lobar obstructive emphysema in infancy treated by lobectomy. *J. Thoracic Surg.* 26: 1-16; discussion, 16-20, 1953.
2. Nelson, R. L.: Congenital cystic disease of lung; report of case. *J. Pediat.* 1: 233-238, 1932.
3. Gross, R. E., and Lewis, J. E., Jr.: Defect of anterior mediastinum; successful surgical repair. *Surg. Gynec. & Obst.* 80: 549-554, 1945.
4. Bolande, R. B.; Schneider, A. F., and Boggs, J. D.: Infantile lobar emphysema; etiological concept. *A.M.A. Arch. Path.* 61: 289-294, 1956.
5. Nelson, T. Y., and Reye, R. D. K.: Tension emphysema: surgical emergency in infants. *M. J. Australia* 2: 342-343, 1954.
6. Overstreet, R. M.: Emphysema of portion of lung in early months of life. *Am. J. Dis. Child.* 57: 861-870, 1939.
7. Robertson, R., and James, E. S.: Congenital lobar emphysema. *Pediatrics* 8: 795-804, 1951.
8. Holzel, A.; Bennett, E., and Vaughan, B. F.: Congenital lobar emphysema. *Arch. Dis. Childhood* 31: 216-221, 1956.
9. Case records of Massachusetts General Hospital; weekly clinicopathological exercises; case 36041. *New England J. Med.* 242: 149-152, 1950.
10. Wethered, F. J.: Case of hypertrophy of lung. *Tr. Path. Soc. London* 48: 34-37, 1896-1897.
11. Royes, K.: Localized hypertrophic emphysema. *Brit. M. J.* 2: 659, 1938.
12. Korngold, H. W., and Baker, J. M.: Non-surgical treatment of unilobar obstructive emphysema of newborn. *Pediatrics* 14: 296-303, 1954.
13. Diamond, I.: Case of lobar emphysema. *J. Kentucky M. A.* 54: 354-356, 1956.
14. Fischer, H. W.; Potts, W. J., and Holinger, P. H.: Lobar emphysema in infants and children. *J. Pediat.* 41: 403-410, 1952.
15. Shaw, R.: Localized hypertrophic emphysema. *Pediatrics* 9: 220-227, 1952.

16. Silver, A. W.; Kirklín, J. W.; Harris, L. E., and McDonald, J. R.: Localized hypertrophic emphysema. *Dis. Chest* 30: 456-462, 1956.
17. Leahy, L. J., and Butsch, W. L.: Surgical management of respiratory emergencies during first few weeks of life. *Arch. Surg.* 59: 466-483, 1949.
18. Cottom, D. G., and Myers, N. A.: Congenital lobar emphysema. *Brit. M. J.* 1: 1394-1396, 1957.
19. Williams, M. H.: Localized pulmonary hypertrophic emphysema. *J. Thoracic Surg.* 24: 522-529, 1952.
20. Van Epps, E. F., and Davies, D. H.: Lobar emphysema. *Am. J. Roentgenol.* 73: 375-386, 1955.
21. Liebner, E. J.: Radiologic aid in regional and generalized emphysema of lungs in infants. *Pediatrics* 24: 1050-1064, 1959.
22. Fischer, H. W.; Lucido, J. L., and Lynxwiler, C. P.: Lobar emphysema. *J.A.M.A.* 166: 340-345, 1958.
23. Henry, W.: Localized pulmonary hypertrophic emphysema. *J. Thoracic Surg.* 27: 197-203, 1954.
24. Koontz, A. R.: Congenital cysts of lung. *Bull. Johns Hopkins Hosp.* 37: 340-361, 1925.
25. Lewis, J. E., and Potts, W. J.: Obstructive emphysema with defect of anterior mediastinum; report of case. *J. Thoracic Surg.* 21: 438-443, 1951.
26. Potts, W. J.; Holinger, P. H., and Rosenblum, A. H.: Anomalous left pulmonary artery causing obstruction to right main bronchus; report of case. *J.A.M.A.* 155: 1409-1411, 1954.
27. White-Jones, R. H., and Temple, L. J.: Congenital lobar emphysema. *Arch. Dis. Childhood* 29: 248-253, 1954.