

CYSTS AND SINUSES OF THE NECK*

EUGENE A. GASTON, M.D.

Cysts and sinuses of the neck may be roughly classified into those which occupy the midline and those which lie lateral to the midline. This discussion deals with cysts and sinuses lying in both locations but is limited to those which arise from the deeper-lying embryologic structures. Thus dermoids, simple retention cysts of the skin, etc., have been excluded except as they are involved in the differential diagnosis.

The nomenclature of the subject is in a rather chaotic state. There is considerable evidence to show that not only do the so-called "branchio-genic" or "branchial" cysts and fistulae fail to arise from the branchial apparatus but that, in like manner, the "thyroglossal" cysts and sinuses do not arise directly from the thyroglossal apparatus. Because the terms "branchial" and "thyroglossal" have become so ingrained in the literature, they have been retained in this discussion and used synonymously with the simpler terms "lateral" and "median" respectively.

PART I

BRANCHIAL CYSTS AND FISTULAE

Etiology and Embryology: In the human embryo, the branchial apparatus is a very transitory structure which is first evident during the latter half of the first month of intra-uterine life and has completely disappeared by the end of the second month. This apparatus arises in the region of the neck and consists of five or six bars or arches separated by corresponding depressions or grooves. The arches are termed the branchial or visceral arches and the intervening depressions, as viewed from the outside, are called the branchial grooves. Similarly the lining of the pharynx, as viewed from the inside, is thrown into elevations by the depth of the branchial arches and these depressions between the arches are spoken of as the pharyngeal pouches. On the outside the arches are covered with ectoderm while on the inside the covering is entodermal in origin. Mesoderm separates entoderm from ectoderm, and, in the regions where the branchial clefts meet the pharyngeal pouches, this mesodermal separation is very thin. In gill-bearing animals the ectoderm and entoderm disappear at this point of apposition to form the gill slits.

Most writers are in agreement regarding the ultimate disposal of the components of the branchial apparatus in normal development. The first arch is larger than the others and divides into upper and lower portions. The upper portion forms the upper lip and a portion of the maxilla and side of the cheek. The lower portion forms the lower lip and a portion

*Abstract of Fellowship Thesis which was awarded the William E. Lower Fellowship Thesis Prize for 1936.

of the mandible, the body of the tongue, and the muscles of mastication. From the first branchial cleft comes the external auditory canal and the lobe of the ear; the first pharyngeal pouch gives rise to the eustachian tube and the tympanic cavity. The tympanic membrane is the remnant of the first gill membrane, that point of apposition of ectoderm and entoderm where the first branchial cleft meets the first pharyngeal pouch.

The second branchial arch gives rise to the lesser cornu of the hyoid bone, the styloid process, which fuses with the temporal bone, and the intervening stylohyoid ligament. From it also develop muscles of the anterior portion of the base of the tongue and the arcus palatoglossus. No traces of the second, third, or fourth branchial clefts persist. The second pharyngeal pouch develops into the sinus tonsillaris and the tonsil.

The third arch gives rise to the greater cornu and body of the hyoid bone, the stylopharyngeus muscle, and some of the muscles making up the soft palate. The corresponding pharyngeal pouch gives rise to the thymus, a structure of great importance to the present consideration.

The ultimate destination of the fourth, fifth, and sixth arches is not definitely known nor is it of great importance to this discussion. In general these arches make up the soft parts in the region of the greater cornu of the hyoid bone. The fourth pharyngeal pouches give rise to the lateral lobes of the thyroid gland.

Most authorities today subscribe to Wenglowski's¹ theory that lateral cervical cysts and fistulae arise from remnants of the embryologic thymic duct. This structure is first visible in the 6.5 mm. embryo where it may be seen as a tube-like structure with a definite lumen descending from the third pharyngeal pouch on each side. It then descends laterally to the anlagen of the lateral thyroid lobes to a point near the lower border of the latter where the structure changes from that of a tube to that of a solid, gland-like organ (Figs. 1 and 2). Concomitant with this caudalward progression, the tube-like prolongation extending from the third pharyngeal pouch retrogresses and eventually disappears in an orderly fashion from above downward.

"If the thymus anlage did not retrogress it would go from the pharynx laterally and slightly downward to the area between the angle of the jaw and the ear lobe. From here it passes downward, forward and medially, lying close to the lateral border of the thyroid gland and medial to the anterior border of the sternomastoid muscle, down to the sternum where it passes into the actual gland substance."² Because this so accurately describes the course actually taken by lateral cervical fistulae, Wenglowski¹ concluded that remnants of the tubular thymus anlage actually comprise the lateral cervical fistula. As further evidence that these pathological entities do not arise from the branchial

CYSTS AND SINUSES OF THE NECK

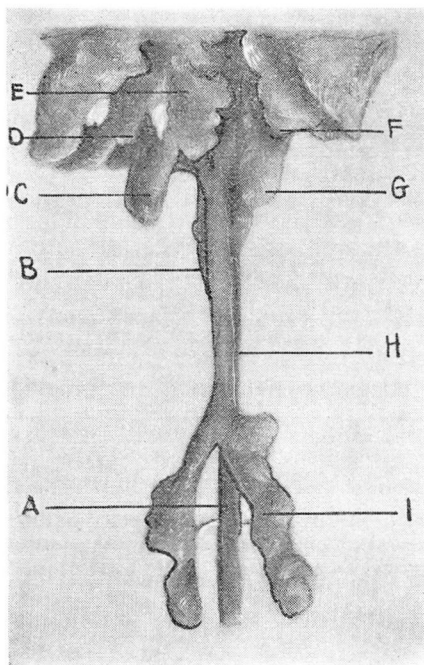


FIGURE 1: Esophageal lumen and branchial apparatus of 6.5 mm. embryo. A. esophagus; B. trachea; C. lateral thyroid lobes; D. thymus anlage; E. midthyroid anlage; F. thymus anlage; G. lateral thyroid anlage; H. esophagus; I. left lung anlage. (Redrawn after Wenglowski¹).

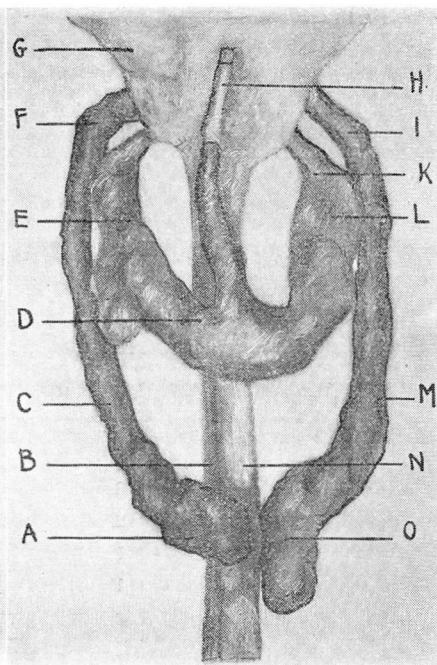


FIGURE 2: Pharynx, esophagus, trachea, and organs developing from them in a 14 mm. embryo. A. thymus; B. esophagus; C. thymus duct; D. midthyroid lobe; E. lateral thyroid lobe; F. thymus duct; G. pharynx; H. thyroglossal tract; I. thymus duct; K. lateral thyroid lobe duct; L. lateral thyroid lobe; M. thymus lobe; N. trachea; O. thymus. (Redrawn after Wenglowski¹).

apparatus proper, he pointed out that remnants of the latter could not exist below the level of the hyoid bone, a point which no present day authority disputes. Against this theory is the fact that not infrequently a lateral cervical fistula opens internally in the supratoronsillar fossa which, as we have seen, arises from the second pharyngeal pouch.

Accepting Wenglowski's theory, it is evident that complete lateral cervical fistulae, (i. e., a patent sinus connecting internal and external openings) are a remnant of the thymic duct per se. Cysts in this region arise from remnants of the midportion of the duct where there is no avenue for the products of epithelial metabolism to escape into the pharynx or externally. Incomplete fistulae with internal openings only are rare and are a remnant of the upper portion of the duct. Fistulae with external openings only arise from the surgical or, less frequently, the spontaneous rupture of a preëxisting cyst.

CLINICAL ASPECTS

Incidence: At the Cleveland Clinic the diagnosis of branchiogenic cyst or fistula has been made a total of eighty-nine times, an incidence in this institution of less than 0.05 per cent. The incidence in the population at large must, of course, be considerably less than this.

Pathology: These embryological remnants give rise to symptoms because they are made up of misplaced epithelium which retains its capacity to form the products of epithelial metabolism. These products are the content of the cysts and the discharge which proves so annoying to the patient with an open sinus.

The epithelium may vary in its structure from that of stratified squamous to transitional or columnar. In the majority of instances where the epithelium is columnar, it is of the ciliated variety. Wengowski was able to explain this variation by showing that the lining of the thymic duct varies from squamous at its upper extremity to ciliated columnar at its lower extremity. It is true, as a general rule, that cysts placed high in the neck are usually lined by squamous epithelium whereas those low in the neck are very often lined with columnar epithelium.

The epithelium, regardless of its type, is surrounded by a layer of fairly dense fibrous tissue which usually contains lymphoid follicles in great abundance. The presence of these lymphoid follicles is such a constant finding that it is of considerable importance in establishing a diagnosis microscopically.

Like all embryological remnants, these cysts and fistulae are subject to certain pathological processes which are not peculiar to themselves but may also affect normal tissues. Chief among these is infection which may be either acute or chronic. The acute suppuration of a lateral cervical cyst not infrequently follows an acute infection of the upper respiratory tract, probably as a result of drainage into the lymphatics that abound in the cyst wall. The acute suppuration may point and rupture spontaneously, following which the infection may subside or become chronic. In the latter instance the resulting sinus may continue to discharge intermittently for years. In rare instances the cyst or sinus may be the site of a tuberculous infection as was true in one patient operated upon at this clinic. When infection has been present for a long time, there frequently is no trace of an epithelial lining. It is interesting to note that these embryological remnants are but rarely the sites of malignant degeneration.³

Clinical features: The following study was made on a series of twenty-nine cases of lateral cervical cyst and four cases of lateral cervical fistula in which operation was performed at the Cleveland Clinic. In general the findings agree with similar studies reported in the literature.

CYSTS AND SINUSES OF THE NECK

Cysts: The average age of the patients operated upon was 40.5 years; the youngest was 15 and the eldest 65. The sexes were equally divided—15 men and 14 women. The average duration of symptoms before the patient was seen was 3.7 years, the longest duration 20 years.

In the majority of instances the patient first consulted a physician because of a painless swelling of the neck. Since the swelling usually is painless, the tumor often reaches a considerable size before the patient is aware of its presence. In this series the size of the tumor was described as varying from that of an olive to that of a large orange. In four cases the onset followed an acute infection of the upper respiratory tract.

On examination the tumor usually was described as being cystic or fluctuant but in rare instances it was so tense that its cystic nature was overlooked. In twenty-one of the twenty-nine cases the tumor was located between the angle of the jaw and the mastoid process at or just under the medial edge of the sternomastoid muscle. In three cases, the tumor was found at the level of the hyoid while in five cases the position was not accurately described. The cysts were evenly divided between the two sides, fifteen on the right and fourteen on the left. An internal opening was seen in but one case and that was described as being "low in the pharynx."

Surgery had been employed previously in four of the cases. In each instance, simple incision had been made which resulted in a period of drainage, following which the cyst refilled. On the basis of a mistaken diagnosis one patient was given a course of deep x-ray therapy without relief.

Of the twenty-nine patients operated upon, one postoperative death occurred, a mortality of 3.4 per cent. Follow-up data of one year or more are available for twelve patients (41 per cent), and none of these has had a recurrence of the cyst or drainage from a cervical sinus.

Sinuses: Four patients, all of whom were women, have been operated upon for lateral cervical fistula. The average age was 18 years; the youngest was 8 and the eldest 27 years. One sinus had been present since infancy and the ages of onset of symptoms in two of the remaining three patients were 6 and 19 years respectively. All patients gave a history of having had a cyst previously which either had ruptured spontaneously or been incised surgically. An internal opening was present in but one case and this was in the suprathonsillar fossa.

The external opening in each case was along the medial border of the sternomastoid muscle. In one case it was at the level of the cricoid cartilage; in two it occurred at the level of the sternoclavicular articulation, and the level was not stated in one instance.

At operation it was possible to trace the sinus tract to the pharyngeal wall in every case. In all but one of the cases, this occurred at a point low in the pharynx, definitely below the level of the tonsillar fossa.

Follow-up studies are available in two of the four cases. Both these patients have remained free from symptoms for an average of 8 years since the operation.

Diagnosis: Lateral cervical fistulae usually present little difficulty in diagnosis. The location, as emphasized above, is typical while the presence of an internal opening establishes the diagnosis. Fistulae without internal openings may be distinguished from tuberculous sinuses by the history of a preceding cyst which has been drained surgically or has ruptured spontaneously as a result of secondary infection. Very rarely is more than one external opening present whereas the scrofulous sinus frequently has many. The presence of tuberculous disease elsewhere in the body, of course, favors the diagnosis of scrofula.

In making a diagnosis of branchial cyst one should keep in mind that this is a smooth cystic tumor which bears a constant relationship to the sternomastoid muscle; it is usually fixed to the underlying tissues but, in the absence of acute inflammatory change, is never fixed to the overlying skin.

Branchial cysts are most frequently confused with broken-down tuberculous glands, as was the case in four patients operated upon at this clinic. In making a differential diagnosis between the two conditions, the complete absence of cervical adenitis favors the diagnosis of the former while the presence of tuberculosis elsewhere in the body favors the diagnosis of the latter. Furthermore it is unlikely that a tuberculous abscess would exist for several years without becoming attached to the overlying skin. The fact that the contents of tuberculous abscesses and branchial cysts are quite similar on gross examination while, with ordinary culture methods, both are sterile are factors which tend to confuse the picture. The presence of cholesterol crystals in the fluid removed from the cyst is evidence on which a positive diagnosis can frequently be made.

Simple dermoid cysts of the neck occur infrequently. Usually they are more superficial than branchial cysts, and the presence of hair as well as the lack of any especial attachment to the lateral pharyngeal wall makes their diagnosis at operation comparatively easy. Fortunately it is rarely necessary to make a careful distinction between the two before operation, since adequate operative removal is essential in either case.

Cystic hygroma of the neck presents a loculated cystic tumor of very soft consistency which usually can be transilluminated with light. Branchial cysts can never be transilluminated. The occurrence of cystic hygroma in early childhood is a further differentiating point.

CYSTS AND SINUSES OF THE NECK

Deep seated venous hemangioma of the neck may be distinguished by the "sign of emptying,"⁴ i. e., pressure on one portion of the tumor mass causes the fluid to be translocated into another portion.

Lipoma is easily distinguished by its consistency and by the negative results of aspiration.

Malignant neoplasms of the neck, both primary and secondary, are occasionally subject to cystic degeneration. In the case of primary growths the diagnosis must often be made from a biopsy specimen removed at operation. In secondary growths the discovery of a primary site of the disease will establish the diagnosis.

Thyroglossal cysts and fistulae are readily distinguished by the fact that they occur in the midline. Their attachment to the hyoid causes them to change position with deglutition.

Treatment: The treatment of branchial cysts and sinuses is entirely surgical and involves the complete extirpation of all epithelial bearing tissue. The fistulous tract must be carefully dissected down to the lateral wall of the pharynx and amputated. In our experience it has not been necessary to invert the stump of the fistula into the cavity of the pharynx. In the case of branchial cyst a careful search must be made at the time of operation for a strand of epithelial-bearing tissue connecting the cyst to the pharynx. If such a strand is allowed to remain, a recurrence of the cyst is possible.

PART II

THYROGLOSSAL CYSTS AND SINUSES

Incidence: At the Cleveland Clinic the diagnosis of thyroglossal cyst or sinus has been made 130 times, an incidence of 0.07 per cent. In this series sixty operations were performed. The results of a clinical study of these sixty cases are presented.

Etiology and Embryology: Thyroglossal cysts and fistulae result from a defect in the development of the thyroid gland, which has three points of origin, two lateral and one medial, which give rise to the corresponding lobes. The lateral lobes develop as prolongations from the fourth pharyngeal pouches. These prolongations grow downward and medially to join the anlage of the median lobe (Fig. 2). Development of the lateral anlagen is first evident in the 6.5 mm. embryo. As downward growth proceeds, the pharyngeal or upper portion of the anlage atrophies and, at the 16 mm. stage, the lateral lobes have no connection with the pharynx.

The median thyroid anlage, with which we are most concerned here, begins in the fourth week of embryonic life at a point between the first

and second branchial arches near the tuberculum impar which, in the adult, is marked by the foramen caecum of the tongue. His⁵ called this median thyroid anlage the "thyroglossal duct," believing that it had a lumen and that it was directly responsible for the formation of these midline cysts. Wenglowski¹, however, showed this tract to be a solid down-growth of cells which never exhibits a lumen. He presented adequate evidence to show that the midline cysts associated with the thyroglossal tract are the result of proliferation and secretion of epithelial cells carried from the oral epithelium into the mesenchyme of the neck by the rapid descent of the thyroglossal tract. Cysts arise from the misplaced oral epithelium because these cells retain their embryonic properties of developing as oral epithelium and of forming a secreting surface which, surrounded on all sides by connective tissue, give rise to a cyst for lack of a means of drainage. Sinuses arise by the spontaneous or surgical opening of such cysts.

The only embryological defects to which the cells of the thyroglossal strand itself give rise are the aberrantly placed nodules of thyroid tissue which are seen occasionally. These may arise at any point along the course of the thyroglossal tract from the base of the tongue to the lower part of the neck. Lateral aberrant thyroids similarly arise from the anlagen of the lateral thyroid lobes.

Pathology: Like the branchial cysts and fistulae described in Part I, the midline cysts and fistulae are lined with epithelium which may vary in structure from stratified squamous to ciliated columnar. The underlying tissue consists of fibrous tissue which may or may not be infiltrated with lymphoid elements. Microscopically it is impossible to distinguish the cysts and sinuses occurring in the midline from those arising on the lateral aspects of the neck.

Midline cysts and sinuses, like those on the lateral aspects of the neck, are subject to infection; this probably is often due to the lymphatic drainage of the upper respiratory passages into the lymphoid tissue which surrounds them. No case of tuberculous infection of a thyroglossal cyst or sinus has come to our attention.

Clute and Cattell⁶ have described the only case of adenocarcinoma arising from the thyroglossal tract that has been reported in the literature. These authors feel that the rare cases of epidermoid carcinoma of the thyroid gland probably arise from misplaced oral epithelium which is carried down by the thyroglossal tract.

The contents of midline cysts are similar to those of branchial cysts and both may contain cholesterol crystals.

Clinical Features: This study is based upon thirty-four operations for thyroglossal cysts and twenty-six for thyroglossal sinus which have been performed at the Cleveland Clinic.

CYSTS AND SINUSES OF THE NECK

The sex, age of the patients at the onset of symptoms and at the time of operation, as well as the duration of symptoms before any surgical procedure was instituted are summarized in Table I. As will be seen,

TABLE I
THYROGLOSSAL DISEASE

	Cyst (34 Cases)	Sinuses (26 cases)
Sex—Male	10 cases—29 per cent	10 cases—39 per cent
Female	24 cases—71 per cent	16 cases—61 per cent
Age at onset		
Average	32 years	13.6 years
Present at birth	1 case	1 case
Eldest at onset.....	60 years	67 years
Age when first seen		
Average	34.7 years	21 years
Youngest	5 years	6 years
Eldest	65 years	68 years
Duration of symptoms		
Before First Operation	3.1 years	3.1 years

females predominate over males in a proportion of 2 to 1. This is to be compared with an incidence of 7 to 1 for females in diseases of the thyroid gland.⁶ Thyroglossal sinus occurs at a considerably younger age than does thyroglossal cyst, 13.6 years being the average age of onset of the former and 32 years of the latter. The extremes of age at the time of onset are approximately the same, one patient in each group giving a history that the anomaly was present at birth. The duration of symptoms from onset until operation was the same in each case, 3.1 years.

Symptomatology: The patient with thyroglossal cyst comes for treatment because of a painless, usually slowly growing, tumor in the midline of the neck. In only rare instances does this tumor cause pain (four instances in the present series). The size of the tumor may vary from that which is just palpable to the size of a golf ball or even larger. In consistency, the cyst usually is firm or semifluctuant. Hoarseness and dysphagia are much less frequent symptoms than would be expected from the location of the tumor, the former occurring but once and the latter but three times in this series.

Patients with thyroglossal sinus are much more uncomfortable because of the persistent or recurrent drainage which soils the clothing and generally is unsightly. The majority of patients (73 per cent in this series) gave a history of a cyst which either had ruptured spontaneously or had been drained surgically. Very often spontaneous

rupture is a result of acute infection of the lining of the cyst, often coming on after an infection of the upper respiratory tract. It bears repeated emphasis that surgical drainage with or without the presence of acute infection always results in a chronically draining sinus.

TABLE II
LOCATION OF MIDLINE CYSTS AND FISTULAE

<i>Location</i>	Cyst	Sinus (External opening)	Total Cases	Per cent
Submental	1	2	3	5.0
Between hyoid and thyroid cartilage.....	18	8	26	43.3
Level of thyroid cartilage	6	8	14	23.3
Level of cricoid cartilage.....	2	3	5	8.3
Level of isthmus of thyroid gland	3	1	4	6.6
Suprasternal notch	2	0	2	3.3
Level not stated	2	4	6	10.0

Table II presents a summary of the location of midline cysts and fistulae. Two-thirds occurred between the hyoid bone and the lower border of the thyroid cartilage.

Diagnosis: The fact that thyroglossal sinuses occur in the midline, that the patients give a typical history of a preceding cyst which had ruptured spontaneously or been surgically drained combined with the fact that the sinus tract can be felt to extend from the external orifice to the hyoid region and can be felt to move with deglutition makes the diagnosis comparatively easy. Rarely (in two instances in this series), the cyst will be opened not at its lowermost midline portion, but away from the midline. This, of course, makes the point of drainage lateral to the midline and may lead to confusion in the diagnosis. However, the sinus tract always leads to the region of the hyoid bone and usually the major part of its course can be felt. The sinus tract moves with deglutition regardless of the location of the external opening. These points serve to distinguish it from tuberculous sinus which rarely opens in the midline.

Thyroglossal cysts present a somewhat more perplexing diagnostic problem. They may be distinguished from the midline adenomas of the thyroid by the difference in consistency and by aspiration of the contents of the cyst. Confusion with discrete, midline, tuberculous glands has been reported in a few instances. Dermoids are not easily differentiated, but these and wens are less likely to move with deglutition.

Treatment: The treatment of midline cysts and sinuses of the neck consists of the complete extirpation of all epithelial-bearing tissue.

CYSTS AND SINUSES OF THE NECK

In order to accomplish this it is necessary to remove not only the cyst or sinus tract below the level of the hyoid bone, but also that portion which extends from the center of the hyoid up to the foramen caecum. In order to accomplish this latter and most important step in the operation, it is necessary to split or resect the central portion of the body of the hyoid. The tract per se usually cannot be traced above this point, but must be removed by coning out the surrounding tissue for a distance of 0.3 cm. on each side up to the foramen caecum. In performing this dissection it is necessary to keep clearly in mind the direction the thyroglossal tract takes in its course from the hyoid to the foramen caecum. Sistrunk⁷ has pointed out that this corresponds to a line drawn at an angle of 45 degrees posteriorly and superiorly through the right angle intersection of lines drawn horizontally and perpendicularly to the superior central portion of the hyoid bone.

Results of Treatment: Of the thirty-four patients with thyroglossal cyst who have been operated upon at the Cleveland Clinic, previous excision of the cyst had been performed elsewhere in three instances. In each case the cyst recurred and the hyoid was resected in none. Simple incision and drainage was done elsewhere in one instance.

Excision of the cyst was performed in thirty-three of the thirty-four cases and one simple incision and drainage was done for acute infection. Of the thirty-three cases in which excision was done, a portion of the hyoid was resected and the dissection carried up to the foramen caecum in seventeen. In two additional cases, the hyoid was split in the midline, the dissection was carried up to the foramen caecum, and the hyoid was resutured without the removal of a portion of its center. In fourteen cases the dissection was not carried through or above the hyoid. A satisfactory follow-up was obtained in twenty of the thirty-three cases in which excision was done. The average time of follow-up was 5.4 years, the extremes varying from 1 to 10 years. The cyst recurred in only one case, this being one in which the hyoid was not resected and in which the dissection was not carried up to the foramen caecum, while in none of the cases in which this procedure was carried out was there a recurrence. This serves to illustrate again the adequacy of the Sistrunk⁷ operation and the inadequacy of any lesser procedure.

Of the twenty-six patients with thyroglossal sinus, who have been operated upon at this clinic, fifteen (58 per cent) had been operated upon previously. Of these fifteen cases, excision of the sinus tract or of a preceding midline cervical cyst had been performed in seven instances. At operation there was no evidence in any of these that the hyoid bone had been divided or excised in its midportion. Simple incision and drainage of a preceding cyst had been done elsewhere in seven cases and repeated incision and drainage plus an unsuccessful

attempt at excision had been used in one case. One patient gave an unusual history of the complete absence of symptoms for a period of fifteen years following simple incision and drainage of a noninfected cyst. These figures again speak for the necessity of doing the complete operation in every case.

Of the twenty-six operations performed for thyroglossal sinus sixteen were complete; in nine the dissection was not carried above the hyoid, and in one the treatment of the hyoid was not described. A satisfactory follow-up was obtained from twelve patients, the time of follow-up varying from 1 to 10 years (average 4.3 years). In none of these has there been a recurrence. In ten of the twelve cases followed, the hyoid bone was divided or excised in its midportion and the thyroglossal tract dissected out in its entirety up to the foramen caecum.

REFERENCES

1. Wenglowski, R.; Ueber die Halsfisteln und Cysten, Arch. f. klin. Chir., 98:151-208, 1912; 100:789-902, 1913.
2. Meyer, H. W.: Congenital cysts and fistulae of neck, Ann. Surg., 95:1-26; 226-248, (January, February) 1932.
3. Ewing, J.: Neoplastic Diseases, 3rd. ed. W. B. Saunders Co., Philadelphia, p. 1023, 1928.
4. Bailey, H.: Thyroglossal cysts and fistulae, Brit. J. Surg., 12:579-589, (January) 1925.
Complete eradication of the thyroglossal tract, Brit. M. J., 2:138-139, (July 25) 1931.
Clinical aspects of branchial fistulae, Brit. J. Surg., 21:173-182, (October) 1933.
5. His, W.: The Precervical Sinus and Thymus Anlage. Arch. f. Anat. u. Entwicklungsgeschichte, p. 241-426, 1886.
6. Clute, H. M. & Cattell, R. B.: Thyroglossal cysts and sinuses, Ann. Surg., 92:57-66, (July) 1930.
7. Sistrunk, W. E.: Surgical treatment of cysts of thyroglossal tract, Ann. Surg., 71:121, (February) 1920.
Cysts of thyroglossal tract, Surg. Clin. N. Amer., 1:1509, (October) 1921.
Technique of removal of cysts and sinuses of thyroglossal duct., Surg., Gynec., & Obst., 46:109-112, (January) 1928.