

THE ILEAL CONDUIT IN THIRTY-FIVE CHILDREN

RALPH A. STRAFFON, M.D.,

Department of Urology

RUPERT B. TURNBULL, JR., M.D.,

Department of General Surgery

and

ROBERT D. MERCER, M.D.

Department of Pediatrics

CHILDREN who require urinary diversion rarely have malignant disease, therefore, with the possibility of a normal life span, long-term results are of vital importance. Of the surgical procedures employed, ureterosigmoidostomy has been used most frequently, particularly in patients with exstrophy of the bladder. However, the sequela of chronic pyelonephritis, hydronephrosis, and electrolyte imbalances after ureterosigmoidostomy, have prompted searches for other methods of urinary diversion.

In 1956 Bricker¹ reported the use of an isolated ileal segment as a conduit for urine. Since then, other authors²⁻⁵ have presented their experience with the ileal conduit. These reports have dealt primarily with the ileal conduit in adults, with little emphasis on its use in children.

Ileocystoplasty⁶ and cutaneous vesicostomy⁷ are alternative methods that require an intact bladder, and closure of the vesical neck when incontinence is present. These procedures have been utilized in only a few children to date,⁸ and the long-term effectiveness remains to be determined.

This report presents our experience with the ileal conduit constructed in 35 children.

Indications

The ileal conduit has been used in three groups of patients in our series: (1) 9 children with exstrophy of the bladder, (2) 23 children with autonomous neurogenic bladder with incontinence, and (3) 3 children with obstructive lesions that produce severe hydronephrosis and renal insufficiency. The ileal conduit has been used by other surgeons in children who have epispadias and incontinence, severe trauma to the bladder, congenital absence of abdominal musculature, or when there is a bladder neoplasm such as sarcoma botryoides which requires cystectomy.

In children with exstrophy of the bladder the ileal conduit was used to salvage the urinary tract when ureterosigmoidostomy was a failure. Primary diversion with the ileal conduit was performed in only one child in this series.

In our experience no child with an autonomous neurogenic bladder and urinary incontinence has spontaneously gained complete continence as growth progressed.

There is no apparent correlation between the severity of the physical handicap produced by muscle weakness and atrophy of the lower extremities and the degree of bowel and bladder dysfunction. When the child is able to empty the bladder, has uninfected urine, a normal upper urinary tract according to the pyelograms, and normal renal function, surgical intervention may be delayed. A schedule of periodic evaluations of these factors should be adhered to in order to be able to note any progressive deterioration of renal function or other signs that would make surgical intervention mandatory. When the incontinent child starts school life, the uriniferous odor and the protective padding may stimulate ridicule from his classmates. We have noted great improvement in the social and psychologic development of the handicapped child after construction of the ileal conduit.

Obstructive lesions in the lower urinary tract may produce severe hydronephrosis and renal insufficiency early in life. Implantation of the dilated, tortuous ureters into an ileal conduit is often a lifesaving procedure, by providing drainage of the upper urinary tract and preserving the remaining renal function. The presence of an increased blood urea content has not been considered a contraindication to operation, the ileal conduit having given good results under such circumstances. Extreme youth has not been a contraindication to the procedure.

Results

In the 35 children who underwent supravescical diversion utilizing the ileal conduit there were no operative or postoperative deaths. All the children have adjusted well to the ileostomy and the collection appliances. The average postoperative hospital stay was 12 days, and the postoperative follow-up period ranges from two months to more than six years.

We have operated on three children under two years of age, the youngest being nine months. The young children tolerated the procedure extremely well, and were progressing satisfactorily at the time of their most recent examinations. The all-plastic appliance, consisting of a Torbot* mounting ring and a Marlin† polyvinyl pouch, has been used on each child. This appliance in appropriate size has worked well even in the tiny children.

The postoperative status of the urinary tract, as determined by intravenous pyelography, is summarized in *Table 1*. The preoperative and postoperative intravenous pyelograms of a child with a normal upper urinary tract before the operation are demonstrated in *Figure 1, A and B*. The pyelograms have shown a normal upper urinary tract for more than three years after the construction of the ileal conduit. *Figure 2* shows the improvement that may be obtained in a child with hydronephrosis by providing better drainage via the ileal conduit.

Preoperative and postoperative blood urea and electrolyte determinations are

*Torbot Company, 175 Vine Avenue, Warwick, Rhode Island.

†Marlin Manufacturing Company, 14807 Kinsman Road, Cleveland, Ohio.

summarized in *Table 2*. No serious electrolyte imbalances have been encountered in children in whom an ileal conduit was constructed.

Table 1.—*Postoperative status of the urinary tract in 35 children* with ileal conduits, as determined by intravenous pyelography*

Preoperative urogram	Postoperative urogram, function		
	Unchanged	Improved	Deteriorated
Normal structure	28	0	3
Mild hydronephrosis	0	7	0
Moderate hydronephrosis	14	7	0
Not visualized	7	3	0
Total	49 (71%)	17 (25%)	3 (4%)

*Representing 69 kidneys; each kidney is considered a separate unit.

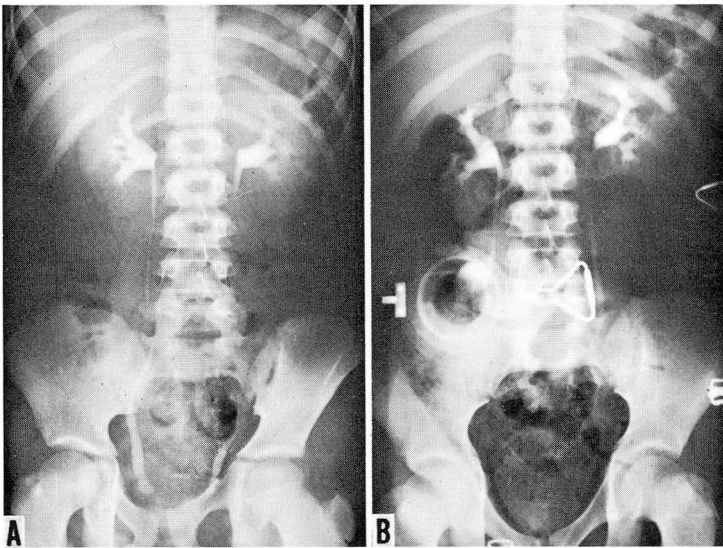


Fig. 1. A, preoperative intravenous pyelogram of a child with an autonomous neurogenic bladder. B, postoperative intravenous pyelogram made more than three years after construction of the ileal conduit.

Postoperative Complications

Early complications. The early postoperative complications were essentially minor. There were no children in whom urinary leakage occurred at the ureteroenterostomy. A prolonged ileus developed in one child, but there was no mechanical bowel obstruction in any child. Four children had transient episodes of chills and

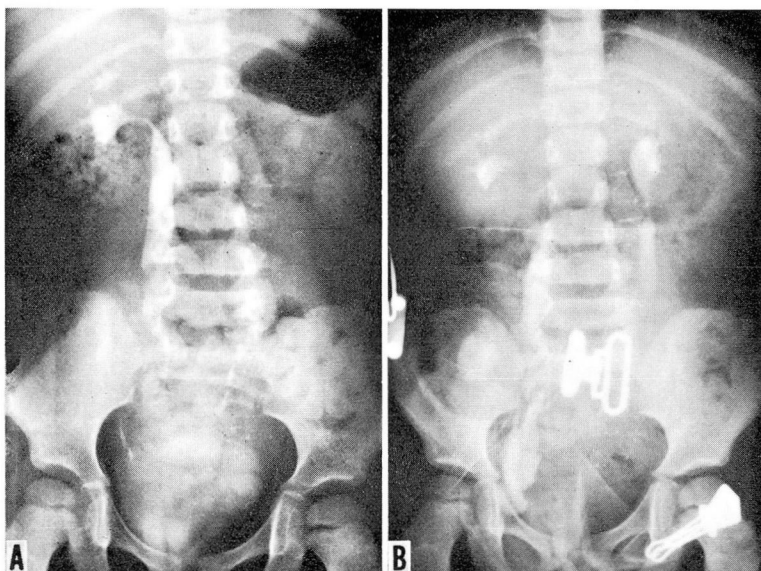


Fig. 2. A, intravenous pyelogram made before the construction of an ileal conduit in a child with hydronephrosis. B, postoperative intravenous pyelogram showing an improvement in the hydronephrosis.

Table 2.—Preoperative and postoperative blood urea and electrolyte determinations in 35 children with ileal conduits

Test	Preoperative value, number of patients			Postoperative value, number of patients		
	Normal	Increased	Decreased	Normal	Increased	Decreased
Blood urea	24	11	0	30	2	3
Serum chloride	29	6	0	25	7	2
Serum potassium	32	2	1	35	0	0
Plasma carbon dioxide	16	0	19	35	0	0

fever due to exacerbation of preexisting urinary tract infections. Superficial wound infections developed in two children, which responded to conservative therapy. Severe irritation of the peristomal skin occurred in only one child in the early postoperative period.

Late complications. Mechanical bowel obstruction occurred in only one child. This required a second laparotomy and was due to fibrous adhesions. Obstruction at the enteroenterostomy has not been a problem since utilizing the elliptic bowel anastomosis previously described.⁹

Nearly all children were maintained on long-term therapy for chronic urinary tract infection, with nitrofurantoin.* One child had repeated bouts of chills and fever postoperatively despite antibiotic therapy, and subsequently residual urine was found in the ileal segment. Surgical revision of the stoma promptly eliminated the obstructive lesion.

Two children had persistent purulent discharge from the bladder, which responded to irrigations with a solution of neomycin, and one patient failed to respond to conservative therapy and required a cystectomy. We have not performed a cystectomy routinely in the patient with a neurogenic bladder.

Numerous problems of rather important significance have occurred with the ileal stoma. These have included: (1) trauma to the ileostomy because of improper fitting of the appliance; (2) allergic reaction to rubber, producing a whitish membrane on the stoma, which is friable and bleeds easily; (3) peristomal skin irritation; (4) superimposed *Candida* infection that produces the characteristic "diaper rash"; (5) phosphate crystal deposition on the stoma, producing a grayish-white membrane; (6) burn of the stomal mucosa from a heat lamp used to treat irritation of the peristomal skin; (7) peristomal pseudoepitheliomatous hyperplasia produced by an improperly fitted mounting ring that exposed too much skin to a constant bath of urine; (8) erosion of the skin from excessive belt pressure, or from pulling off the appliance without dissolving the adhering cement with the cement remover; and (9) ileostomy dysfunction, requiring surgical revision of the stoma. The detailed management of these problems has been discussed in another paper.⁹

Discussion

Urinary diversion in children must provide for the long-term maintenance of the upper urinary tract in as nearly a normal state as possible, preventing recurrent infections and progressive renal deterioration. Our previous experience with ureterosigmoidostomy indicated that some children did extremely well, but in a larger portion hydronephrosis, chronic pyelonephritis, or electrolyte imbalances developed.^{10,11} Ureterosigmoidostomy has frequently been the preferred method of creating urinary diversion in the child with exstrophy of the bladder, but recently many attempts at primary closure of the bladder defect have been made with variable results.¹² There are a few scattered reports of success in obtaining a normally functioning bladder^{12,13} but, in our experience, in those children who are continent, hydronephrosis develops, and in the remainder, while a relatively normal upper urinary tract is maintained, degrees of incontinence persist. It is not a difficult problem to achieve closure of the bladder, but the formation of a urethral sphincter that functions in a physiologically normal manner is rarely attained.

We have utilized the ileal conduit in children with exstrophy of the bladder when primary bladder closure failed functionally, and in children who underwent

*Furadantin, Eaton Laboratories.

ureterosigmoidostomy that failed to maintain a normal upper urinary tract and resulted in renal deterioration. Persky, Levy, and Abbott¹⁴ have shown that the hyperchloremic acidosis occurring after ureterosigmoidostomy can be reversed by the formation of an ileal conduit. Drainage of the upper urinary tract is improved, and the incidence of recurrent sepsis due to urinary tract infection is reduced.

Obstructive lesions at the vesical neck or in the urethra, particularly in urethral valves, may produce severe hydronephrosis and renal insufficiency early in life. *Figure 3* demonstrates the upper urinary tract in an eight-month-old child with a urethral valve, who was examined because of constipation and a suspected diagnosis of congenital megacolon. During the initial evaluation the blood urea content was

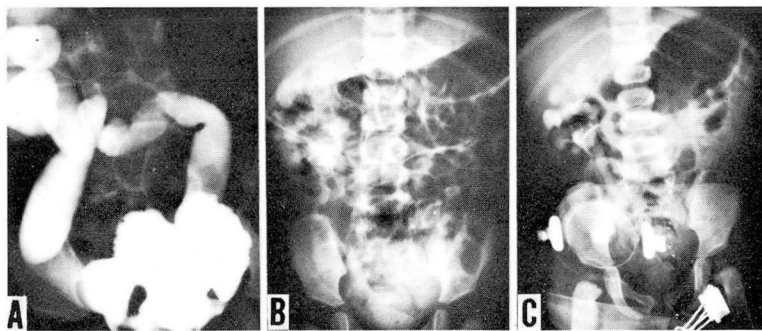


Fig. 3. A, voiding cystourethrogram demonstrating a urethral valve with severe hydronephrosis in an eight-month-old infant. B, preoperative intravenous pyelogram demonstrating severe hydronephrosis. C, postoperative intravenous pyelogram showing some improvement in the hydronephrosis.

found to be increased, which prompted further study of the urinary tract. Colon studies, as well as rectal biopsy, ruled out Hirschsprung's disease, but studies of the upper urinary tract revealed severe bilateral hydronephrosis. In this infant at nine months of age an ileal conduit was made; he is the youngest child in our series. This identical lesion was recently seen in a two-day-old infant, with an imperforate anus, who had some difficulty in voiding. This again shows that the urethral valve may produce severe damage to the upper urinary tract in utero, making primary correction of the obstructive lesion untenable in terms of salvaging the upper urinary tract.

We have studied these tortuous, dilated ureters at the time of voiding cystourethrography with cineradiography. The caliber of the ureter at the ureterovesical junction remains relatively normal, is widely patent, and allows reflux of urine. The ureter above this region is dilated, and peristaltic ureteral contractions may be seen to pass into the lower third of the ureter and then to reverse their direction to pass up the ureter. This results in ineffective emptying of the ureter because of a physiologic obstruction at the ureterovesical junction, much as suggested by Murnaghan.¹⁵ At the time of operation the entire ureterovesical junction is excised en bloc and is

studied histologically. The intravesical ureter has been found to be surrounded by fibrous connective tissue, which replaces the usual supporting musculature. We believe that it is secondary to chronic inflammation, and prevents dilation of this segment of the ureter, as well as interferes with the transmission of the peristaltic contraction wave down the ureter. This in turn produces the physiologic obstruction at the ureterovesical junction. In these children with severe hydronephrosis and hydroureters, we have utilized the ileal conduit with a shortening and straightening of the ureters to promote effective drainage and eliminate obstruction. The children have tolerated the operative procedure well, despite being uremic, and all have shown evidence of improvement by a decrease in the blood urea content and, or, the hydronephrosis. *Figure 4* is the roentgenogram of a child with a urethral valve and severe upper urinary tract damage that was managed successfully by urinary diversion into an ileal conduit.

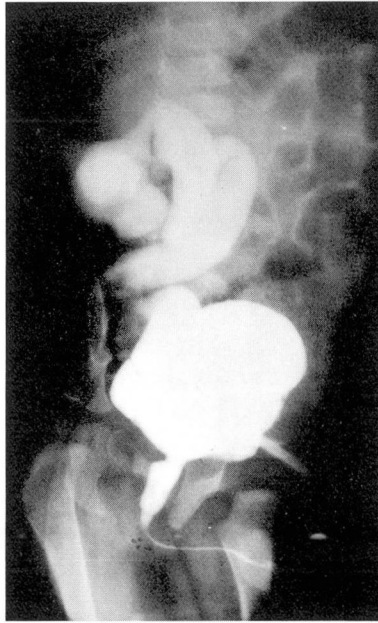


Fig. 4. Voiding cystourethrogram of a 12-year-old boy with severe upper urinary tract damage secondary to obstruction produced by a urethral valve.

The most frequent indication for an ileal conduit in children has been an autonomous neurogenic bladder with incontinence, and to date we have operated on 23 children who had this condition. The results obtained in 18 of these children have been reported previously.⁹

Children with either normal or mild dilatation of the upper urinary tracts have had the best results following the construction of an ileal conduit. Salvage of some badly damaged upper urinary tracts has been accomplished but, in general, little

improvement as evidenced on the intravenous pyelogram was obtained. Therefore, it seems important to do the diversion procedure before severe hydronephrosis develops, and this tenet is of particular importance applied in those children with neurogenic bladders. Too often the operative procedure is delayed, hoping that continence will be achieved along with growth, and in the interim renal deterioration occurs. We advocate early operation of these children, which is a more aggressive approach than heretofore presented.

At the present time we believe that the ileal conduit offers a satisfactory solution to the problem associated with a neurogenic bladder with incontinence, obstructive lesions with severe hydronephrosis and incontinence, and deterioration of renal function. It has also proved useful in children with exstrophy of the bladder in whom primary closure or ureterosigmoidostomy has failed. Continued periodic observation of each patient will be needed to determine the long-term response to this operative procedure.

References

1. Bricker, E. M.: Substitution for urinary bladder by use of isolated ileal segments. *S. Clin. North America* 36: 1117-1130, 1956.
2. Hodges, C. V.; Lehman, T. H.; Moore, R. J., and Loomis, R.: Use of ileal segments in urology. *J. Urol.* 85: 573-579, 1961.
3. Cordonnier, J. J., and Nicolai, C. H.: Evaluation of use of isolated segment of ileum as means of urinary diversion. *J. Urol.* 83: 834-838, 1960.
4. Parkhurst, E. C., and Leadbetter, W. F.: Report on 93 ileal loop urinary diversions. *J. Urol.* 83: 398-403, 1960.
5. Burnham, J. P., and Farrer, J.: Group experience with uretero-ileal-cutaneous anastomosis for urinary diversion: results and complications of isolated ileal conduit (Bricker procedure) in 96 patients. *J. Urol.* 83: 622-629, 1960.
6. Cordonnier, J. J.: Illeocystostomy for neurogenic bladder. *J. Urol.* 78: 605-610, 1957.
7. Lapides, J.; Ajemian, E. P., and Lichtwardt, J. R.: Cutaneous vesicostomy. *J. Urol.* 84: 609-614, 1960.
8. Cordonnier, J. J.: Ileocystostomy: followup evaluation of 14 cases. *J. Urol.* 87: 60-62, 1962.
9. Straffon, R. A.; Turnbull, R. B., Jr., and Mercer, R. D.: Ileal conduit in management of children with neurogenic lesions of bladder. *J. Urol.* 89: 198-206, 1963.
10. Jay, J. B.; Borski, A. A., and Kimbrough, J. C.: Substitute urinary bladder: review of literature and report of new indications for its use. *J. Urol.* 74: 109-117, 1955.
11. Ferris, D. O., and Odel, H. M.: Blood electrolyte pattern of blood after bilateral uretero-sigmoidostomy. *J.A.M.A.* 142: 634-640, 1950.
12. Lattimer, J. K.; Dean, A. L., Jr.; Dougherty, L. J.; Ju, D.; Ryder, C., and Uson, A.: Functional closure of bladder in children with exstrophy: report of twenty-eight cases. *J. Urol.* 83: 647-655, 1960.
13. Pierce, J.: Personal communication, April 1962.
14. Persky, L.; Levey, S., and Abbott, W. E.: Metabolic alterations following diversion of urine from colon to ileal loop. *J. Urol.* 79: 463-470, 1958.
15. Murnaghan, G. F.: Experimental aspects of hydronephrosis. *Brit. J. Urol.* 31: 370-376, 1959.