

## ECHOENCEPHALOGRAPHY: AN AID IN THE DIAGNOSIS OF INTRACRANIAL LESIONS

### Report of a Case

THOMAS M. TANK, M.D.,\* and WALLACE B. HAMBY, M.D.

*Department of Neurological Surgery*

**E**CHOENCEPHALOGRAPHY is a diagnostic procedure in which minute and harmless quantities of pulsed ultrasound are used to measure physical characteristics of the intracranial contents. It can detect slight changes in tissue density and elasticity such as those between white and gray matter, or those of interfaces between the ventricular wall and the ventricular fluid. However, its strongest and most easily recognized wave forms (echoes) come from midline brain structures, particularly the pineal body because of its calcium content.<sup>1</sup>

While in Sheffield, England, in June of 1962, one of us (T.M.T.) visiting with Mr. Anthony Jefferson, F.R.C.S., was introduced to echoencephalography and echoencephalographic technic. The intriguingly simple and harmless test could be done rapidly and repeatedly. Mr. Jefferson's machine was a converted industrial model. Since then, a highly versatile and specialized electronic ultrasound machine† (*Fig. 1*) has been designed which can measure with extreme accuracy the position of the pineal body with respect to the lateral walls of the skull. A 2.0 mm.- lateral dislocation of the pineal echo definitely indicates that a pathologic condition is causing the displacement.<sup>1</sup> An expanding supratentorial lesion shifts the pineal structure away from the midline so that the lesion is lateralized by the direction of the shift (*Fig. 2*). A double-exposed Polaroid photograph is taken of the oscilloscopic tracing to make a permanent record of readings from the right and then from the left side of the skull. The test is easily performed and the results are immediately available for interpretation.

The usefulness of this procedure in determining the occurrence and lateralization of a lesion is demonstrated in the case reported here. The test was particularly helpful in this instance because the patient's neurologic status did not suggest the presence of an intracranial lesion.

### Report of a Case

A 52-year-old white man, a physician, was admitted to the Cleveland Clinic Hospital as a patient of Dr. Guy H. Williams, Jr., Department of Neurology, and was examined on July 30, 1963, because of headaches of two months' duration. The headache, which was explosive over the vertex, initially was triggered by a sneeze. The headache subsided rapidly, but then recurred repeatedly when the patient sneezed violently. Ten days before examination the headache became constant, subsiding only when the patient would lie down. The patient had no recollection

\*Fellow in the Department of Neurological Surgery.

†Ekoline 20, Smith Kline—Precision Company.

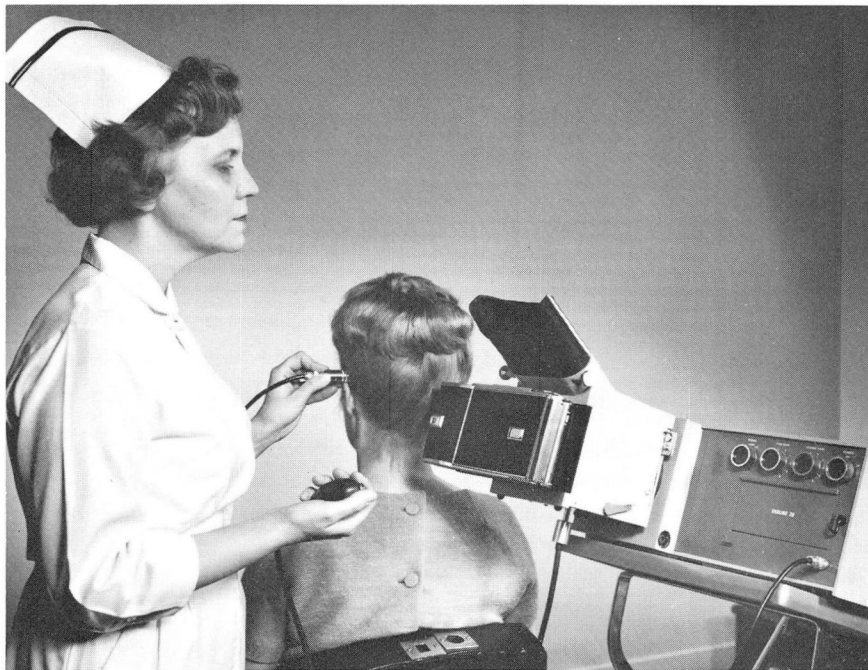

Fig. 1. Photograph showing the application of the transceiver probe of the Ekoline 20 unit to the skin over the ear, and the camera unit that photographs the oscilloscope tracing.

tion of a head injury. Two months previously he had had muffled hearing and tinnitus; examination by a specialist revealed fluid behind the ear drum.

*Neurologic examination.* We found no masses or tender areas about the scalp, and no evidence of rhinorrhea or otorrhea. Funduscopic examination showed scarring and pigmentation around both discs, indicating prior chorioretinitis. Headache was precipitated in the sitting position, was worsened by jugular compression, and was relieved by manually applied abdominal pressure. Lumbar puncture disclosed a spinal fluid pressure of 70 mm. and a clear colorless fluid. Findings on roentgen study of the skull were normal, and those on electroencephalography were interpreted as not remarkable. Analysis of cerebrospinal fluid showed a trace of globulin, 70 mg. of protein, no white blood cells, and 100 red blood cells per cubic millimeter. Blood urea content was 59 mg. per 100 ml., and acid phosphatase, 1.7 Bodansky units.

Our initial diagnosis after examination was postpuncture type of headache, probably caused by a tear in the arachnoid, which occurred when the patient sneezed. This condition would account for the low spinal fluid pressure. However, echoencephalography was performed and revealed a 7-mm. shift of the pineal echo to the right of the midline. On August 1, 1963, left carotid arteriography demonstrated evidence of a chronic subdural hematoma over the left parietal area. A left parietal trephine opening was made by Dr. W. James Gardner on the same day. More than 65 ml. of liquid hematoma was aspirated. Ringer's solution, 100 ml., was injected intrathecally by lumbar puncture to expand the collapsed cerebral hemisphere. In the evening after operation the patient was so alert that it was then realized that preoperatively his affect had been dulled. When again questioned about a blow to the head, he recalled that, some time after the initial sneezing episode, he had been bent over to examine the forefoot of one of his horses, and, as he dropped the foot and straightened up, the horse's head struck him a severe blow on the back of the head.

On the second preoperative day the patient began again to experience severe occipital headaches. Although echoencephalography showed an 8-mm. shift of the pineal echo to the right of

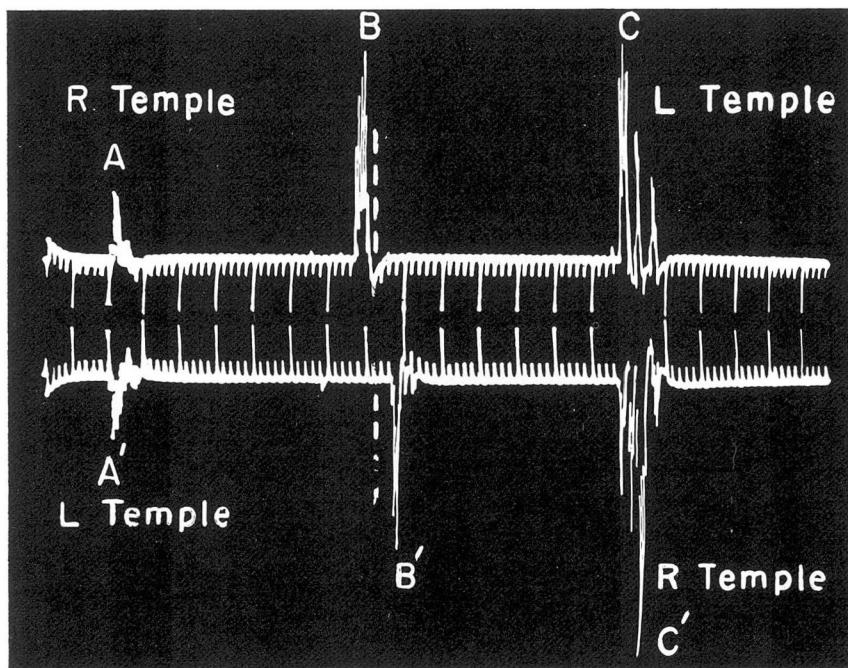


Fig. 2. Echoencephalogram tracing of August 17, 1963, the tenth postoperative day, rephotographed with increased exposure for clarity. In the upper tracing ABC: A, the right temple; B, the pineal echo; C, the group of echoes from the left temple. In the lower tracing A'B'C': A', the left temple; B', the pineal echo; C', the group of echoes from the right temple. AC or A'C' is 144 mm., the diameter of the skull. The midline (dashed line) is 72 mm.; AB is 67 mm.; and A'B' is 77 mm., showing that the pineal echo shifted 5 mm. from the midline toward the right temple in both tracings. The four closely placed echoes on the right side of the photograph represent the dural, inner skull table, outer skull table, and skin echoes, respectively. On the scale each large marker is 1 cm. and each small marker is 2 mm.

the midline, the patient still was alert. Two days later he suddenly became somnolent. The findings on neurologic examination were normal. A lumbar puncture disclosed a spinal fluid pressure of 125 mm. An intrathecal injection of Ringer's solution raised the spinal fluid pressure to 305 mm., but there was no change in somnolence. On August 7, 1963, six days after operation, bilateral carotid arteriography indicated the presence of a hematoma again over the left cerebral cortex. A generous left frontoparietal craniotomy was then performed by Doctor Gardner and a large quantity of dark liquid blood and solid black clot was evacuated. The underlying cerebral cortex appeared normal. The patient once more became alert, but on the day after operation was again deeply somnolent. Spinal fluid pressure was only 55 mm., indicating continued presence of intracranial hypotension. When 50 ml. of Ringer's solution was injected intrathecally, the blood pressure promptly fell from 220/110 to 140/90 mm. of Hg, and the patient became alert. It was necessary to repeat this procedure three more times, 5, 4, and 14 hours, respectively, after the initial injection to bring the patient out of stupor.

On August 9, 1963, two days after the second operation, the echoencephalogram showed a 7.5-mm. shift of the pineal echo to the right of the midline, and on August 14, 1963, an 8.5-mm. shift. Until August 15, 1963, the patient was dysphasic. Occasionally he had sensory seizures in the right hand. His somnolence subsided on August 17, 1963, when the echoencephalogram showed a 5-mm. shift (Fig. 2). On August 20, 1963, when his sensorium was clear, the shift of the pineal echo was 1.2 mm. He was discharged from the hospital on August 24, 1963, 17 days



after the second operation, and advised to take anticonvulsant medication. On January 6, 1964, four and one-half months after his discharge from the hospital, echoencephalography showed the pineal echo located exactly in the midline. At that time the patient was working full time without difficulty. His memory was excellent.

### Comment

Echoencephalography played a significant part in the handling of this case. The procedure involves no discomfort to the patient and, because of the maneuverability of the instrument, can be used as a bedside test. We have seen a number of cases now in which an echoencephalogram has furnished the only positive finding before carotid angiography was performed; echoencephalography provides a simple and useful screening test for patients suspected of having intracranial tumor. Although from the echoencephalogram one cannot differentiate among tumor, subdural hematoma, intracerebral clot, or cerebral edema after a cerebrovascular accident as the cause of the shift of the midline brain structures, absence of a shift rules out the presence of an expanding supratentorial mass. This negative information can be particularly useful in a patient in metabolic or drug-induced coma, especially when there is a concomitant history of head injury.

In retrospect, in regard to the case reported here, the pattern of the echoes indicated that the depth of the hematoma in the temporoparietal area just under the probe was 8 mm. before the first and 12 mm. before the second operation. In the future such tracings might permit the differentiation of hematomas from tumors and cerebral edema as the cause of a shift of the pineal body.

The finding of an increasing shift of the midline brain structures on successive postoperative echoencephalograms indicates the occurrence of postoperative hemorrhage or of progressive cerebral edema. It might also indicate the duration and extent of control of cerebral edema when using intravenous hypertonic solutions.

Echoencephalography can be performed on a person of any age. In the infant the diameter of the third ventricle can be measured; and after a shunting procedure for hydrocephalus, repeated echoencephalograms will show whether or not the hydrocephalus is progressive, arrested, or regressive. In addition, the pathophysiology of cerebral swelling in cases of subdural hematoma and cerebral contusion can be studied by echoencephalography. In the case reported here, the cerebral hemisphere did not expand until several weeks after the hematoma had been completely removed. In one of our subsequent patients who had cerebral contusion the midline structures were shifted 4 mm. for four days after the injury. The return of the pineal echo to the midline correlated well with resolution of the patient's neurologic deficit. Thus, it is not necessary to subject all patients having significant head trauma to cerebral angiography, a procedure that may add to the injury already present in a traumatized brain.

Summary

A case is reported here to illustrate the value of echoencephalography in the diagnosis of an intracranial lesion in a seriously ill patient in whom the neurologic status did not suggest the correct diagnosis. The procedure is safe, accurate, and can be used at the bedside without discomfort to the patient. There are several possible phases of future applicability of the test, such as the differentiation of hematomas from tumors, the diagnosis of postoperative hemorrhage or severe cerebral edema, the estimation of the physical status of hydrocephalus, and the study of the pathophysiology of cerebral swelling in subdural hematoma and cerebral contusion.

Reference

1. Jeppsson, S.: Echoencephalography. IV. Midline echo; evaluation of its usefulness for diagnosing intracranial expansivities and investigation into its sources. *Acta chir. scandinav. suppl.* 272: 1-151, 1961.