

Anterior transperitoneal operative approach to the kidney

BRUCE H. STEWART, M.D.

CLARENCE B. HEWITT, M.D.

WILLIAM S. KISER, M.D.

RALPH A. STRAFFON, M.D.

Department of Urology

MOST surgeons by tradition have exposed the kidney through a standard flank incision, resecting a rib or opening the chest when wider exposure was needed. The rationale of the retroperitoneal approach was sound, since many operations resulted in prolonged drainage of infected urine. However, with the advent of vascular surgery, it became apparent that adequate exposure of the renal vessels was often not possible through conventional flank incisions. Furthermore, the establishment of retroperitoneal drainage was not only unnecessary, but actually undesirable in revascularization procedures. As a result, the transabdominal transperitoneal approach to the kidney became popular.¹⁻³ With greater experience, this approach has become the procedure of choice in an increasing range of clinical conditions requiring surgical treatment.

This report represents in detail the merits of the anterior approach to the kidney, and outlines both the advantages and the limitations in specific clinical conditions.

The incision

The kidney can be exposed through one of many different anterior incisions. When exposure of only the renal vessels or pelvis is necessary, especially in slender patients, a standard subcostal incision usually is adequate. In obese patients, or when maximum exposure of the great vessels or of both kidneys is required, a bilateral subcostal incision^{4,5} will give excellent exposure (*Fig. 1A*). If there is a large tumor of the kidney or adrenal gland, the incision may be extended to include most of the eleventh rib, with the patient in a slightly oblique position, as recommended by Stewart and Meaney⁶ (*Fig. 1B*). A vertical midline incision from the xiphoid process to just below the umbilicus gives rapid access to the abdominal cavity, and is particularly useful in cases of renal trauma; it has also been used for bilateral nephrectomy in preparing patients for transplantation, when incisional

Presented at the American Medical Association Annual Meeting, San Francisco, California, June 16-20, 1968.

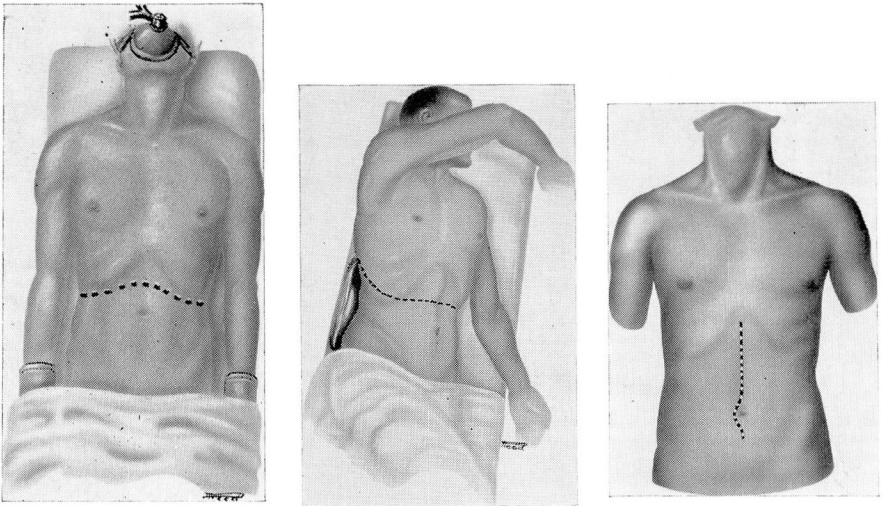


Fig. 1. A, When wide exposure of both kidneys, renal vasculature, or adrenal glands is necessary, a bilateral subcostal incision is usually preferable. B, Should a large or high-lying tumor be present, the incision may be extended to include the ipsilateral eleventh rib with the patient in the semioblique position. C, A vertical incision allows rapid entry into the abdominal cavity with minimal blood loss in patients who are poor operative risks. (A and B, courtesy of Stewart, B. H., and Meaney, T. F.: *Diagnosis and treatment of renal neoplasm—a fresh approach*. *Cleveland Clin. Quart.* 33: 45–57, April 1966; and the *Cleveland Clinic Quarterly*.)

bleeding must be kept to a minimum (*Fig. 1C*). In cases of renovascular disease or neoplasm, optimal exposure of the kidneys and adrenal glands is not so easily obtained with the midline approach.

Clinical indications

Renovascular disease. Most occlusive renovascular lesions are best exposed through a bilateral subcostal incision. The colon and the duodenum are mobilized and retracted medially, giving excellent exposure of both the inferior vena cava and the aorta and of the entire renal artery and vein. Atherosclerotic lesions usually involve the origin of the renal artery; complete control of the aorta is vital if adequate endarterectomy, reimplantation, or bypass grafting is to be performed. Many of the fibrous occlusive lesions affect a great length of the renal artery and require an aortorenal bypass graft. A subcostal incision that can be extended across the midline makes this a relatively easy task, even in heavy patients. Autogenous splenic arterial segments may be used for bypass grafting in selected patients, and bilateral renal biopsy performed when indicated, all through a single incision. The incision heals well, and rarely requires the use of retention sutures.

A few patients have fibrous lesions that are sufficiently well localized to

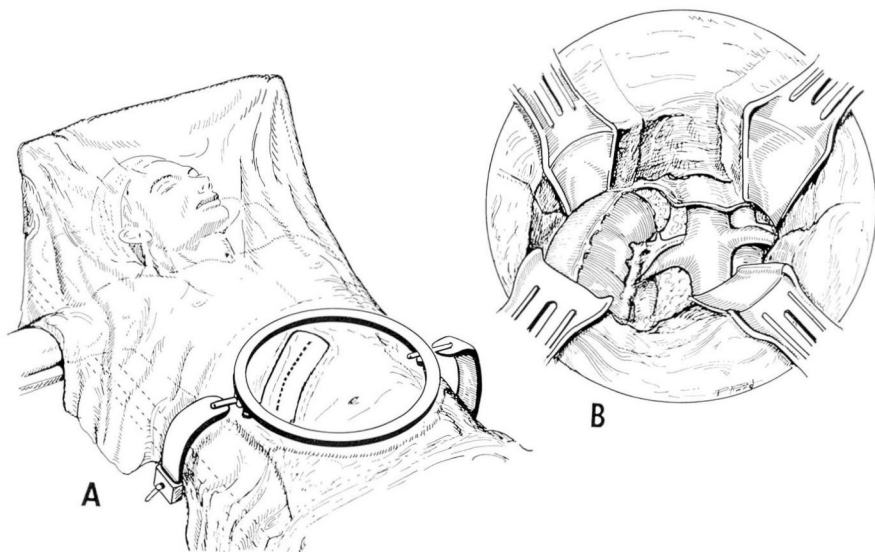


Fig. 2. A, After the abdominal incision is made, the circular Smith ring is placed over the patient and anchored to the table by curved armatures. B, Excellent and unchanging exposure of the kidney and its vasculature is obtained by multiple-angled retractors placed at intervals about the ring.

permit resection and reanastomosis; unless the patient is extremely obese, this can be easily accomplished through a unilateral subcostal incision.

Exposure of the kidney and its surrounding structures is greatly facilitated by the use of the Smith selective retractor.* After the incision is made and the posterior peritoneum opened to expose the kidney and its pedicle, the surgeon, assisted by a circulating nurse, attaches sterile curved armatures to each side of the operating table. The retractor ring is then centered over the incision and fixed to the armatures (*Fig. 2A*). Protective moist towels are placed over the liver, the duodenum, and the colon, and these structures are held out of the way by multiple retractors of various depths, which are suitably placed around the retaining ring, as described by Smith⁷ (*Fig. 2B*). The exposure is constantly maintained and is more than adequate, allowing any of the major operations upon the kidney and its vessels to be performed by the surgeon and only one assistant.

Renal carcinoma. Exposure of neoplastic kidneys by a conventional flank incision usually requires excessive manipulation of the kidney before the vascular pedicle is secured, increasing the risk of dissemination of tumor cells. Profuse bleeding from large collateral veins often occurs, and the bulky tumor mass may prevent adequate visualization of the renal artery and vein.

The anterior transperitoneal approach permits the surgeon to expose

* Commercially available from Codman and Shurtleff, Inc., Boston, Massachusetts.

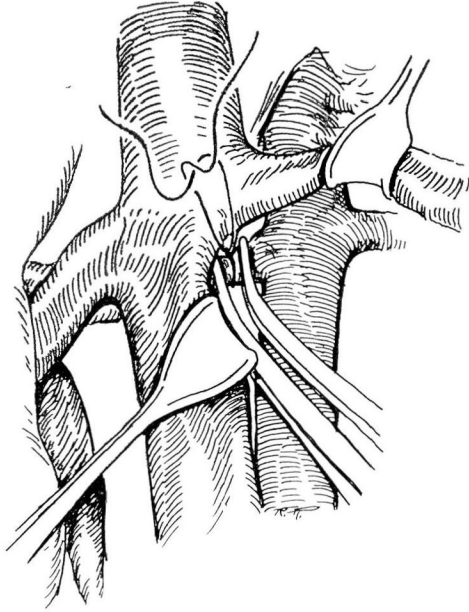


Fig. 3. In radical nephrectomy for cancer, the renal artery is isolated and divided *first*, before the tumor mass is manipulated.

and ligate the renal artery *first*, thus stopping all blood flow from renal and collateral veins before the tumor is manipulated (*Fig. 3*). The renal vein, the ureter, and the collateral vessels are then divided and the tumor mass is removed *en bloc*, preserving the peritoneal and fascial coverings of the kidney and avoiding exposure of the tumor itself. Preoperative establishment of a definitive diagnosis of renal cell carcinoma by means of selective renal angiography is considered essential in the management of renal mass lesions.⁸

A bilateral subcostal incision provides excellent exposure for the removal of most renal neoplasms. When the tumor is unusually large or is located in the upper pole of the kidney, the patient can be placed in a semioblique position and the eleventh rib resected. This gives wide exposure and allows even massive tumors to be removed without opening the chest. Once the vascular supply has been interrupted, resection of the neoplastic mass is usually not difficult, even when the diaphragm or psoas muscles are involved. Blood loss is usually minimal when the anterior approach is used, and transfusion is rarely required unless the patient is anemic before the operation.

When the inferior vena cava is invaded by neoplasm, the kidney and the tumor thrombus may be excised without excessive blood loss after partial occlusion of the vena cava and its tributaries by vascular clamps (*Fig. 4A and B*). A regional lymph node dissection extending to the crura of the

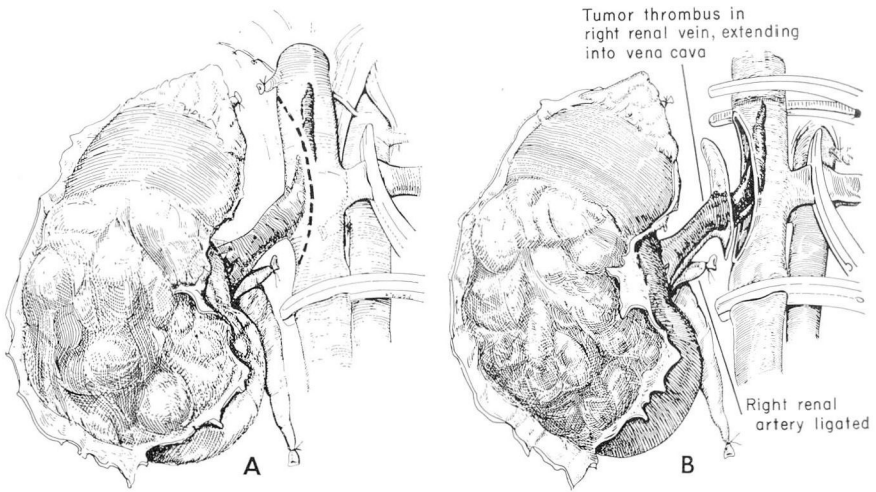


Fig. 4. A, When tumor thrombus extends from the renal vein into the vena cava, the cava and its tributaries are temporarily occluded with vascular clamps. B, The entire tumor mass is then removed, by opening the vena cava and extracting the thrombus under direct vision.

diaphragm can then be performed with ease (*Fig. 5*). Exploration of the opposite kidney is possible, particularly if there is angiographic evidence of contralateral disease. It is considered mandatory in all cases of Wilms' tumor, in which bilateral involvement is not uncommon and may be surgically correctable.

Pyeloplasty. When a conventional retroperitoneal flank approach is employed for pyeloplasty, the kidney must often be rotated out of its normal position, thus distorting normal anatomic relationships. Normal relationships are better maintained when the kidney is exposed through an anterior subcostal incision, allowing a meticulous repair to be done without risk of subsequent distortion when repositioning the kidney.⁹ Retroperitoneal tubes or drains can easily be brought out through the lateral abdominal wall, but care should be taken to close the posterior peritoneum in water-tight fashion after the repair.

Trauma. The anterior approach is preferable in most cases of renal trauma which require operative intervention. A vertical incision allows fairly rapid entry into the peritoneal cavity in these patients, who are often in poor condition from multiple injuries. Other abdominal viscera can be adequately examined and repaired when necessary, which is not possible through a conventional flank incision.

When the abdominal cavity is entered, the transverse colon is reflected upward and the small bowel to the right, exposing the posterior peritoneum. The posterior peritoneum is opened vertically between the base of the small-bowel mesentery and the inferior mesenteric vein; the duodenum is

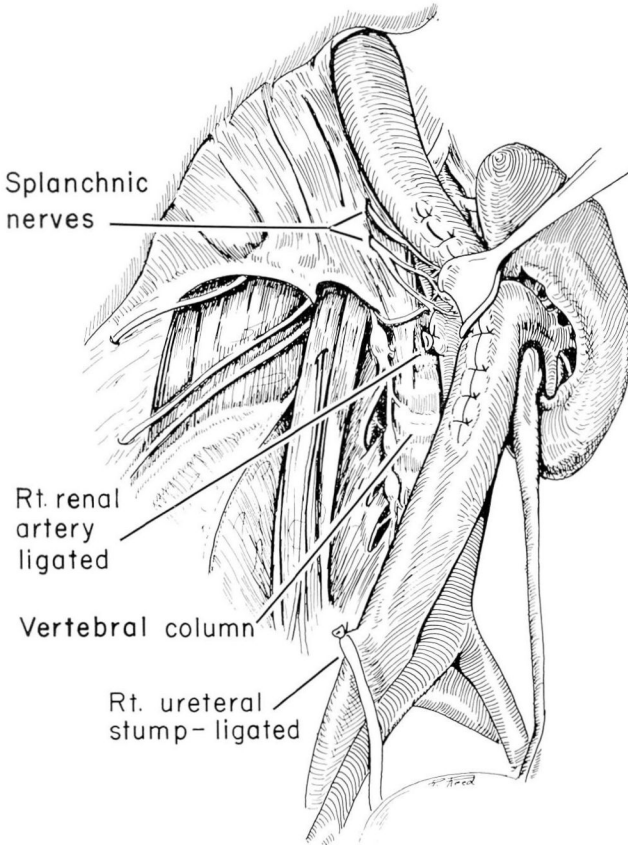


Fig. 5. Great vessels and retroperitoneal region after excision of tumor mass and lymph node dissection.

mobilized upward, exposing the renal artery that supplies the injured kidney. The renal artery is isolated and temporarily occluded with a vascular clamp. After bleeding from the kidney is thus controlled, the intestinal contents are repositioned to expose the kidney. The colon on the side of injury is reflected medially and Gerota's fascia is opened, allowing evacuation of the perinephric accumulation of blood clots and careful inspection of the kidney. Debridement, suture ligation of bleeding vessels, and repair of lacerations of the collecting system or capsule can be performed easily under direct vision. The vascular clamp on the renal artery prevents massive bleeding so often encountered when Gerota's fascia is opened, and allows the surgeon to salvage some kidneys that might otherwise be sacrificed because of uncontrollable hemorrhage. Retroperitoneal drains may be placed after repair, at the discretion of the surgeon.

Using this anterior approach in a large series of patients with renal

trauma, Scott and his associates^{10, 11} reported a significant increase in the percentage of kidneys salvaged. This aspect assumes even more importance when injury is sustained in patients with solitary kidneys.

Bilateral nephrectomy is usually necessary in the preparation of patients with chronic renal failure for transplantation.¹² A vertical incision is preferable, minimizing the blood loss from incised muscles that can be troublesome in uremic patients. Small incisions are made lateral to the colon on each side and the colon is reflected medially, exposing each kidney which can then be removed with a minimum of perirenal dissection. The single incision allows rapid removal of both of the kidneys and the spleen with less trauma in those patients who are considered to be poor operative risks. In selected patients, simultaneous bilateral nephrectomy, splenectomy, vagotomy, and pyloroplasty have been performed through this type of incision. In those patients, the midline vertical incision should be closed with retention sutures.

Upper ureters and retroperitoneum. The entire retroperitoneal region from above the renal vessels to the sacral promontory can easily be exposed through a vertical midline abdominal incision extending from the xiphoid process to just below the umbilicus. The transverse colon is reflected upward, the descending colon to the left, and the right colon and small intestines to the right, being protected by moistened folded towels. The posterior peritoneum is opened vertically between the duodenum and the inferior mesenteric vein, exposing the great vessels and both ureters. Retroperitoneal lymphadenectomy, transureteroureterostomy, or bilateral ureterolysis can be performed with ease through this single incision.^{13, 14}

The adrenals. Both adrenal glands can be exposed satisfactorily through a single bilateral subcostal incision. In a patient with a large adrenal tumor, resection of the ipsilateral eleventh rib, with the patient in a semioblique position, improves the exposure. Early control of the adrenal vascular supply is much easier from the anterior than from the conventional approach; this is especially useful in regard to pheochromocytomas, when prompt occlusion of the adrenal vein is important to prevent severe hypertensive crises. Evaluation of the contralateral adrenal gland and the retroperitoneal region is essential in the management of pheochromocytoma. A careful search of the entire abdominal cavity for metastases is important in all cases of adrenal malignant lesions. However, extremely obese patients with Cushing's disease, and many patients with small aldosterone tumors may be operated upon best through bilateral posterior incisions; resection of the eleventh or twelfth ribs with the patients in the prone position is performed by two operating teams.¹⁵

Limitations

The technic of the anterior approach to the kidney has limitations that preclude its use in some clinical situations. In most cases of infected hydro-

nephrosis, multiple calculi, or perinephric abscess, a conventional retroperitoneal approach through the flank is preferable. The anterior approach may be difficult in obese patients, whereas with these patients in the conventional flank position the retroperitoneal fat tends to fall forward and exposure of the kidney is relatively easy. Also, the anterior approach is not suitable in patients who have had numerous previous laparotomies and have extensive intraabdominal adhesions. In patients who have been operated on through anterior transperitoneal incision, adhesions and intestinal obstruction occasionally may develop, but this possible complication should not be a deterrent to its use considering the advantages of better exposure and reduction of blood loss in appropriately selected patients.

Summary and conclusions

Many operations upon the kidney can best be performed via an anterior transperitoneal approach. This gives excellent exposure of the aorta, the vena cava, and renal vessels, and it is therefore the method of choice for most renal revascularization procedures. This approach makes possible an effective radical nephrectomy for cancer, with isolation of the renal blood supply before the tumor is manipulated, and allows wide removal of the kidney and its surrounding structures with minimal blood loss. Anatomic relationships of the obstructed renal pelvis are better preserved during pyeloplastic procedures, and a high salvage rate of kidneys can be achieved in cases of renal trauma when the anterior approach is used. Excellent exposure of the adrenal glands and the retroperitoneum can in most cases be best attained through a single abdominal incision.

The use of a self-retaining ring retractor has greatly facilitated exposure in all instances, permitting even the most extensive procedures to be performed by the surgeon and one assistant.

References

1. Humphries, A. W., and Poutasse, E. F.: A technique of arterial grafting for renal artery stenosis causing hypertension. *Surg. Gynec. Obstet.* **105**: 764-765, 1957.
2. DeCamp, P. T., and Birchall, R.: Recognition and treatment of renal arterial stenosis associated with hypertension. *Surgery* **43**: 134-151, 1958.
3. Morris, G. C., Jr., and others: Surgical treatment of hypertension resulting from renal artery stenosis. *Amer. Surg.* **26**: 745-749, 1960.
4. Stewart, B. H., and others: Renal hypertension; an appraisal of diagnostic studies and of direct operative treatment. *Arch. Surg.* **85**: 617-635, 1962.
5. Chute, R.; Baron, J. A., Jr., and Olsson, C. A.: The transverse upper abdominal "chevron" incision in urological surgery. *J. Urol.* **99**: 528-532, 1968.
6. Stewart, B. H., and Meaney, T. F.: Diagnosis and treatment of renal neoplasm—a fresh approach. *Cleveland Clin. Quart.* **33**: 45-57, 1966.
7. Smith, D. P.: An anchored mechanical retractor. *Amer. J. Surg.* **83**: 717-720, 1952.
8. Meaney, T. F., and Stewart, B. H.: Selective renal angiography: an integral part of the management of renal mass lesions. *J. Urol.* **96**: 644-650, 1966.

9. Rolleston, G. L., and Reay, E. R.: The pelvi-ureteric junction. *Brit. J. Radiol.* **30**: 617-625, 1957.
10. Scott, R., Jr., and Selzman, H. M.: Complications of nephrectomy: review of 450 patients and a description of a modification of the transperitoneal approach. *Trans. Amer. Assn. Genitourin. Surg.* **57**: 49-54, 1965.
11. Scott, R., Jr.; Carlton, C. E., and Goldman, M.: Penetrating injuries of the kidney: an analysis of one hundred eighty-one patients. *J. Urol.* In press.
12. Straffon, R. A., and others: The use of ninety-four cadaveric kidneys for transplantation—clinical experience. *Brit. J. Urol.* **38**: 640-649, 1966.
13. Mallis, N., and Patton, J. F.: Transperitoneal bilateral lymphadenectomy in testis tumor. *J. Urol.* **80**: 501-503, 1958.
14. Hewitt, C. B., and others: Surgical treatment of retroperitoneal fibrosis. *Ann. Surg.* **169**: 610-615, 1969.
15. Nesbit, R. M.: Primary aldosteronism: its diagnosis and structural management. *J. Urol.* **97**: 404-408, 1967.