

# Colonic diverticulitis with perforation to region of left hip: a rare complication

## *Report of a case*

RICHARD G. FARMER, M.D.  
Department of Gastroenterology

FRANK L. WEAKLEY, M.D.  
Department of Colon and Rectal Surgery

HOWARD J. KLEIN, M.D.  
Department of Hospital Radiology

CHARLES M. EVARTS, M.D.  
Department of Orthopaedic Surgery

ONE of the most severe complications of diverticulitis of the sigmoid colon is perforation with fistula formation. The urinary bladder is the most common site of colonic diverticular fistulization because of its anatomic location. Other sites as possible targets for fistulas in diverticulitis are: bowel (enterocolic or colocolic fistula); adjacent integument (colocutaneous fistula); pelvic floor (ischorectal abscess or perianal fistula); or vagina (rectovaginal fistula).<sup>1</sup> In a study by Localio and Stahl<sup>2</sup> of 164 surgically treated cases of diverticulitis, fistulas from the sigmoid colon were reported to have developed in 10 patients. Asch and Markowitz,<sup>3</sup> reporting on 209 patients with diverticulitis in a 10-year period, found 23 with fistula formation (17 sigmoidovesical, 4 rectovaginal, 1 sigmoidocutaneous, and 1 sigmoidoretroperitoneal). Bolt and Hughes,<sup>4</sup> describing the follow-up study of 100 patients with diverticulitis, found that seven had fistulas to the bladder or vagina. Other authors<sup>5-8</sup> have commented on the rarity of fistulas elsewhere in the body and also on the rarity of "free" perforations of sigmoid diverticula.

Empysematous cellulitis of the thigh and hip rarely originates from an enteric fistula secondary to colonic diverticulitis. Four cases have been reported in which a perforated diverticulum resulted in a fistulous tract extending into the hip region.<sup>9-11</sup> Because of the rarity of this complication, we present the following case report.

### **Report of a case**

A 65-year-old man was transferred to the Cleveland Clinic Hospital on May 30, 1969, with a diagnosis of chronic diverticulitis of the sigmoid colon. He had first been hospitalized on May 12, 1969, because of a short history of nausea and vomiting after an insidious onset of symptoms in April 1969. During this time, he had weakness, anorexia, early

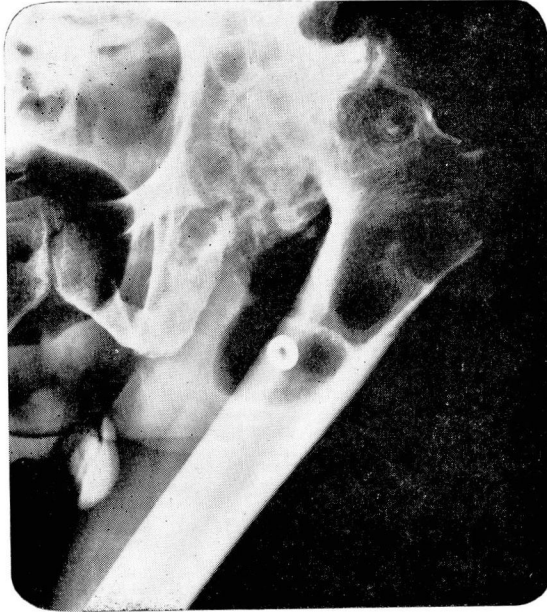

Fig. 1. Plain roentgenogram of the left hip. Note evidence of gas-filled area in region of proximal femur.

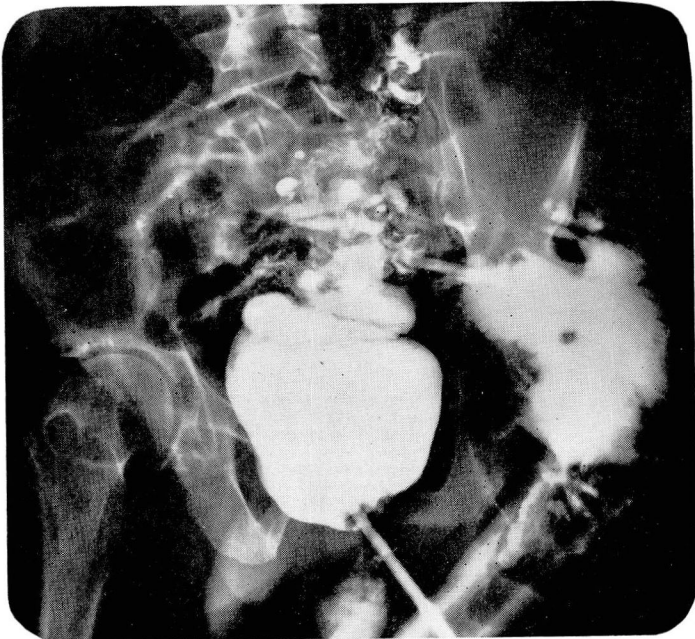


Fig. 2. Roentgenogram of the colon after barium enema, showing diverticulosis of sigmoid colon, with diverticulitis and fistula to region of the left hip.

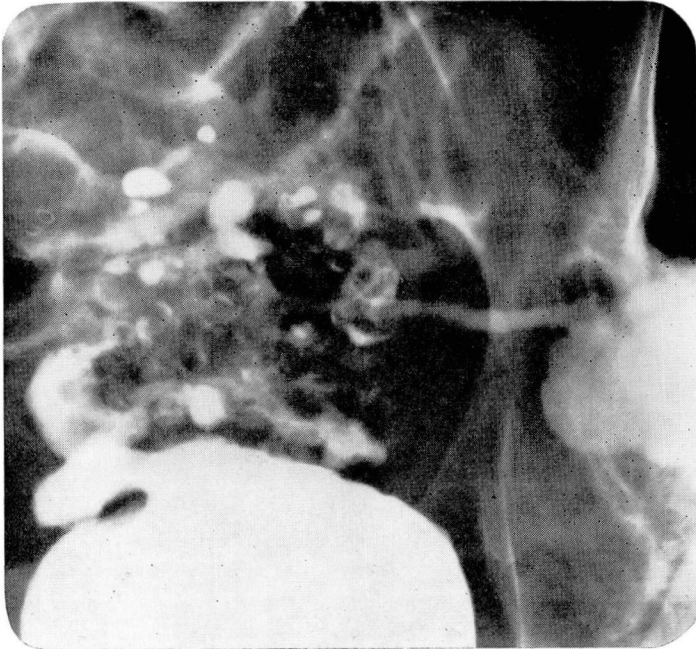


Fig. 3. Close-up of fistulous formation from perforated diverticulitis.

satiety, and had lost more than 30 pounds. He had not experienced a "change in bowel habits," and there was no history of gastrointestinal bleeding. There was no significant abdominal pain and there was no fever or dysuria. He was treated symptomatically, and had improved somewhat and was transferred to the Cleveland Clinic Hospital for further evaluation and therapy of diverticulitis.

In 1949 he underwent an abdominal operation for "an inflammation of the small bowel." Apparently a portion of the small intestine was removed. In 1964, an abscess was drained from the left lower quadrant of the abdomen (possibly a colocutaneous fistula). The patient stated that as a child he had a "deformity of the left hip" for which he underwent surgery at the age of 12 years. As a teenager he fractured his left hip and was placed in a cast. Subsequently a severe deformity of the left hip developed, with stiffness and shortening. After an injury in 1964, he experienced increased pain and further deformity of the left hip. There was no previous hip infection.

On physical examination he was emaciated and appeared chronically ill; he weighed 107 pounds. Ankylosis of the left hip was present in a position of adduction, flexion, and internal rotation. There was no abdominal distension or rebound tenderness. It was believed clinically that he had partial intestinal obstruction, on the basis of diverticulitis, or an internal hernia. Three days after hospitalization, crepitus was noted over the region of the left hip and buttock. There was also tenderness in the left lower quadrant of the abdomen; again there was no rebound tenderness or abdominal distension. There was no external evidence of a hernia. Proctoscopic examination was possible to 10 cm only, because of severe spasm; the mucosa was mildly edematous but no specific abnormalities were seen. A plain roentgenogram of the abdomen showed a collection of gas in the soft tissue in the region of the left hip and proximal femur (*Fig. 1*). A barium enema demonstrated a communication between the sigmoid colon and a cavity posterior to the left hip and proximal femur (*Fig. 2 and 3*). Another tract led into the right lower quadrant of the abdomen.

Because of the extensive perforative changes, laparotomy with sigmoid loop colostomy was performed on June 6, 1969. At that time, perforated sigmoid diverticulitis with a

chronic abscess on the left buttock was found. A chronic cavity containing barium and pus extended from the midline to the pericapsular region of the left hip, and from the top of the gluteus maximus muscle to the upper posterior part of the thigh. This large cavity was drained through multiple incisions which were used to accommodate several drains. Culture of the abscess cavity taken at the time of surgery revealed *Escherichia coli* and *Pseudomonas*.

Postoperatively the patient improved and was discharged from the hospital on June 14, 1969. He was readmitted to the hospital electively on September 5, 1969. On September 10, 1969, laparotomy was again performed with partial sigmoidectomy and closure of the rectum. Drains were placed in the pelvic cavity. Because of the extensive, chronic inflammatory process, a primary anastomosis was not made. The patient further improved and was discharged from the hospital on September 20, 1969.

On December 18, 1969, he was again admitted to the hospital, and the remainder of the sigmoid colon and upper part of the rectum were resected. The descending colostomy was taken down, a colorectal anastomosis was made, and a transverse loop colostomy was constructed. Pelvic drains were again placed. On May 25, 1970, the transverse colostomy was closed.

### Comment and conclusion

Fistula formation following perforation of diverticulitis of the sigmoid colon is a serious but relatively unusual complication of diverticulitis of the colon. Symptoms may be insidious in onset, and largely referable to the development of a chronic abscess. The puzzling features of this particular case were the rather rapid development of an obviously severe disease, the confusing history of "ileitis," and the preexisting injury to the left hip with resultant posttraumatic arthritic changes and ankylosis. The initial roentgenogram of the abdomen demonstrating a collection of gas in the soft tissue in the region of the left hip led to a differential diagnosis of herniation of air-filled intestine, abscess with gas-forming bacteria, subcutaneous emphysema, or intestinal perforation with a fistulous communication. Radiographic examination of the gastrointestinal tract is imperative in such a case to ascertain by which mechanism the air has reached the soft tissue. In this case, the roentgenogram of the colon after barium enema was diagnostic, and it also outlined the fistulous tract for definitive treatment.

We believe that it is important to be aware of the unusual features of perforation of sigmoid diverticulitis when it extends into structures not usually affected.

### Addendum

Since submission of this manuscript for publication, Ward and associates have reported, in a study of colovesical fistulas, a case similar to ours with a fistulous tract into the region of the left hip. (Ward, J. N.; Lavengood, R. W., Jr.; Nay, H. R., and Draper, J. W.: Diagnosis and treatment of colovesical fistulas. *Surg. Gynec. Obstet.* 130: 1082-1090, June 1970.)

### References

1. Bockus, H. L. (editor): *Gastroenterology*, 2d ed., Vol. 2. Philadelphia: W. B. Saunders Co., 1964, 1241 p.; p. 934.



2. Localio, S. A., and Stahl, W. M.: Diverticular Disease of the Alimentary Tract. Part I: The Colon, p. 53-56, in *Current Problems in Surgery*. Chicago: Yearbook Medical Publishers, 1967, 78 p.
3. Asch, M. J., and Markowitz, A. M.: Diverticulitis coli: a surgical appraisal. *Surgery* **62**: 239-247, 1967.
4. Bolt, D. E., and Hughes, L. E.: Diverticulitis: a follow-up of 100 cases. *Brit. Med. J.* **1**: 1205-1209, 1966.
5. Belding, H. H., III: Acute perforated diverticulitis of the sigmoid colon with generalized peritonitis. *A.M.A. Arch. Surg.* **74**: 511-515, 1957.
6. Fleischner, F. G., and Ming, S. C.: Revised concepts on diverticular disease of the colon; II. So-called diverticulitis: diverticular sigmoiditis and perisigmoiditis; diverticular abscess, fistula, and frank peritonitis. *Radiology* **84**: 599-609, 1965.
7. Colcock, B. P.: Indications for surgery in diverticulitis. *Surg. Clin. N. Amer.* **44**: 785-790, 1964.
8. Kroening, P. M.: Sigmoido-ileal fistulas as a complication of diverticulitis. *Amer. J. Roentgen.* **96**: 323-325, 1966.
9. Linscheid, R. L.; Kelly, P. J., and Symmonds, R. E.: Emphysematous cellulitis of the hip and thigh resulting from enteric fistula. *J. Bone Joint Surg.* **45-A**: 1691-1697, 1963.
10. Barrington, F. J. F., and Gardham, A. J.: Diverticulitis of the large intestine. *Clin. J.* **61**: 337-343, 1932.
11. Dawson, R. L. G., and Hardy, R. H.: Diverticulitis presenting as emphysematous cellulitis of leg; clinical report on two cases. *Brit. Med. J.* **1**: 498-499, 1948.