

# Enlargement of the sella turcica secondary to juvenile myxedema

## Report of a case

KAY F. McFARLAND, M.D.

O. PETER SCHUMACHER, M.D., PH.D.

Department of Endocrinology

**A** FREQUENT presenting sign of hypothyroidism in children is short stature. Failure to grow may be a manifestation of hypothyroidism due to pituitary malfunction or to primary thyroid failure. This differentiation is of prime importance before appropriate therapy can be initiated. This paper presents a case of enlargement of the sella turcica in a child of short stature. After the diagnosis of primary juvenile myxedema was made, thyroid replacement therapy was begun and the size of the sella turcica decreased to normal.

## Report of a case

A 9¾-year-old girl was first examined at the Cleveland Clinic in March 1966 because of short stature. She weighed between 7 and 8 lb. at birth. Weight and height values were not available for the years before 1966, but she had been short for several years and had worn the same size dress for three years prior to 1966. There was no family history of exceptionally short stature.

She had sat alone at eight months and had walked at 18 months. After that her development had been slower than average. She was described as a quiet and shy child with slow movements. Despite increased emotional lability, she was an A student. Since infancy she had had a problem with constipation, which had been controlled with diet. Her skin had always been quite dry. Her medical history and review of systems were otherwise non-contributory.

On physical examination the blood pressure was 80/60 mm Hg, height 46 in., weight 56 lb., and temperature 98.2F. The results of the examination were unremarkable except for the short stature and dry skin. The patient's dental age was approximately equal to the chronological age or slightly less.

The initial laboratory studies showed a protein-bound iodine (PBI) of 2.5 µg per 100 ml, triiodothyronine red cell uptake of 12.6 percent, total cholesterol of 440 mg per 100 ml, and a serum carotene content of 380 µg per 100 ml. Thyroglobulin antibody test was negative. The hemoglobin was 12.6 g per 100 ml, cell volume 36 percent, and white cell count 4,300 per c mm. The electrolytes were normal except for a decrease in the carbon dioxide which was 17.5 meq per liter. The sedimentation rate, VDRL, urinalysis, and serum alkaline phosphatase value were all normal. The urinary 17-ketosteroid and the 17-hydroxycorticoid values were as follows:

|                                  | 17-ketosteroids<br>mg/24 hr | 17-hydroxycorti-<br>coids mg/24 hr |
|----------------------------------|-----------------------------|------------------------------------|
| Baseline                         | 1.3                         | 1.3                                |
| First day of Metopirone          | 2.2                         | 4.3                                |
| Day after Metopirone             | 2.3                         | 2.9                                |
| After adrenocorticotropin (ACTH) | 3.6                         | 4.6                                |

Two and one-half units of regular insulin was given intravenously and the blood sugar values after this were as follows: 35 mg per 100 ml at 30 minutes, 72 mg at 60 minutes, and 86 mg at 90 minutes. Growth hormone levels were 13.5  $\mu\text{g}$  per ml at 60 minutes and less than 0.4  $\mu\text{g}$  per ml at 90 minutes. The high value of the growth hormone after insulin-induced hypoglycemia was indicative of a normal response. Gonadotrophins were  $>13$  and  $<105$  mouse units in 24 hr.

On a buccal smear, 10 of 100 cells exhibited sex chromatin mass and the chromosome analysis revealed a 46 XX pattern.

Bone age was four years and three months. A roentgenogram of the skull showed a large sella turcica (*Fig. 1*). Visual fields were normal.

To further document the etiology of the hypothyroidism, a thyroid-stimulating hormone (TSH) test was done. No increase of  $^{131}\text{I}$  uptake by the thyroid after intramuscular administration of 5 units of TSH was found. This test was repeated after three doses of TSH, again with a complete lack of response, indicating that the hypothyroidism was due to primary thyroid failure.<sup>1</sup>

In April 1969, a course of desiccated thyroid, 32 mg daily, was begun and the dose was gradually increased to 120 mg daily in two months. Within two months a notable increase in activity and an improvement of the appetite were noted. Seven months after treatment was initiated a striking change in personality was evident and there was less dryness of the skin and decreased constipation.

Height and weight measurements were as follows:

| Date          | Age, yr           | Height, in.      | Weight, lb |
|---------------|-------------------|------------------|------------|
| March 1966    | 9 $\frac{1}{12}$  | 46 $\frac{1}{4}$ | 56         |
| June 1966     | 9 $\frac{7}{12}$  | 46 $\frac{1}{4}$ | 53         |
| November 1966 | 10                | 48 $\frac{3}{8}$ | 53         |
| August 1967   | 10 $\frac{8}{12}$ | 52 $\frac{1}{4}$ | 64         |
| July 1968     | 11 $\frac{8}{12}$ | 55 $\frac{1}{2}$ | 79         |
| June 1969     | 12 $\frac{7}{12}$ | 58 $\frac{3}{4}$ | 90         |
| July 1970     | 13 $\frac{3}{12}$ | 61               | 101        |

On November 11, 1966, the roentgenogram of the skull showed a slight decrease in the size of the sella turcica as compared with the roentgenogram of April 6, 1966, and by August 11, 1967, the size of the sella turcica was normal. The bone age on November 11, 1966, was approximately six years (chronological age 10 years) and by August 11, 1967, was approximately 10 years with a chronological age of 10 $\frac{2}{3}$  years. In August 1970, bone age was normal. Menses began in December 1970. At this time the urinary 17-hydroxycorticoid values were as follows:

|                         | urinary 17-hydroxycorticoids |
|-------------------------|------------------------------|
| Baseline                | 3.0 mg/24 hr                 |
| First day of Metopirone | 4.2 mg/24 hr                 |
| Day after Metopirone    | 7.7 mg/24 hr                 |

## Discussion

The diagnosis of hypothyroidism was obvious in the child from the initial evaluation because of the short stature, dry skin, low PBI, low triiodothyronine red cell uptake, and elevated cholesterol and carotene levels. However, the etiology was not apparent. The initial roentgenogram of the skull was suggestive of an intrasellar tumor, that in turn raised the question of thyroid failure secondary to pituitary failure.

Further testing, however, indicated that the pituitary function was normal. Growth hormone secretion was stimulated by insulin-induced hypoglycemia, which is an indication of normal pituitary response to stress.

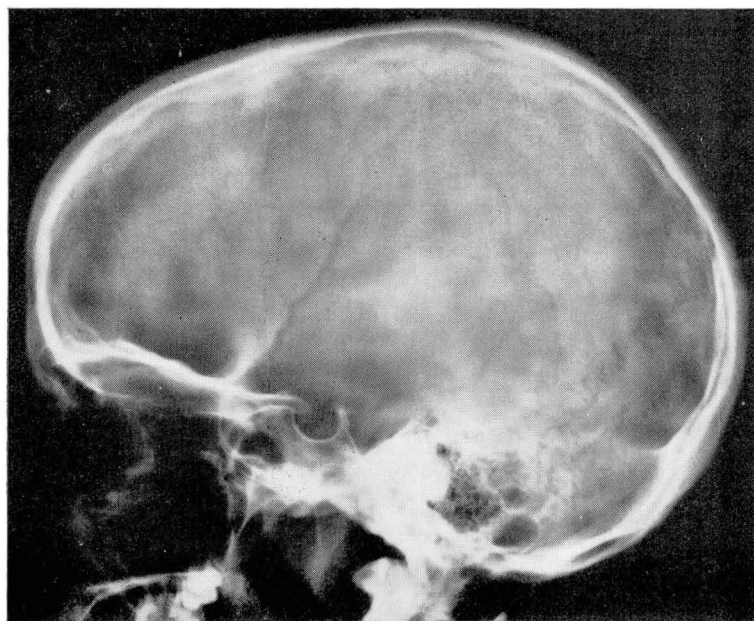
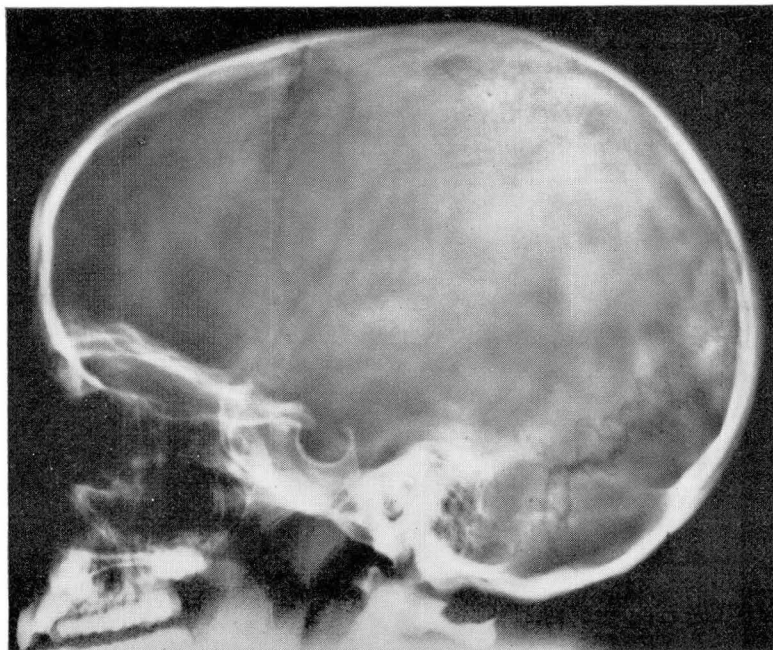


Fig. 1. A, *upper*, Roentgenogram of skull in 1966 showing enlarged sella. B, *lower*, Roentgenogram of skull in 1970 showing normal sella.

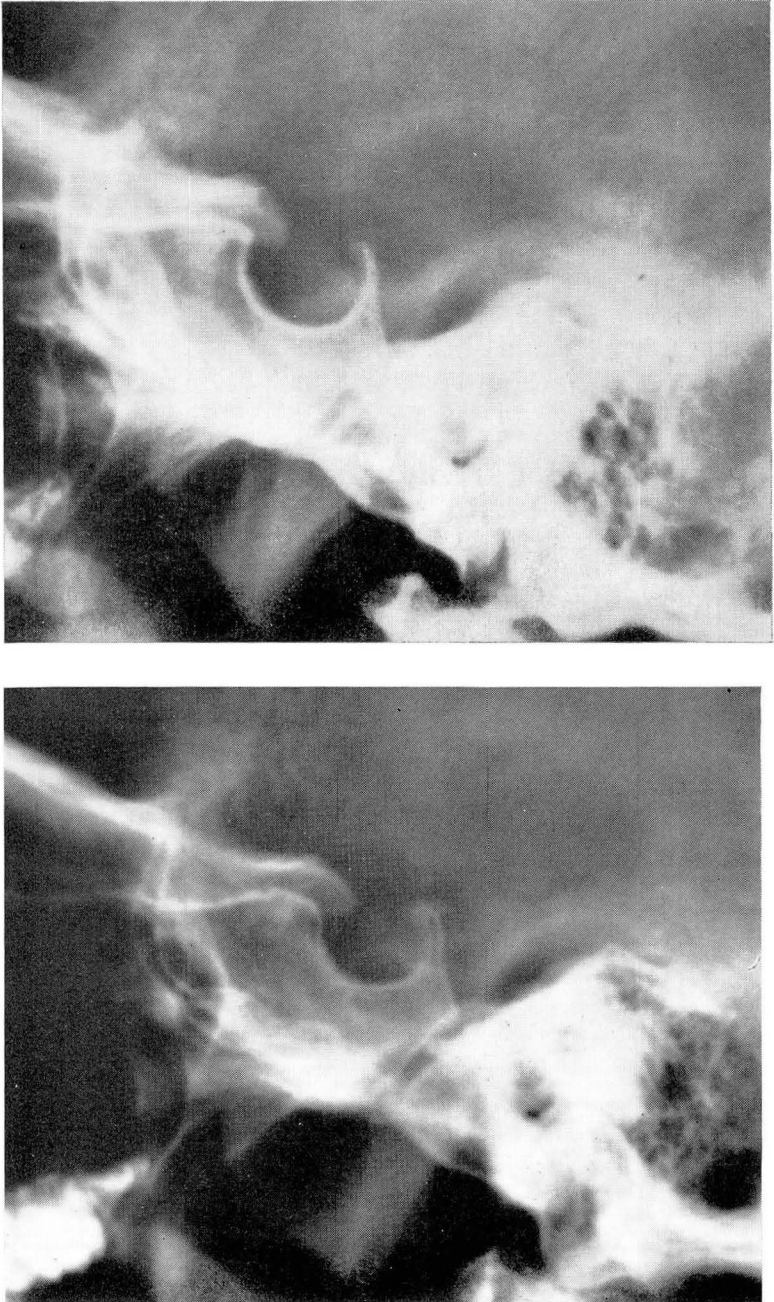


Fig. 2. Roentgenograms of sella turcica showing progression from enlarged sella in 1966 to normal sella in 1970. A, *upper left*, 4-6-66. B, *lower left*, 11-11-66. C, *upper right*, 8-10-67, D, *lower right*, 7-1-70.

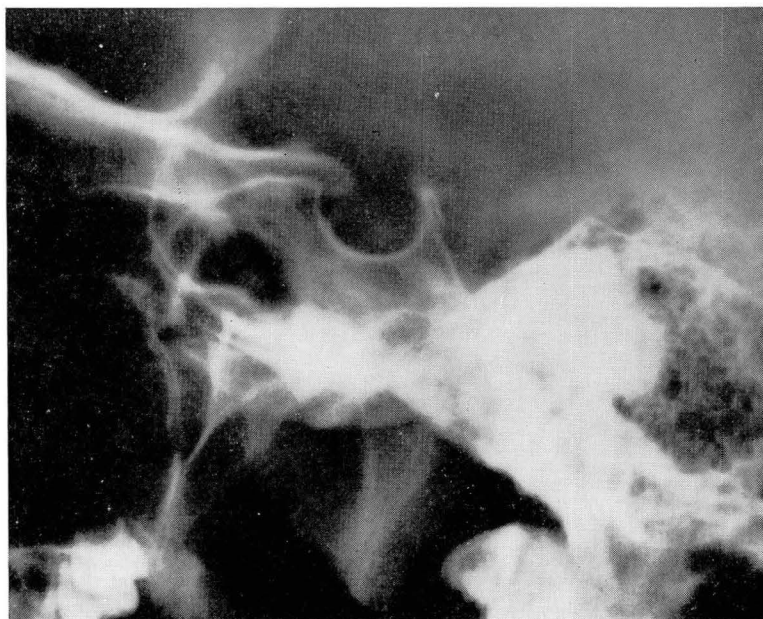
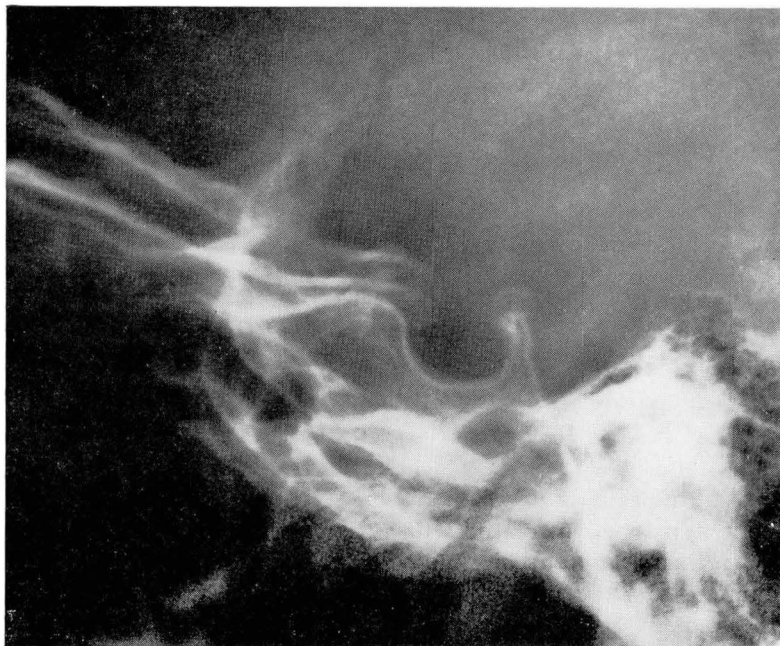
FIG. 2C and D.

Gonadotrophin levels also were normal. Poor and delayed responses as well as a normal response to Metopirone in cases of hypothyroidism have been reported by Brownie and Sprunt<sup>2</sup> and do not indicate low corticotropin reserve. The twofold increase of urinary 17-ketosteroids and hydroxycorticoids on the day of administration of Metopirone in this case was normal. The day after the administration of Metopirone the hydroxycorticoid values were low, which is indicative of a poor response.

The radiographic evidence of sellar enlargement, therefore, was considered due to primary hypothyroidism, which has been described<sup>3</sup> but still is not widely known. After therapy with desiccated thyroid, the sella turcica decreased in size to within normal limits (*Fig. 2*).

Evidence of pituitary enlargement in cases of long-standing myxedema was reported in 1892.<sup>4</sup> Hyperplasia and an increased number of the thyrotropin-secreting cells of the pituitary have been found by several investigators<sup>5, 6</sup> to be secondary to thyroid hormone deficiency. Chromophobe adenomas of the pituitary after thyroxin deficiency also have been reported.<sup>7</sup>

Although enlargement of the sella turcica is not demonstrated in many cases of primary hypothyroidism, plasma levels of TSH determined by radioimmunoassay are increased in most cases of myxedema.<sup>8</sup> More than 10 cases of precocious menstruation and/or galactorrhea also have been associated with hypothyroidism.<sup>9</sup> This association suggests that there may be an increased secretion of several hormones in addition to TSH. The phenomenon has been referred to as hormonal overlap, or the pituitary overflow syndrome. Van Wyk and Grumbach<sup>10</sup> have suggested that the overlap may be at the cellular level in the pituitary or may occur at the hypothalamic level.

One may conclude, therefore, that sellar enlargement associated with hypothyroidism may be caused by primary thyroid deficiency, as well as by a pituitary tumor that causes secondary thyroid failure.

## Summary

A case of enlargement of the sella turcica secondary to juvenile myxedema is reported, emphasizing the difficulties in differential diagnosis. Although one can obtain clues as to the correct diagnosis of the problem on the initial examination and evaluation, the final resolution of the problem can be made only with careful follow-up study.

## References

1. Taunton, O. D.; McDaniel, H. G., and Pittman, J. A., Jr.: Standardization of TSH testing. *J. Clin. Endocrinol.* 25: 266-277, 1965.
2. Brownie, A. C., and Sprunt, J. G.: Metopirone in the assessment of pituitary-adrenal function. *Lancet* I: 773-778, 1962.
3. Bellini, M. A., and Neves, I.: The skull in childhood myxedema: its roentgen appearance. *Am. J. Roentgenol. Radium Ther. Nucl. Med.* 76: 495-498, 1956.
4. Boyce, R., and Beadles, C. F.: Enlargement of the hypophysis cerebri in myxedema; with

- remarks upon hypertrophy of the hypophysis, associated with changes in the thyroid body. *J. Path. Bact.* **1**: 223-239, 1892.
5. Purves, H. D., and Griesbach, W. E.: Pituitary cytology in relation to thyrotrophic hormone secretion. *Ciba Foundation Colloquia on Endocrinology* **10**: 51-58, 1957.
  6. Russfield, A. B.: Histology of the human hypophysis in thyroid disease. *J. Clin. Endocrinol.* **15**: 1393-1408, 1955.
  7. Furth, J.; Dent, J. N.; Burnett, W. T., and Gadsden, E. L.: The mechanism of induction and the characteristics of pituitary tumors induced by thyroidectomy. *J. Clin. Endocrinol.* **15**: 81-97, 1955.
  8. Utiger, R. D.: Radioimmunoassay of human plasma thyrotrophin. *J. Clin. Invest.* **44**: 1277-1286, 1965.
  9. Jenkins, M. E.: Precocious menstruation in hypothyroidism. *Am. J. Dis. Child.* **109**: 252-254, 1965.
  10. Van Wyk, J. J., and Grumbach, M. M.: Syndrome of precocious menstruation and galactorrhea in juvenile hypothyroidism: an example of hormonal overlap in pituitary feedback. *J. Pediatr.* **57**: 416-435, 1960.