

Heavy chain disease

Report of a case

William M. Murphy, M.D.*
Sharad D. Deodhar, M.D.,
Ph.D.

Department of Immunology

John D. Battle, Jr., M.D.

*Department of Hematology and
Medical Oncology*

In 1963 and 1964, Franklin^{1, 2} reported the first case of a rare disorder of immunoglobulin metabolism characterized clinically by a generalized lymphadenopathy, recurrent respiratory infections, hepatosplenomegaly, and intermittent proteinuria. The serum and urine had increased amounts of protein corresponding to the heavy chain fragment of IgG \dagger , and this disorder was named "heavy chain disease." Since then 15 cases have been reported.³⁻⁵ We are reporting another case of IgG heavy chain disease which has certain unusual features.

Case Report

A 42-year-old Negro man was first seen at the Cleveland Clinic in July 1969. Five years before he had experienced shortness of breath and a "swelling" in the left side of the neck. A diagnosis of malignant lymphoma was made from a lymph node biopsy. He received several courses of cyclophosphamide and x-ray therapy during the next few years and was essentially asymptomatic when referred for further evaluation and treatment.

* Present address: Naval Hospital, 8750 Mountain Boulevard, Oakland, California 94627.

\dagger IgG—immunoglobulin G; intact molecules composed of two light chains (κ or λ type) and two heavy chains (γ).

On physical examination the patient was an obese, well-developed man in no acute distress and with normal vital signs. The cervical, axillary, submandibular, and supraclavicular lymph nodes were greatly enlarged, varying from 2 to 8 cm in greatest dimension. They were nontender, slightly firm, and matted. The liver was slightly enlarged. The remainder of the physical examination was unremarkable.

Laboratory studies. Results of pertinent laboratory studies are listed in *Table 1*. Lymphocyte transformation to phytohemagglutinin (PHA) was 9% (normal 50–80%), indicating an impaired cellular immune system. A bone marrow smear contained 34% mature and 4% immature plasma cells, and 2% plasmablasts. X-ray films of the chest, sinuses, skull, abdomen, and spine showed no bony lesions. A supraclavicular lymph node biopsy was performed, and the slides from the original biopsy were reviewed. The diagnosis of lymphocytic lymphoma was confirmed (*Fig. 1*). Examination by electron microscopy re-

vealed increased ribosomes in the tumor cells indicating increased protein synthesis (*Fig. 2A, 2B*).

Clinical course. After initial evaluation in July 1969, the patient was treated with prednisone. Vincristine sulfate was added in August 1969 and given until October, at which time cyclophosphamide was substituted. In April 1970 he was readmitted with a rectal abscess. At that time corticosteroid-induced diabetes mellitus was diagnosed. Chlorambucil and tolbutamide were added to the treatment regimen. In July 1970 x-ray films showed large abdominal lymph nodes. Only slight fluctuations in the size of the peripheral lymph nodes had occurred, and there was no change in his clinical condition. He was again admitted in October 1970 with an episode of cyclophosphamide-induced cystitis. At that time a complete immunologic evaluation, including examination of the serum obtained in July 1969 was performed (*Table 2*), and a heavy chain fragment was identified in the serum and urine. This protein had a different mobility from

Table 1.—Laboratory studies

	July 1969	October 1970	April 1971
Hgb (g/100 ml)	7.3	9.9	9.3
WBC/cu mm	2700	6000	18,700
Neutrophils (%)	23	32	31
Lymphocytes (%)	48	41	16
Monocytes* (%)	23	24	36
Platelets/cu mm	180,000	135,000	Normal
BUN (mg/100 ml)	9	21	14
Creatinine (mg/100 ml)		1.0	1.1
Bence Jones test	Negative	Negative	
Serum protein electrophoresis	Broad increase in γ region	Broad increase in γ region	
Urinary protein	Trace	3+	0.97 g/100 ml
Cryoglobulin	Negative		
Cold agglutinin	Negative		

* A few atypical cells were observed.

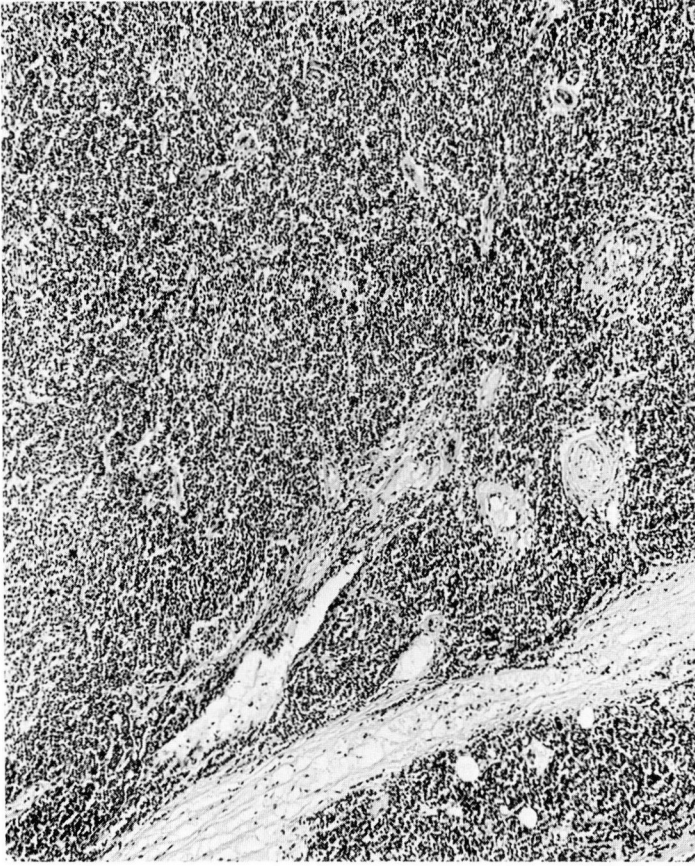

Fig. 1. Histology of a supraclavicular lymph node. Normal architecture of the lymph node is replaced by a uniform population of lymphocytes which infiltrate through the capsule into the surrounding adipose tissue. Hematoxylin and eosin, $\times 80$.

IgG and reacted with antisera specific for IgG and Fc* fragment, but did not react to κ , λ , Fab κ or Fab λ † antisera (Fig. 3). Immuno-electrophoretic comparison with whole human serum indicated an α -globulin mobility. A repeat lymphocyte transformation to PHA was 39%. The urine continued to contain a heavy chain fragment.

* Fc—crystallizable fragment of IgG after papain digestion; composed of fragments of the two heavy chains.

† Fab (κ or λ)—antigen-binding fragment(s) of IgG after papain digestion; composed of portions of both light and heavy chains.

The patient spent most of the remaining 7 months of his life in the hospital with recurrent prostatic, periprostatic, and pelvic abscesses. The patient died with clinical evidence of septicemia. An autopsy was not performed.

Discussion

Heavy chain disease is a rare, although not unexpected, aberration of IgG synthesis, in which an excess of heavy chains or portions thereof are produced and secreted into the circulation. The cells responsible for this abnormal protein usually appear as

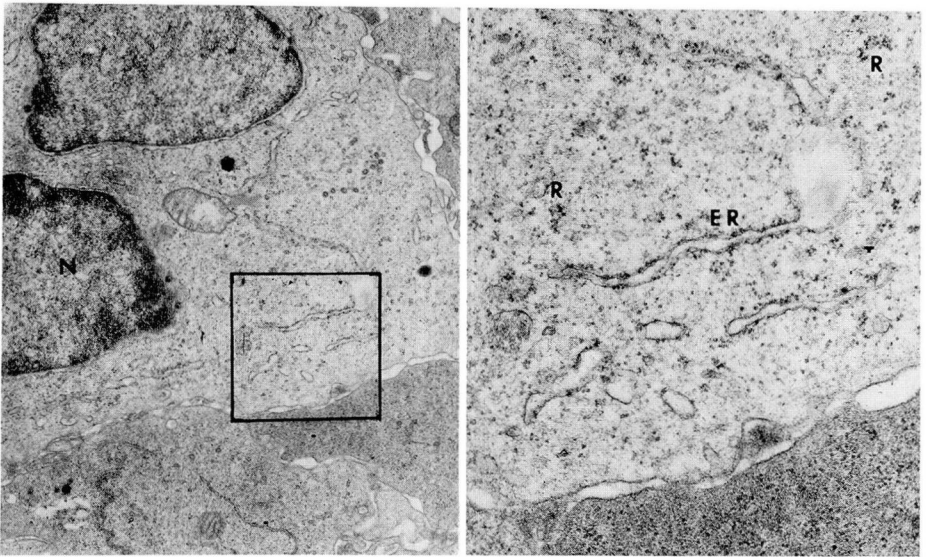


Fig. 2. Electron microscopy of supraclavicular lymph node. **A**, Ultrastructural appearance of tumor cells in *Figure 1* with nucleus (N) at left. The cells are larger than small lymphocytes and contain increased numbers of ribosomes, $\times 18,400$. **B**, Higher magnification of the enclosed portion of the tumor cell in *Figure 2A*. In this area the ribosomes (R) and granular endoplasmic reticulum (ER) are particularly well developed, although the latter were not prominent features of the tissue. Uranyl acetate and lead citrate, $\times 49,750$.

Table 2.—Immunologic studies

Specimen	Immuno-electrophoresis		Immunoglobulins mg/100 ml			Sedimentation constant of abnormal protein	Total protein, g/100 ml
	Fc fragment	IgG	G	A	M		
Serum							
July 1969	+	+	9000	260	175	3.9 S	13.0
October 1970	—	+	3700	240	110		8.1
Urine							
October 1970	+	+				2.8–3.2 S	
April 1971	+	+				3.2 S	

large lymphocytes and plasma cells, and the overall clinical picture is more closely related to a malignant lymphoma than to multiple myeloma. Usually the patients are middle-aged men with lymphadenopathy that waxes and wanes, hepatosplenomegaly, a peculiar uvular and palatal edema, and mild anemia. Bone le-

sions are not seen. Examination of the bone marrow reveals a variable number of mature plasma and plasmacytoid cells, usually less than 30% of the total. Immature plasma cells and plasmablasts are uncommon.

The common feature of this disease is the presence of an abnormal protein in the serum and urine. This protein

migrates in the fast gamma or slow beta region on paper electrophoresis. On immunoelectrophoresis, it precipitates with antisera to IgG and the Fc fragment of IgG. It does not react with antisera to light chains or the Fab κ or Fab λ fragments of IgG (Fig. 3). Ultracentrifugation of the purified protein reveals Svedberg constants from 2.8 to 4.7 S_{20} indicating the presence of both heavy chain fragments and polymers. In the few cases in which amino acid sequences have been studied, homology to IgG heavy chains has been demonstrated.

These patients have a variable clinical course with death from 7 months to many years after diagnosis. Despite the proteinuria, which may be as much as 20 g/day, renal function is not significantly impaired. The major complication and usual cause of death is recurrent infection, often caused by pneumococci.

This patient had, in many ways, a typical example of heavy chain disease. However, certain atypical features deserve comment. Perhaps the single most unusual aspect of this case was the presence of a large amount of intact IgG molecules and only a small quantity of heavy chain fragments. It is possible that the abnormal protein was a product of nonspecific breakdown in the serum or urine, but several facts indicated differently. The abnormal protein obtained from specimens collected over a period of several months had a constant mobility. The shape and density of the precipitin indicated a homogeneous substance. No free light chains were identified in either the serum or urine and there were no substances corresponding to Fab fragments in the fresh material analyzed. In short, all studies indicated the presence of a homogene-

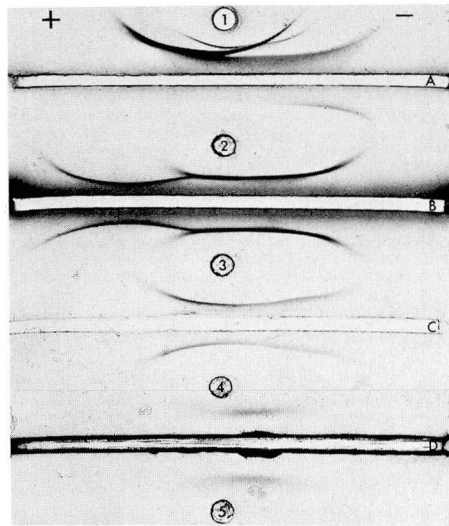


Fig. 3. Demonstration of heavy chain fragment by immunoelectrophoresis. Wells containing test protein(s) numbered 1 through 5. Troughs containing antisera lettered A through D. Number 1—normal human serum; numbers 2–5—patient's urine precipitated with ammonium sulfate and concentrated 10-fold. A—Goat trivalent antiserum (IgG, IgA, IgM) obtained from Hyland Laboratories, Costa Mesa, California. B—Goat anti-heavy chain (Hyland). C—Goat anti-kappa light chains obtained from Bio-ware, Inc., Wichita, Kansas. D—Rabbit anti-lambda light chains made in the Immunology Department, Cleveland Clinic. The heavy chain fragment migrates toward the anode. There is no corresponding light chain precipitin arc and no evidence of free light chains. Ponceau red S.

ous protein related to the Fc fragment of IgG, a highly unlikely result of random cleavage by serum or urinary enzymes. These results, viewed in the clinical setting, completed the picture of heavy chain disease. This patient had had numerous courses of chemotherapy before 1969. However, the serum obtained in July 1969 contained a significant quantity of heavy chain fragment. Not all subsequent serum specimens exhibited the heavy chain fragment. This emphasizes the impor-

tance of adequate immunological evaluation before the institution of therapy.

The α -mobility of the abnormal protein was unusual. Although some cases with γ_1 -mobility have been reported, most heavy chain fragments migrate with the β -globulin fraction. It is possible that the rapid mobility of this protein is related to the immunoelectrophoretic system used in this institution and is not a function of the heavy chain fragment itself.

It is of interest that the patient's cellular immune system was severely impaired as evidenced by a decreased lymphocyte transformation to PHA, and that it improved with treatment. The same phenomenon has been reported in patients with other lymphoproliferative diseases (Hodgkin's disease, chronic lymphocytic leukemia, lymphosarcoma),⁶ but to our knowledge not in individuals with heavy chain disease.

Lastly, this patient survived 7 years after the original diagnosis of malignant lymphoma and represents one of the longest survivals. Whether this is due to specific treatment or is related more to the natural course of the disease is a question that only the study of more cases will answer.

The foregoing discussion relates almost entirely to heavy chain diseases of the gamma type. It was predicted on theoretical grounds that other types (α , μ , δ and ϵ) of heavy chain disease would be discovered. To date, at least six well-documented cases of α -chain disease^{7, 8} and three of μ -chain disease⁹⁻¹² have been reported. Reports of ϵ -chain and δ -chain disease will almost certainly follow.

Acknowledgment

The authors thank Dr. E. C. Franklin, New York University Medical Center, for confirmation of the diagnosis; Dr. Lena A. Lewis of the Research Division for evaluation of the ultracentrifugation results; and Miss Barbara Barna for expert technical assistance.

References

- Franklin EC, Meltzer M, Guggenheim F, et al: An unusual microgamma-globulin of the serum and urine of a patient. *Fed Proc* 22: 264, 1963.
- Franklin EC, Lowenstein J, Bigelow B, et al: Heavy chain disease—a new disorder of serum γ -globulins. *Am J Med* 37: 332-350, 1964.
- Osserman EF, Takatsuki K: Clinical and immunochemical studies of four cases of heavy ($H\gamma_2$) chain disease. *Am J Med* 37: 351-373, 1964.
- Case records of the Massachusetts General Hospital. Weekly clinicopathological exercises. Case 50-1970. *N Engl J Med* 283: 1332-1339, 1970.
- Lönnroth I, Falsen E, Westin J, et al: Two cases of 'heavy chain disease'. *Acta Pathol Microbiol Scand* B79: 443, 1971.
- Pentycross CR: Lymphocyte transformation in diseases of lymphoid tissue. *Proc R Soc Med* 63: 355-357, 1970.
- Seligmann M, Danon F, Hurez D, et al: Alpha-chain disease: a new immunoglobulin abnormality. *Science* 162: 1396-1397, 1968.
- Franklin EC: Heavy-chain diseases. *N Engl J Med* 282: 1098-1099, 1970.
- Forte FA, Prelli F, Yount WJ, et al: Heavy chain disease of the μ (γ M) type. *Blood* 36: 137-144, 1970.
- Josephson AS, Price E, Biro L: A low molecular weight fragment related to IgM in the serum of a patient with an IgA plasma cell dyscrasia. *Clin Res* 17: 604, 1969.
- Ballard HS, Hamilton LM, Marcus AJ, et al: A new variant of heavy-chain disease (μ -chain disease). *N Engl J Med* 282: 1060-1062, 1970.
- Zucker-Franklin D, Franklin EC: Ultrastructural and immunofluorescence studies of the cells associated with μ -chain disease. *Blood* 37: 257-271, 1971.