

# Postpericardiotomy syndrome following surgery for congenital heart disease

Derek Fyfe, M.D., Ph.D.

*Department of Pediatrics and Adolescent Medicine*

Douglas S. Moodie, M.D.

*Department of Cardiology  
Department of Pediatrics and Adolescent Medicine*

Carl C. Gill, M.D.

*Department of Thoracic and Cardiovascular Surgery*

The postpericardiotomy syndrome (PPS) may occur after intrapericardial surgery and is usually characterized by fever and pericardial and pleural effusions as major clinical manifestations.<sup>1-3</sup> A similar syndrome has also been observed after myocardial infarction (Dressler's syndrome),<sup>4</sup> and after penetrating or blunt trauma to the pericardium.<sup>5</sup> As yet no specific treatment for this syndrome is available and anti-inflammatory agents with supportive medical or surgical measures are generally used when necessary. Although PPS is believed to be a self-limited illness, in some cases it has led to cardiac tamponade and death. In the largest reported series of 400 patients who had undergone intracardiac surgery, PPS occurred in about 27%; it rarely occurs before age 2.<sup>6</sup>

The recent surgical experience with congenital heart disease at the Cleveland Clinic was reviewed with regard to the frequency and manifestations of the clinically significant PPS.

## Results

PPS occurred in 13 of 217 patients after correction of various congenital cardiac lesions (*Table*). Six of 13 patients had simple secundum atrial septal defects. The other congenital lesions are listed in the *Table*. The age range was 11 to 47 years (mean,

**Table. Clinical profile of 13 patients with postpericardiectomy syndrome**

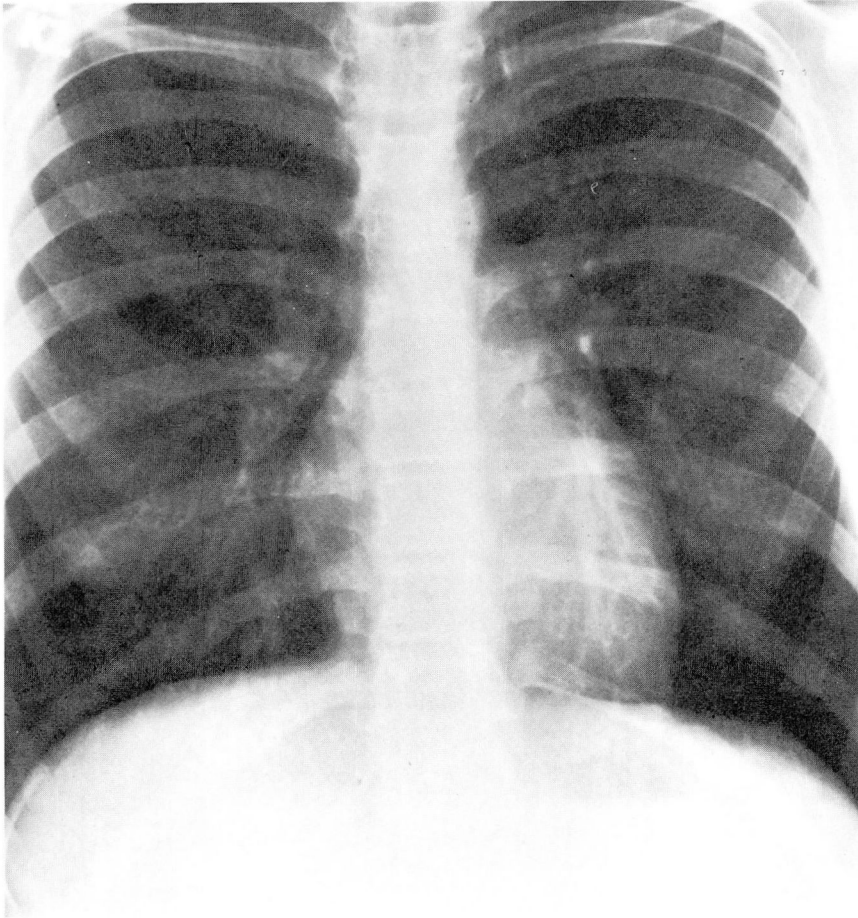
Patient	Operation	Age	Sex	Fever	Pain	Cough	Decreased breath sounds	Rub	Chest x-ray, cardiomegaly	Pleural effusion	Echocardiogram pericardial effusion	ECG, ST changes	Onset* (days)	Duration (days)	Leukocytosis	Severity	Treatment
1	ASD	16	M	-	-	+	-	-	+	-	+	-	46	4	-	Mild	ASA
2	ASD	17	M	-	+	+	+	+	+	-	+	+	5	14	-	Mild	ASA
3	ASD, PVC	15	F	+	-	+	-	-	+	+	+	-	3	14	-	Mild	ASA
4	ASD	11	F	+	+	-	-	-	+	+	+	-	9	28	-	Mild	ASA, pred
5	ASD	33	F	-	-	-	-	-	+	-	+	-	39	25	-	Moderate	ASA, dig
6	ASD	14	M	+	+	-	+	+	+	-	+	-	4	30	+	Moderate	ASA, ind, pred
7	VSD, RVI	15	M	+	+	-	+	-	+	+	+	-	18	58	+	Severe	ASA, pred, tap
8	VSD, RVIP	18	M	+	+	-	+	+	+	+	+	-	4	17	-	Mild	Ind
9	ASD, RVIME	11	F	+	+	+	+	-	+	+	+	-	3	55	-	Very severe	ASA, pred, tap
10	ASD, AVR	33	M	+	-	-	+	+	+	-	+	-	7	34	-	Mild	ASA
11	ASD, VSD, AVR	32	M	+	+	-	+	+	+	+	+	-	7	7	-	Mild	ASA
12	ASD	47	M	-	+	-	-	-	+	+	+	+	55	70	ND	Moderate	Pred
13	AVR, RAE	20	M	-	-	-	-	+	+	-	+	-	8	13+	ND	Mild	Ind

\* Days postoperatively.

ASD = atrial septal defect, ASA = aspirin, PVC = pulmonary valve commissurotomy, pred = prednisone, dig = digoxin, ind = indomethacin, VSD = ventricular septal defect, RVI = right ventricular infundibulectomy, tap = pericardiocentesis, RVIP = right ventricular infundibular patch, RVIME = right ventricular infundibular muscle excision, AVR = atrioventricular valve replacement, ND = no data, RAE = right atrial excision.

21.6 years). Nine of the 13 patients were between 11 and 20 years of age. The most frequent presenting symptoms were fever, pleuritic chest pain, and shoulder pain (eight patients). Frequent findings on physical examination were decreased breath sounds (eight patients), and the presence of a pleural or pericardial rub (six patients). Symptoms began between the third and 55th days postoperatively; the mean onset was 16 days, and the mean duration of the syndrome was 29 days. Initial echocar-

diograms demonstrated large pericardial effusions in all 13 patients. Electrocardiographic findings of ST elevation were present in only two patients. Chest roentgenograms demonstrated increased cardiac size in all patients and pleural effusions in six patients. Laboratory studies including white blood cell counts (WBC) revealed only moderate elevations of leukocytes usually accompanied by a predominance of neutrophils. Several blood cultures done on each patient were negative.



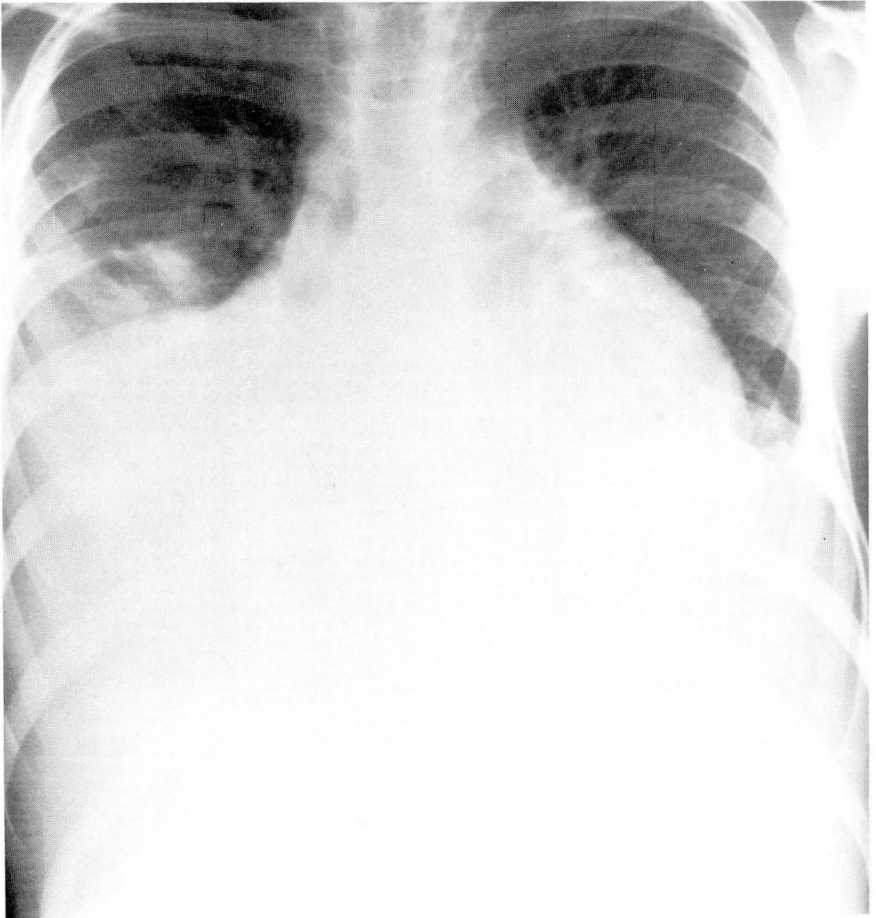
**Fig. 1.** Preoperative chest roentgenogram before excision of an anomalous right ventricular outflow tract muscle bundle.

Four of the 13 patients had moderate to severe disease. Two patients required thoracentesis, and one patient required emergency pericardiocentesis for tamponade and resection of a pericardial window. In this patient, 1000 cc of serous pericardial fluid was aspirated and the patient subsequently had a cardiac arrest 12 hours postoperatively. After 2 days of continuous inotropic support, the patient completely recovered. The progression of roentgenographic changes is shown in *Figures 1-4*; a large posterior pericardial effusion was shown by echocardiography (*Fig. 5*).

Medications prescribed were aspirin, indomethacin, and prednisone. Five patients were receiving warfarin sodium (Coumadin) at onset of PPS. Five of the 13 patients were rehospitalized with PPS. There were no deaths in this series.

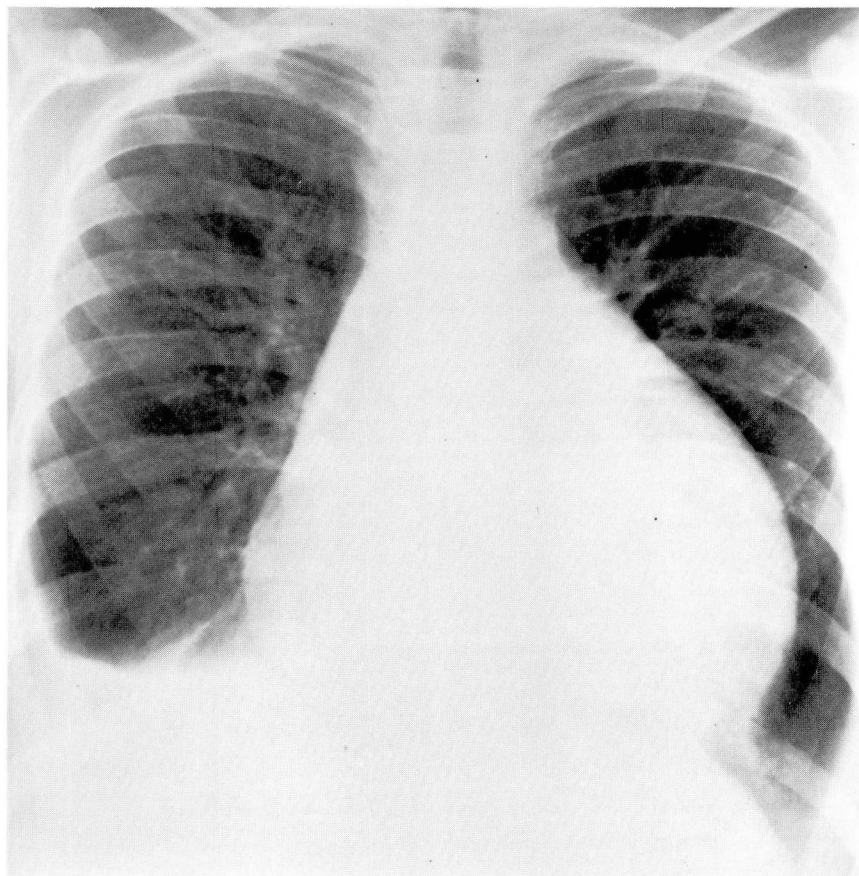
### Discussion

In our experience with clinically significant PPS after surgery for congenital heart disease, onset of symptoms tended to be within the first 2 weeks postoperatively, often heralded by fever, pleuritic chest pain, and cough. Patients usually had decreased breath sounds and a



**Fig. 2.** Postoperative day 15 showing severe cardiomegaly and large bilateral pleural effusions.





**Fig. 3.** Postoperative day 23 showing prominent globular heart and resolving pleural effusions following treatment with anti-inflammatory agents.

pleural or pericardial rub by examination. All patients had large pericardial and often pleural effusions on initial chest roentgenogram and echocardiogram. Neither electrocardiograms nor WBCs were helpful in diagnosis or in following the course of the disease. The severity of clinical symptoms ranged from mild in most cases, to severe in three patients, one of whom developed tamponade and suffered cardiac arrest. All patients survived.

A 6%<sup>7</sup> to 53% incidence of PPS has been reported.<sup>8</sup> Recently, in a series of 400 pediatric patients, Engle et al<sup>6</sup> reported an overall incidence of 27%. This

was significantly less in patients older than 40 years of age and rare in patients younger than age 2. In the present report, the 6% incidence may reflect the fact that most of our patients with PPS had clinically significant illness, causing prolonged hospitalization or rehospitalization in some cases. The symptoms of fever, pain, and polyserositis used as diagnostic criteria by most observers were not uniformly present in our patients, although all had moderate to large pericardial effusions. In a study by Clapp et al,<sup>8</sup> diagnostic criteria were liberalized, i.e., patients were selected by the presence of three of five clinical

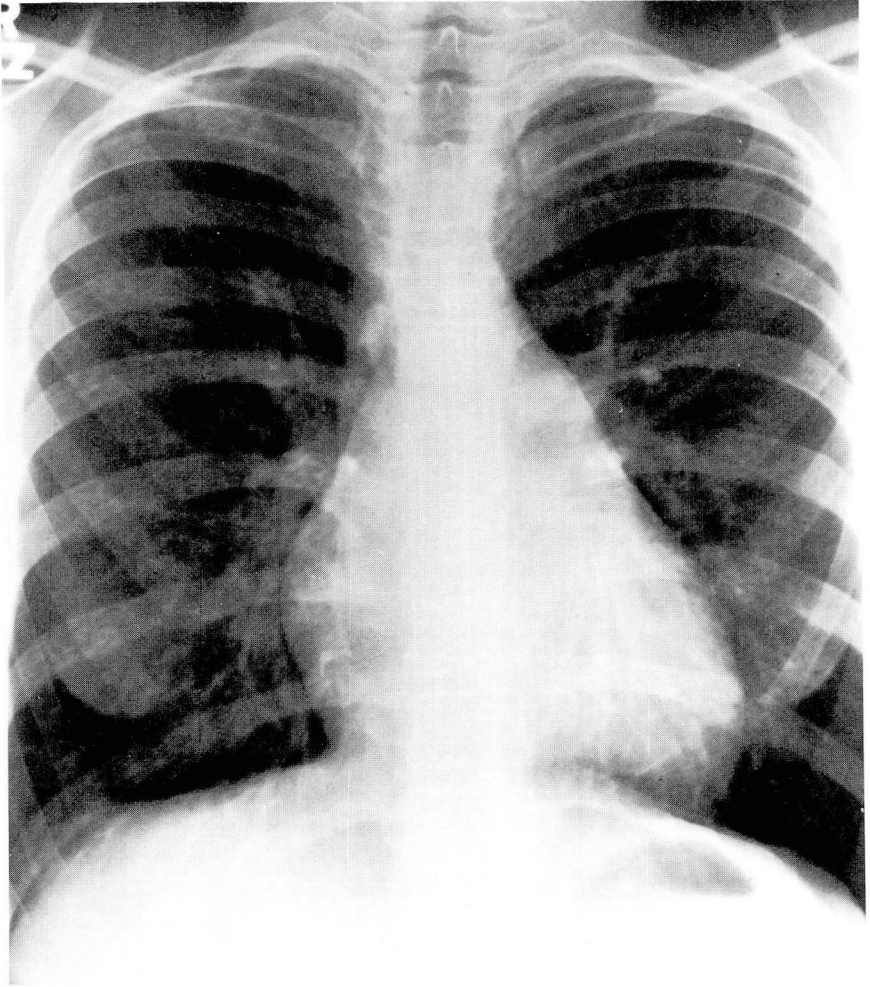


Fig. 4. Postoperative follow-up chest roentgenogram at 6 months.

features: fever, chest pain, pericardial friction rub, fluid retention, and irritability or anorexia. Sixteen of 18 patients with PPS as defined above had echocardiographic findings of pericardial effusion, and in 15 patients, pericardial effusion was present by the second postoperative day. Only one patient with pericardial effusion had no clinical evidence of PPS. This specific finding may, therefore, indicate that PPS or "benign postoperative pericarditis" may be underdiagnosed when postoperative echo-

cardiograms are not routinely obtained following cardiac surgery.

It is important to study the relationship between early pericardial effusions and immunologic factors to determine those features associated with different clinical outcomes. It is possible that the mild early disease may be different from the lingering, life-threatening disease seen in some of our patients.

It has been demonstrated that patients with PPS may have increased titers of antibodies to one or even several



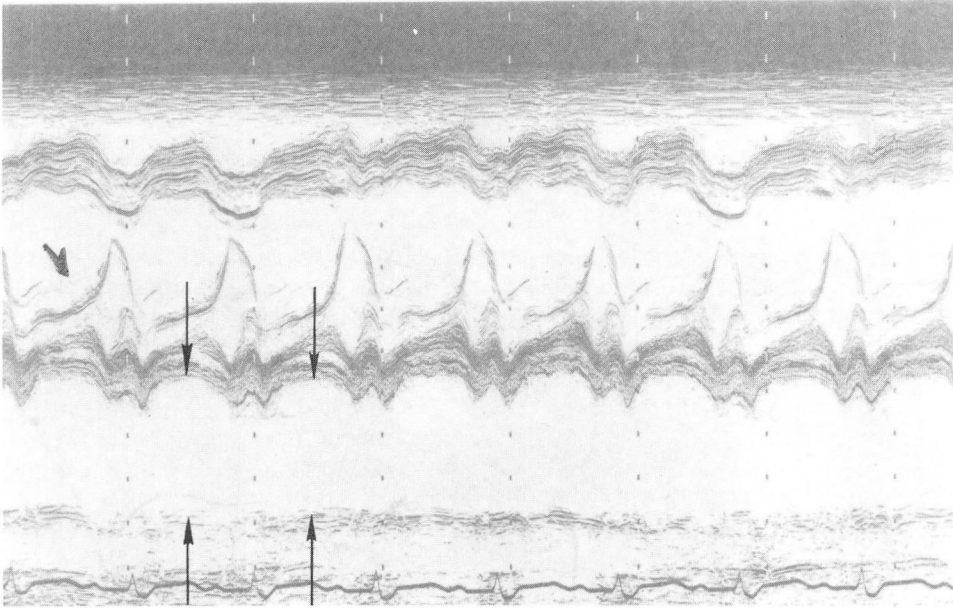


Fig. 5. Echocardiogram showing large posterior pericardial effusion from the same patient.

viruses that are epidemic in the community at or after the time of surgery, i.e., Coxsackie, adenovirus, and cytomegaloviruses. Also, a putative "anti-heart antibody" may also be present in high titer in the sera of patients with PPS. Engle et al<sup>3</sup> postulated that PPS may represent an autoimmune disease triggered by a viral infection after pericardial or myocardial injury. This attractive hypothesis fails, however, to encompass findings of elevated antiheart antibodies in patients postoperatively or in those who have myocardial infarction when no PPS is present.<sup>4,9,10</sup> Antiheart antibodies may represent an epiphenomenon, being formed in response to myocardial damage due to various mechanisms but not etiologic to PPS itself.

It has also been suggested that development of PPS may relate to the extent of surgical manipulation of the myocardium.<sup>11</sup> In the series of Engle et al,<sup>3</sup> 40% of patients had PPS following ventric-

ular septal defect repair when infundibulectomy was also performed, whereas when simple ventricular septal defect was corrected, the incidence was only 9%. However, atrial septal defect repair, in which no muscle resection is required, accounted for 24% of patients. Also, in the series reported here, atrial septal defect was often associated with PPS, again casting doubt on this hypothesis.

As a clinical entity, PPS is not uncommon and may be mild or life threatening. It is apparent that identification of more specific biochemical or immunologic markers is needed before the full spectrum of PPS is comprehensible and optimal therapy may be provided.

## References

1. Ito T, Engle MA, Goldberg HP. Postpericardiotomy syndrome following surgery for non-rheumatic heart disease. *Circulation* 1958; **17**: 549-56.
2. Engle MA, Ito T. The postpericardiotomy syndrome. *Am J Cardiol* 1961; **7**: 73-82.

3. Engle MA, Gay WA, Kaminsky ME, et al. The postcardiotomy syndrome then and now. *Curr Probl Cardiol* 1978; **3**: 5-40.
4. Kennedy HL, Das SK. Postmyocardial infarction (Dressler's) syndrome; report of a case with immunological and viral studies. *Am Heart J* 1976; **91**: 233-9.
5. Tabatznik B, Issacs JP. Postpericardiotomy syndrome following traumatic hemopericardium. *Am J Cardiol* 1961; **7**: 83-96.
6. Engle MA, Zabriskie JB, Senterfit LB, Gay WA Jr, O'Loughlin JE Jr, Ehlers KH. Viral illness and the postpericardiotomy syndrome; a prospective study in children. *Circulation* 1980; **62**: 1151-8.
7. Roses DF, Rose MR, Rapaport FT. Febrile responses associated with cardiac surgery; relationships to the postpericardiotomy syndrome and to altered host immunologic reactivity. *J Thorac Cardiovasc Surg* 1974; **67**: 251-7.
8. Clapp SK, Garson A, Gutgesell HP, Cooley DA, McNamara DG. Postoperative pericardial effusion and its relation to postpericardiotomy syndrome. *Pediatrics* 1980; **66**: 585-8.
9. Heine WI, Friedman H, Mandell M, Goldberg H. Antibodies to cardiac tissue in acute ischemic heart disease. *Am J Cardiol* 1966; **17**: 798-803.
10. Liem KL, ten Veen JH, Feltkamp TEW, Durrer RD. Incidence and significance of heart muscle antibodies in patients with acute myocardial infarction and unstable angina. *Acta Med Scand* 1979; **206**: 473-5.
11. Engle MA, Ehlers KH, O'Loughlin JE, et al. The postpericardiotomy syndrome; iatrogenic illness with immunologic and virologic components. *Cardiovasc Clin* 1980; **11/2**: 381-91.