

## THE INTERPRETATION OF QUALITATIVE CHANGES IN NEUTROPHILIC LEUKOCYTES

*“Shift to Left”—“Shift to Right”—“Toxic” Granulation*

RUSSELL L. HADEN, M. D.

The neutrophilic granulocyte (polymorphonuclear neutrophilic leukocyte) plays a major rôle in the mechanism of defense against infection and toxemia. The defensive value of this cell depends upon its maturity and the integrity of its chemical substances which normally enable it to dispose of bacteria and poisons. The quality of the neutrophilic granulocyte is thus even more important than the quantity.

The granulocyte is essentially a drop of protoplasm containing active ferments surrounded by a membrane. Anything interfering with the development of the protective substances or injuring them must impair the usefulness of the cell. All granulocytes are formed in the bone marrow. Each cell goes through a definite cycle of development and maturation before entering the circulation. When a granulocyte is released from the marrow, its development normally is complete. No further changes take place while it is in the circulation or tissues except those incidental to the death of the cell.

The granulocytes have no function in the blood stream. All cells in the circulation are only passing from the site of formation in the marrow to the point of excretion or localization in the tissues. The mature granulocyte circulates only a short time, certainly not more than three or four days. When a cell dies in the circulation or leaves the blood stream to be excreted by a mucous membrane or to localize in the tissues, another emerges from the marrow to keep the total number at a relatively fixed level. Five to ten billion neutrophilic granulocytes are formed every day to replace those lost. Only a few cells die in the blood stream and are disposed of by the scavenger (reticulo-endothelial) cells; some die in the tissues where they have localized; the remainder are excreted through the mucous membranes of the gastro-intestinal, genito-urinary and respiratory tracts. The stimulus for the formation of new cells to replace those lost seems normally due to substances released when the nuclei of the granulocytes disintegrate. Thus, the normal picture shows a constant growth and release of new cells to replace those excreted or disposed of in the tissues or blood stream.

Under abnormal conditions of infection or toxemia, the normal marrow has an enormous capacity for supplying granulocytes. The stimulus for expansion is again a chemical one, the inciting agents being bacterial products or other toxins. The number and quality of the granular leukocytes in the circulation depend upon the need of the tissues for cells

# QUALITATIVE CHANGES IN NEUTROPHILIC LEUKOCYTES

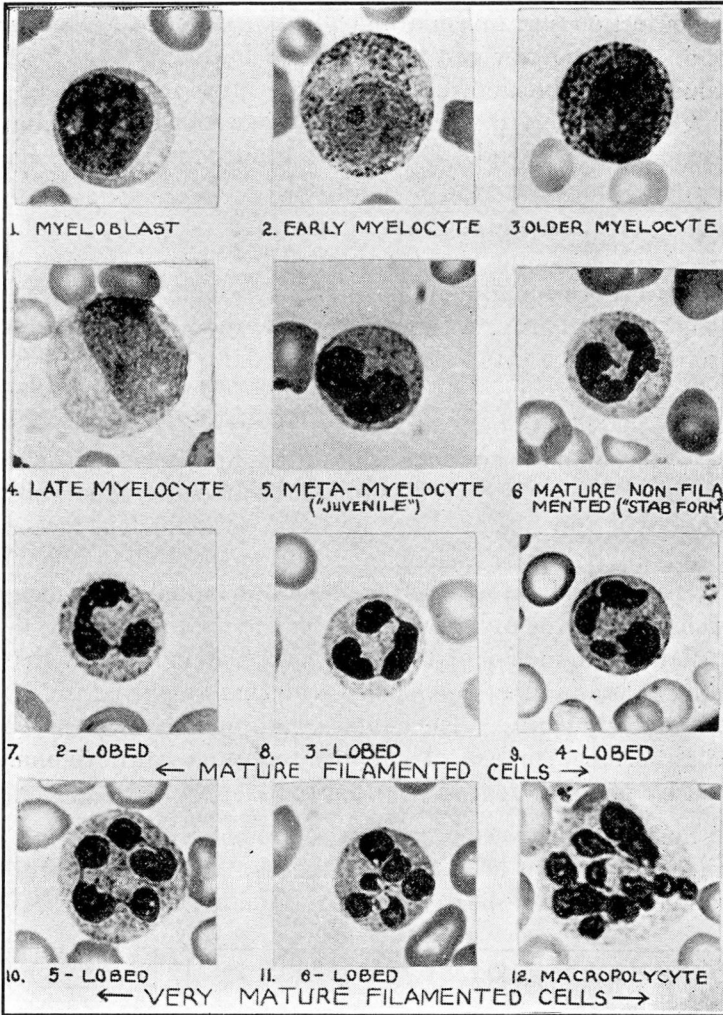


FIGURE 1: Stages in development of the neutrophilic granulocyte. (Photomicrographs x 1100.)

1. **Myeloblast:** The cell is small; the cytoplasm is scanty, basophilic and contains no granules; the nucleus is relatively large, contains nucleoli and has the characteristic "sieve" or "lace-net" pattern.
2. **Early myelocyte:** The cell is larger; the cytoplasm is more abundant, less basophilic, and contains a few granules; the nucleus is relatively smaller, still contains nucleoli and shows a "sieve" pattern.
3. **Older myelocyte:** The cytoplasm contains more granules; the nucleoli have disappeared; the nucleus is still immature but is oval and the chromatin has less of the "sieve" effect.
4. **Late myelocyte:** The cell is still larger than normal, the nucleus does not yet have the mature chromatin pattern; the granules are small and show the mature neutrophilic staining.
5. **Metamyelocyte:** The cell is now of normal size; the granules in the cytoplasm are normal; the nucleus is indented and has almost the normal chromatin pattern. This is designated a "juvenile" cell in the Schilling classification.
6. **A mature non-filamented cell:** ("stab" cell in Schilling classification).
- 7, 8, 9, 10. **Mature filamented cells:** In each instance, two or more lobes are united by a thin thread (Cooke's criterion).
- 11, 12. **Mature filamented cells:** Here there is an unusually large number of lobes indicating hypermaturity.

to combat infection and toxemia and the capacity of the bone marrow to respond. The marrow can be exhausted by overactivity or injured by the same toxins which normally stimulate it to form more cells. The circulating cells reflect the extent of the infection or toxemia if the marrow can freely respond. Qualitative changes in the cells may also show the state of the marrow if it is injured.

The parent cell of the granulocyte in the marrow, the myeloblast, consists at first of a large nucleus surrounded by a small amount of clear cytoplasm. The chromatin of the nucleus resembles a "lace-net" or "sieve" and stains lightly. As the cell grows the nucleus becomes relatively smaller and the cytoplasm more abundant. Granules develop in the cytoplasm and oxidase staining appears. The nucleoli disappear. The granules increase in number and are smaller. The nucleus becomes indented. The cell now shows motility for the first time. The chromatin of the nucleus becomes disposed in thick, deeply-staining strands rather than in the earlier fine, "sieve-like" network. The nucleus becomes still smaller and appears V- or S-shaped (non-filamented mature cell). The nucleus separates off into two or more lobes united by a thin thread (filamented cell). The older the cell is on leaving the marrow, the more lobes it shows, although it is uncommon to find more than five lobes. The cytoplasm is abundant and packed with small neutrophilic granules. The cell is actively motile. The oxidase staining is now intense, indicating the high ferment content. These different stages of development are illustrated by photomicrographs in figure 1.

Under normal conditions, granulocytes are not released from the marrow until most of them have reached the non-filamented mature stage at least and only a few appear even then. The normal release of granu-

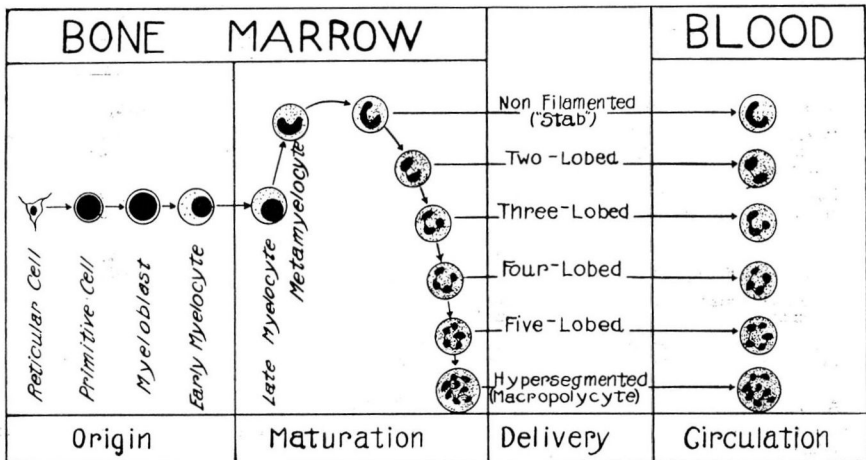


FIGURE 2: Diagram to illustrate the release of neutrophilic granulocytes after maturation.

## QUALITATIVE CHANGES IN NEUTROPHILIC LEUKOCYTES

locytes is illustrated in figure 2. Most of the new cells are filamented, having two to five lobes. If cells are being produced at a rapid rate in response to some abnormal need, the picture is different. At first, mature (filamented) cells appear. Later, a higher-than-normal percentage of less mature (non-filamented mature cells, metamyelocytes, or even myelocytes) are released. The picture in extreme cases may even simulate myelocytic leukemia where there is an unrestrained overgrowth of myeloid cells. A leukocytosis with more immature cells than normal is designated a "regenerative shift to the left."

The marrow may be injured as well as stimulated by bacteria and other toxins. It may be simply depressed so fewer cells than normal are produced in proportion to the stimulus and usually such cells are less mature than normal. This picture is designated a "degenerative shift to the left" since the immaturity of the cells results from the injury to the bone marrow which prevents normal function of the marrow. Here the cells usually show evidence of the toxic action on the marrow. The nucleus presents abnormal patterns as well as immaturity. The cytoplasm often contains basic-staining granules ("toxic" granulation) (Fig. 3). These qualitative changes in the cytoplasm may also occur with any degree of leukocytosis and even with good maturity of cells. The basic-staining granules seem to be abnormal granules and not simply an aggregation and abnormal staining of normal granules. Cells showing "toxic" granulation have a decrease in the normal granules in proportion to the number of "toxic" granules and show little oxidase staining (Fig. 4). Such cells are deficient in the ferments on which the power of defense depends, so seem of little value.

It is apparent that the age and any toxic effect on the cell can be detected by a careful quantitative and qualitative study. Myeloblasts and myelocytes are of no value as defense cells since they are non-motile. The value of a granulocyte in defense depends upon its power to invade tissues where it functions by ameboid activity as well as ferment content. The myeloblasts show no oxidase staining as well as being non-motile. Likewise, the value of cells showing "toxic" granulation, indicating damage to the cytoplasm in the bone marrow, is impaired. This is probably due to a change in ferment activity. These facts emphasize that granulocytes, to assist in defense against infection and toxemia, must be qualitatively as well as quantitatively adequate.

How should these qualitative changes be recorded? Arneth<sup>1</sup> (Fig. 5) was the first to emphasize the relation of age of the leukocyte to morphology. He divided the granulocytes into five classes and numerous subclasses on the basis of the number of nodes and nodulations of the nucleus. This is measuring maturity rather than immaturity. Schilling<sup>2</sup>

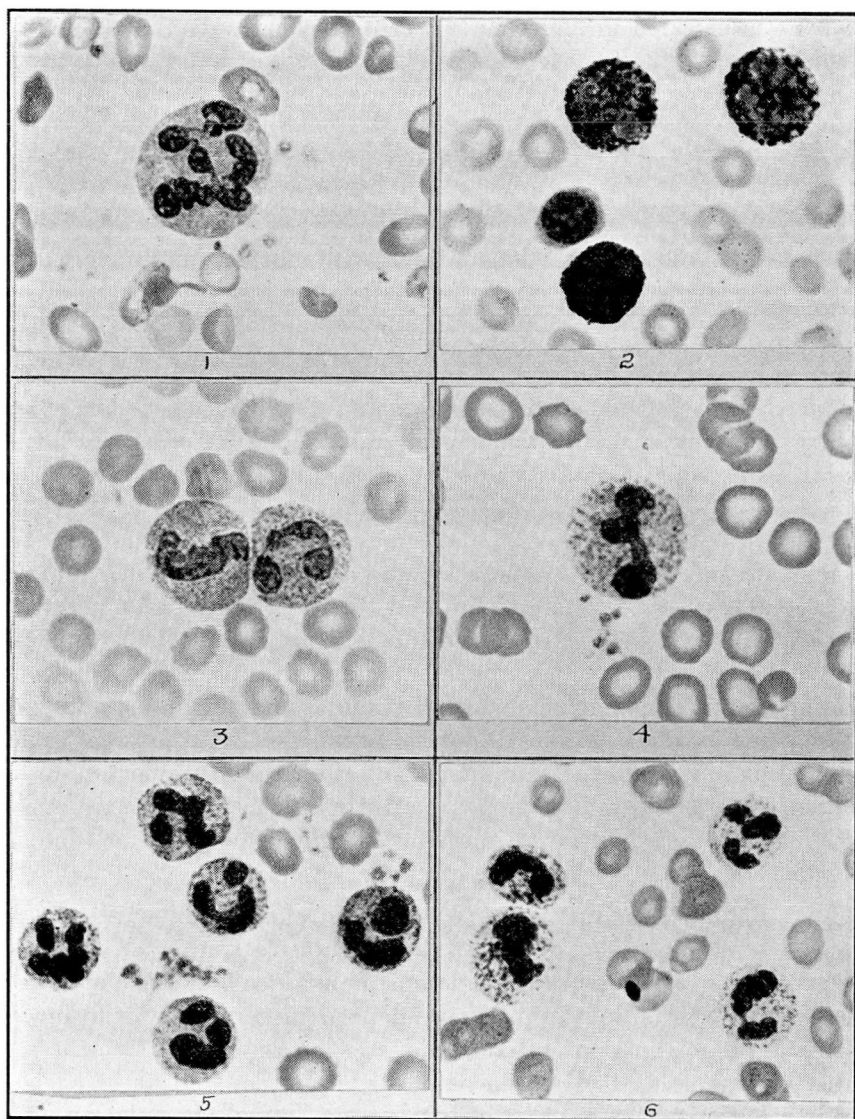


FIGURE 3: Granulation and oxidase staining of neutrophilic granulocytes illustrated with photomicrographs.

1. Normal mature neutrophilic granulocyte: Note the uniform pattern of the chromatin of the nucleus. The cytoplasm is packed with small granules of uniform size (x 1100).
2. Oxidase staining (Washburn method) of normal neutrophilic granulocytes. The cytoplasm is filled with the intense purple staining granules. The small cell is a lymphocyte which does not show oxidase staining (x 1100).
3. "Toxic" (basophilic) granulation in non-filamented (left) and filamented (right) cells. The "toxic" granules are relatively small and abundant (x 1100).
4. "Toxic" (basophilic) granulation in a non-filamented cell. The granules are relatively few in number, very large, and stain intensely. The chromatin of the nucleus is pyknotic instead of having the normal pattern as in No. 1 (x 1100).
5. Leukocytosis with marked "toxic" granulation but very good filamentation of granulocytes (x 800).
6. Oxidase stain (Washburn method) of leukocytosis of lobar pneumonia in which the cells showed marked "toxic" granulation. Note the scarcity of oxidase staining material as compared with normal in No. 2 (x 800).

# QUALITATIVE CHANGES IN NEUTROPHILIC LEUKOCYTES

## Basophilic Granulation Of Neutrophils With Oxidase Stain



























	Wright's Stain	Oxidase Stain
Normal Neutrophilic Granulation		
Fine Basophilic Granulation		
Coarse Basophilic Granulation		

FIGURE 4: Diagram to indicate the relation between "toxic" (basophilic) granulation and the oxidase reaction.

suggested (Fig. 6) that all the segmented mature cells be placed in one group and immature cells be subdivided into myelocytes, juvenile cells (metamyelocytes), and stab cells (non-filamented mature cells). Schilling is not very definite in regard to criteria for determining a mature segmented cell. Cooke<sup>3</sup> suggested a cell should not be considered filamented unless two or more lobes are united by a thin thread or filament (Cooke's criterion). All classifications of maturity agree on separating mature and immature cells and the best criterion for this general division is that of Cooke. Arneht further divides the mature cells only and Schilling the immature only. The clinical value of these subdivisions is questionable. The classification suggested by Farley<sup>4</sup> and his coworkers is simple and is all that is needed in most cases. Here the cells are simply divided into two groups, filamented and non-filamented (Fig. 7).

If one records in the form of a graph (Fig. 8) the different stages of the granulocyte, beginning with the myeloblast on the left, the different types of leukocyte pictures seen in the circulating blood may be indicated by curves of incidence of different cell types. If more than the normal number of immature cells are present as indicated by a higher percentage of non-filamented mature cells, juvenile cells (metamyelocytes), or myelocytes, the curve of incidence appears to the left of the normal curve ("shift to the left"). This picture is found in infection and toxemia. In myeloid leukemia, the cells are still more immature so the

## ARNETH'S Classification OF Neutrophils

Class					
I One Nucleus	 M 0%	 W 0.2%	 T 5%		
II Two-Lobed Nuclei	 2K 0.27%	 2S 23.5%	 1K1S 11.7%		
III Three-Lobed Nuclei	 3K 2.3%	 3S 5.6%	 2K1S 16.7%	 1K2S 16.4%	
IV Four-Lobed Nuclei	 4K 3.8%	 4S 0.07%	 3K1S 6.4%	 2K2S 16%	 1K3S 4.7%
V Five-Lobed Nuclei	 5K 1%	 4K1S 0.4%	 3K2S 0.4%	 2K3S 0.07%	 1K4S 0.07%

M = Myelocyte    W = Slightly Indented Nucleus  
 T = Deeply Indented Nucleus  
 K = Round Piece    S = Bent Piece

FIGURE 5: Arneth classification of the neutrophilic leukocyte.

curve is still further to the left (extreme "shift to the left"). If less than the normal number of immature cells is present and the filamented cells show many nodes, the curve appears to the right of the normal curve ("shift to the right"). This type of granulocyte reaction usually means that the granulocytes are held in the marrow longer than normal so further maturation takes place. Usually this is due to pernicious anemia where the granulocytes are mechanically enmeshed in the hyperplastic erythrogenic tissue in the red marrow. Such cells seldom show "toxic" granulation. One should not think of the leukocytes only in terms of such phases as "shift to the right" and "shift to the left" but with a fundamental understanding of what is taking place in the marrow and with an appreciation that the blood picture is dependent both upon the

QUALITATIVE CHANGES IN NEUTROPHILIC LEUKOCYTES

# SCHILLING Classification OF Neutrophils





Myelocyte (Normal - 0)	
Juvenile Cell (0-1 percent)	
Stab Cell (3-5 percent)	
Segmented Cells (51-67 percent)	

FIGURE 6: Schilling classification of the neutrophilic leukocyte.

# FARLEY, ST. CLAIR and REISINGER Classification Of Neutrophils







Filamented			
Non-Filamented (5-16 percent of 100 Leucocytes)			

FIGURE 7: Farley, St. Clair and Reisinger classification of the neutrophilic leukocyte.

needs of the tissues and on the capacity of the marrow to respond to stimulation.

The presence of "toxic" granulation is equally as important as maturity of the granulocytes in gauging the activity of a toxic process. There is no very satisfactory quantitative method for recording "toxic" granula-



TABLE I

	Total per cent	Normal per cent	"Toxic" Granulation per cent
Polymorphonuclear neutrophils, filamented .....	60	12	48
Polymorphonuclear neutrophils, non-filamented .....	25	5	20
Polymorphonuclear eosinophils.....	0		
Polymorphonuclear basophils.....	0		
Lymphocytes.....	10		
Monocytes.....	5		

Degenerative index =	Number of neutrophils showing "toxic" granulation	68	=	80
	Total number of neutrophils	85		

Percentage of neutrophils showing "toxic" granulation .....	= 80
---	------

## QUALITATIVE CHANGES IN NEUTROPHILIC LEUKOCYTES

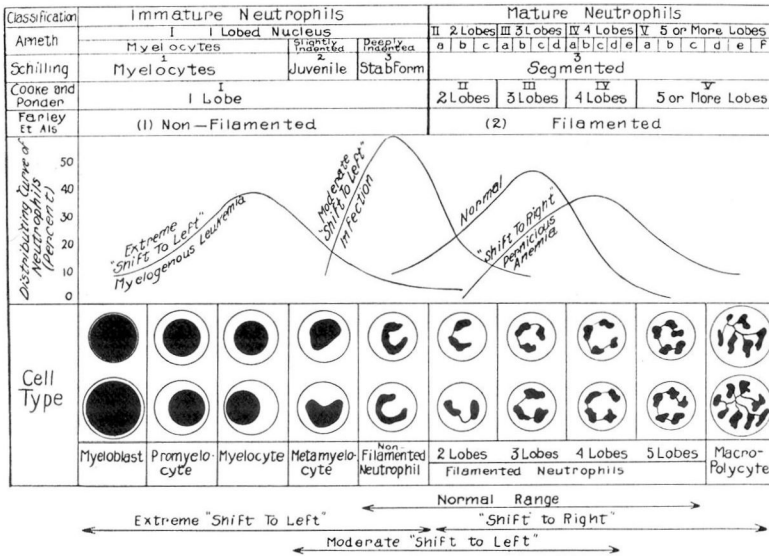


FIGURE 8: Diagram to correlate the different classifications of the neutrophil.

tion except to indicate the percentage of cells showing such changes and to use descriptive terms as mild, moderate, severe, and extreme to record the extent of the granulation. Kugel and Rosenthal<sup>5</sup> suggest a degenerative index based on the percentage of neutrophilic granulocytes showing basophilic or "toxic" granules. A differential count which measures satisfactorily the extent of immaturity of the neutrophilic granulocytes as well as the frequency of basophilic or "toxic" granulation is shown in Table 1.

The interpretation of qualitative changes in the neutrophilic granulocyte may be summarized as follows:

1. A neutrophilic leukocytosis with mature normal cells indicates the presence of an infection or toxemia to which the marrow is fully able to respond.

2. A neutrophilic leukocytosis with less mature cells or a significant increase in immature cells without an increase in the total count indicates either:
  - a. Some difficulty in response of the marrow to an infection or toxemia.
  - b. An overwhelming infection or toxemia requiring the marrow to deliver many granulocytes.

- a. Some difficulty in response of the marrow to an infection or toxemia.

- b. An overwhelming infection or toxemia requiring the marrow to deliver many granulocytes.

3. A normal count with some increase in immature cells indicates a mild infection or toxemia.

4. A leukopenia with immature cells indicates a depression of the marrow preventing the normal reaction to infection or toxemia.

5. A leukopenia, normal count, or leukocytosis with more mature cells than normal indicates that the cells are retained in the marrow without injury to the cells so that excessive maturation takes place.

6. The presence of "toxic" granulation with or without a leukocytosis and regardless of the maturity of the cells, indicates an infection or toxemia which is injuring the marrow.

#### SUMMARY

1. The correct interpretation of qualitative changes in granular leukocytes in reference to maturity or "toxic" granulation requires a fundamental understanding of factors influencing the development of cells in the marrow.

2. The filament non-filament count measures satisfactorily in most cases the degree of maturity of the neutrophilic granulocytes.

3. Basophilic or "toxic" granulation indicates the presence and severity of a toxemia affecting the marrow.

4. The value of the cells in defense depends on the quality of the cells even more than the number.

5. The interpretation of qualitative changes has been summarized.

#### REFERENCES

1. Arneht, J.: Die neutrophilen weissen Blutkörperchen bei Infektions-Krankheiten. Jena, G. Fischer, 1904.
2. Schilling, V.: Ein Praktisch und zur Demonstration brauchbarer Differential-leukozytometer mit Arnethscher Verschiebung des Blutbildes. Deutsch. med. Wchnschr., 37:1159-1163, 1911.
3. Cooke, W. E. and Ponder, Eric: The Polynuclear Count, Philadelphia, Lippincott, 1927.
4. Farley, D. L., St. Clair, H. and Reisinger, J. A.: Normal filament and nonfilament polymorphonuclear neutrophil count; its practical value as diagnostic aid, Am. J. M. Sc., 180:336-344 (September) 1930.
5. Kugel, M. A. and Rosenthal, N.: Pathologic changes occurring in polymorphonuclear leukocytes during progress of infections, Am. J. M. Sc., 183:657-667, (May) 1932.