

Nitrogen washout therapy for pneumothorax¹

Diane A. Butler, M.D.
James P. Orlowski, M.D.

Three episodes of bilateral spontaneous nontension pneumothoraces in 2 adolescents with malignancies who refused chest tube placement were treated with a high concentration of inspired oxygen (FiO_2 approaching 100%) administered via a tight-fitting nonbreathing oxygen reservoir mask. This technique of nitrogen washout is a useful, noninvasive method for the reduction of noncritical pneumothoraces, which may obviate the necessity for more invasive procedures, although it has no place in the treatment of pneumothorax causing cardiopulmonary compromise. Two physiologic principles are involved. Breathing a high inspired FiO_2 causes nitrogen to be washed out of the alveoli, venous blood, body tissues, and body cavities; this is known as "nitrogen washout." Second, a great decrease in total tissue gas tension while breathing a high inspired FiO_2 facilitates absorption of all gas from a closed body space.

Index terms: Nitrogen, washout therapy • Oxygen, therapy
• Pneumothorax
Cleve Clin Q 50:311–315, Fall 1983

The term "spontaneous pneumothorax" is used to describe the occurrence of a nontraumatic pneumothorax. It is often presumed to result from rupture of an emphysematous bleb on the pleural surface, although sarcoidosis, silicosis, infection, and neoplasm also have been noted as predisposing factors. Symptoms depend upon, and treatment is determined by, the extent of pulmonary collapse and whether a tension pneumothorax is present. When minimal air is present in a nontension pneumothorax and symptoms are absent or mild, observation alone may suffice. Massive or tension pneumothorax with acute dyspnea

¹ Pediatric Services, Inc., Parma Heights, OH (D.A.B.), and the Department of Pediatric and Adolescent Medicine (J.P.O.), The Cleveland Clinic Foundation. Submitted for publication April 1983; accepted June 1983.

and cyanosis requires emergency chest tube placement for removal of extrapleural air.

Spontaneous pneumothoraces tend to recur with increasing frequency after each attack (a second attack occurs in 50% of patients). For this reason, open thoracotomy with pleurectomy or poudrage (application of irritants such as talc or tetracycline to the pleural surfaces) to produce adherence of parietal to visceral pleura is often suggested. We report our experience with three episodes of nontension pneumothorax in 2 adolescent oncology patients who, having refused chest tube placement, were treated by breathing a high oxygen concentration through a non-rebreathing oxygen reservoir mask. Although the actual inspired FiO_2 in these patients was not measured, use of similar equipment is reported to produce an FiO_2 of almost 100%.¹ To our knowledge, this technique has not been recently reported as useful in the treatment of pneumothorax.

Case reports

Case 1. In April 1981, a 15-year-old boy was admitted to the hospital for treatment of bilateral pneumothoraces.

In 1977 at the age of 12 years, he was diagnosed as having diffuse histiocytic, non-Hodgkin's lymphoma of the cecum with metastases to the liver. The cecum was excised, and he began a three-year chemotherapy regimen, which included L-asparaginase, thioguanine, prednisone, carmustine (BCNU), daunomycin, hydroxyurea, vincristine, cytosine arabinoside, cyclophosphamide, and oral and intrathecal methotrexate. He received no radiation therapy.

In May 1977, interstitial pneumonia developed, which responded to trimethoprim-sulfamethoxazole, although an open lung biopsy revealed only a histiocytic interstitial infiltrate consistent with low-grade inflammation; cultures were negative.

In September 1980, after playing the drums in a band, the patient complained of left shoulder pain, and a chest roentgenogram demonstrated small (2% to 5%) bilateral pneumothoraces. He had no respiratory distress and was treated conservatively with rest. He was admitted to the hospital a month later after the pneumothoraces had enlarged to 20% on the right and 10% on the left (*Fig. 1*), and he complained of bilateral shoulder and chest pain. Arterial blood gas was normal on admission. Because the patient wished to avoid chest tube placement if possible, a trial of a high concentration of inspired oxygen was administered with a tight-fitting nonrebreathing oxygen reservoir mask for eight hours on each of three consecutive days. A chest roentgenogram on the fourth day, before discharge, showed considerable improvement (*Fig. 2*), and only minimal pneumothorax on the right and 5% on the left, and pain had resolved.

In April 1981, he experienced pain in the right side of the chest but no dyspnea after an episode of coughing and was again admitted with larger bilateral pneumothoraces: 30% on the right and 20% on the left (*Fig. 3*). Again, the patient's desire to avoid chest tube placement prompted the

initiation of conservative therapy, and after eight hours of oxygen breathing on three consecutive days, a roentgenogram showed bilateral pneumothoraces reduced to 5% (*Fig. 4*), and he was discharged symptom free.

Case 2. In September 1981, an 18-year-old boy was admitted to the hospital for treatment of bilateral pneumothoraces.

In April 1981, he had been found to have a synovial sarcoma (monoplastic) of the left anterior thigh with pulmonary metastases. Over the next five months, after surgical debriding of the tumor mass, he received several courses of chemotherapy (including cis-platinum, vincristine, adriamycin, 5-fluorouracil, and cyclophosphamide) and localized radiation therapy to the thigh. Pulmonary metastases persisted, and he gradually became more cachectic.

In September 1981, he became acutely dyspneic while receiving outpatient chemotherapy and was admitted with large bilateral pneumothoraces (*Fig. 5*). Dyspnea lessened with oxygen, and he refused chest tube placement, knowing that his disease was resistant to therapy and preferring to die without further painful procedures. His anemia (Hgb, 10.6 mg/dl) was corrected with transfusions, and he was given high inspired oxygen concentration for approximately eight hours on each of three consecutive days. His dyspnea improved, although repeat chest roentgenogram showed no change, and he was discharged; at home he received oxygen by face mask. He died at home a week later.

Discussion

The feasibility of accelerating absorption of air from a body cavity by breathing a high oxygen concentration was reported in the first half of this century by Schwab et al² and Fine et al,³ who described this technique for reducing the gaseous content of the postoperative intestine and the subarachnoid space after pneumoencephalography. The two principles involved are clearly described by Comroe.¹ First, the inhalation of high concentration oxygen reduces the entrance of nitrogen into the lungs and facilitates the gradual absorption of nitrogen from body cavities, such as the extrapleural space, with subsequent exhalation of nitrogen from the lungs; thus, the term "nitrogen washout." Secondly, however, the inhalation of 100% oxygen produces a decrease in total tissue gas tension to 146.5 torr, a significantly lower tension than the 760 torr in a closed body space, thereby facilitating absorption into the blood.

Absorption atelectasis, an acknowledged phenomenon associated with high FiO_2 breathing (usually 100% FiO_2) under pressure is an undesirable result of removal of gas from a compartment in direct communication with the lung alveoli. The risk of absorption atelectasis and other reported effects of oxygen breathing (alveolar and interstitial edema and hemorrhage) appear

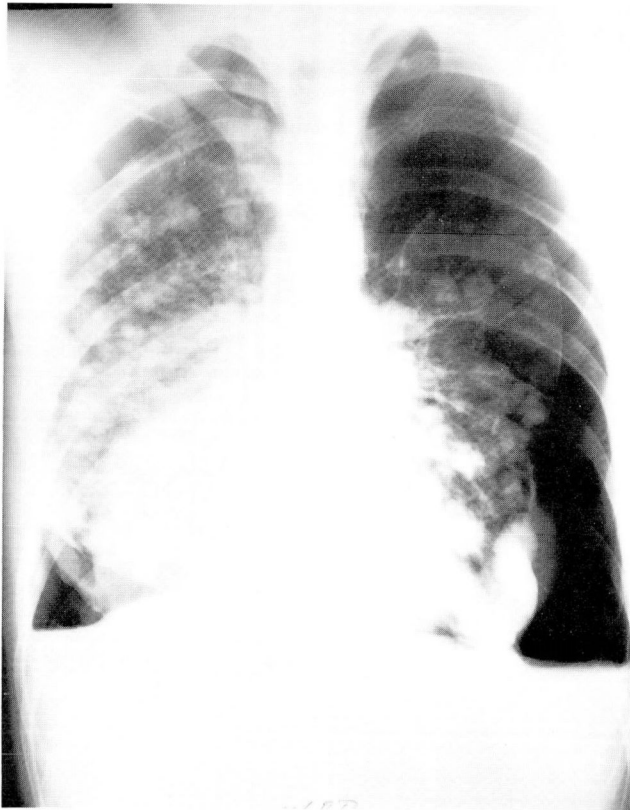


Fig. 5. Case 2. September 1981. Larger bilateral pneumothoraces, 30% on the right and 70% on the left, with multiple pulmonary metastases evident in both lungs.

to increase with prolonged exposure and hyperbaric administration of oxygen. Although completely safe limits are unknown, Van de Water et al⁴ were unable to demonstrate a change in pulmonary vasculature as measured by various physiologic factors in healthy men during periods of continuous exposure to 100% FiO₂ at one atmosphere for up to 12 hours. Likewise, Singer et al⁵ found no apparent difference between a group of postoperative cardiac patients receiving 100% FiO₂ for up to 48 hours and a similar group receiving a maximum FiO₂ of 42%.

Miller et al⁶, however, found that the lungs of dogs exposed to similar conditions for 48 hours demonstrated extensive atelectasis, intra-alveolar hemorrhage, and edema. Signs of respiratory distress (weakness, cough, tachypnea) were noted after 24 hours. Similarly, Barber et al⁷ demonstrated significantly greater impairment of lung function among irreversibly brain-damaged patients ventilated with pure oxygen than among a comparable group of patients ventilated with air. For these reasons, we chose to use high concen-

trations of inspired oxygen for only eight hours on each of three consecutive days.

In both patients reported here, because of the nature of their underlying pulmonary parenchymal abnormalities (fibrosis and metastases), it is possible that despite chest tube placement, the air leak would not have sealed, and the chest tube would have had to remain in place (and the patient hospitalized) until surgical treatment could be attempted (case 1) or for the rest of the patient's life (case 2).

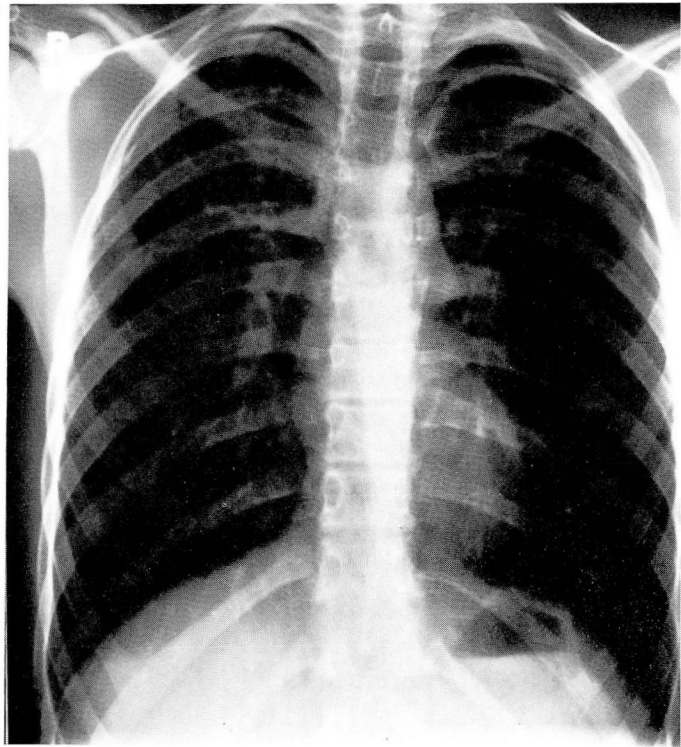
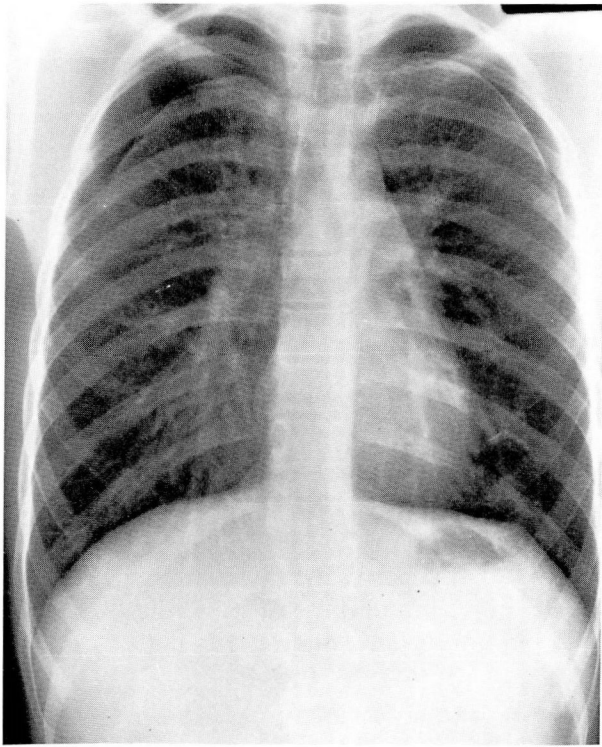
Although pneumothoraces may resolve spontaneously with strict bedrest, the data, especially in case 1, suggest that it was the oxygen therapy and not the bedrest that resulted in reduction of the noncritical pneumothoraces. The first episode of pneumothorax in case 1 was treated for one month with bedrest at home, and the pneumothoraces increased in size. In only three days treatment of high concentration oxygen by mask for eight hours each day, the pneumothoraces resolved almost completely, and the patient remained free of symptoms for eight months. When the pneumothoraces recurred after a bout of coughing, they again resolved with three days of nitrogen washout therapy for eight hours per day.

In case 2, the nitrogen washout technique was not successful in reducing the pneumothoraces, probably because of a continued air leak; but the oxygen therapy alleviated the patient's symptom of dyspnea and permitted him to die peacefully at home in his sleep.

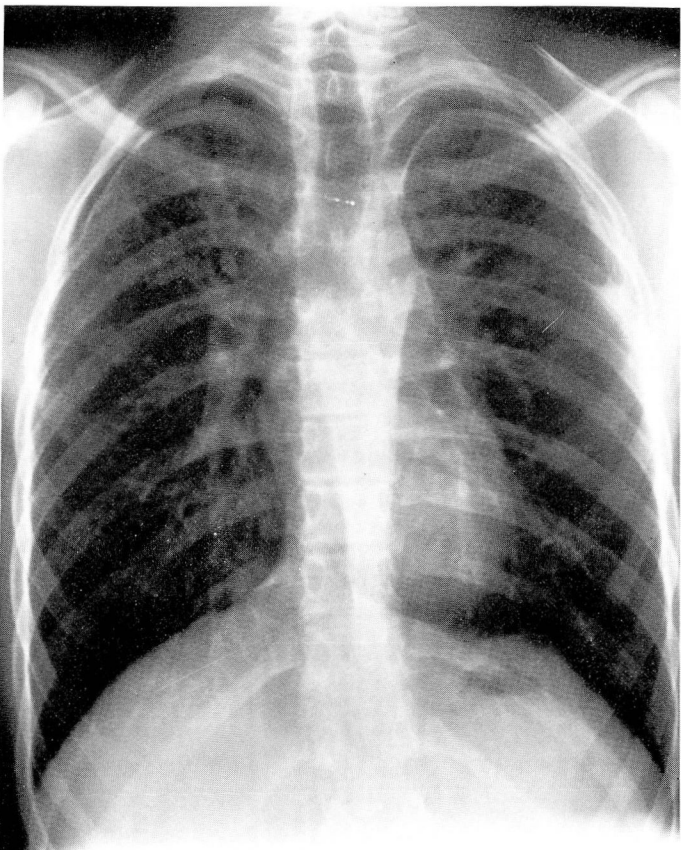
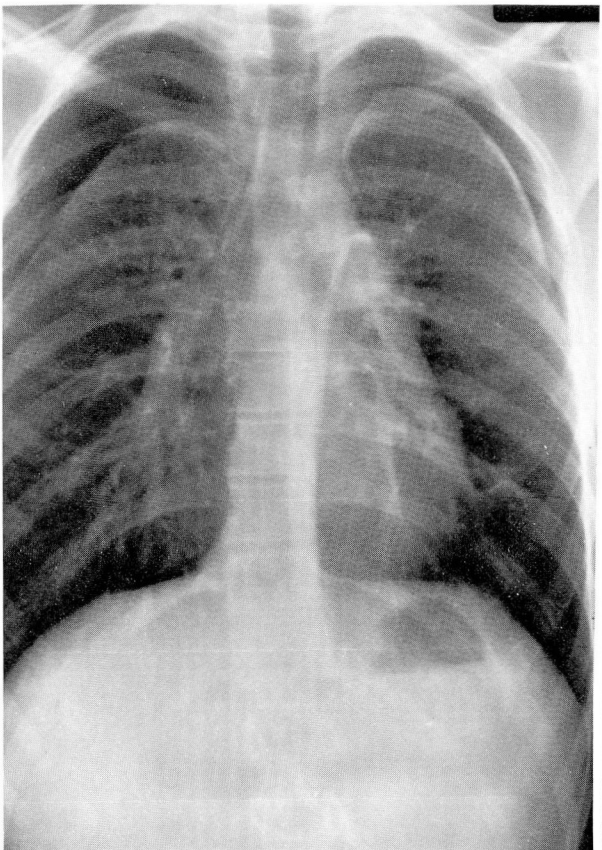
The desire to avoid invasive, painful, or frightening procedures in children and adolescents and in patients with terminal illness in whom traditional treatment of pneumothorax would not only be invasive, but would also prolong hospitalization, provides additional incentive for attempting this technique. Conservative treatment has no place, however, in the management of patients with pneumothorax who exhibit cardiorespiratory compromise. Immediate chest tube placement is the treatment of choice for such patients.

References

1. Comroe JH. *Physiology of Respiration. An Introductory Text.* 2d ed. Chicago, Year Book Medical Publishers, Inc., 1974, pp 275-277.
2. Schwab RS, Fine J, Mixer WJ. The reduction of post-encephalographic symptoms by inhalation of 95% oxygen. *J Nerv Ment Dis* 1936; **84**:316-321.



1, 2



3, 4

Fig. 1. Case 1. September 1980. Bilateral pneumothoraces, 20% on the right and 10% on the left, which failed to respond to bedrest.

Fig. 2. Case 1. September 1980. Improvement of pneumothoraces (5% on both sides) after trial of oxygen breathing (nitrogen washout) for eight hours on each of three consecutive days.

Fig. 3. Case 1. April 1981. Bilateral pneumothoraces, 30% on the right and 20% on the left, which developed acutely after a bout of coughing.

Fig. 4. Case 1. April 1981. Improvement of pneumothoraces (5% bilaterally) after trial of oxygen breathing (nitrogen washout) for eight hours on each of three consecutive days.

3. Fine J, Frehling S, Starr A. Experimental observations on effect of 95 percent oxygen on absorption of air from body tissues. *J Thorac Surg* 1935; **4**:635-642.
4. Van De Water JM, Kagey KS, Miller IT, Parker DA, O'Connor NE, Sheh JM, et al. Response of the lung to six to 12 hours of 100 percent oxygen inhalation in normal man. *N Engl J Med* 1970; **283**:621-626.
5. Singer MM, Wright F, Stanley LK, Roe BB, Hamilton WK. Oxygen toxicity in man: a prospective study in patients after open heart surgery. *N Engl J Med* 1970; **283**:1473-1478.
6. Miller WW, Waldhausen JA, Rashkind WJ. Comparison of oxygen poisoning of the lung in cyanotic and acyanotic dogs. *N Engl J Med* 1970; **282**:943-947.
7. Barber RE, Lee J, Hamilton WK. Oxygen toxicity in man: a prospective study in patients with irreversible brain damage. *N Engl J Med* 1970; **283**:1478-1484.