

A clinical vignette: the clinical significance of systolic-diastolic bruits in the carotid arteries¹

Robert A. Graor, M.D.
Victor G. de Wolfe, M.D.
Ian Elliott, M.D.²

Most authorities agree that an arterial bruit that extends into diastole usually indicates severe stenosis in the underlying artery. Less well known is that a systolic-diastolic bruit at the carotid artery bifurcation indicates that, not only is the underlying artery severely narrowed, but the contralateral carotid artery is also frequently severely stenosed or occluded. In 1956, Myers described systolic-diastolic bruits in the aortic arch syndrome and suggested the hemodynamic etiology. The severity of the lesions in 40 patients with a systolic-diastolic bruit seen at The Cleveland Clinic Foundation over a one year period was checked by reviewing the corresponding arteriograms. Ipsilateral to the bruit, 88% of the carotid arteries were narrowed by greater than 70%. On the side contralateral to the bruit, 80% of the carotid arteries were narrowed by greater than 70%. These studies confirm that a systolic-diastolic bruit often indicates severe bilateral carotid artery disease.

Index terms: Bruit • Carotid arteries, stenosis
Cleveland Clin Q 51: 155–158, Spring 1984

Auscultation of the carotid arteries to detect the presence of bruits should be part of every physical examination. The correlation between the presence of a carotid bruit and a significant lesion in the extracranial carotid arterial system has been well studied.¹⁻⁴ Not only the presence, but also several characteristics of the bruit, such as location, intensity, pitch, and length make a clinical diagnosis of carotid stenosis highly accurate. We have been particularly interested in the carotid bruit which extends into diastole. A systolic-diastolic bruit appears to be a marker of severe occlusive disease, not only on the audible side, but also on

¹ Departments of Peripheral Vascular Disease (R.A.G., V.G.D.) and Endocrinology (I.E.), The Cleveland Clinic Foundation. Submitted for publication Aug 1983; revision accepted Nov 1983.

² Present address: 4235 Secor Rd., Toledo, OH 43623.

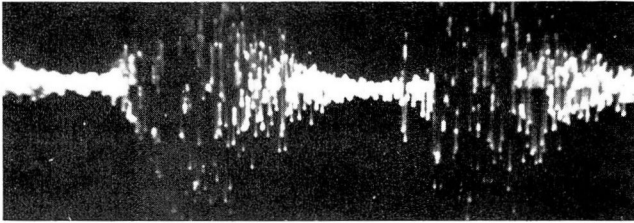


Fig. 1. Phonoangiogram, carotid systolic-diastolic bruit.

the opposite side, even when a contralateral bruit is not present.

Myers et al⁵ described a continuous, systolic-diastolic murmur in patients with the aortic arch syndrome. These murmurs were heard at the base of the neck anteriorly near the proximal common carotid or innominate arteries on the right and common carotid and subclavian arteries on the left. Myers speculated that the diastolic component arose when there was a high pressure gradient across a highly stenotic artery with insufficient collateral circulation around the obstruction to maintain adequate distal pressure. Therefore, flow continues during the diastolic phase of the cardiac cycle and produces the diastolic component of the bruit. Myers' report did not describe a diastolic component to bruits located at the carotid bifurcation.

Atherosclerotic disease of the common carotid bifurcation is probably responsible for 25% to 35% of ischemic strokes.⁶⁻⁹ Patients who experience transient ischemic attacks (TIAs) presum-

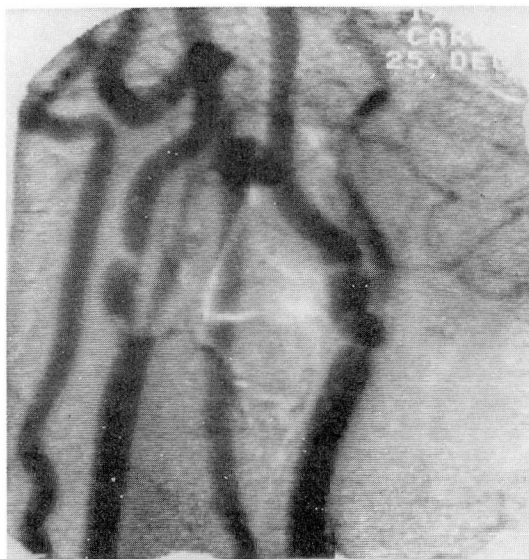

Fig. 2. Digital subtraction angiogram of the carotid arteries in a patient with a left carotid systolic-diastolic bruit.

ably have a similar incidence of carotid artery bifurcation atherosclerosis. Some of these patients, especially those with severe symptoms, have no bruit on the side appropriate to their neurologic events, but instead have a loud bruit with a diastolic component on the contralateral side. In these patients, apparently sufficient flow occurs to produce a bruit not only during systole, but also during diastole. This phenomenon may be demonstrated by phonoangiography (Fig. 1). Most patients with systolic-diastolic bruits have severe carotid disease, frequently with severe stenosis or occlusion of the internal carotid artery on the side contralateral to the bruit (Fig. 2). To document this previously unreported clinical finding, we investigated 40 patients with systolic-diastolic carotid artery bruits from August 1981 to July 1982.

Methods

Forty patients were studied in a prospective consecutive fashion. Presence of a systolic-diastolic carotid bruit in each of the 40 patients was documented by auscultation by a minimum of two experienced examiners and confirmed in 5 patients by phonoangiography. All patients underwent conventional angiography by the Seldinger technique or intravenous digital subtraction angiography (DSA). The films were reviewed independently by a staff neuroradiologist, a member of the Peripheral Vascular Medicine Department, and a member of the Vascular Surgery Department. Because of advanced atherosclerosis, each patient required carotid endarterectomy on the side producing the diastolic bruit, the opposite side, or both. The pathologic diagnosis in all specimens removed at surgery was atherosclerotic disease. Degree of carotid artery stenosis was based on the estimated percentage of the lumen obstructed on the angiogram and the operative findings.

Results

In general, a systolic-diastolic bruit heard at the carotid bifurcation did correlate with severe bilateral carotid atherosclerosis. All patients with systolic-diastolic carotid bruits had greater than 70% stenosis either ipsilateral or contralateral to the bruit. Thirty-five (88%) of the 40 patients had greater than 70% stenosis in the internal carotid artery producing the systolic-diastolic bruit. Twenty of the 40 patients (50%) had greater than 90% stenosis, and none had occlusion on the ipsilateral side. Five patients in this

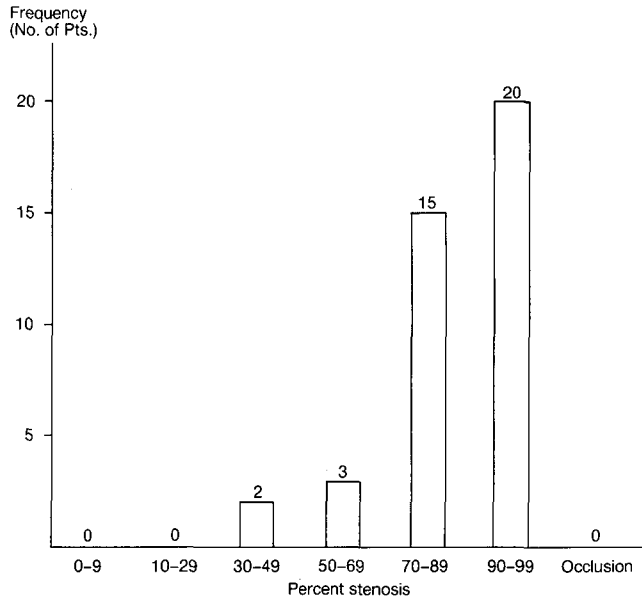


Fig. 3. Distribution and frequency of carotid artery stenosis ipsilateral to the systolic-diastolic bruit.

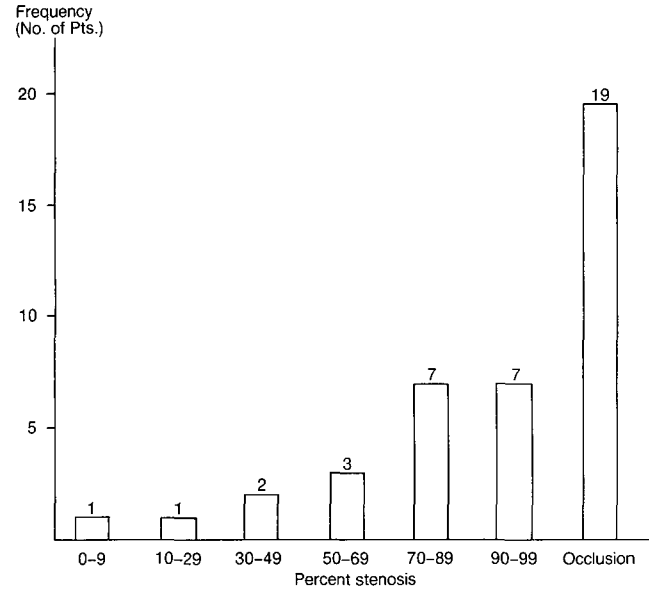


Fig. 4. Distribution and frequency of carotid artery stenosis contralateral to the systolic-diastolic bruit.

group had less than 70% stenosis (Fig. 3; Table 1).

Thirty-two of the 40 patients (83%) had greater than 70% stenosis, and 26 patients (65%) had greater than 90% stenosis or occlusion in the internal carotid artery contralateral to the artery with the systolic-diastolic bruit. Nineteen of these 40 patients (48%) had an occlusion of the contralateral carotid artery, 7 patients (18%) had greater than 90% obstruction, and 7 (18%) had 70% to 90% stenosis of the contralateral carotid artery (Fig. 4). No bruits were heard in the patients with occluded internal carotid arteries contralateral to the systolic-diastolic bruit. Seven patients (18%) had mild disease, and one patient had a normal contralateral carotid artery and no disease (Table).

Discussion

Our interest in systolic-diastolic bruits was stimulated by the clinical impression that patients with this finding had a high incidence of occlusion or severe disease involving the contralateral internal carotid artery. This study confirms our impression. Thirty-five percent of the 40 patients in this investigation had greater than 70% stenosis, and 48% had occlusion of the contralateral internal carotid artery. Therefore, 83% of the study group had greater than 70% stenosis or occlusion of the contralateral carotid artery. Eighty-eight percent of patients had greater than

70% stenosis of the ipsilateral internal carotid artery, but no patients had occlusion of the ipsilateral internal carotid. Therefore, a systolic-diastolic bruit heard in the neck over the carotid bifurcation should alert the examiner to the probable presence of severe disease in the contralateral carotid artery with the likelihood of occlusion of the internal carotid artery when there is no bruit on the other side.

From our observations and Myers', it appears that rapid, turbulent flow continues during the diastolic phase of the cardiac cycle because of a high pressure gradient across the stenotic internal carotid artery. This rapid, turbulent flow causes arterial wall vibration and the diastolic bruit. The principal collateral pathway in patients with significant occlusive disease of the carotid arteries is the contralateral carotid system. If this

Table. Angiographic findings in 40 patients with systolic-diastolic bruits. Percent stenosis is indicated ipsilateral or contralateral to the bruit.

	Systolic-diastolic bruit	
	Ipsilateral	Contralateral
Severe stenosis (70-99%)	35 (88%)	14 (35%)
Occlusion	0	19 (48%)
Mild or no disease	5 (13%)	7 (18%)
TOTAL	40	40

collateral pathway is obliterated by severe occlusive disease, the pressure distal to the stenotic artery being studied is so low that flow is not only rapid and turbulent during systole, but also continues during diastole, producing the typical systolic-diastolic bruit. In none of our patients was the external carotid system implicated in the production of a diastolic component to a systolic bruit. We have found no other studies in the literature concerning the implications and mechanism of systolic-diastolic carotid bruits. In their review of patients with systolic-diastolic murmurs caused by the aortic arch syndrome, Myers and associates⁵ described severe neurologic symptoms and signs caused by complete occlusion of the left subclavian, left common carotid, and right internal carotid arteries with extreme narrowing of the orifice of the innominate artery. Myers et al⁵ also produced a systolic-diastolic bruit in an animal model in which an artery was stenosed by a clamp proximal to complete occlusion. There was no collateral flow in the segment between the clamps, and the diastolic bruit was produced by gradually increasing the proximal stenosis until the diastolic component appeared. The same experiment had been performed earlier by Dornhorst and Sharpey-Shafer.¹⁰

Thus, it appears that in arterial systems with poor collateral potential, systolic-diastolic bruits are common in conjunction with high-grade stenoses. The renal artery is a typical example of such a system. The kidney is an end-organ, and when stenosis of the renal artery becomes sufficiently high-grade to cause rapid and turbulent flow during diastole, the diastolic component occurs. Although systolic bruits are commonly heard in the abdominal aorta and in the iliac and femoral arteries, rarely is a diastolic component heard at rest. This is because the rich collateral circulation in these areas maintains normal diastolic pressure. Exercise to the point of severe claudication produces maximal dilatation of the distal arterial bed and a systolic-diastolic bruit in the main artery below the occlusive disease.

With regard to treatment, the presence of a carotid artery atheroma in the symptomatic patient is less controversial than is the asymptomatic patient with the same disease. Most physicians agree that the symptomatic patient should have a carotid endarterectomy if there is an appropriate atherosclerotic lesion and the risk is acceptable. We believe the asymptomatic patient with a

severely stenotic carotid artery should have a prophylactic carotid endarterectomy if he is an acceptable candidate and the risk factor in arteriography and surgery is reasonable.

Summary

Forty patients with systolic-diastolic bruits over the carotid bifurcation were examined and underwent conventional angiography. All patients had atherosclerotic disease at one or both carotid bifurcations.

Thirty-five patients (88%) had greater than 70% stenosis of the ipsilateral internal carotid artery. There were no occlusions on the ipsilateral side. On the side contralateral to the systolic-diastolic bruit, 14 patients (35%) had greater than 70% stenosis, and 19 patients (48%) had internal carotid occlusions.

During auscultation for a carotid bruit, not only should intensity and pitch be noted, but also whether or not the sound extends into diastole. If it does, these patients should be studied angiographically and carotid endarterectomy considered if severe disease is found and the patient is an acceptable candidate for angiography and surgery.

References

1. Fisher CM. Cranial bruit associated with occlusion of the internal carotid artery. *Neurology* 1957; **7**:299-306.
2. David TE, Humphries AW, Young JR, Beven EG. A correlation of neck bruits and arteriosclerotic carotid disease. *Arch Surg* 1973; **107**:729-731.
3. Barnett HJM. Pathogenesis of transient ischemic attacks, 10th Princeton Conference on Cerebrovascular Disease. New York, Raven Press, 1976.
4. Ziegler DK, Zileli T, Dick A, Sebaugh JL. Correlation of bruits over the carotid artery with angiographically demonstrated lesions. *Neurology* 1971; **21**:860-865.
5. Myers JD, Murdaugh HV, McIntosh HD, Blaisdel RK. Observations on continuous murmurs over partially obstructed arteries: an explanation for the continuous murmur found in the aortic arch syndrome. *Arch Int Med* 1956; **97**:726-737.
6. Mohr JP, Caplan LR, Melski JW, et al. The Harvard Cooperative Stroke Registry: a prospective registry. *Neurology* 1978; **28**:754-762.
7. Mohr JP. Asymptomatic carotid artery disease (editorial). *Stroke* 1982; **13**:431-433.
8. Javid H, Ostermiller WE Jr, Hengesh JW, et al. Natural history of carotid bifurcation atheroma. *Surgery* 1970; **67**:80-86.
9. Duncan GW, Pressin MS, Mohr JP, Adams RD. Transient cerebral ischemic attacks. *Adv Int Med* 1976; **21**:1-20.
10. Dornhorst AC, Sharpey-Shafer EP. Collateral resistance in limbs with arterial obstruction: spontaneous changes and effects of sympathectomy. *Clin Sci* 1951; **10**:371-381.