

## Silicone pericarditis<sup>1</sup>

Norman B. Ratliff, M.D.  
James T. McMahon, Ph.D.  
Earl K. Shirey, M.D.  
Laurence K. Groves, M.D.

A 62-year-old white man was referred to the Cleveland Clinic for evaluation of dyspnea and chest pain. He had moderate aortic insufficiency and severe three-vessel coronary artery atherosclerosis. Some years before, epicardial pacemaker leads had been inserted, which were subsequently abandoned. At surgery for replacement of the aortic valve, and bypass grafts to the affected coronary arteries, an exuberant polypoid villonodular pericarditis was encountered. Frozen sections revealed a severe foreign body giant cell reaction. Light microscopy examination confirmed the foreign body reaction and revealed abundant foreign material in the pericardium. This was identified as silicone via electron microscopy coupled with energy dispersive analysis of emitted x-rays (EDAX). Silicone had inadvertently been introduced into the pericardium during insertion of epicardial pacemaker leads. The following report illustrates both the severity of the tissue reaction to silicone compounds introduced into body cavities, and the utility of EDAX in the identification of foreign material.

**Index terms:** Foreign body reaction • Pacemaker, artificial • Pericarditis

**Cleve Clin Q** 51:185-189, Spring 1984

Silicone and compounds containing it are widely used in medicine. Silicone is used in breast augmentation and other cosmetic procedures, both legally and illicitly. Silicone compounds are important constituents of the tubing used for hemodialysis and cardiopulmonary bypass. Silicone adhesives are used for the bonding of Silastic elastomers and other implantable synthetics,

<sup>1</sup> Departments of Pathology (N.B.R., J.T.M.), Cardiology (E.K.S.), and Thoracic and Cardiovascular Surgery (L.K.G.), The Cleveland Clinic Foundation. Submitted for publication Oct 1983; accepted Nov 1983.

including electrical connections of pacemaker leads.

Previously, silicone has been difficult to identify in tissues.<sup>1,2</sup> It does not take any known histologic stains, does not polarize (in contrast to silica), and previous descriptions of tissue reactions to silicone have relied on either a known injection of silicone into the tissue under study, unequivocal clinical history of silicone injection, or chemical analysis of the affected tissue or fluids.<sup>1-10</sup> However, a relatively new technique permits the rapid identification of silicone and other elemental substances in electron microscopy specimens by spectroscopic analysis of x-rays emitted from the specimen under excitation of the electron beam.<sup>11,12</sup> In the case reported here, via this technique, silicone was shown to be the cause of an exuberant pericarditis in a patient who had had epicardial pacemaker leads implanted some years before.

### Case report

A 62-year-old white man was told approximately 40 years ago that he had a cardiac murmur and that he probably had had rheumatic fever as a child. In 1975 he was evaluated at another institution and was told that he had a very slow heart beat. A pacemaker was installed and subsequently replaced in 1976 and 1980. He was referred to the Cleveland Clinic for evaluation of aortic insufficiency and possible coronary artery atherosclerosis. At the time of examination here, he complained of dyspnea on exertion and non-radiating pressure-like pain in the anterior chest, which was not precipitated by any particular activity, and which had been present for approximately one year. The patient also complained of a sharper chest pain, which was provoked by exertion and relieved by rest.

He was a well-developed, well-nourished man in no acute distress. Blood pressure was 100/80 mm Hg, and pulse was

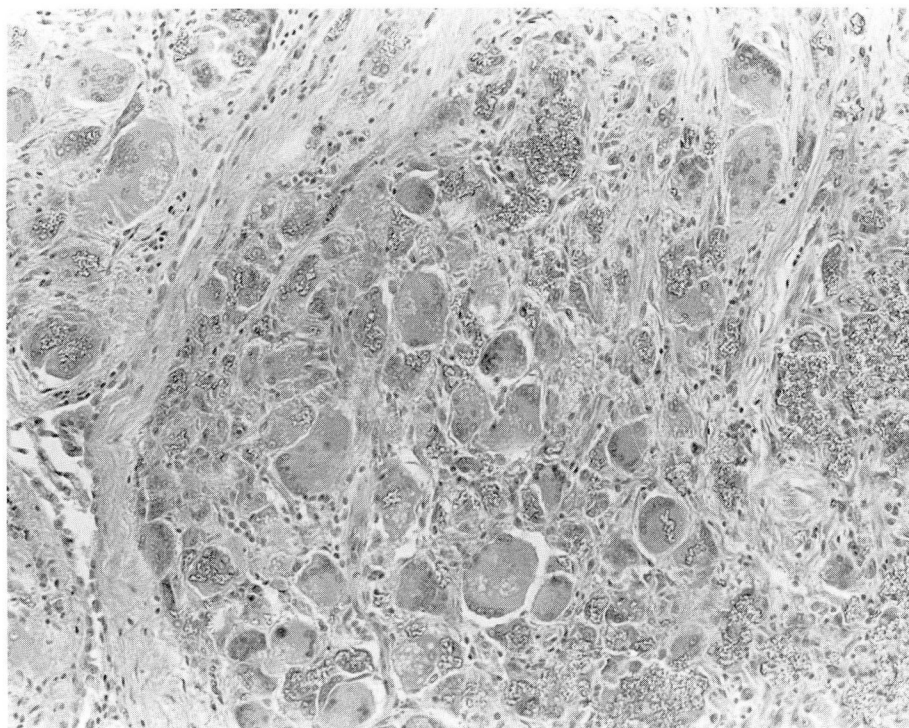
64 beat/minute, regular and bounding. A grade I-II/VI systolic murmur at the base radiating to the neck vessels and a grade III/VI diastolic murmur at the base radiating to the right and left sternal borders were detected by cardiac auscultation. The left ventricle was moderately enlarged, and there was moderate dilatation of the ascending aorta. Laboratory data including SMA-18, complete blood count (CBC), and urinalysis were all within normal limits. Cardiac catheterization revealed moderate aortic insufficiency and severe three-vessel coronary artery atherosclerosis. He was taken to surgery for planned replacement of the aortic valve and for saphenous vein bypass grafts to the affected coronary arteries. Abandoned epicardial pacemaker leads were noted and removed. When the pericardium was opened, the surgeons encountered an exuberant polypoid villonodular pericarditis. It did not appear to be constrictive or obliterative, but did obscure the coronary artery anatomy. Multiple frozen sections revealed a severe foreign body giant cell reaction. The planned surgery was then completed without incident, and the patient made an uneventful recovery.

Examination of pericardial biopsy specimens by light microscopy revealed a thickened pericardium with large numbers of multinucleated foreign body giant cells admixed with a few lymphocytes and plasma cells embedded in loose fibrous connective tissue (*Fig. 1*). Abundant foreign material was present within the giant cells and extracellularly in the connective tissue. The foreign material was not fibrillar, and appeared as small, irregular globules and large clusters of apparently coalesced globules. It did not stain and was

almost colorless. It was slightly refractile but did not polarize.

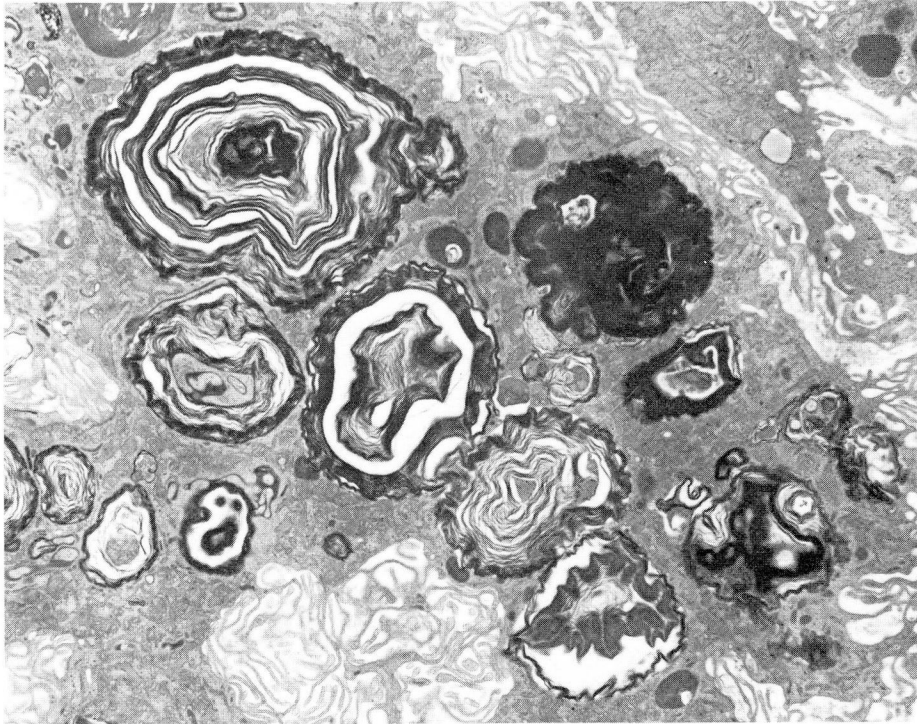Specimens for electron microscopy were sequentially fixed in cacodylate-buffered glutaraldehyde and phosphate-buffered osmium tetroxide. Thin sections were double-stained with lead citrate and uranyl acetate and mounted on carbon-coated copper grids. Sections for elemental analysis were not stained and were mounted on nylon grids. Electron microscopy and elemental analysis were performed via a Philips 400 transmission electron microscope equipped with a Philips scanning transmission electron microscopy attachment, a beryllium emission detector, and an EDAX system for energy dispersive analysis of emitted x-rays.

The foreign material was seen in three forms in the cytoplasm of the giant cells. The first was multilayered osmiophilic membranes contained in variable size membrane-lined inclusions (*Fig. 2*). The second was relatively small, partially osmiophilic, very electron-dense material without apparent substructure in small membrane-lined vacuoles (*Fig. 3*). In some vacuoles this material was admixed with protein. The third was large, irregular nonmembrane-limited cytoplasmic inclusions, which contained an amorphous material of variable osmiophilia, substantial portions of which had dropped out of the sections (*Fig. 4*). This appearance initially suggested a saturated lipid. However, upon examination by EDAX, pure silicone peaks in high concentration were recorded over numerous inclusions from several different stained and unstained sections (*Fig. 5*).

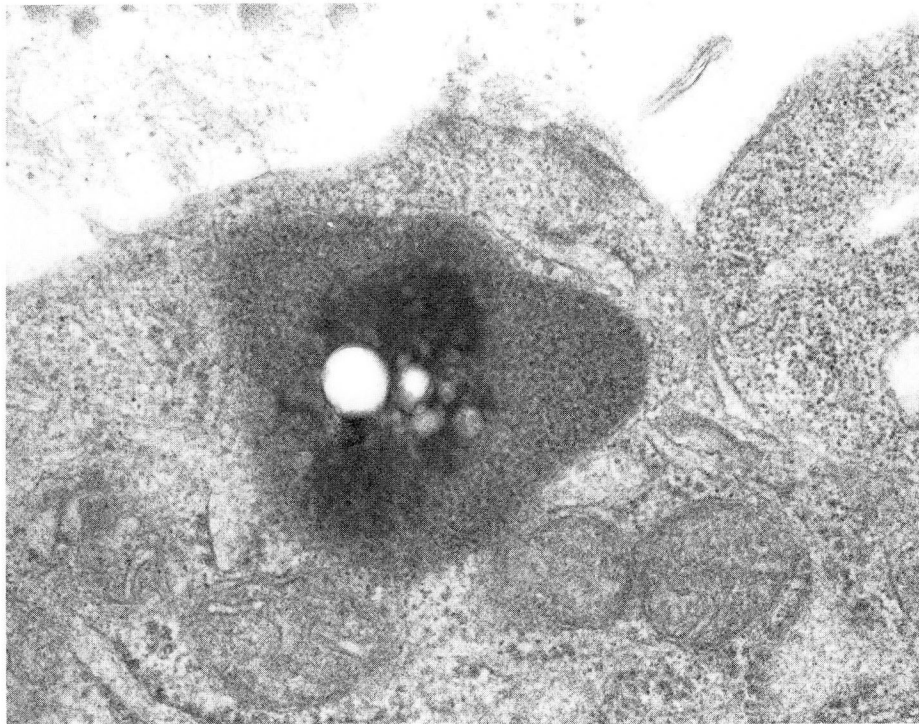


**Fig. 1.** Pericardial biopsy, light micrograph. Numerous multinucleated foreign body giant cells lie in loose connective tissue. Within the cytoplasm of several of the giant cells are slightly refractile, irregular silicone globules. Abundant similar extracellular foreign material is also present (hematoxylin and eosin  $\times 125$ ).



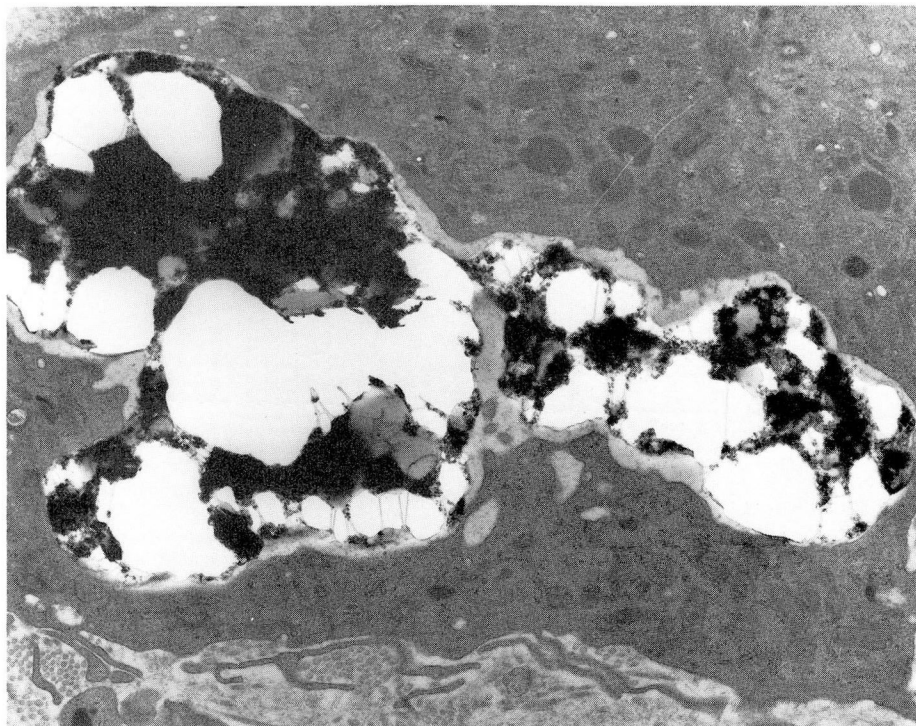


**Fig. 2.** Pericardial biopsy, electron micrograph. Multilayered osmiophilic membranes in variable size membrane-lined inclusions in the cytoplasm of a giant cell ( $\times 5500$ ).



**Fig. 3.** Pericardial biopsy, electron micrograph. Small, electron-dense, partially osmiophilic material without apparent substructure in a membrane-lined vacuole in a giant cell. The electron-dense material in the center of the vacuole is surrounded by less dense, granular material which has the appearance of protein ( $\times 58,000$ ).





**Fig. 4.** Pericardial biopsy, electron micrograph. Large, irregular, nonmembrane-limited cytoplasmic inclusion in a giant cell. The inclusion is filled with an electron-dense, amorphous material of variable density, some of which has dropped out of the section ( $\times 9800$ ).

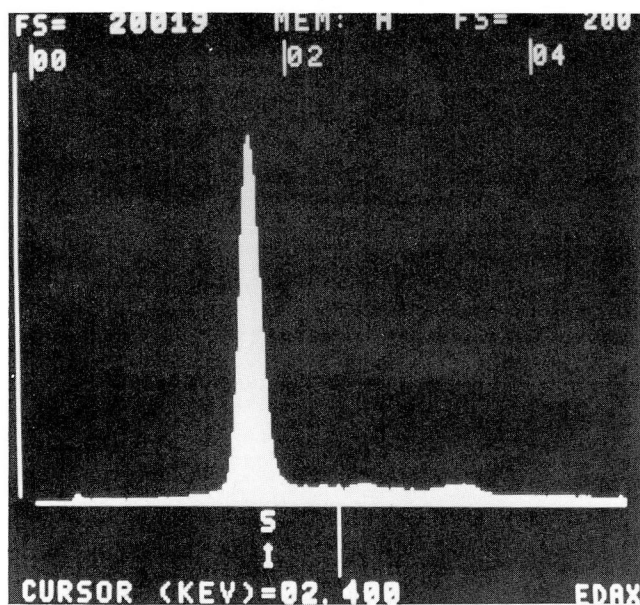
## Discussion

Abundant evidence suggests that silicone can induce foreign body reactions, including granulomas, in various human and animal tissues.<sup>1-10</sup>

Early attention was focused on local reactions to injectable silicone (breast augmentation), but it was later recognized that a systemic illness can be produced by injectable silicone and by silicone gel.<sup>2,5</sup> Recent reports suggest that in patients on long-term hemodialysis, silicone migrating from blood pump tubing may produce granulomatous hepatitis and hepatic granulomas.<sup>8-10</sup> Silicone has also been identified as the etiologic agent in a severe acute pneumonitis that developed after illicit silicone injection.<sup>2</sup>

Silastic silicone adhesive (Dow Corning) is commonly used to secure the connections between pacemaker electrodes and generator. Therefore, it seems reasonable to assume that silicone was inadvertently introduced into the pericardium of our patient when the epicardial pacemaker leads were originally inserted or during replacement, thereby initiating the exuberant pericardial foreign body reaction. Caution should be exercised when using silicone substances that might enter body cavities.

This case illustrates the extraordinary utility of EDAX coupled with electron microscopy in the identification of foreign materials in tissue samples. No special preparation or chemical tests are required. Specimens need not be initially pro-



**Fig. 5.** EDAX spectrum of cytoplasmic inclusion. Note the pure, sharp silicone peak.

cessed for electron microscopy. They can be retrieved from paraffin-embedded blocks, and even from histologic sections that have already been mounted on glass slides. In this case, with no tissue or fluid available for chemical analysis and no distinct historical clues, identification of the foreign material would have been extremely difficult without EDAX.

## References

1. Nosanchuk JS. Silicone granuloma in breast. *Arch Surg* 1968; **97**:583-585.
2. Chastre J, Basset F, Viau F, et al. Acute pneumonitis after subcutaneous injections of silicone in transsexual men. *N Engl J Med* 1983; **308**:764-767.
3. Rees TD, Ballantyne DL Jr, Seidman I, Hawthorne GA. Visceral response to subcutaneous and intraperitoneal injections of silicone in mice. *Plast Reconstr Surg* 1967; **39**:402-410.
4. Ben-Hur N, Ballantyne DL Jr, Rees TD, Seidman I. Local and systemic effects of dimethylpolysiloxane fluid in mice. *Plast Reconstr Surg* 1967; **39**:423-426.
5. Uretsky BF, O'Brien JJ, Courtiss EH, Becker MD. Augmentation mammoplasty associated with a severe systemic illness. *Ann Plast Surg* 1979; **3**:445-447.
6. Christie AJ, Weinberger KA, Dietrich M. Silicone lymphadenopathy and synovitis: complications of silicone elastomer finger joint prostheses. *JAMA* 1977; **237**:1463-1464.
7. Cronin TD, Brauer RO. Augmentation mammoplasty. *Surg Clin North Am* 1971; **51**:441-452.
8. Parfrey PS, O'Driscoll JB, Paradinas FJ. Refractile material in the liver of haemodialysis patients. *Lancet* 1981; **1**:1101-1102.
9. Bommer J, Ritz E, Waldherr R, Gastner M. Silicone cell inclusions causing multiorgan foreign body reaction in dialysed patients. *Lancet* 1981; **1**:1314.
10. Leong AS-Y, Disney APS, Gove DW. Spallation and migration of silicone from blood-pump tubing in patients on hemodialysis. *N Engl J Med* 1982; **306**:135-140.
11. Woldseth R. X-ray energy spectrometry. Berkeley, Kevex Corp., 1973.
12. Abraham JL. Recent advances in pneumoconiosis: the pathologist's role in etiologic diagnosis. [In] Thurlbeck WM, Abell MR, eds. *Lung: Structure, Function, and Disease*. Baltimore, Williams & Wilkins, 1978, pp 96-137.